

## INTRACRANIAL EPIDURAL HEMATOMA IN NEWBORN INFANTS: CLINICAL STUDY OF 15 CASES

### Rachel Heyman, M.D.

Department of Pediatrics,  
CHRU Pontchaillou,  
Rennes, France

### Anne Heckly, M.D.

Department of Obstetrics and  
Gynecology,  
CHRU Pontchaillou,  
Rennes, France

### Joseph Magagi, M.D.

Department of Pediatrics,  
CHRU Pontchaillou,  
Rennes, France

### Patrick Pladys, M.D.

Department of Pediatrics,  
CHRU Pontchaillou,  
Rennes, France

### Abderrahmane Hamlat, M.D.

Department of Neurosurgery,  
CHRU Pontchaillou,  
Rennes, France

### Reprint requests:

Abderrahmane Hamlat, M.D.,  
Service de Neurochirurgie,  
CHRU Pontchaillou,  
Rue Henri Le Guilloux,  
35000 Rennes Cedex 2, France.  
Email: hamlat.abd@wanadoo.fr

Received, February 21, 2005.

Accepted, June 8, 2005.

**OBJECTIVE:** Epidural hematoma (EDH) in newborn infants is rare. We have described the history of 15 newborns with EDH to provide a better understanding of this pathology.

**METHODS:** This is a descriptive case series study using a retrospective review of the medical records of newborns who were admitted to the Pediatric Intensive Care Unit and Neurosurgery Department with the diagnosis of birth EDH over a 24-year period (1979–2002).

**RESULTS:** There was no sex predominance, and most of the mothers were young, nulliparous women. The time latency from birth to the first signs varied from 0 to 24 hours. Clinical presentation was nonspecific: seizures and hypotonia were the main symptoms. The parietal area was the most frequent location. Surgical drainage was required in nine patients, and no deaths were reported.

**CONCLUSION:** This report highlights the clinicoradiological characteristics of newborn EDH, which occurs more frequently in newborns that experienced difficult delivery from a nulliparous mother. Surgery is not a rule; some patients can be managed with conservative treatment. The outcome is generally good.

**KEY WORDS:** Birth trauma, Difficult delivery, Epidural hematoma, Intracranial, Newborn infants, Treatment

*Neurosurgery* 57:924-929, 2005

DOI: 10.1227/01.NEU.0000180026.73246.bf

www.neurosurgery-online.com

Epidural hematoma (EDH) in newborn infants is rare (2, 5, 24). According to Yamamoto et al. (38), only 31 cases have been reported and most often as case reports (4, 14, 20, 21, 22, 29).

The present study reports a descriptive case series study using a retrospective review of 15 cases of EDH to provide a better understanding of the clinico-radiological significance and to give a prognosis for newborns with EDH. To our knowledge, this is the largest series of EDH in newborns reported up to now.

### MATERIALS AND METHODS

The study was carried out retrospectively on all consecutive newborns who were admitted to the Pediatric Intensive Care Unit and Neurosurgical Department between January 1978 and December 2002. The study includes all patients that presented with an isolated history of EDH or EDH associated with other intracranial injuries owing to birth trauma. The medical case histories of 15 babies were reviewed. All babies underwent neurological, physical, and psychomotor examinations,

and all had a computed tomographic (CT) scan or a magnetic resonance imaging (MRI) scan between Day 1 and Day 5, which revealed the EDH.

Patient outcome was classified based on the follow-up evaluation assessed by neurological and neuropsychomotor examinations. The Denver Developmental Screening Test is widely used in pediatric units for screening developmental delays in newborns and children. We have retrospectively classified these patients into three groups: Group 1 (G1) had a normal neurological and psychomotor examination, Group 2 (G2) had moderate neurological deficits or psychomotor development, and Group 3 (G3) had severe neurological or psychomotor disability. Patients who presented with other intracranial conditions without an EDH such as subdural hematoma, cerebral contusion, intracerebral hematoma, or intraventricular hemorrhage were excluded.

### RESULTS

This study reports 15 cases of neonatal EDH. There was no sex predominance. The average birth weight was 3400 g (range, 2835–

4310 g), and the average head circumference was 36.5 cm (range, 33.5–39 cm). The 5-minute Apgar score was greater than 8 for 11 patients, 1 patient experienced a cardiac arrest and was resuscitated (Patient 7), and in the score was unknown for 3 patients (Patients 12, 13, 14).

Most of the mothers were primipara and primigravida (11 out of 15), and the age range of the respective parturient was 22 to 34 years with an average age of 28 years. Of the women who delivered vaginally, eight had an instrumental delivery, two had normal delivery, and five had a caesarean delivery after a vaginal attempt failed.

The time (latency) from birth to the first symptoms varied from 0 hours to 4 days, but most often, the latency was less than 24 hours. *Table 1* shows the delivery characteristics and clinical symptoms.

EDH was most frequently located in the parietal area. The presence of fracture is not a rule in newborns either. Of 15 babies, the radiograph showed a cranial fracture in 10 cases, six of which were depressed cranial fractures and four linear. The fracture was on the same side as the EDH in all but one patient, who had a contralateral linear fracture. The parietal bone was the most common fracture site.

Ultrasonography is not reliable in EDH diagnosis, and an electroencephalogram does not show any specificity. Nine patients had a fundoscopic examination that revealed a single or bilateral retinal hemorrhage in all cases. Surgical treatment was conditioned by the hematoma thickness and an eventual associated depressed cranial fracture. Radiology data, treatment and outcome are summarized in *Table 1*.

## DISCUSSION

Birth trauma is still an ever-present cause of death in newborn infants, with the greatest danger being to the head. EDH in newborn infants is a rare condition. The reasons given for this rarity are the specific anatomic cranial conditions (2) and the fact that it may be overlooked; Govaert (15) reported five cases over a 3-year period. Another reason is that newborn infants are less exposed to trauma. From the in utero state to the first month of life, the most frequent cause of trauma is delivery, especially during instrumented delivery from nulliparous women. To our knowledge, until now, most reported cases have followed birth trauma (2, 5) or "uncomplicated vaginal delivery" (23, 25, 38) except one, which was caused by intrauterine trauma (27). In our series, as reported previously (32), one infant who underwent a spontaneous vaginal delivery suffered accidental trauma from being dropped on the labor room floor (Patient 8).

It has been suggested that the rate of intracranial hemorrhage was higher in infants delivered by vacuum, forceps, or caesarean section with labor than in infants delivered spontaneously or by caesarean section without labor (34). Most babies involved in this study and reported in the literature have experienced this condition (2, 38). Male predominance has been suggested because of the fact that boys have a larger head circumference than girls (2); our study does not corrob-

orate this explanation, and in some cases, the head coming through the birth canal was the only explanation for EDH formation (23, 25, 29, 30) (see Patient 4).

## Clinical Examination

The onset of clinical symptoms is variable. In most cases, it appears less than 24 hours after delivery, although it may be later. The time latency depends upon the associated lesions and the thickness of the hematoma. Seizures and hypotonia were the predominant signs in our study, but the neurological examination may be normal (4, 15, 23, 25, 32), particularly in cases of small EDH. Incidentally, two cases of EDH were accompanied by hydrocephalus (*Fig. 1*), and the babies' head circumference was 38.5 cm (Patient 5) and 39 cm (Patient 15), respectively. Hydrocephalus has also been recorded previously in association with Chiari malformation (2, 19). It is not known whether babies with congenital hydrocephalus are more at risk of EDH than normal newborns (2), but neonatal hydrocephalus is now diagnosed before birth, so fetuses with a biparietal diameter of less than 10 cm or a head circumference of less than 36 cm should be allowed a vaginal delivery, whereas caesarean delivery is recommended for fetuses with a greater head circumference (3).

Hematological forms should also be kept in mind. Pallor may be the first sign (11, 13, 22) because EDH may represent 50% of the baby's total blood volume (12, 23), and clotting of the hematoma could induce disseminated intravascular coagulation (22, 23, 25).

Mallet and Boumahni (22) have classified the clinical symptoms observed in EDH into three categories: 1) neurological symptoms, 2) visible signs on the head, 3) no specific symptoms of acute neonatal distress. EDH is usually located in the supratentorial compartment; however, a few cases have been described in the posterior fossa (11, 29, 33) or in both compartments (7). EDH is sometimes associated with other head and intracranial injuries (cephalohematoma, cranial fracture, subdural hematoma, subarachnoid hemorrhage, brain contusion, and intraventricular hemorrhage), and it may develop in a predisposed child, such as Patient 7 (a hemophilic child) in this study and two cases reported in Prader-Willi syndrome (15, 17).

## Radiology Data

A cranial radiograph is not sufficient to rule out intracranial hematoma, yet it may alert the practitioner by revealing a cranial fracture. Therefore, the possibility of an EDH particularly exists when a cranial fracture is detected because the histological examinations of the bones of infants have shown increased diploic vascularization (8), and bleeding will accumulate intra- and extracranially to form both extradural and subperisotal hematoma (19).

EDH can be detected early by CT or MRI scans. The imaging features of an EDH are distinctive and characterized by a hyperdense lentiform collection (*Fig. 2*), but it may also be hypodense or heterogeneous (5). Its CT scan features do not differ from that in other age groups (5), although small EDHs,

**TABLE 1. Modes of delivery, clinical characteristics, radiology data, type of surgery, and outcome of newborns<sup>a</sup>**

Patient no.	Sex	Delivery	Symptoms	CT scan		Treatment	Follow-up	Group no.
				Site	Associated lesions			
1	F	Caesarean	Seizures, anemia, macrocrania, cephalohematoma	R parietal	Intraventricular hemorrhage, brain contusion	Medical	Seizure at 8 yr	2
2	M	Instrumented vaginal delivery	Lethargy	L parietal	Depressed cranial fracture	Craniotomy	Normal at 1 yr	1
3	M	Instrumented vaginal delivery	Hypotonia, respiratory distress, subgaleal hematoma	R parietal	Subarachnoid hemorrhage	Medical	Normal at 6 mo	1
4	F	Vaginal delivery	Seizures	L frontal	Brain contusion	Medical	Normal at 8 mo	1
5	F	Failure Instrumented vaginal delivery/ caesarean	Seizures, subgaleal hematoma, pallor	R frontal	Hydrocephalus	Disk trephine/ ventriculoperitoneal shunting	Hypotonia at 12 mo	2
6	F	Failure vaginal delivery/caesarean	Seizure, cephalohematoma	R frontoparietal	Depressed cranial fracture	Craniotomy	Lost to follow-up	—
7	M	Vaginal delivery and external maneuver	Seizures, pallor, hemophilia	L temporal	Cerebellar hematoma, subdural hematoma	Medical	Aggressiveness at 7 yr	2
8	M	Vaginal delivery	Postdelivery head injury (Fall)	R Temporoparietal	Linear Fracture	Medical	Normal at 16 mo	1
9	M	Instrumented vaginal delivery	Hypotonia, seizures, cephalohematoma	R parietal	Linear fracture, subarachnoid hemorrhage, brain contusion	Failure aspiration/ medical	Lost to follow-up	—
10	F	Instrumented vaginal delivery	Cries, cephalohematoma	L temporal	Depressed cranial fracture, Subarachnoid hemorrhage	Craniotomy	Lost to follow up	—
11	M	Failure instrumented vaginal delivery/ caesarean	Hypotonia	L parietal	Depressed cranial fracture	Craniotomy	Normal at 6 yr	1
12	F	Failure vaginal delivery/caesarean	Hypotonia	R parietal	Depressed cranial fracture	Craniotomy	Normal at 2 yr	1
13	F	Failure Instrumented vaginal delivery/ caesarean	Seizures, hypotonia, cephalohematoma	R parietal	Depressed cranial fracture	Craniotomy	Normal at 10 mo	1
14	M	Instrumented vaginal delivery	Seizures, hypotonia	R temporoparietal	Linear fracture, subarachnoid hemorrhage	Aspiration/medical	Normal at 9 mo	1
15	M	Instrumented vaginal delivery	Hyperexcitability, macrocrania	R parietal	Linear fracture, hydrocephalus	Craniotomy/ ventriculoperitoneal shunting	Seizures, PMD at 5 yr	3

<sup>a</sup> CT, computed tomography; R, right; L, left; PMD, psychomotor delay.

especially those of venous origin, may be indistinguishable from acute subdural hematoma (35). MRI scanning is an excellent tool for imaging intracranial hemorrhage during the neonatal period and for differentiating between epidural and subdural hemorrhages (16).

Ultrasonography is less specific and has only detected one case in six examinations in our study. Lam et al. (19) found

only six cases in 10,000 ultrasound scans. Although it reveals other associated brain diseases, ultrasonography could misdiagnose EDH, as cranial sonogram accuracy in defining primary diseases is 59% (1), and peripheral intracranial lesions can be excluded from the probe's field of view (6, 21).

Our observations reveal encephalography's lack of specificity in this pathology, but it provides information about seizures

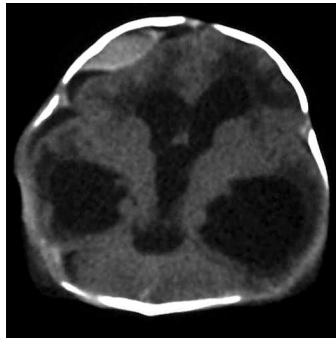
(including those not clinically recognized (9) and background electrical activity of the brain. It may differentiate the role of EDH when associated with other brain diseases and assess the effect of antiepileptic treatment. Fundoscopic examination was always altered in our series, but it is nonspecific because the incidence of retinal hemorrhage observed in newborns without intracranial disease is found in 30 to 50% of the cases (10).

#### Indication to Treatment

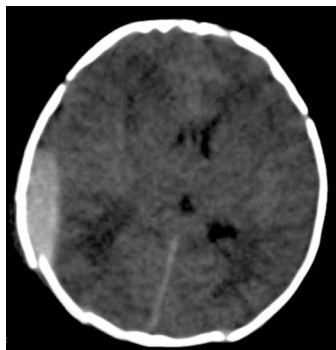
This series of 15 babies shows how heterogeneous the presentation of EDH can be in newborn infants, and it emphasizes the difficulty in determining EDH involvement in the clinical profile, particularly when EDH is associated with other brain diseases because the neurological development of the newborn is incomplete. Although Pozzati and Tognetti (30) suggested that the absence of focal neurological deficits is a criterion for conservative treatment, and successful nonsurgical management of EDH in children was reported by several authors (15, 18, 25, 28, 29), others maintained that raised intracranial pressure may be compensated for by an increase in head circumference because of unfused sutures, and therefore an absence of neurological signs might not mean the case is suitable for conservative management (2, 23). Consequently, in our series, the main indications for surgical treatment of newborn infants with EDH were based on the thickness of the hematoma, the shifting of the brain, and an eventual associated depressed cranial fracture or hydrocephalus.

A conservative approach was chosen in patients with a small, isolated hematoma (less than 1 cm thick and less than 4 cm long in the anteroposterior plan) with no clinical deterioration. In this case, very close observation in an intensive care unit is mandatory, and a repeat CT or MRI scan is advised within 24 hours, even if no clinical deterioration occurs.

When the hematoma is larger than the above-mentioned dimensions or associated with a depressed cranial fracture,



**FIGURE 1.** CT scan showing a hydrocephalus and a right frontal EDH compressing the frontal lobe in a 1-day-old baby (Patient 5). The hematoma was aspirated through a disk trephine with dura attachment to the pericranium followed by a right frontal ventriculoperitoneal shunt.



**FIGURE 2.** CT scan of a 4-day-old baby (Patient 14) showing a right parietal EDH and a linear cranial fracture of the parietal bone. The hematoma was aspirated through the cranial fracture.

surgery is performed because it is well known that most brain damage caused by EDH is caused by mechanical pressure. In addition, significant hydrocephalus requiring early shunting may influence the need to surgically treat an EDH; however, in the case of small EDH with minimal ventricular dilatation, one could wait for the EDH to resolve before treating the hydrocephalus, if needed.

#### Treatment Modalities

We agree that many EDHs require medical rather than surgical attention; it has been well documented that some neonatal EDHs may resolve spontaneously (15, 25, 29). A neonatal EDH may liquefy earlier than in other age groups (4, 15), and, in most cases where the content of the hematoma was described, it contained liquid blood (2, 5, 15, 22, 38). Unlike EDH occurring in other age groups, there is no rule regarding the surgical technique for treating newborn infants with EDH, and many procedures have been successfully described (4, 5, 11, 15, 23, 36), so less invasive therapies should be attempted before resorting to a craniotomy.

Consequently, when EDH is associated with cephalohematoma (subperiosteal hematoma), a single aspiration of the latter should be attempted because this method has resulted in the disappearance of EDH with no recurrence (4, 15, 25, 38). The common features of this combination were a communication between the cephalohematoma and the EDH through the cranial fracture and a fluid aspect of the hematoma. However, this technique could fail when there is no communication between the two entities or when the hematoma is clotted (23, 26).

Thus, failure of the first cited technique may lead to consideration of other treatment modalities such as aspiration through the cranial fracture (as in Patient 14), percutaneous epidural tapping (regardless of the cranial sutures) using a subdural tapping needle for those EDH without cranial fracture or cephalohematoma (5), an ultrasound-guided needle aspiration (36), or EDH evacuation through a burr hole (15). However, these therapeutic modalities may fail because of a clotting hematoma (23, 26), as occurred in Patient 9, and therefore, surgical evacuation through a trephine disk (23 and Patient 5 in our study) or craniotomy (11, 14, 22) is mandatory according to the hematoma volume.

#### Outcome

Prognosis and outcome are generally good. Most of our patients were in the first group; a poor outcome was caused, in part, by associated lesions, and the most frequent disability in our series was seizures. Except for the cases where EDH was discovered at postmortem examination (33, 37), the survival rate seems good, with only two deaths reported (38). However, in our series, the follow-up CT or MRI scan disclosed a porencephalic cavity in three babies, mostly in cases associated with brain contusion. It is well known that damage sustained in pregnancy or during the perinatal period may not be revealed until much later in childhood or even in adult life (31), and therefore, further studies are required to define these risks.

## CONCLUSION

Because newborns rarely sustain injury in the first month after birth and most trauma occurs during delivery, EDH in newborn infants is a rare condition that may be detected even less frequently when asymptomatic. Surgical treatment is not a rule; most EDHs can be managed with a repeat CT scanning and careful clinical evaluation.

## REFERENCES

- Adcock LM, Moore JP, Schlesinger AE, Armstrong DL: Correlation of ultrasound with post mortem neuropathologic studies in neonates. *Pediatr Neurol* 19:263–271, 1998.
- Akiyama Y, Moritake K, Maruyama N, Takamura M, Yamasaki T: Acute epidural hematoma related to cesarean section in a neonate with Chiari II malformation. *Childs Nerv Syst* 17:290–293, 2001.
- Anteby EY, Yagel S: Route of delivery of fetuses with structural anomalies. *Europ J Obstet Gynecol* 106:5–9, 2003.
- Aoki N: Epidural hematoma communicating with cephalhematoma in a neonate. *Neurosurgery* 13:55–57, 1983.
- Aoki N: Epidural haematoma in newborn infants: Therapeutic consequences from the correlation between haematoma content and computed tomography features. A review. *Acta Neurochir (Wien)* 106:65–67, 1990.
- Babcock DS, Han BK, Weiss RG, Ryckman FC: Brain abnormalities in infants on extracorporeal membrane oxygenation: sonographic and CT findings. *AJR* 153:571–576, 1989.
- Campbell JB, Cohen J: Epidural hemorrhage and skulls of children. *Surg Gynecol Obstet* 92:257–280, 1951.
- Choux M, Grisoli F, Peragut JC: Extradural hematomas in children. 104 cases. *Childs Brain* 1:337–347, 1975.
- Clancy RR, Legido A, Lewis D: Occult neonatal seizures. *Epilepsia* 29:256–261, 1988.
- Emerson MV, Pieramici DJ, Stoessel KM, Berreen JP, Gariano RF: Incidence and rate of disappearance of retinal hemorrhage in newborns. *Ophthalmology* 108:36–39, 2001.
- Esparza J, Portillo JM, Mateos F, Lamas E: Extradural hemorrhage in the posterior fossa in neonates. *Surg Neurol* 17:341–343, 1982.
- Gaab M, Gruss P, Jeschke R: Special features of epidural hematoma in neonates and infants (author's translation). *Klin Padiatr* 187:281–284, 1975 (abstr).
- Gama CH, Fenichel GM: Epidural hematoma of the newborn due to birth trauma. *Pediatr Neurol* 1:52–53, 1985.
- Gouyon JB, Cinquin AM, Sautreaux JL, Thierry A, Giroud M, Alison M: L'hematome extradural du nouveau né. Complication rare d'un accouchement par forceps. *Arch Fr Pediatr* 42:333, 1985 (letter).
- Govaert P: Epidural haematoma (cephalhematoma internum, internal subperiosteal bleeding), in Govaert P (ed): *Cranial Haemorrhage in the Term Newborn Infant. Clinics in Developmental Medicine*. Cambridge, Mac Keith Press, distributed by Cambridge University Press, 1994, pp 34–40.
- Keeney SE, Adcock EW, McArdle CB: Prospective observations of 100 high-risk neonates by high-field (1.5 Tesla) magnetic resonance imaging of the central nervous system: I—Intra ventricular and extra cerebral lesions. *Pediatrics* 87:421–430, 1991.
- Klinge L, Scott RC, de Sousa C: Neonatal subdural and extradural haemorrhage in Prader-Willi syndrome. *Neuropediatrics* 32:221–222, 2001.
- Lahat E, Livne M, Barr J, Schiffer J, Eshel G: The management of epidural haematomas: Surgical versus conservative treatment. *Eur J Pediatr* 153:198–201, 1994.
- Lam A, Cruz GB, Johnson I: Extradural hematoma in neonates. *J Ultrasound Med* 10:205–209, 1991.
- Leblanc A, Bamberger J, Busy F, Leseney A: Extradural hematoma in a newborn infant [in French]. *Arch Fr Pediatr* 43:68, 1986 (letter).
- Leboucq N, Hercot O, Baud C, Veyrac C, Couture A, Tronc F: Ultrasonics in extradural hematoma in newborn infants [in French]. *Pediatric* 42:17–20, 1987.
- Mallet EC, Boumahni B: Neonatal extradural hematoma [in French]. *Arch Pediatr* 3:608–609, 1996 (letter).
- Merry GS, Stuart G: Extradural hematoma in the neonate. *J Neurosurg* 51:713–714, 1979.
- Natelson SE, Sayers MP: The fate of children sustaining severe head trauma during birth. *Pediatrics* 51:169–174, 1973.
- Negishi H, Lee Y, Itoh K, Suzuki J, Nishino M, Takada S, Yamasaki S: Nonsurgical management of epidural hematoma in neonates. *Pediatr Neurol* 5:253–256, 1989.
- Okuno T, Miyamoto M, Itakura T, Ueno M, Shimizu M, Minamide A, Komai N: A case of epidural hematoma caused by a vacuum extraction without any skull fractures and accompanied by cephalohematoma [in Japanese]. *No Shinkei Geka* 21:1137–1141, 1993 (abstr).
- Palmer JD, Sparrow OC: Extradural haematoma following intra uterine trauma. *Injury* 25:671–673, 1994.
- Pang DHJ, Hertton JM, Wilberger: Non surgical management of extradural hematomas in children. *J Neurosurg* 59:958–971, 1983.
- Piyaraly S, Edmar A, Raudrant-Sigogne N, Boumahni B, Mallet EC, Bintner M: Extradural hematoma in the posterior fossa without fracture in a neonate [in French]. *Arch Pediatr* 5:204–205, 1998 (letter).
- Pozzatti E, Tognetti E: Spontaneous healing of acute extradural hematomas: Study of twenty-two cases. *Neurosurgery* 18:696–700, 1986.
- Stewart AL: Measures of outcome in the newborn. *Br J Obstet Gynaecol* 100:711–713, 1993.
- Tada M, Echizenya K, Satoh M: Communication between epidural hematoma and cephalhematoma in a neonate. *Hokkaido Igaku Zasshi* 61:244–248, 1986.
- Takagi T, Nagai R, Wakabayashi S, Mizawa I, Hayashi K: Extradural hemorrhage in the newborn as a result of birth trauma. *Childs Brain* 4:306–318, 1978.
- Towner D, Castro MA, Eby-Wilkens E, Gilbert WM: Effect of mode of delivery in nulliparous women on neonatal intracranial injury. *NEMJ* 341:1709–1714, 1999.
- Tsai FY, Zee C-S, Apthorp, JS, Dixon JH: Computed tomography in child abuse head injury. *J Comput Tomogr* 4:277–286, 1980.
- Vachharajani A, Mathur A: Ultrasound-guided needle aspiration of cranial epidural hematoma in a neonate: Treating a rare complication of vacuum extraction. *Am J Perinatol* 19:401–404, 2002.
- Valdes-Dapena MA, Arey JB: The causes of neonatal mortality: An analysis of 501 autopsies on newborn infants. *J Pediatr* 77:366–375, 1970.
- Yamamoto T, Enomoto T, Nose T: Epidural hematoma associated with cephalohematoma in a neonate—case report. *Neurol Med Chir (Tokyo)* 35:749–752, 1995.

## Acknowledgments

We thank Aschkars El-Ouahid for his help and advice and Ms. Tracey Wescott for correcting the English in our manuscript.

## COMMENTS

In this retrospective review, Heyman et al. report 15 cases of intracranial epidural hematoma secondary to birth trauma in newborn infants. This work represents the largest existing series on this topic and points out a number of unique features of epidural hematoma in this population. The mothers were generally young, primigravidas, and most deliveries occurred at or around term. Most infants had some type of difficulty during delivery. Only two of the nine vaginal deliveries were uncomplicated; the majority were instrumented deliveries. Of the six patients delivered by Caesarean section, only one was without labor; all of the other Caesarean sections followed failed vaginal delivery, most of which had been instrumented. The majority of epidural hematomas owing to birth trauma are located in the parietal region and interestingly, one-third of them occurred without an associated cranial fracture. Thus, routine cranial films would not be an effective screening mechanism and even cranial ultrasonography is

not useful, as it successfully identified an epidural hematoma in only one of six cases in the present series. Computed tomography seems to be the diagnostic procedure of choice.

This series makes the point that the prognosis for epidural hematoma related to birth trauma is generally good. The presence of an epidural hematoma in a newborn infant does not necessarily mandate surgery and, in fact, only half the infants in this series underwent craniotomy. If the hematoma is small and the patient is in good clinical shape, observation with repeat neuroimaging studies seems to be an effective strategy.

**Alan R. Cohen**  
Cleveland, Ohio

The authors of this manuscript present their series of 15 newborns with epidural hematomas (EDH). As would be anticipated, all but two neonates had a difficult delivery with one of these two developing an EDH after being dropped on the floor after a normal vaginal delivery. Cranial fractures, most in the parietal region as expected, were present in 10 of the 15 newborns, with six being depressed. The clinical presentation often develops within the first day of life and was frequently nonspecific with hypotension and seizures being the most common. Pallor, hypotension, and disseminated intravascular coagulopathy can develop if the clot is of sufficient size. A coagulation disorder was present in one newborn in the series. A craniotomy was undertaken in eight, percutaneous aspiration in one, and observation was conducted in the remaining six patients. Developmental outcome was good unless additional injuries or hydrocephalus were present.

Although I have not reviewed our series, I would anticipate that it would be similar to the authors'. A relatively small EDH most often needs no invasive manipulation. We have been able to percutaneously aspirate a cephalohematoma/EDH/subdural hematoma on occasion after checking the coagulation status. In the face of a large and expanding EDH, a craniotomy is definitely warranted.

**J. Gordon McComb**  
Los Angeles, California

This article describes the clinical features of 15 newborns with EDH collected over a 24-year period. A number of the children had evidence of other intracranial pathology, such as subdural hemorrhages or hydrocephalus. Their injuries were most often the product of a first pregnancy, presented clinically within 24 hours, and approximately half did not require any surgical treatment. The outcome was generally good, with seizures being the most common sequelae. If operation is undertaken, the extradurals can often be removed via a minimal opening. Needless to say these can be very ill neonates who require intensive resuscitation and careful monitoring. If taken to surgery, careful attention to blood loss and replacement is extremely important.

**James M. Drake**  
Toronto, Ontario, Canada

The authors have compiled a careful retrospective analysis of newborns with EDH. The fact that there are only 15 patients over a 24-year period supports the observation that this is a rare occurrence. However, I suspect, that this is a very underreported event. I have seen several neonates with EDH over the past 5 years, but have assumed, like many surgeons, that EDH was a well documented form of birth trauma, which it is not. Furthermore, neonatologists in some institutions are reluctant to order computed tomographic scans on newborns unless they demonstrate clear-cut signs of increased intracranial pressure, such as a bulging fontanel. Ultrasonography is apparently far less specific. In my experience, some of these children with EDH require no surgery simply because they decompress their EDH through the fracture line. Other nonsurgical EDH are most likely a result of venous bone blood oozing from the fracture line and are thus low pressure. Regardless, this uncommon form of birth injury is meticulously described in this "large" series of newborns. The treatment options in newborns are individual and vary based on the clinical status of the newborn, presence of hydrocephalus or a depressed fracture, and the size of the EDH. The authors have nicely demonstrated that newborns represent one of the rare groups of patients in whom conservative therapy for EDH may occasionally be appropriate.

**Richard G. Ellenbogen**  
Seattle, Washington

### Future Meetings—Congress of Neurological Surgeons

The following are the planned sites and dates for future annual meetings of the Congress of Neurological Surgeons:

2006	Chicago, IL	October 7–12
2007	San Diego, CA	September 15–20
2008	Orlando, FL	September 20–25

### Future Meetings—American Association of Neurological Surgeons

The following are the planned sites and dates for future annual meetings of the American Association of Neurological Surgeons:

2006	San Francisco, CA	April 22–27
2007	Washington, DC	April 14–19
2008	Chicago, IL	March 29–April 3
2009	San Diego, CA	May 2–7