

CASE STUDY

Deep vein thrombosis and pulmonary embolism in an ambulatory chronic stroke patient

SAM-GYU LEE¹, JAE-HYUNG KIM², IN-SUNG CHOI¹, & JAE-GYU KIM²

¹Department of Physical Medicine and Rehabilitation, and ²Department of Radiology, Research Institute of Medical Sciences, Chonnam National University Medical School & Hospital, Gwangju City, Republic of Korea

Accepted January 2005

Abstract

Purpose: Deep vein thrombosis (DVT) is a well-known complication of stroke and frequently develops in acute stroke patients. Immobility in stroke patients increases the risk of DVT and pulmonary embolism (PE). The incidence of DVT in non-ambulatory stroke patients is more frequent than the incidence in ambulatory stroke patients. We report a case of DVT and PE in an ambulatory chronic stroke patient.

Method: Initial physical examination showed heat and swelling of hemiplegic leg. The patient was only able to ambulate with the assist of a monocane and a plastic leaf spring orthosis due to ankle dorsiflexor weakness. The patient was treated with anticoagulation and inferior vena cava filter placement.

Results: After long-term anticoagulation, follow-up studies revealed satisfactory resolution of DVT and PE.

Conclusions: We present a case of DVT and PE which developed during the chronic stage of stroke, 2 years from the onset of stroke, and review the cause of DVT.

Keywords: Venous thrombosis, pulmonary embolism, stroke, muscle weakness

Introduction

Deep vein thrombosis (DVT) is a well-known complication of immobility associated with stroke, spinal cord injury, trauma, orthopedic procedures and medical illnesses. The incidence of DVT is 22–75% in patients who have had strokes [1]. Pulmonary embolism (PE), the most dangerous complication of DVT, occurs in 16–37% of patients who suffer from an acute stroke [2]. DVT is also present in a significant proportion of patients during the subacute phase of stroke, the risk being greater in those who are more immobile. In a study of 150 patients admitted to a stroke rehabilitation unit at, on average, 9 weeks after stroke, bilateral venography revealed DVT in 33% [3]. However, there is little information available regarding the chronic stage of stroke and DVT.

In stroke patients, DVT is 10 times more common in the involved extremities than in the uninvolved

extremities [4]. In non-ambulatory stroke patients, DVT is five times more frequent than in patients who can walk more than 50 feet [5]. Venous stasis in the affected leg and hemostasis abnormalities, which occur frequently in the setting of acute stroke, probably contribute to the pathogenesis of DVT [6]. We present a case of DVT and PE in an ambulatory chronic stroke patient and review the cause of DVT in stroke cited in the literature.

Case report

A 52-year-old man was admitted to the hospital with a 4-day history of hemiplegic leg swelling. He underwent various rehabilitative treatments due to incomplete right hemiplegia and global aphasia in association with cerebral infarction in the left middle cerebral arterial region for the previous 2 years. He had already been taking triflusal (300 mg/day) as a

Correspondence: In-Sung Choi, M.D., Ph.D., Department of Physical Medicine & Rehabilitation, Research Institute of Medical Sciences, Chonnam National University Medical School & Hospital, # 8, Hak-dong, Dong-gu, Gwangju City, 501-757 Republic of Korea. Tel: 82 62 220 5186. Fax: 82 62 228 5975. E-mail: drchoiis@hotmail.com

secondary prevention of stroke and thigh-high compressive stockings were used for the prevention of venous thrombosis. At the time of admission, the patient showed heat and swelling on the right calf, but no pain or tenderness on the hemiplegic swollen leg. He was able to ambulate using a monocane and a plastic leaf spring orthosis (PLSO). The strength of the hemiplegic hip and knee extensors was fair and that of the ankle dorsiflexors and plantarflexors was trace on manual muscle testing. Spasticity of the lower limb was a grade 1 on the modified Ashworth scale.

We performed several diagnostic workups to find the cause of heat and swelling. D-dimer testing was carried out at admission. D-dimer level of the patient was 0.6 mg/l (normal range 0–0.3 mg/l). Chest radiograph was unremarkable. Tc-99m MAA venograph showed radionuclide retention in the right tibial vein and collateral flow in the left greater saphenous vein (Figure 1). Ventilation/perfusion scan revealed a V/Q mismatched perfusion defect on the posterior segment of the right upper lobe and the superior segment of the right lower lobe, indicating a high probability of pulmonary thromboembolism (Figure 2). We performed computed tomographic angiography of the lower extremity and detected DVT from the right iliac vein to the tibial vein (Figure 3). On chest computed tomographic angiogram, we found thromboembolism in the left interlobar pulmonary artery (Figure 4).

The patient was treated with absolute bed rest and compression stockings and anticoagulated with

intravenous heparin and then transitioned to warfarin. Two weeks later, the hemiplegic leg swelling subsided, however, follow-up lung perfusion scan demonstrated newly developed segmental perfusion defects. A titanium Greenfield inferior vena cava filter was placed at the origin of the common iliac vein. Intravenous heparin and warfarin were restarted after the placement of the inferior vena cava filter. The patient was dis-

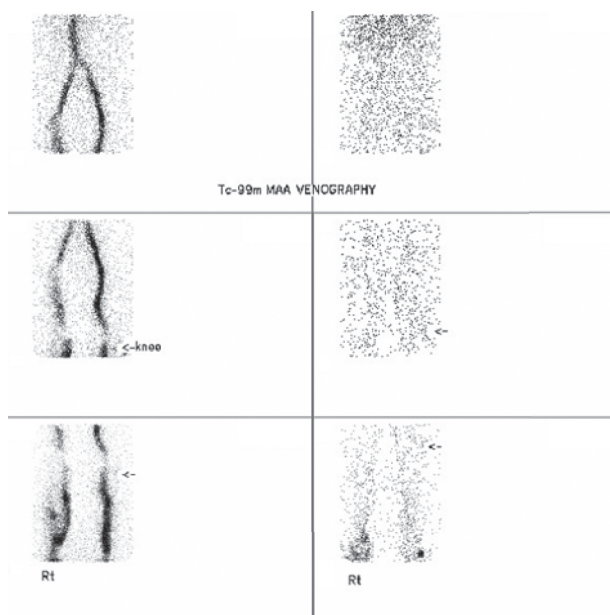


Figure 1. Tc-99m MAA venograph shows the radionuclide retention in the right tibial vein and collateral flow in the left greater saphenous vein.

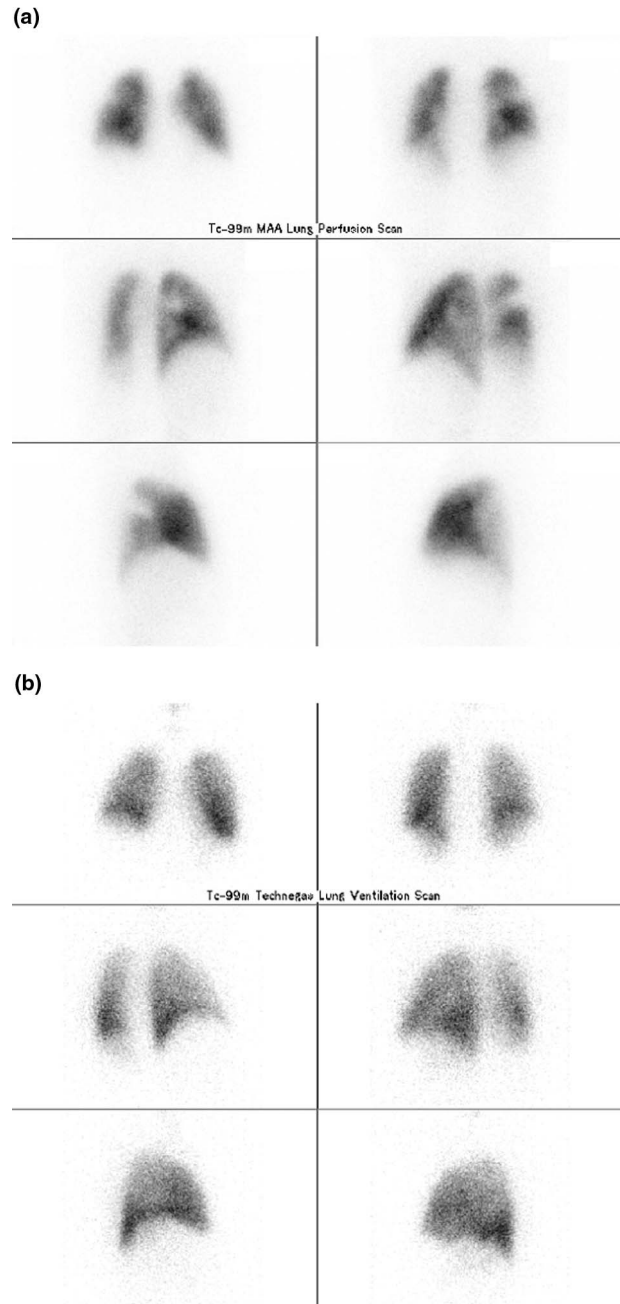


Figure 2. Lung perfusion scan (a) shows perfusion defect on posterior segment of the right upper lobe and the superior segment of right lower lobe. Lung ventilation scan (b) shows no ventilation defect on perfusion defected segment indicating V/Q mismatch.

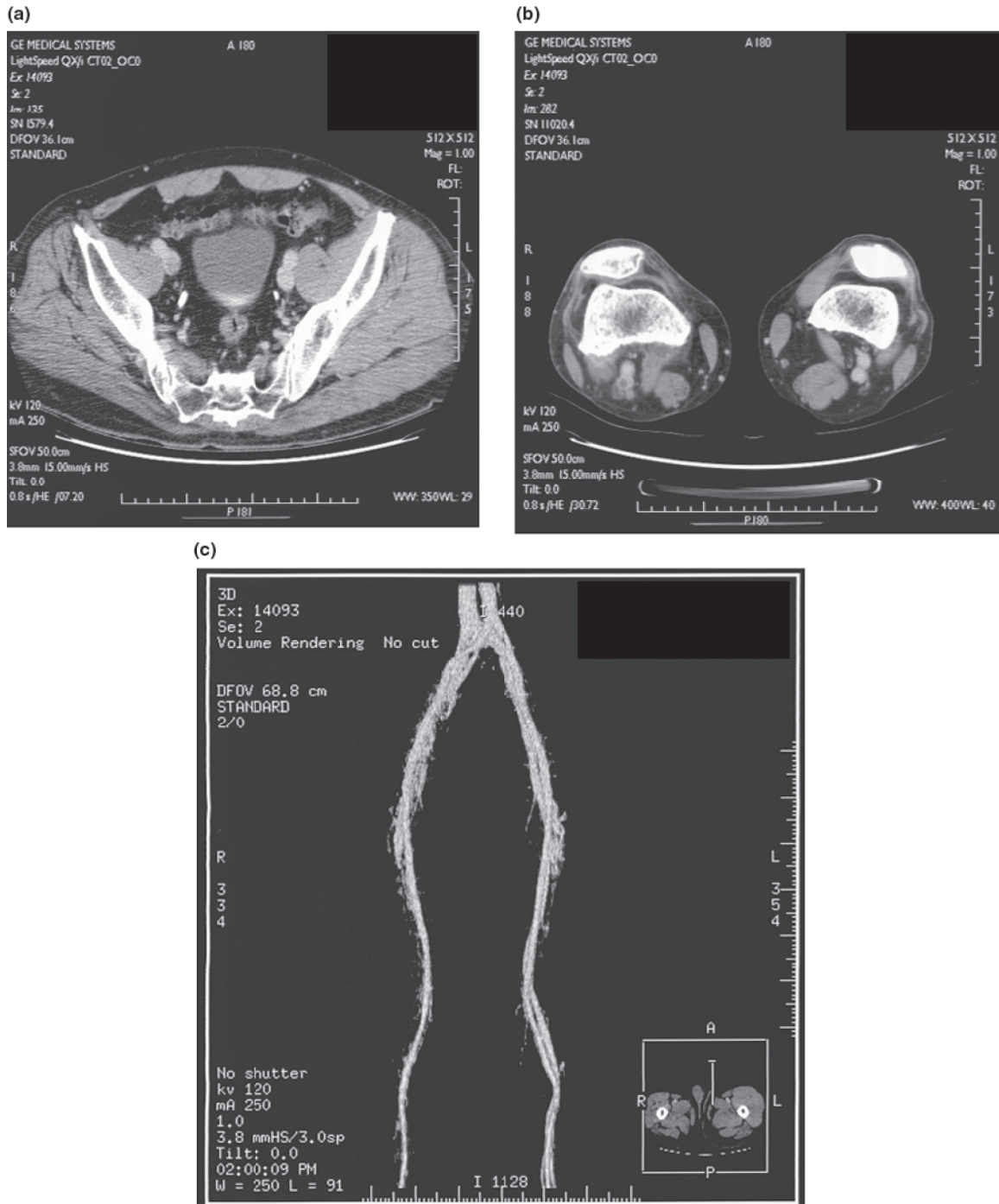


Figure 3. Lower extremity computed tomographic angiogram shows the deep vein thrombosis extending from the right iliac vein (a, c) to this tibial vein (b, c).

charged on oral warfarin. After oral anticoagulation for 6 months, follow-up imaging studies were performed. Lower extremity computed tomographic angiograph (Figure 5) and Tc-99m MAA venograph (Figure 6) demonstrated no evidence of venous obstruction in either lower extremity. And also, lung perfusion scan (Figure 7) demonstrated no perfusion defect in either lung.

Discussion

Acute stroke patients are at high risk for DVT. DVT develops as early as the second day, with peak incidence between days 2 and 7 [7], although some new DVT events are recorded several weeks after onset in the subacute rehabilitation phase [3]. In this patient, DVT developed during the chronic stage of

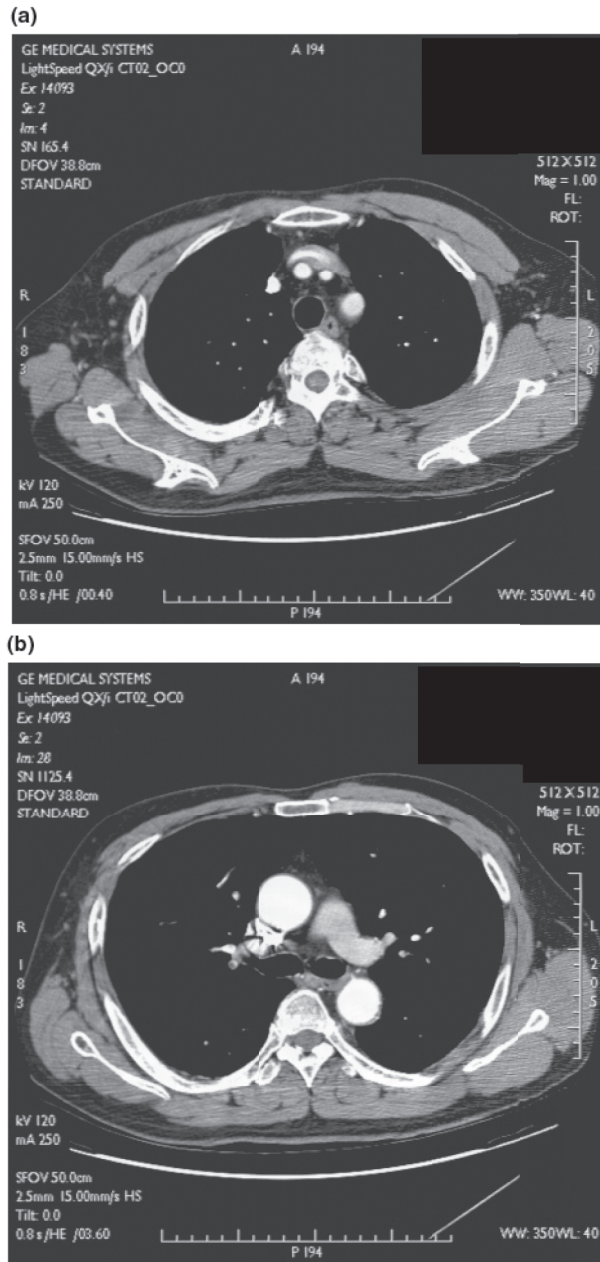


Figure 4. Chest computed tomographic angiogram shows the thromboembolism in the left interlobar pulmonary artery (a, b).

stroke, 2 years from the onset of stroke. However, there was little information available regarding the chronic stage of stroke and DVT.

Approximately two-thirds of DVT with stroke are below-knee DVT, in contrast to non-stroke patients presenting with symptomatic DVT, in whom the majority are proximal [8,9]. In our patient, DVT was detected from the right common iliac vein through the right popliteal vein.

Kelly *et al.* [10,11] suggested that research on DVT might be directed towards evaluating a strategy of screening for subclinical DVT, and investigated an hypothesis that plasma D-dimer might be a useful

discriminator of post-stroke DVT status, potentially allowing identification of a patient subgroup with a high risk of proximal DVT who should be selectively imaged. In our patient, D-dimer level increased at admission, and that caused us to perform further imaging studies, but unfortunately follow-up D-dimer level was not checked. According to Akman *et al.* [12] the sensitivity and negative predictive value of the D-dimer test were high, but the specificity and positive predictive value were low. This means that the testing of D-dimer levels is a reliable method for excluding but not diagnosing DVT. Therefore, D-dimer assay can be used as a routine screening test or to assess the cases of suspected DVT in stroke patients.

At the time of admission, our patient had been taking triflusal for about 2 years as a secondary prevention of stroke and he was able to walk around with the assistance of a monocane and PLSO and routinely used thigh-high elastic stockings. It has not been investigated whether the risk of DVT is lower in chronic patients under aspirin or warfarin, because the majority of the studies on DVT prophylaxis after stroke were performed in acute stroke patients. Although it seems reasonable to assume that aspirin reduces the risk of DVT and PE after stroke, this has not yet been clearly demonstrated [10,11]. The American College of Chest Physicians (ACCP) recommends the use of low-dose unfractionated heparin or low-molecular weight heparin (LMWH) to prevent DVT and PE among the patients with acute ischemic stroke in the first 10–14 days after the event [13]. They also stated that the continued use of prophylaxis would depend on the presence of ongoing risk factors such as paresis, bed rest, atrial fibrillation, and congestive heart failure. However, there is a lack of quantitative data that support the continued use of heparin prophylaxis for DVT prevention beyond 2 weeks after stroke. Pambianco *et al.* [1] found no difference in DVT incidence among patients who received the adjusted dose heparin, patients who used intermittent pneumatic compression, and control patients. However, Harvey *et al.* [14] showed the efficacy of therapeutic anticoagulation and heparin prophylaxis for the prevention of venous thromboembolism (VTE) during stroke rehabilitation, whereas the antiplatelet agents alone provide at best a modest reduction in VTE risk. Oral anticoagulants are the standard intervention for the long-term prevention of DVT, and they are effective in patients surviving stroke [14,15]. Anticoagulants can also be used for the reduction of the risk for DVT in many patients with recent stroke. There is insufficient evidence from randomized trials to support the routine use of physical methods, such as compression stockings and intermittent pneumatic compression devices, for

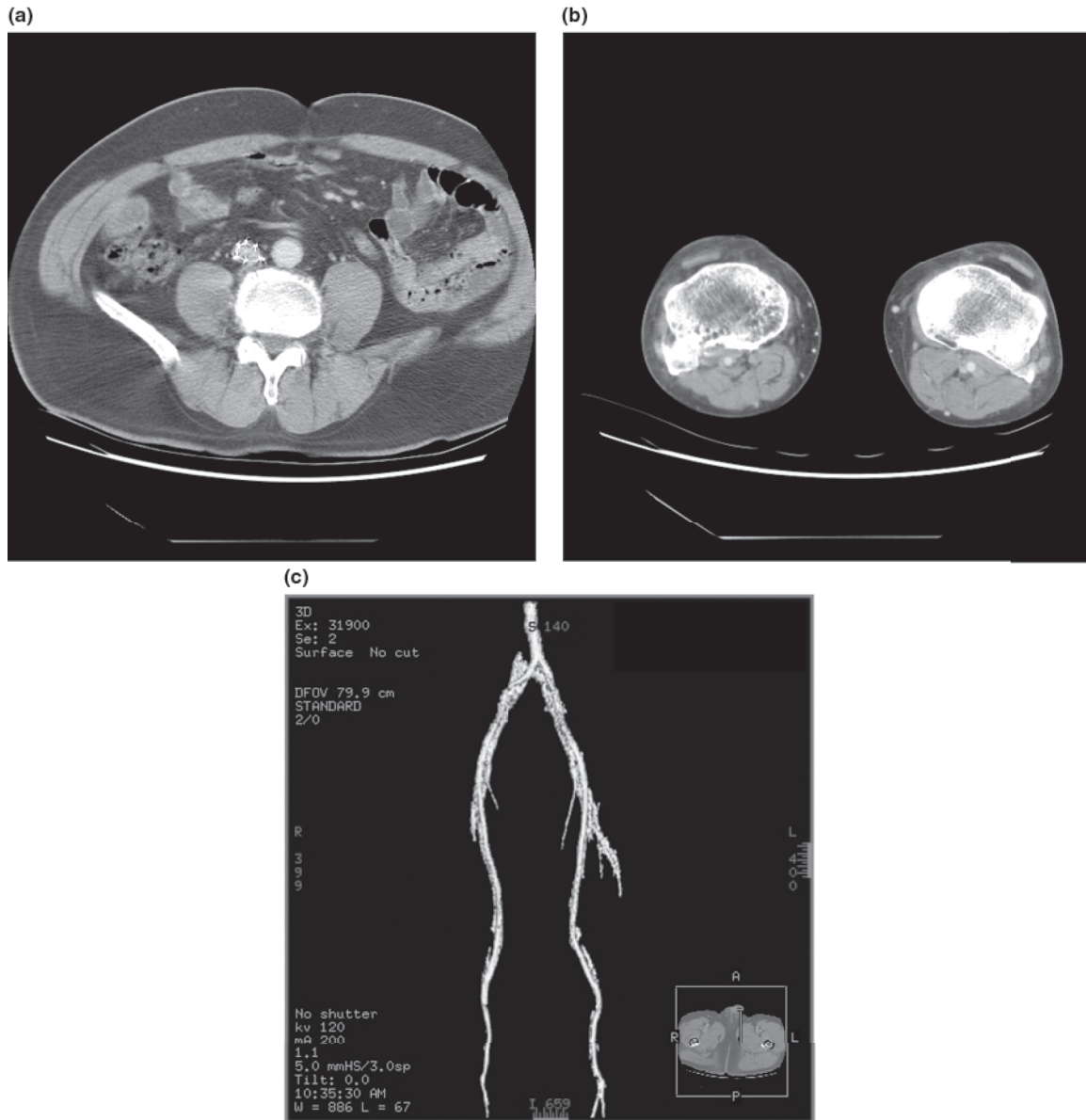


Figure 5. Follow-up lower extremity computed tomographic angiogram shows the evidence of inferior vena cava filter placement (a) and normal venous system in both lower extremities (b, c).

preventing DVT in acute stroke [16]. As far as we know, there is no report on the effect of DVT prophylaxis in chronic completed stroke patients, therefore further studies will be needed on this issue.

Stroke patients have a high risk for DVT in the paralyzed lower extremity. When taken into account in combination with all the other potential factors, immobility, i.e. being bedridden or wheel chair-bound, is the most predictive factor for the development of VTE. Diminished incidence of DVT after mobilization suggests a diminishing prevalence of thrombus formation with the passage of time after the acute stroke, possibly due to systemic factors or improved mobilization of the paretic limbs. So, early ambulation and intensive rehabilitation programs

have an important role in diminishing DVT after stroke.

There is some controversy on the correlation between the degree of weakness in the lower extremity and the development of DVT. Izzo *et al.* [17] reported that the high risk factors for DVT in hemiplegic patients were one or more weeks of complete bed rest, poor or absent muscle power in the ankle dorsiflexors and plantar flexors, lack of sensation, and repeated minor trauma. Gibberd *et al.* [18] stated that the muscle power in the weaker leg was unrelated to the tendency to develop DVT in their patients, but their small number of cases may account for this finding. On the other hand, in a more recent report [8], only patients with severe

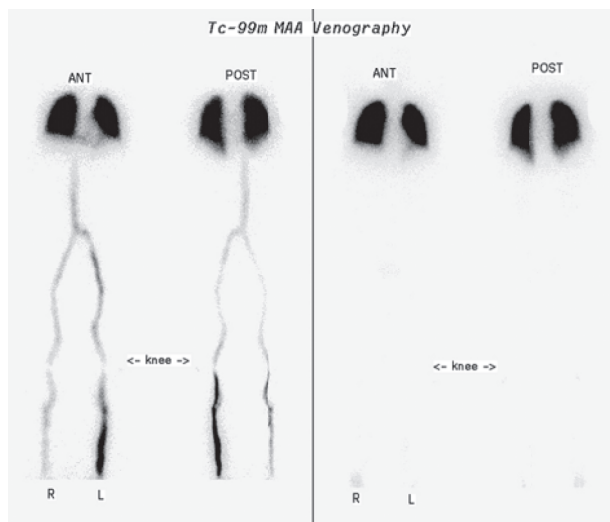


Figure 6. Follow-up Tc-99m MAA venograph after oral anti-coagulation for 6 months demonstrates no evidence of venous obstruction in either lower extremity.

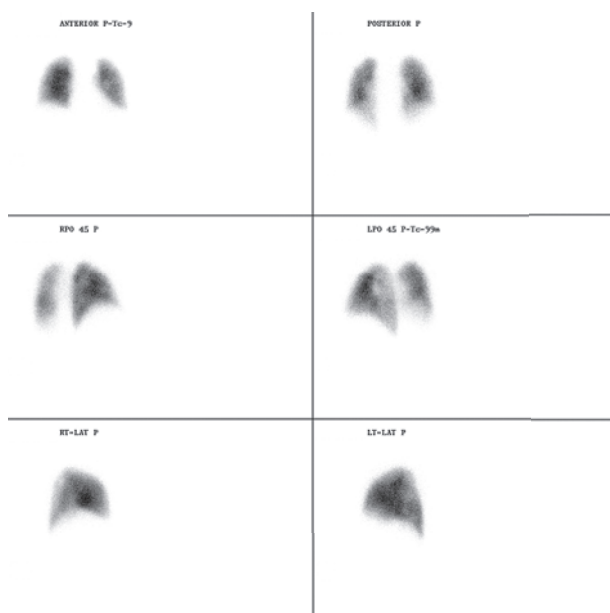


Figure 7. Follow-up lung perfusion scan demonstrates no perfusion defect in either lung.

paralysis developed DVT. Landi *et al.* [19] demonstrated a significant correlation between the growing severity of lower limb paresis and the incidence of DVT, with 95% of DVT developing in patients with severe or complete leg weakness. The important role of leg weakness is strengthened by many findings that DVT occurring after acute stroke is almost always confined to the affected leg. Two factors may contribute to this association, namely, the decrease of venous flow velocity due to the reduction of normal blood pumping action in the severely paretic calf muscles and the damage to the vessel wall following prolonged external pressure on an

immobilized limb. Besides venous stasis and vessel wall abnormalities, changes in blood constituents represent the third element of Virchow's classic triad predisposing to thrombosis.

Paralysis of the muscles can cause local circulatory disturbance. An active muscle produces vasodilator substances, and probably reduced flow of blood through the paralyzed limbs is due to increased arteriolar tone. However, these factors would not explain the tendency of DVT to occur within 1 week of the onset of the paralysis rather than throughout the period of paralysis. In our chronic ambulatory stroke patient the edema was not associated with a DVT shown on the imaging study but with the paralyzed leg, and therefore the edema is unlikely to be solely due to a DVT. This would imply a cause associated with the lack of muscular activity such as poor ankle dorsiflexors and plantar flexors rather than a venous stasis.

Conclusively, we think that the hemiparetic limb swelling is probably suggestive of the occurrence of DVT and PTE even in an ambulatory chronic stroke patient. Therefore, we want to emphasize the importance of muscular activity such as ankle dorsiflexors and plantar flexors of the hemiparetic limb in an ambulatory stroke patient as a cause of DVT.

Acknowledgements

This study was financially supported by Regional Research Centers Program from the Ministry of Education and Human Resources Development.

References

1. Pambianco G, Orchard T, Landau P. Deep vein thrombosis: Prevention in stroke patients during rehabilitation. *Archives of Physical Medicine and Rehabilitation* 1995;76:324–330.
2. Warlow C, Ogston D, Douglas AS. Deep venous thrombosis of the legs after strokes. Part II: Natural history. *British Medical Journal* 1976;1:1181–1183.
3. Bromfield EB, Reding MJ. Relative risk of deep venous thrombosis or pulmonary embolism post-stroke based on ambulatory status. *Journal of Neurologic Rehabilitation* 1988;2:51–57.
4. Walow C, Ogston D, Douglas AS. Deep vein thrombosis of the leg after stroke: Part I. Incidence and predisposing factors. *British Medical Journal* 1976;1:1178–1181.
5. Miyamoto AT, Miller LS. Pulmonary embolism in stroke: Prevention by early heparinization of venous thrombosis detected by iodine-125 fibrinogen leg scans. *Archives of Physical Medicine and Rehabilitation* 1980;61:584–587.
6. Landi G, D'Angelo A, Boccardi E, Mannucci PM, Orazio EN, Morasito A. Hypercoagulability in acute stroke: Prognostic significance. *Neurology* 1987;37:1667–1671.
7. Brandstater ME, Roth EJ, Siebens HC. Venous thromboembolism in stroke: Literature review and implications for clinical practice. *Archives of Physical Medicine and Rehabilitation* 1992;73:S379–391.

8. Turpie AG, Levine MN, Hirsh J, Carter CJ, Jay RM, Powers PJ, Andrew M, Magnani HN, Hull RD, Gent M. Double-blind randomized trial of ORG 10172 low-molecular-weight heparinoid in prevention of deep-vein thrombosis in thrombotic stroke. *Lancet* 1987;523-526.
9. Prandoni P, Lensing AW, Cogo A, Cuppini S, Villalta S, Carta M, Cattelan AM, Polistena P, Bernardi E, Prins MH. The long-term clinical course of acute deep vein thrombosis. *Annals of Internal Medicine* 1996;125:1-7.
10. Sandercock P, Dennis M. Venous thromboembolism after acute stroke. *Stroke* 2001;32:1443-1448
11. Kelly J, Rudd A, Lewis R, Hunt BJ. Venous thromboembolism after acute stroke. *Stroke* 2001;32:262-267.
12. Akman MN, Cetin N, Bayramoglu M, Isiklar I, Kilinc S. Value of the D-dimer test in diagnosing deep vein thrombosis in rehabilitation inpatients. *Archives of Physical Medicine and Rehabilitation* 2004;85:1091-1094.
13. Geerts WH, Heit JA, Clagett GP, Pineo GF, Colwell CW, Anderson FA Jr, Wheeler HB. Prevention of venous thromboembolism. *Chest* 2001;119:S132-175.
14. Harvey RL, Lovell LL, Belanger N, Roth EJ. The effectiveness of anticoagulant and antiplatelet agents in preventing venous thromboembolism during stroke rehabilitation: A historical cohort study. *Archives of Physical Medicine and Rehabilitation* 2004;85:1070-1075.
15. Ginsber JS, Bates SM, Oczkowski W, Booker N, Magier D, MacKunion B, Weite J, Kearon C, Cruickshank M, Julian JA, Gent M. Low-dose warfarin in rehabilitating stroke survivors. *Thrombosis Research* 2002;107:287-290.
16. Mazzone C, Chiodo GF, Sandercock P, Miccio M, Salvi R. Physical methods for preventing deep vein thrombosis in stroke. *Cochrane Database of Systematic Reviews* 2004;4: CD001922.
17. Izzo KL, Aquino E. Deep venous thrombosis in high risk hemiplegic patients: Detection by impedance plethysmography. *Archives of Physical Medicine and Rehabilitation* 1986; 67:799-802.
18. Gibberd FB, Gould SR, Marks P. Incidence of deep vein thrombosis and leg oedema in patients with strokes. *Journal of Neurology, Neurosurgery, and Psychiatry* 1976;39:1222-1225.
19. Landi G, D'Angelo A, Boccardi E, Candese L, Mannucci P, Horabito A, Orazio EN. Venous thromboembolism in acute stroke. Prognostic importance of hypercoagulability. *Archives of Neurology* 1992;49:279-283.