

X-linked Charcot-Marie-Tooth disease and progressive-relapsing central demyelinating disease

G. Isoardo, MD; N. Di Vito, MD; M. Nobile, MD; G. Benetton, MD; and F. Fassio, MD

Transient signs and symptoms of CNS involvement have been reported in Charcot-Marie-Tooth disease type 1X (CMT1X).^{1,2} We describe a patient with CMT1X and chronic progressive-relapsing inflammatory demyelinating CNS disease.

Case report. A 44-year-old man was admitted because of subacute onset of gait ataxia, dysphagia, and dysarthria. He had experienced worsening stepping gait for the previous decade, and an EMG examination a year and a half before presentation had shown a demyelinating sensorimotor neuropathy. Otherwise, his medical history was unremarkable. Neurologic examination showed a wide based gait with ataxia worsening after eye closure, upper limb incoordination, and gaze-evoked nystagmus. There was weakness of foot dorsiflexion and toe extension. Tendon reflexes were absent. The patient was dysarthric and had dysphagia for liquids. EMG showed a mixed axonal-demyelinating polyneuropathy (table E-1 on the *Neurology* Web site at www.neurology.org). Visual evoked potentials (VEPs) were normal, whereas brainstem auditory potentials (BAEPs) showed alterations bilaterally (table E-1). Brain MRI showed multiple T2-hyperintense lesions in the pons, paraventricular region, and corpus callosum (see figure, A through C), without gadolinium (Gd) enhancement. Analysis of CSF showed increased protein content (82 mg/dL) with normal cell count. Oligoclonal IgG bands restricted to CSF were also detected. Sural nerve biopsy showed onion bulbs and loss of myelinated fibers, without inflammatory infiltrates. The patient was treated with IV methylprednisolone 1 g/day for 5 days, without appreciable benefit. One month later, during rehabilitation, he suddenly developed bilateral loss of visual acuity. VEPs showed marked prolongation of P100 wave latency (table E-1). He was treated again with IV methylprednisolone 1 g/day for 5 days, without benefit. Three years later, he was again admitted to our hospital. The neurologic examination showed severe gait ataxia which confined the patient to a wheelchair, and severe incoordination of upper limbs with marked action tremor. Dysarthria and dysphagia were moderate. Muscle strength was normal except for moderate weakness of tibialis anterior, extensor hallucis, and dorsal interossei. Urinary retention was also present. Brain MRI scans demonstrated increased T2-lesion load and one Gd-enhancing lesion in the pons (figure, D). BAEPs and VEPs were unchanged. Treatment with IV immunoglobulins (0.4 g/kg/day) was withdrawn after 2 days because of hematuria. DNA analysis showed the mutation c490 C>T, R164W in the GJB1 gene. The family history was reassessed. A brother showed stepping gait with bilateral severe deficit of ankle dorsiflexion and, to a lesser degree, plantar flexion. EMG showed a mixed sensorimotor polyneuropathy with conduction velocities in the same range of the index case. BAEP and VEP were unremarkable. Brain MRI was normal. Genetic analysis showed the same mutation of GJB1 gene identified in the index case.

Discussion. Our index patient showed a CNS demyelinating disease that satisfied the diagnostic criteria for primary progressive multiple sclerosis (MS).³ Previous reports described transient involvement of CNS in patients with CMT1X,^{1,2} however, none of the reported patients satisfied the diagnostic criteria for MS. Even if the association of CMT1X and MS in our index patient is coincidental, there seems to be a relationship between these entities.

First, the patient showed a pure clinical cerebellar/brainstem syndrome, which accounts for no more than 10% of clinical presentation of primary progressive MS.³ The preferential involvement

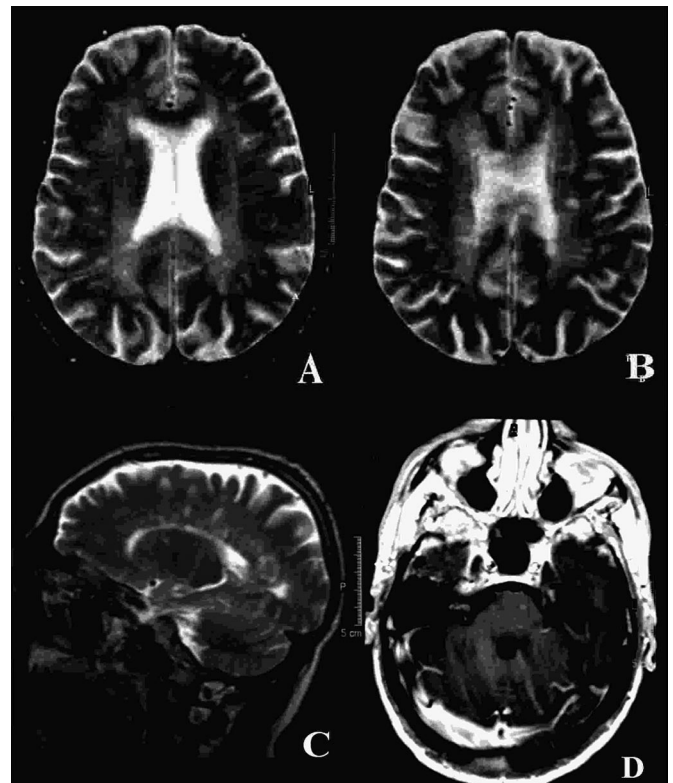


Figure. (A–C) At presentation, MRI showing multiple T2-hyperintense lesions involving corpus callosum, pons, and paraventricular region. (D) At 3-year follow-up, MRI showing the presence of a gadolinium enhancing lesion.

of brainstem and cerebellum in CMT1X was previously suggested by the high frequency of abnormal BAEPs,⁴ and the evidence of decreased blood flow in the cerebellum by SPECT.⁵ The course of our patient seems to suggest a preferential axonal damage as responsible for worsening disability. Axonal damage is now regarded as an important pathogenic factor in progressive MS.³ Patients with CMT1X may show either a demyelinating or an axonal neuropathy and previous reports suggested that axonal damage may be a primary effect of connexin 32 mutations.⁶

The presence of a Gd-enhancing lesion in the MRI and of intrathecal synthesis of IgG suggested the presence of inflammation. Superimposed inflammatory demyelinating polyneuropathies were described in patients with CMT1X,⁷ suggesting that alterations in myelin proteins may trigger a secondary autoimmune response.

Taken together, these observations suggest a possible role of the connexin 32 mutation in determining the onset, clinical features, and course of our patient. Further studies are needed to evaluate the role of these proteins in the pathogenesis of progressive MS with cerebellar/brainstem presentation.

Acknowledgment

The authors thank N. Pallechi, L. Civitate, and S. Cappello for help collecting data.

From SOC Neurologia (Drs. Isoardo, Di Vito, Nobile, and Fassio), Ospedale Civile di Asti; and SCDU Genetica Medica (Dr. Benetton), Ospedale San Giovanni Battista di Torino, Italy.

Disclosure: The authors report no conflicts of interest.

Received April 13, 2005. Accepted in final form August 4, 2005.

Address correspondence and reprint requests to Dr. Gianluca Isoardo, SOC Neurologia, Ospedale Civile di Asti, via Botallo 4, 14100 Asti, Italy; e-mail: gianlucaisoardo@yahoo.it

Additional material related to this article can be found on the *Neurology* Web site. Go to www.neurology.org and scroll down the Table of Contents for the November 22 issue to find the title link for this article.

References

1. Panas M, Karadimas C, Avramopoulos D, Vassilopoulos D. Central nervous system involvement in four patients with Charcot-Marie-Tooth disease with connexin 32 extracellular mutations. *J Neurol Neurosurg Psychiatry* 1998;65:947-948.
2. Taylor RA, Simon EM, Marks HG, Scherer SS. The CNS phenotype of X-linked Charcot-Marie-Tooth disease. More than a peripheral problem. *Neurology* 2003;61:1475-1478.
3. Thompson A. Overview of primary progressive multiple sclerosis (PPMS): similarities and differences from other forms of MS, diagnostic criteria, pros and cons of progressive diagnosis. *Mult Scler* 2004;10:S2-S7.

4. Nicholson G, Corbett A. Slowing of central conduction in X-linked Charcot-Marie-Tooth neuropathy shown by brainstem auditory evoked responses. *J Neurol Neurosurg Psychiatry* 1996;61:43-46.
5. Kawakami H, Inoue K, Sakakihara I, Nakamura S. Novel mutation in X-linked Charcot-Marie-Tooth disease associated with CNS impairment. *Neurology* 2002;59:923-926.
6. Hattori N, Yamamoto M, Yoshihara T, et al. Demyelinating and axonal features of Charcot-Marie-Tooth disease with mutations in the myelin-related proteins (PMP22, MPZ and Cx32): a clinicopathological study of 205 Japanese patients. *Brain* 2003;126:134-151.
7. Ginsberg L, Malik O, Kenton AR, et al. Coexistent hereditary and inflammatory neuropathy. *Brain* 2003;127:193-202.

Autoimmune hearing loss in chronic inflammatory demyelinating polyneuropathy

K. Sivakumar, MD; and Terry D. Fife, MD

Asymptomatic cranial nerve involvement, most commonly in oculomotor and facial nerves, can be seen in chronic inflammatory demyelinating polyradiculoneuropathy (CIDP). It is not always possible to delineate whether cranial nerve abnormalities are related to brainstem or extra axial involvement.¹ However, disabling vestibular symptoms on one occasion² and auditory symptoms on another occasion³ were described and attributed to peripheral nerve demyelination.

We describe a patient with CIDP who developed sensorineural hearing loss suggestive of autoimmune inner ear disease (AIED).

Case report. A 42-year-old previously healthy woman reported distal sensory symptoms in her feet and hands with distal weakness that began 1 year earlier. She also described difficulty hearing with the right ear from onset, which developed suddenly, without tinnitus. She had moderate intrinsic hand muscle, ankle, and toe dorsiflexion weakness. She was areflexic with only vibration deficits up to the ankles. The nerve conduction studies confirmed a demyelinating polyneuropathy with classic abnormalities of marked slowing of motor nerve conduction in a patchy fashion. The CSF protein level was normal. The sural nerve biopsy demonstrated moderate loss of myelinated fibers, thinly myelinated fibers, and multi-layered onion bulbs. The picture was consistent with CIDP; other associated conditions were excluded.

When treated with prednisone 40 mg daily, her motor and sensory symptoms improved dramatically within 4 weeks. However, on tapering doses, she developed significant ankle weakness at 20 mg a day of prednisone. At the same time, she developed some vertigo, otalgia, tinnitus, and increasing hearing loss. Ear examination did not identify any abnormalities. An audiogram identified normal hearing on the left side with only a 30 dB loss at 8 kHz. On the right side there was a near linear sloping loss which began at 1.5 kHz and reached 40 dB at 8 kHz (figure, A). Discrimination score was excellent. The antibodies to 68-kD bovine inner ear protein were positive by Western blot immunoassay (IMMCO, Buffalo, NY). Screening for serologic markers of connective tissue diseases was negative. Quantitative vestibular testing demonstrated 73% right caloric paresis and 19% right directional preponderance. All other caloric motor recordings were normal. The distortion product otoacoustic emissions study of the right ear showed poor responses above 3,000 Hz but normal responses at low frequencies (see the figure, B). Responses were all normal on the left. The brainstem auditory evoked potential (BAEP) study was normal with no abnormalities of absolute or interwave latencies.

Discussion. Patients with CIDP and abnormal BAEP suggesting brainstem dysfunction do not have vestibulocochlear symptoms.¹ However, bilateral vestibular or cochlear symptoms reported on only two occasions in patients with CIDP were identified to be due to demyelination of the vestibulocochlear nerve and responded well to immunomodulatory therapy.^{2,3} The patient we described developed fluctuating hearing loss that, at least initially, followed the clinical course of the CIDP. She had evidence of auditory hair cell dysfunction, associated with anti-68kD antibodies, as seen with AIED that responds to steroids.^{4,5} Auditory neuropathy from demyelination, as described in previous cases of CIDP,^{2,3} appeared unlikely since abnormal otoacoustic emissions specifically implicated the micromechanical activity of outer hair cells. However, in our patient the hearing loss did not respond to

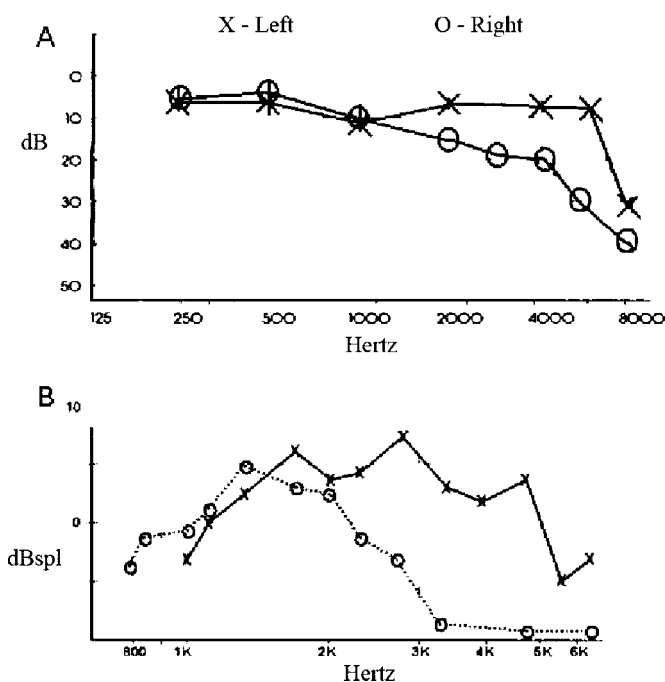


Figure. (A) Reduction in hearing on the right side at frequencies greater than 1,000 Hz. (B) Reduction in otoacoustic responses on the right side above 3,000 Hz that is consistent with outer hair cell dysfunction in the right labyrinth. dB = decibels; dBspl = decibels of sound pressure level.

high dose prednisone or immunomodulatory therapy despite improvement in the sensory motor deficits of CIDP.

The antibodies against 68 kD bovine inner ear protein, subsequently identified to be heat shock protein (HSP) 70, are seen in normal sera.^{5,6} However, these antibodies are significantly elevated in patients with hearing loss of inner ear origin that respond to steroids.⁵ The biologic meaning of elevated HSP 70 in AIED is yet unknown. Whether the Western Blot or the recently described ELISA would give a better quantitative measure of this antibody is also not resolved.^{4,6} Hearing loss in AIED is most frequently associated with tinnitus and vestibular symptoms. While only 25% of patients with AIED have unilateral hearing loss, 17% have other associated systemic autoimmune diseases, and an even smaller 15% respond to various immunomodulatory therapy.⁷ This report of CIDP and inner ear disorder, both of autoimmune origin occurring simultaneously in the same patient, raises issues of shared precipitating factors and antigenic targets.

From Barrow Neurological Institute and University of Arizona College of Medicine, Phoenix.

Disclosure: The authors report no conflicts of interest.

Received March 25, 2005. Accepted in final form August 16, 2005.

Address correspondence and reprint requests to Dr. K. Sivakumar, Neuromuscular Research Center, 10200 N 92nd Street, Scottsdale, AZ 85258; e-mail: ksivakumar@azneuromuscular.org

References

1. Mendell JR, Kolkun S, Kissel JT, et al. Evidence for central nervous system demyelination in chronic inflammatory demyelinating polyradiculoneuropathy. *Neurology* 1987;37:1291-1294.
2. Frohman EM, Tusa R, Mark AS, Cornblath DR. Vestibular dysfunction in chronic inflammatory demyelinating polyneuropathy. *Ann Neurol* 1996;39:529-535.
3. Hengstman GJ, Schelhaas HJ, Zwarts MJ. Auditory dysfunction in chronic inflammatory demyelinating polyradiculoneuropathy. *Neurology* 2004;62:1446-1448.

4. Moscicki RA, San Martin JE, Quintero CH, Rauch SD, Nadol JB Jr., Bloch KJ. Serum antibody inner ear proteins in patients with progressive hearing loss. Correlation with disease activity and response to steroid treatment. *JAMA* 1994;272:611-616.
5. Munari L, Charchat S, Rodriguez L, et al. An ELISA serum assay for autoantibodies to HSP70 in immune-mediated hearing loss. *J Immunol Methods* 2003;283:155-161.
6. Samuelsson AK, Hyden D, Roberg M, Skogh T. Evaluation of ant-hsp 70 antibodies in sudden deafness. *Ear Hear* 2003;24:233-235.
7. Broughton SS, Meyerhoff WE, Cohen SB. Immune-mediated inner ear disease: 10-year experience. *Semin Arthritis Rheum* 2004;34:544-548.

Herpes encephalitis after meningioma resection

Markus Ploner, MD; Bernd Turowski, MD; and Gabriele Wöbker, MD

Herpes simplex encephalitis (HSE) is the most common and gravest sporadic form of acute encephalitis.^{1,2} Between 30 and 70% of cases are fatal, and the majority of patients who survive have serious neurologic complications. In adults, HSE mostly results from reactivation of latent herpes simplex virus (HSV) infection of trigeminal nerve ganglia or brain parenchyma. We present a case of HSE in an immunocompetent patient after uneventful meningioma resection, which shows that HSE is a rare^{3,4} but severe complication after neurosurgery. We also show that decompressive craniotomy can be a lifesaving option for HSE treatment.

Case report. A 47-year-old woman presented with headache and a slowly progressive right-sided disturbance of vision. Otherwise, the medical history of the patient was unremarkable. On examination, apart from a decreased visual acuity of the right eye, no neurologic deficit was detected. A CT scan revealed a meningioma of the right sphenoid wing, which was uneventfully resected. To diminish postoperative edema, the patient received steroid therapy for 2 days. Three days after neurosurgery, the patient left the hospital without complaints. Ten days after resection, she presented with fever and fluctuating confusion. On clinical examination, no focal neurologic abnormality was detected. Laboratory investigations revealed a slight elevation of C-reactive protein (2.2 mg/dL) and liver enzymes. CSF was unremarkable; white blood cell count was $<1/\mu\text{L}$. A CT scan showed a right-sided edema with diffuse contrast enhancement. During the next 2 days, the patient's level of consciousness decreased to a comatose state. On the third day after presentation, an anisocoria evolved, and a CT control showed beginning tentorial herniation. Decompressive craniotomy was immediately carried out. HSE was considered, and therapy with acyclovir was started. HSE was confirmed by HSV PCR from brain biopsy and CSF, which now showed a slight pleocytosis of 12 white blood cells/ μL . A MRI scan 2 days after craniotomy showed typical features of HSE (figure). During the next 3 months, the patient returned to an awake but apathic state.

Discussion. HSE results from primary infection or reactivation of latent HSV infection of trigeminal nerve ganglia or brain parenchyma.^{1,2} The mechanisms of HSV reactivation are unclear. However, immunodeficient states associated with steroid therapy, radiotherapy, trauma, and stress predispose for reactivation of HSV. In this case of an otherwise healthy young woman, stress, trauma, and short-term perioperative steroid therapy may have yielded a transient immunodeficiency, facilitating HSV reactivation.

Fever, headache, confusion, and an impairment of consciousness are typical clinical features of HSE.^{1,2} However, after neurosurgery, these unspecific symptoms may be attributed to local or systemic bacterial infections rather than to HSE. The current case and previous reports^{3,4} show that HSE should always be considered in patients with fever of unknown origin after neurosurgery. Particularly, a latency period from 4 to 10 days after surgery appears to be typical for the onset of HSE. In the case of inconclusive CSF and CT scan findings in the typical latency period, HSV PCR and MRI scan should be immediately carried out, which may allow for an early diagnosis and therapy of HSE.

Moreover, in the case of increasing intracranial pressure with progressive clinical deterioration, decompressive craniotomy can be lifesaving if carried out in time. This is supported by previous

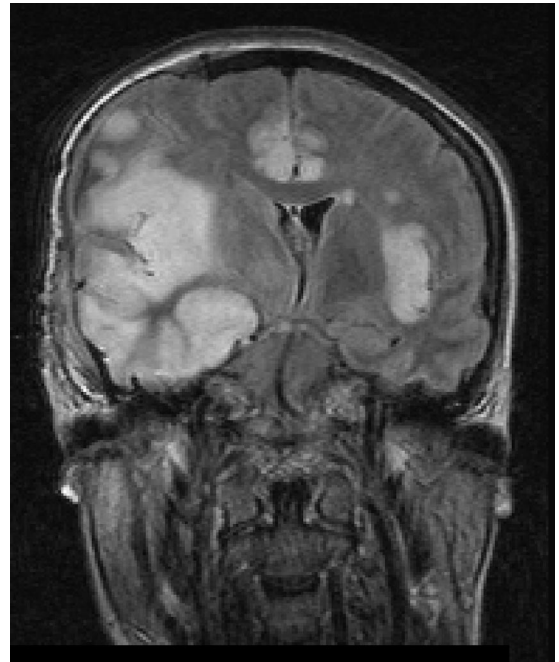


Figure. The coronal fluid-attenuated inversion recovery MRI scan shows signal increases in the right temporal lobe, the bilateral insular cortex and the cingulate gyrus, a pattern typical for herpes encephalitis. The scans were taken 2 days after decompressive craniotomy and 15 days after resection of a meningioma of the right sphenoid wing.

reports on surgical decompression in patients with severe encephalitis and increased intracranial pressure unresponsive to medical treatment.⁵⁻⁷ In these cases, most patients had a favorable outcome. However, in the current case, the patient persisted in an apathic state without focal neurologic sequelae. Thus, in HSE, decompressive craniotomy should be considered carefully.

We present a case of an immunocompetent patient with HSE after meningioma resection. HSE should be considered in cases of unexplained fever, confusion, and impairments of consciousness after neurosurgery. HSV PCR and an early MRI scan may help in early establishment of the diagnosis. Moreover, in selected cases, decompressive craniotomy can be a lifesaving therapy of increased intracranial pressure in HSE.

From the Departments of Neurology (Dr. Ploner), Radiology (Dr. Turowski), and Neurosurgery (Dr. Wöbker), Heinrich Heine University, Düsseldorf, Germany.

Disclosure: The authors report no conflicts of interest.

Received May 3, 2005. Accepted in final form August 16, 2005.

Address correspondence and reprint requests to Dr. M. Ploner, Department of Neurology, Heinrich-Heine-University, Moonenstr. 5, 40225 Düsseldorf, Germany; e-mail: ploner@neurologie.uni-duesseldorf.de

Copyright © 2005 by AAN Enterprises, Inc.

References

1. Tyler K. Herpes simplex virus infections of the central nervous system: encephalitis and meningitis, including Mollaret's. *Herpes* 2004;11:57A-64A.
2. Baringer JR. Herpes simplex virus encephalitis. In: Davis LE, Kennedy PGE, eds. *Infectious diseases of the nervous system*. Oxford: Butterworth Heinemann, 2000:139-164.
3. Spuler A, Blaszyk H, Parisi JE, Davis DH. Herpes simplex encephalitis after brain surgery: case report and review of the literature. *J Neurol Neurosurg Psychiatry* 1999;67:239-242.
4. Aldea S, Joly LM, Roujeau T, Oswald AM, Devaux B. Postoperative herpes simplex virus encephalitis after neurosurgery: case report and review of the literature. *Clin Infect Dis* 2003;36:e96-e99.
5. Schwab S, Junger E, Spranger M, et al. Craniectomy: an aggressive treatment approach in severe encephalitis. *Neurology* 1997;48:412-417.
6. Taferner E, Pfausler B, Kofler A, et al. Craniectomy in severe, life-threatening encephalitis: a report on outcome and long-term prognosis of four cases. *Intensive Care Med* 2001;27:1426-1428.
7. Yan HJ. Herpes simplex encephalitis: the role of surgical decompression. *Surg Neurol* 2002;57:20-24.

Rotational vestibular epilepsy from the temporo-parieto-occipital junction

E. Erbayat Altay, MD; A. Serdaroglu, MD; K. Gucuyener, MD; E. Bilir, MD; N.I. Karabacak, MD; and L.L. Thio, MD, PhD

Humans likely have multiple cortical areas for processing vestibular information rather than a primary vestibular cortex.¹ The parietal, temporal, and frontal lobes contain areas that receive vestibular input, with the temporo-perisylvian vestibular cortex having a dominant role.²

Cortical stimulation studies and naturally occurring lesions such as strokes have helped map the human vestibular cortex. Alternatively, partial seizures can serve as a natural form of cortical stimulation for mapping human cortical function. Ictal EEG recordings demonstrate that the posterior portion of the middle frontal gyrus receives rotational vestibular input and can serve as the focus for epileptic rotational vertigo.³ Although previous studies implicate the parieto-temporal area as a focus for vestibular epilepsy,⁴ direct clinical evidence is lacking. We report a boy with partial epilepsy characterized by rotational vertigo and ipsilateral head and eye deviation with jerking eye movements triggered visually following a moving object.

Case report. An otherwise healthy, developmentally normal 8-year-old boy was evaluated for a 3-year history of episodes of dizziness and eye jerking. These episodes lasted <1 minute and were not associated with other motor activity or loss of consciousness.

The episodes were often induced by looking at a moving object. His initial evaluation included a normal head MRI and a 20-minute awake EEG showing right mid to posterior temporal spikes with extension into the parietal area. Two days of continuous video-EEG monitoring revealed >30 typical seizures. Clinically, the seizures began with vertigo. A few seconds later, his head and eyes turned to the right as he developed bilateral horizontal jerking eye movements. Each seizure lasted 30 to 60 seconds and ended with his head and eyes returning to midline. Each seizure showed a similar EEG pattern starting with subtle voltage attenuation for 3 to 6 seconds in the right posterior quadrant simultaneously with the onset of vertigo. The attenuation evolved into rhythmic low voltage 12- to 14-Hz activity in that area. We induced a typical seizure by repetitively moving colorful flowers horizontally across his visual fields for an ictal SPECT. We injected the radiotracer within 10 seconds of the onset of vertigo. Comparison of the ictal and interictal SPECT scans showed increased perfusion in the right temporo-parieto-occipital area during the seizure (figure).

Discussion. Vestibular seizures classically consist of rotational or linear vertigo accompanied by body or head and eye rotation with or without nystagmus.⁵ Our patient had classic rotational vertiginous seizures with the vertigo being the first symptom of a seizure and occurring simultaneously with the EEG onset. This case further demonstrates that rotational vertiginous seizures can originate in the parieto-occipital area as might be expected from prior cortical stimulation studies.² However, the

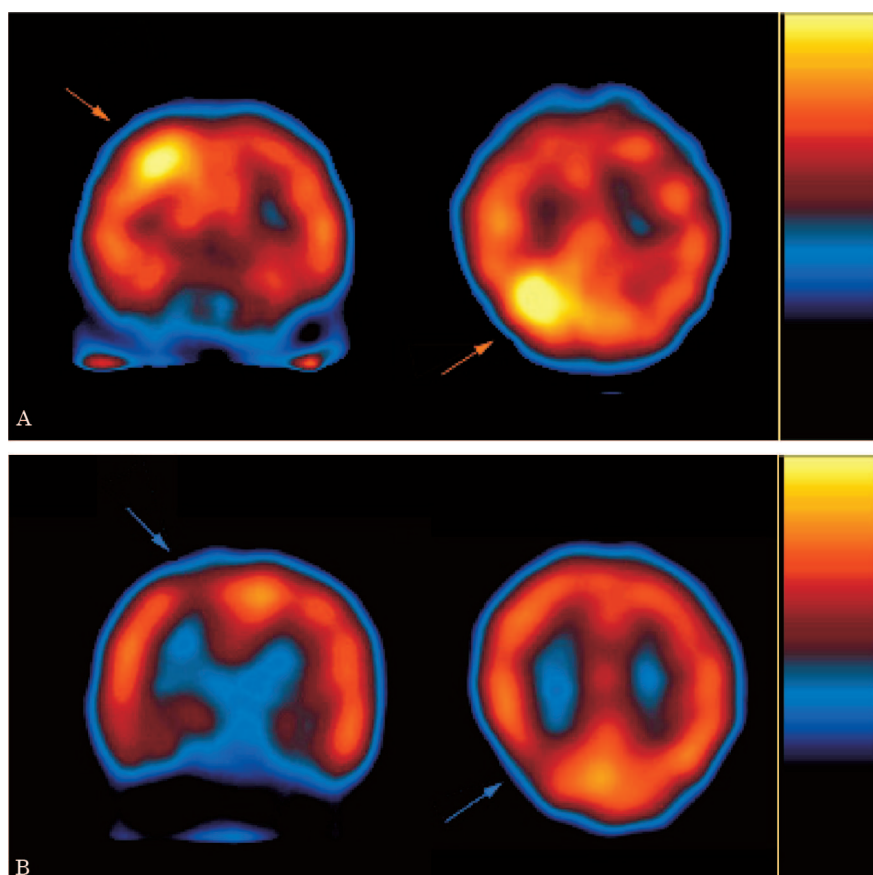


Figure. Interictal and ictal SPECT scans indicate a temporo-parieto-occipital focus for vertiginous seizures. (A) Ictal SPECT images obtained 30 minutes after the injection of radiotracer (14 mCi of ^{99m}Tc-hexamethylpropyleneamine oxime). Coronal (left) and axial (right) views show localized hyperperfusion at the right temporo-parieto-occipital junction (arrows). (B) Interictal SPECT images obtained after injection of the same radiotracer when the patient was seizure-free for 12 hours on medication. Coronal and axial views show localized hypoperfusion at the same area. Black and white color scales with black indicating low perfusion and bright white indicating high perfusion.

parieto-occipital area is not the only cortical site that can generate rotational vestibular seizures. An earlier case report showed that epileptic rotational vertigo can originate in the frontal lobe.³ These case studies are consistent with the idea that multiple cortical areas process a single type of self-motion perception such as rotational information. Thus, these findings are also consistent with the absence of a primary unimodal vestibular cortex in humans and demonstrate that vestibular seizures cannot be localized on clinical semiology alone.

The seizure focus in our case is consistent with the temporo-parieto-occipital focus identified previously in nonobtunded patients with epileptic horizontal nystagmus in which the fast phase is contraversive to the seizure focus.⁶ This type of epileptic nystagmus may originate in the cortical saccade, cortical pursuit, or cortical optokinetic region.⁶ Cortical representations for pursuit and optokinetic nystagmus within the temporo-occipital area when stimulated produce nystagmus with the fast phase contraversive to the side of stimulation.⁶ Given the relatively poor spatial resolution of the ictal EEG and SPECT, our patient may have a single focus in vestibular cortex or two with one in the vestibular cortex and another in the cortical pursuit or optokinetic region. Alternatively, a single focus may exist in the optokinetic region. Activation of the optokinetic region in the temporo-occipital area may cause vertigo because in monkeys it projects to the nucleus of the optic tract, which in turn projects to brainstem vestibular nuclei.⁷ As most seizures began with vertigo alone, we believe that a single focus in the optokinetic region is less likely. A simpler explanation for our patient having seizures beginning with vertigo and inducible by observing a moving object is that they start in multisensory neurons in the parieto-occipital vestibular cortex.¹

From the Departments of Neurology (Drs. Erbayat Altay and Thio) and Pediatrics (Dr. Thio) and Hope Center for Neurological Disorders (Drs. Erbayat Altay and Thio), Washington University School of Medicine, and

Department of Pediatric and Developmental Neurology (Dr. Thio), St. Louis Children's Hospital, St. Louis, MO; and Departments of Pediatric Neurology (Drs. Serdaroglu and Gucuyener), Adult Neurology (Dr. Bilir), and Nuclear Medicine (Dr. Karabacak), Gazi University School of Medicine, Ankara, Turkey.

Disclosure: The authors report no conflicts of interest.

Received December 3, 2004. Accepted in final form August 16, 2005.

Address correspondence and reprint requests to Dr. E. Erbayat Altay, Department of Neurology, Washington University School of Medicine, Campus Box 8111, 660 South Euclid Avenue, St. Louis, MO, 63110; e-mail: erbayate@neuro.wustl.edu

Acknowledgment

The authors thank Dr. Stephen M. Highstein for his helpful discussions.

Copyright © 2005 by AAN Enterprises, Inc.

References

1. Guldin WO, Grusser OJ. Is there a vestibular cortex? Trends Neurosci 1998;21:254-259.
2. Kahane P, Hoffmann D, Minotti L, Berthoz A. Reappraisal of the human vestibular cortex by cortical electrical stimulation study. Ann Neurol 2003;54:615-624.
3. Kluge M, Byenburg S, Fernandez G, Elger CE. Epileptic vertigo: evidence for vestibular representation in human frontal cortex. Neurology 2000;55:1906-1908.
4. Smith BH. Vestibular disturbances in epilepsy. Neurology 1960;10:465-469.
5. Brandt T. Vestibular epilepsy. In: Brandt T, ed. Vertigo: Its Multisensory Syndromes. 2nd ed. London: Springer-Verlag; 1999:233-239.
6. Kaplan PW, Tusa RJ. Neurophysiologic and clinical correlations of epileptic nystagmus. Neurology 1993;43:2508-2514.
7. Tusa RJ, Ungerleider LG. Fiber pathways of cortical areas mediating smooth pursuit eye movements in monkeys. Ann Neurol 1988;23:174-183.



Pacemaker-induced tachycardia caused by inappropriate response to parkinsonian tremor

A.-M. Wills, MD; D.T. Plante, MD; S.R. Dukkipati, MD; C.P. Corcoran, RN; and D.G. Standaert, MD

We report a 76-year-old man with Parkinson disease (PD) who developed symptomatic tachycardia (133 beats/min) as a result of the rate response of a cardiac pacemaker to his parkinsonian tremor.

Case report. The patient had a 20-year history of PD, treated with carbidopa/levodopa, entacapone, pramipexole, and amantadine. He presented to the Movement Disorders Clinic at Massachusetts General Hospital with 3 months of progressive confusion, hallucinations, decreased mobility, and considerable weight loss.

Three months prior to his presentation, he had undergone a four-vessel coronary bypass graft. Two weeks later, he required implantation of a Guidant Insignia I Plus DR model no. 1297 pacemaker for tachy-brady syndrome. Over the next few months, the patient experienced increasing confusion, hallucinations, and a 50-pound weight loss and became wheelchair bound. The day

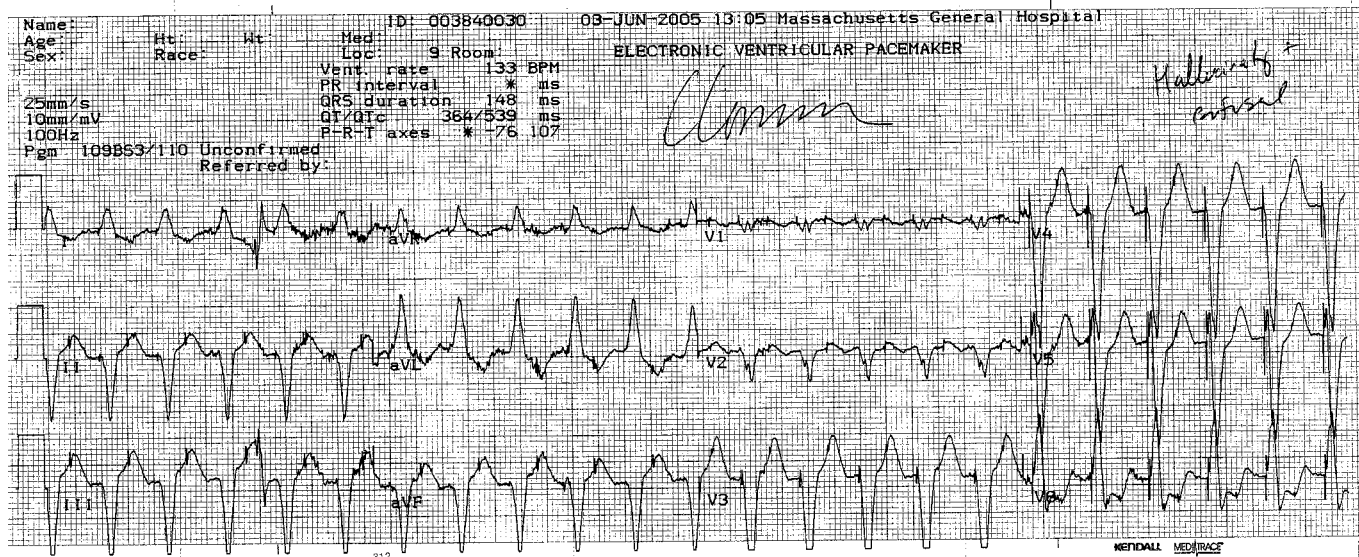


Figure. Wide complex tachycardia at a rate of 133 beats/min. Pacer spikes are seen in the T wave and before each QRS complex, representing atrial and ventricular pacing. Note the artifact created by the patient's tremor that is most prominent in leads I and aVL.

prior to admission, the hallucinations dramatically increased, and he attempted to call the police to report "people setting fire to his house."

On admission, he had a regular heart rate (88 beats/min), orientation to self and year but not to place, and no active hallucinations. His PD symptoms fluctuated between an "off" state with marked hypophonia (Unified Parkinson's Disease Rating Scale [UPDRS] score 3), moderate hypomimia (UPDRS 3), marked rigidity but full range of motion achieved in all four extremities (UPDRS 3), moderate amplitude tremor in the upper extremities (UPDRS 3), and slight tremor in the lower extremities (UPDRS 1) and an "on" state with a rating of mild to moderate rigidity (UPDRS 2) in the extremities and absent tremor (UPDRS 0). Head CT demonstrated microangiopathic changes but no interval changes to explain his hallucinations and decreased mobility.

During a routine echocardiogram the next afternoon, the patient was in an "off" state with significant tremor, including of the pectoralis muscles. His nurse, who accompanied him to the study, also noted increasing agitation, mild diaphoresis, and the onset of vivid hallucinations: "seeing kids in the backyard, wanting to call the police." His echocardiogram revealed tachycardia to the 130s. An EKG demonstrated that the tachycardia was 100% electronically paced (figure). The patient's heart rate normalized approximately 2 hours after the onset of tachycardia, after his next dose of PD medications, when he became less tremulous. The patient's hallucinations resolved, and his mental state improved as his heart rate normalized. His echocardiogram demonstrated an ejection fraction of 42% with segmental left ventricular dysfunction. Following this event, the peak troponin T was 0.06 ng/mL (normal range 0.00 to 0.09 ng/mL).

Interrogation of the pacer revealed a dual-chamber pacemaker with rate response pacing (DDD/R mode). (The Insignia I Plus pacemaker was approved by the Food and Drug Administration in

2002. According to the manufacturer's product data: "Adaptive-rate pacing is indicated for patients who may benefit from increased pacing rates concurrent with increases in level of physical activity."¹) Rate response (rate-adaptive) pacing is available in most newer pacemakers and is designed to allow patients to increase their heart rates in response to exercise, which is sensed by movement or increased respiratory rate.² Inappropriate tachycardia has been reported from going over bumpy roads,² but to our knowledge has not been previously reported from tremor. Rate response pacing was disabled in this patient, and his tachycardia did not recur.

Discussion. The rate response mode in cardiac pacemakers can cause adverse effects in patients with PD. This phenomenon may have importance in other types of hyperkinetic movement disorders. Of interest is the fact that the patient's tachycardia appeared to cause reversible hallucinations.

From the Department of Neurology (Dr. Wills and Standaert), Massachusetts General Hospital, Charlestown, and Departments of Psychiatry (Drs. Plante) and Cardiology (Dr. Dukkipati), Massachusetts General Hospital (C.P. Corcoran), Boston.

Disclosure: The authors report no conflicts of interest.

Received July 7, 2005. Accepted in final form August 16, 2005.

Address correspondence and reprint requests to Dr. A.-M. Wills, Department of Neurology, Massachusetts General Hospital, CNY 16 St., 114-2001, Charlestown, MA 02129; e-mail: awills@partners.org

Copyright © 2005 by AAN Enterprises, Inc.

References

1. Available at http://www.guidant.com/products/ProductTemplates/CRM/INSIGNIA_IFU.shtml. Accessed August 10, 2005).
2. Trohman RG, Kim MH, and Pinski SL. Cardiac pacing: the state of the art. *Lancet* 2004;364:1701–1719.

Neurology[®]

Pacemaker-induced tachycardia caused by inappropriate response to parkinsonian tremor

A. -M. Wills, D. T. Plante, S. R. Dukkipati, et al.
Neurology 2005;65;1676-1677
DOI 10.1212/01.wnl.0000184489.74795.b2

This information is current as of November 21, 2005

Updated Information & Services

including high resolution figures, can be found at:
<http://www.neurology.org/content/65/10/1676.full.html>

References

This article cites 1 articles, 0 of which you can access for free at:
<http://www.neurology.org/content/65/10/1676.full.html##ref-list-1>

Permissions & Licensing

Information about reproducing this article in parts (figures, tables) or in its entirety can be found online at:
<http://www.neurology.org/misc/about.xhtml#permissions>

Reprints

Information about ordering reprints can be found online:
<http://www.neurology.org/misc/addir.xhtml#reprintsus>

Neurology® is the official journal of the American Academy of Neurology. Published continuously since 1951, it is now a weekly with 48 issues per year. Copyright . All rights reserved. Print ISSN: 0028-3878. Online ISSN: 1526-632X.

