

CASE REPORT

Magnetoencephalography and positron emission tomography studies of a patient with auditory agnosia caused by bilateral lesions confined to the auditory radiations

KIMITAKA KAGA¹, TAKAHIDE KURAUCHI¹, MASAKO NAKAMURA¹,
MITSUKO SHINDO² & KENJI ISHII³

¹Department of Otolaryngology, University of Tokyo, ²Department of Language Disorders, Sophia University and

³Department of Positron Research, Geriatrics Research Institute of Tokyo, Tokyo, Japan

Abstract

The aim of this study was to investigate auditory cortex function in the context of auditory stimuli in a patient with auditory agnosia due to bilateral lesions confined to the auditory radiations. A male patient experienced mild left temporal hemiplegia because of right putaminal hemorrhage at the age of 43 years. Thereafter he recovered completely but hypertension persisted. When he was 53 years old, he suffered left putaminal hemorrhage and went into a coma. After recovering from the coma and right hemiplegia he could hear but could not discriminate speech sounds. Brain CT and MRI demonstrated small bilateral lesions confined to the auditory radiations. Magnetoencephalography demonstrated the disappearance of middle latency responses and auditory-evoked potential studies showed a very small Pa peak. In contrast, a positron emission tomography study demonstrated a marked increase in blood flow in the bilateral auditory cortex in response to both click and monosyllable stimuli. It is speculated that the auditory cortex receives functional projections from the cochlea via non-specific pathways in the cerebral hemispheres.

Keywords: Auditory agnosia, auditory radiation, magnetoencephalography, positron emission tomography

Introduction

Auditory agnosia is caused by bilateral lesions in the auditory cortex, auditory radiation or medial geniculate body [1–4]. However, in the case of bilateral lesions involving only the auditory radiations, it is not known what function remains in the preserved but isolated auditory cortex.

There are two parallel auditory systems in the brain [5]. The most important is the primary auditory pathway, which conveys neural signals of speech, music and environmental sounds from the cochlea through the cochlear nerve, brainstem auditory pathway and medial geniculate to the auditory radiation and auditory cortex. The other system is the non-specific auditory pathway, which conveys neural signals from the cochlea through the pontine and thalamic reticular formation or medial geniculate body to the cerebral cortex.

The aim of this study was to investigate whether function is absent or present in the auditory cortex of a patient with auditory agnosia due to bilateral lesions of auditory radiations but with a preserved auditory cortex. The investigation was conducted using magnetoencephalography (MEG), auditory-evoked potential (AEP) studies and positron emission tomography (PET). Many MEG studies of auditory cortex function have been reported [6–9] but studies of patients with auditory cortex lesions are rarely reported [10].

Case report

A male patient experienced left mild temporal hemiplegia as a result of right putaminal hemorrhage at the age of 43 years. Thereafter he recovered completely but hypertension persisted. When he was 53 years old, he went into a coma due to left

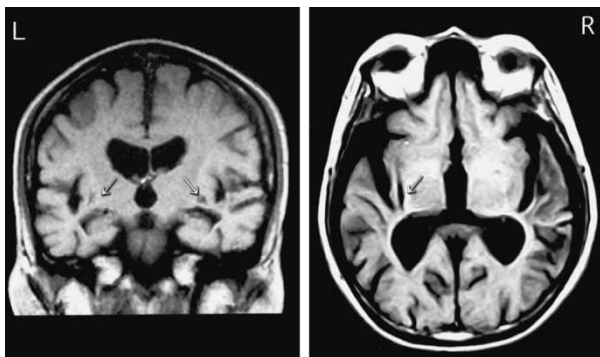


Figure 1. Brain MRI scan. In both hemispheres, the auditory radiations are damaged (arrows) by small brain infarctions.

putaminal hemorrhage. After recovering from the coma, he manifested mild right hemiplegia and hearing problems. The hemiplegia resolved with the exception of some residual weakness, but the auditory problems persisted. Although the patient could hear, he could not discriminate any speech, music or environmental sounds. Brain CT and MRI demonstrated localized small lesions in the bilateral auditory radiation only (Figure 1). Pure-tone audiometry revealed bilateral mild hearing loss (Figure 2).

AEP studies (Figure 3) demonstrated a normal electrocochleogram (EcochG), auditory brainstem response (ABR) and middle latency response (MLR). The K complex to sound stimuli was clearly recorded on electroencephalography (EEG) (Figure 4).

Neuropsychological tests demonstrated that although the patient could not discriminate any speech, music or environmental sounds he did not have aphasia (Figure 5). He was diagnosed as having auditory agnosia due to bilateral lesions confined to the auditory radiation, with preservation and isolation of the auditory cortex bilaterally. Subsequently,

his pure-tone threshold worsened in the higher frequencies (Figure 2).

MEG, AEP and PET studies

Audiological and neuropsychological tests were conducted to investigate the patient's auditory function and perception. Thirty-two-channel MEG was used to study middle latency auditory-evoked magnetic fields (MLAEFs), while electrical middle latency responses (EMLRs) were simultaneously recorded for comparison [5]. PET using fluorodeoxyglucose was conducted to investigate blood flow in the auditory cortex in response to auditory stimuli, consisting of clicks and monosyllables.

MEG and AEP studies were conducted 4 years after the second hemorrhage, at the time of the second audiogram shown in Figure 2. They demonstrated that MLAEFs were absent, with a very small Pa peak in the EMLR (Figure 6). In contrast, the PET study demonstrated increased blood flow in the bilateral auditory cortex in response to clicks and Japanese monosyllable verbal stimuli (Japanese monosyllables generally correspond to consonant-vowel sounds in English). Cerebral blood flow increased by at least 10% above the resting baseline in areas of the auditory cortex, especially with verbal stimuli, but did not reach the 20% increases typical of normal subjects (Figure 7).

Discussion

In this patient, the results of audiological and neuropsychological examinations were almost the same as those in patients with auditory agnosia or cortical deafness, which are caused by bilateral lesions of the auditory cortex [2,3]. However, because the auditory cortex was not damaged in

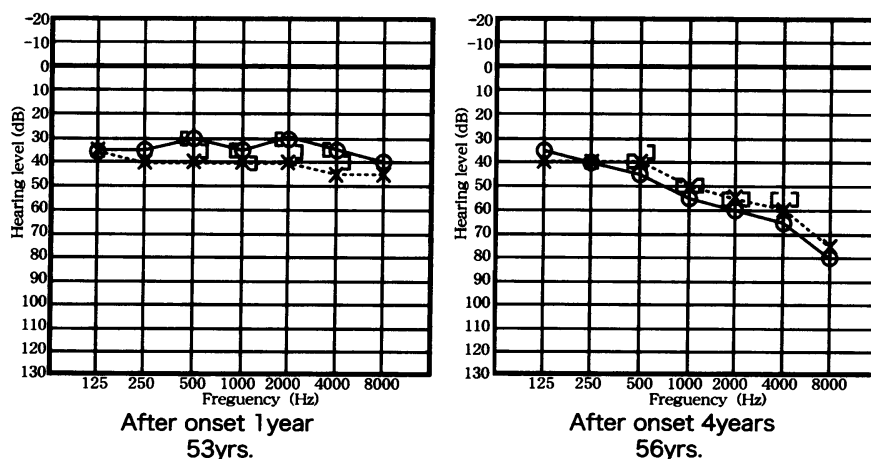


Figure 2. Pure-tone audiograms recorded 1 and 4 years after the second hemorrhage. The tests reported here were performed at the time of the later audiogram.

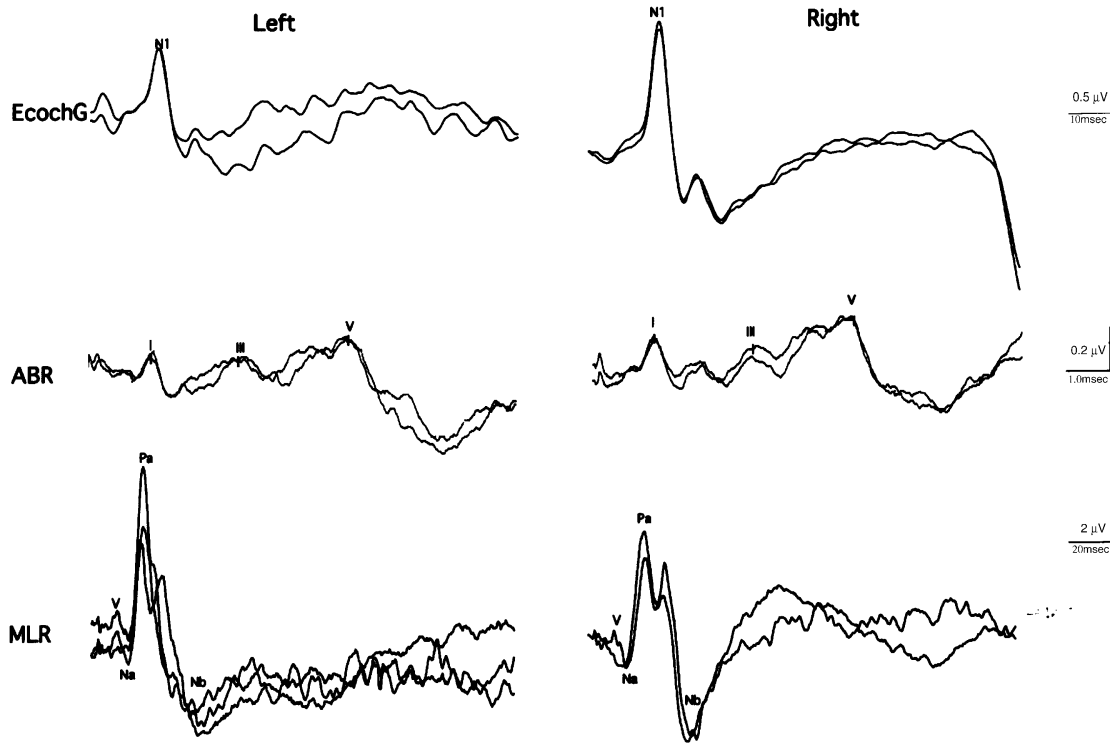


Figure 3. Results of the AEP studies. EcochG, ABR and MLR were normal in the right and left ears.

our patient, our concern was to investigate, using objective measures, whether the auditory cortex could respond to auditory stimuli.

There are two auditory pathways in the brain [5,11,12]. The most important is the specific auditory pathway, which is used for auditory perception. The other is the non-specific auditory pathway,

which is involved in arousal [5,12]. Although our patient's specific auditory pathway was damaged at the subcortical level of the auditory radiation, the non-specific auditory pathway was preserved. The PET study demonstrated an increase in blood flow in the auditory cortex of 10% (approximately half of normal) in response to auditory stimuli. However,

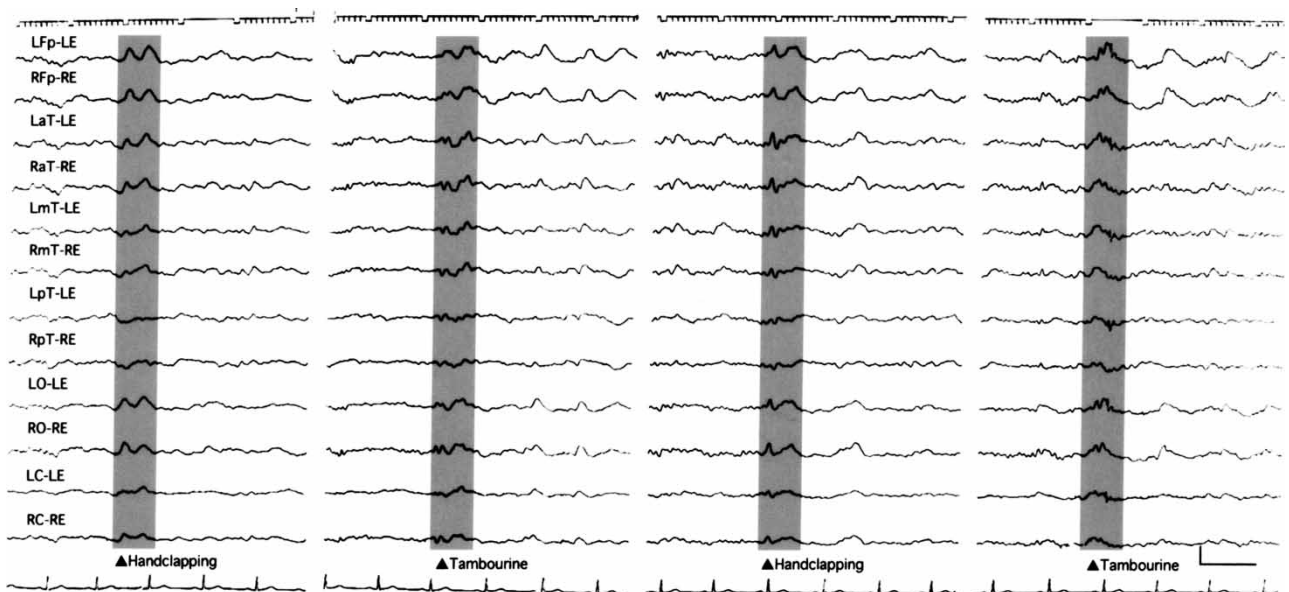
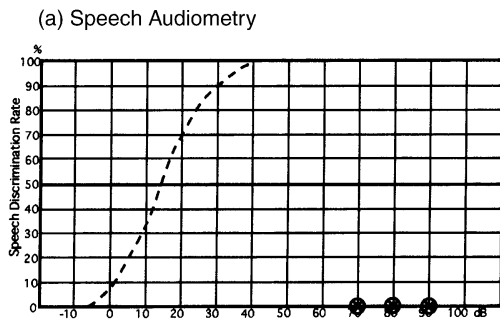


Figure 4. EEG recording. The K complex to sound stimuli was recorded from all electrode leads (shadow area).

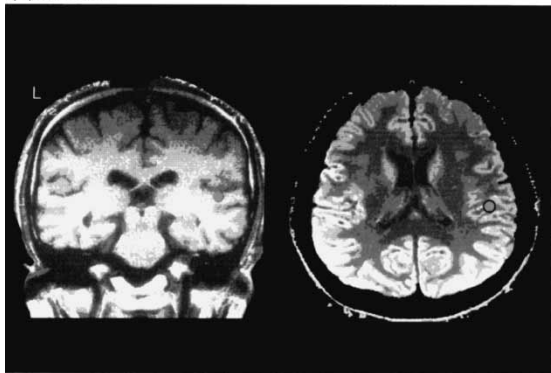


(b) Environmental sound perception test

Test Sound		Response	
		Oral Answer	Picture Matching
Human	1. Man's voice	×	×
	2. Woman's voice	×	×
	3. Singing	×	×
	4. Baby's cry	×	○
	5. English speech	×	×
	6. Laughter	×	○
Animal and Bird	1. Mewing (cat)	×	○
	2. Barking (dog)	○	○
	3. Mooing (cow)	×	×
	4. Neighing (horse)	×	×
	5. Cawing (crow)	×	○
	6. Crowing (cock)	×	×
Instrument	1. Drum	○	○
	2. Trumpet	×	○
	3. Wall clock	×	○
	4. Telephone ring	×	×
Nature	1. Whistle of wind	×	×
	2. Wave	×	○
	3. Stream	×	×
Artificial	1. Electric train	×	○
	2. Car	×	×
	3. Gunshot	○	×
	4. Saw	×	×
	5. Footsteps	×	×
		12.5%	41.5%

Figure 5. Results of the auditory perception tests. (a) Speech audiometry demonstrated zero discrimination at any intensity. (b) The environmental sound perception test showed poor performance as well (circles indicate correct responses). Normal individuals typically score 100% on both the open-set oral responses and the much less difficult closed-set picture matching task.

(a) Normal



(b) Patient

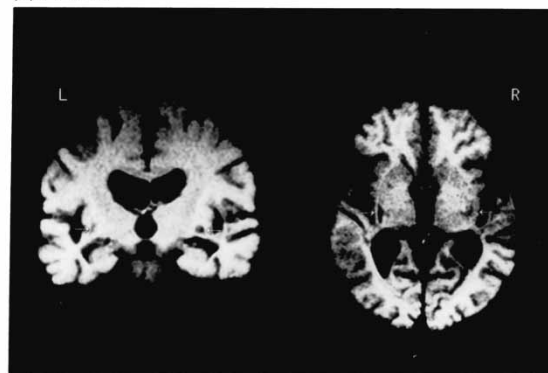


Figure 6. (a) Typical simultaneous recordings of AMLR and MLAEF in a normal subject (25-year-old male). Right and left hemisphere recordings were made with contralateral stimulation. The equivalent current dipole is superimposed on the audiology cortex in the brain MRI scan. The circle indicates the dipole localization. (b) Simultaneous recordings of AMLR and MLAEF in our patient. The Pam peak in the MLAEF is absent in both hemispheres but a very small Pa peak is present in the AMLR of both hemispheres.

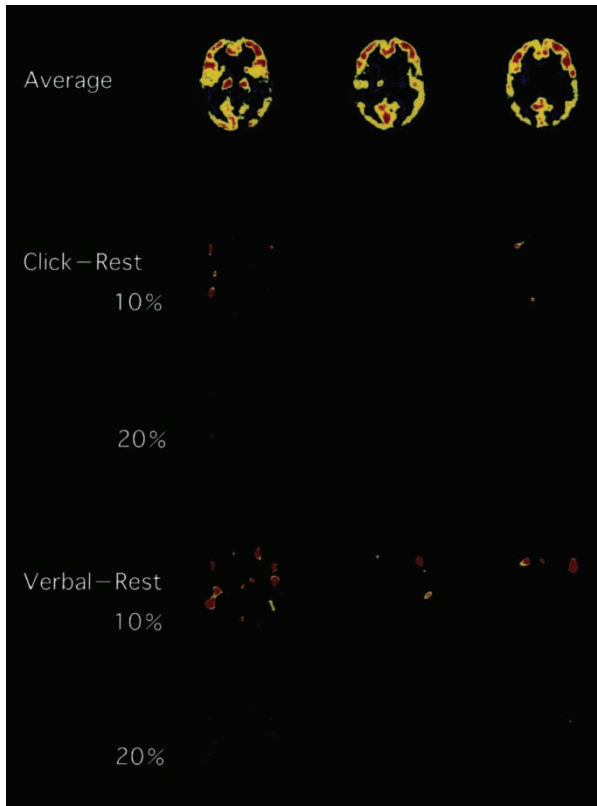


Figure 7. PET scans showing changes in regional cerebral blood flow (CBF) in response to click and verbal stimuli (100 monosyllables). *Top row* = averaged CBF image at rest. *Middle two rows* = increases in CBF over baseline in response to clicks. *Lower two rows* = increases in CBF over baseline in response to verbal stimuli. The images show areas of 10% and 20% increases over baseline blood flow. There are substantial areas showing 10% increases in response to verbal stimuli and smaller areas showing 10% increases in response to clicks. No areas show 20% increases, as would be expected in normal individuals.

the absence of MLAEFs and EMLRs indicated impaired function of the specific auditory pathway as a result of the bilateral lesions of the auditory radiation. In patients with auditory cortex lesions, MLAEFs and EMLRs have been reported to be absent [10]. However, it is significant that our patient could hear but could not discriminate most speech, music and environmental sounds. This discrepancy is considered to be caused by loss of the specific auditory pathway and preservation of the non-specific auditory pathway.

Finally, it is speculated that the auditory cortex receives projections not only from the specific auditory pathway but also from non-specific auditory pathways in the cerebral hemispheres.

Acknowledgement

We thank Ms H. Miyazaki for word processing.

References

- [1] Wernicke C, Friedländer C. Ein fall von Taubheit in folge von doppelseitiger lesion des Schlä felappens. *Fortschr Med* 1883;1:6.
- [2] Kaga K, Shindo M, Tanaka Y. Central auditory information processing in patients with bilateral auditory cortex lesions. *Acta Otolaryngol Suppl (Stockh)* 1997;532:77–82.
- [3] Kaga K, Shindo M, Tanaka Y, Haebara H. Neuropathology of auditory agnosia following bilateral temporal lobe lesions. *Acta Otolaryngol* 2000;120:259–62.
- [4] Kaga M, Shindo M, Kaga K. Long-term follow-up of auditory agnosia as a sequel of herpes encephalitis in a child. *J Child Neurol* 2000;15:626–9.
- [5] Rauschecker JP, Tian B. Mechanisms and streams for processing of “what” and “where” in auditory cortex. *Proc Natl Acad Sci U S A* 2000;97:11800–6.
- [6] Pantev C, Lütkenhöner B, Hoke M, Lehnertz K. Comparison between simultaneously measured auditory-evoked magnetic fields and potentials elicited by ipsilateral, contralateral and binaural tone burst stimulation. *Audiology* 1986;25:54–61.
- [7] Pantev C, Hoke M, Lehnertz K, Lütkenhöner B. Neuro-magnetic evidence of an amplitopic organization of the human auditory cortex. *Electroencephalogr Clin Neurophysiol* 1989;72:225–31.
- [8] Pelizzone M, Hari R, Mäkelä JP, Huttunen J, Ahlfors S, Hämäläinen M. Cortical origin of middle-latency auditory evoked responses in man. *Neurosci Lett* 1987;82:303–7.
- [9] Mäkelä JP, Hämäläinen M, Hari R, McEvoy L. Whole-head mapping of middle-latency auditory evoked magnetic fields. *Electroencephalogr Clin Neurophysiol* 1994;92:414–21.
- [10] Kaga K, Kurauchi T, Yumoto M, Uno A. Middle-latency auditory evoked magnetic fields in patients with auditory cortex lesions. *Acta Otolaryngol* 2004;124:376–80.
- [11] Kraus N, McGee T, Littsman T, Nicol T. Reticular formation influences on primary and non-primary auditory pathways as reflected by the middle latency response. *Brain Res* 1992;587:186–94.
- [12] Woods DL, Clayworth CC, Knight RT, Simpson GV, Naser MA. Generators of middle- and long-latency auditory evoked potentials: implications from studies of patients with bitemporal lesions. *Electroencephalogr Clin Neurophysiol* 1987;68:132–48.

Copyright of Acta Oto-Laryngologica is the property of Taylor & Francis Ltd. The copyright in an individual article may be maintained by the author in certain cases. Content may not be copied or emailed to multiple sites or posted to a listserv without the copyright holder's express written permission. However, users may print, download, or email articles for individual use.