

Case report

Alexia without agraphia following cerebral venous thrombosis associated with protein C and protein S deficiency

Nese Celebisoy*, Ayse Sagduyu, Ceyla Atac

Department of Neurology, Ege University Medical School Hospital, Bornova, 35100 Izmir, Turkey

Received 18 June 2004; received in revised form 13 September 2004; accepted 3 November 2004

Abstract

A 26-year-old right handed female was admitted to hospital with right homonymous hemianopia associated with alexia without agraphia. Her cranial magnetic resonance imaging and magnetic resonance angiography revealed a left occipital venous infarction due to thrombosis of the left transverse, sigmoid sinuses and the left internal jugular vein. The underlying conditions were protein C and protein S deficiency associated with the use of oral contraceptives. To our knowledge, alexia without agraphia has never been described due to a venous infarction associated with hereditary thrombophilia in the literature.

© 2004 Elsevier B.V. All rights reserved.

Keywords: Alexia without agraphia; Intracranial venous thrombosis; Protein C and S deficiency

1. Introduction

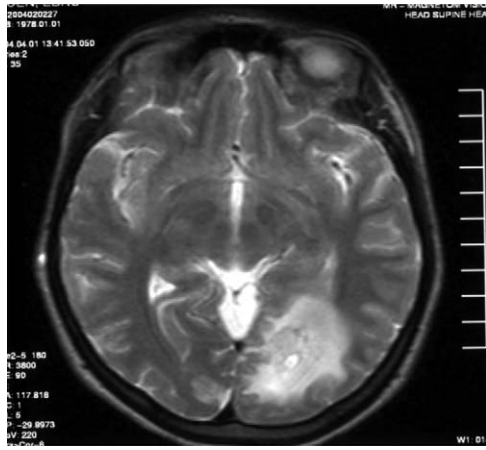
Alexia without agraphia is a rare disturbance, which is mostly caused by a stroke in the territory of the left posterior cerebral artery, with infarction of the medial occipital lobe, the medial temporal lobe, and often the splenium of the corpus callosum. However, the syndrome has also been reported in CNS infections [1,2], tumors [3], multiple sclerosis [4], eclampsia [5] and following head trauma [6], as well as with right occipital lobe lesions in left handed patients [7]. Venous infarction has not been mentioned as one of the etiologic factors.

2. Case Report

A 26-year-old right handed female was admitted to our clinic with right sided visual loss. Three days before admission she had complained about occipital head pain radiating to neck, followed by vomiting and loss of vision in both eyes for which she had been seen in another hospital. Loss of vision

had lasted for 3 h and resolved partially leaving a right sided hemianopia when she was taken to our clinic for further investigations. She had never experienced memory loss. Her past medical history was insignificant other than oral contraceptive usage for 6 months. Her physical examination was normal. The neurological examination revealed right homonymous hemianopia. The visual acuities were normal on both sides with normal fundoscopic appearance. At the time her history was taken she had almost normal language function but Boston Diagnostic Aphasia Examination revealed that she was unable to read the words and had difficulty in spelling. However, she could read the letters and the numbers and could name visually presented objects without difficulty. Her comprehension of oral spelling was normal. Though she was slow, she could write orally presented words correctly and she could name the colors. These clinical features were consistent with alexia without agraphia. The remainder of the examination was unrevealing. Her complete blood count showed anemia with Hb levels 8.6 mg/dl and Hct 27.2. Leukocyte and platelet counts were normal. Blood smears showed hypochromia and microcytosis. On blood biochemistry, serum iron concentration was found to be 12 µg/dl (50–140) and the iron binding capacity was 360 µg/dl (250–350), which were consistent with iron deficiency anemia. The rest of the blood

* Corresponding author. Tel.: +90 232 3880980; fax: +90 232 3880980.
E-mail address: celebi@med.ege.edu.tr (N. Celebisoy).



Cerebral venous thrombosis (CVT) accounts for less than 1% of all strokes [12]. The disease occurs in all age groups with peak incidences in neonates and in adults in their third decade with a female/male ratio of 1.5–5 [13]. The presenting clinical picture depends on the extension, localisation and activity of the thrombotic process as well as on the presence of venous collaterals [12]. Headache is the most frequent symptom of CVT and occurs in 75–95% of all cases [13,14]. In most cases, headache precedes the development of other neurological deficits for days. Focal neurological signs are the most common finding. They include central motor and sensory deficits, aphasia or hemianopia and occur 40–60% of all cases. Our patient had a history of occipital head pain for 3 days when she first realized bilateral visual loss which lasted for a few hours and resolved partially leaving a right sided homonymous hemianopia associated with alexia without agraphia, found on neurological examination. The usual lesion for this disorder is one that destroys the visual cortex of the left hemisphere and the splenium of the corpus callosum. However, in our patient the lesion was restricted to the

3. Discussion

Alexia without agraphia is a rare disconnection syndrome first described by the French neurologist Dejerine in 1892 in a patient with an infarction involving the medial occipital

left occipital lobe and alexia without agraphia was a transient disorder, which seems to be due to the edema effect on the medial structures.

The diagnosis of CVT is based on neuroimaging. CT is usually the first investigation performed in the emergency room [15]. The cord sign, a visualization of a hyperdense thrombosed cortical vein and a dense triangle sign indicating a fresh thrombus in the posterior part of the superior sagittal sinus are direct signs of CVT on unenhanced CT. Empty triangle or delta sign, a non-filling of the confluens sinuum on contrast enhanced CT is the most frequently observed direct sign. MRI and MRA are the best tools both for the diagnosis and follow up of CVT [16,17]. Within the first days, the thrombus appears isointense on T1-weighted and hypointense on T2-weighted images. An absence of flow void in the form of higher intraluminal signal intensity is observed after administration of gadolinium. In the majority of cases multiple small intraparenchymal haemorrhages surrounded by a hypodensity, which is compatible with venous hemorrhagic infarction is found. Pathophysiologically, venous thrombotic occlusion increases venous and capillary pressure and thus promotes diapedesis of erythrocytes causing haemorrhagic infarcts in CVT [18]. MRA shows a loss of signal-due to absence of flow-of the thrombosed sinus. Unenhanced CT of our patient showed hyperdensity of the left sigmoid sinus associated with a left occipital hypodensity. MRI revealed a left occipital lobe lesion with both hypointense and hyperintense components on T1- and T2-weighted images consistent with a hemorrhagic infarction. MRA showed thrombosis of the left transverse, sigmoid sinuses and the left internal jugular vein.

Underlying conditions which may cause CVT are varied [14,15,19]. The aetiology remains unknown in up to 35% of cases [20]. A hereditary thrombophilia will be found in 20–30% of patients [21]. Common inherited thrombophilic dispositions are the factor V Leiden mutation, 20210 G to A mutation of the prothrombin gene, antithrombin, protein C and protein S deficiency. Factor V Leiden mutation is detected in 15–17% and prothrombin gene mutation in 10–12% of the cases whereas protein C and S deficiency is rare and detected in only 2–6% of cases. Several studies have indicated that the combination oral contraceptives and thrombophilia greatly increased the risk of CVT [22,23]. In addition to protein S and C deficiency our patient was using oral contraceptives.

Available treatment data from collected trials favour the use of anticoagulation in patients with CVT [24,25]. However, controlled data about the optimal duration of therapy does not exist [12]. Oral anticoagulation is recommended for 3 months in patients with idiopathic CVT and for 3–6 months if it is related to pregnancy or oral contraceptives. In patients with hereditary thrombophilia it is used for 6–12 months or longer [12]. Anticoagulant therapy was instituted in our patient after the diagnosis of CVT was verified. Alexia without agraphia showed prominent regression at the end of three weeks but right sided hemianopia was continuing.

In the current literature, this is the first case with alexia without agraphia due to CVT associated with hereditary thrombophilia and oral contraceptive usage.

References

- [1] Erdem S, Kansu T. Alexia without agraphia or hemianopia in temporal lobe lesion due to herpes simplex encephalitis. *J Neuroophthalmol* 1995;15:102–4.
- [2] Luscher C, Horber FF. Transitory alexia without agraphia in an HIV-positive patient suffering from toxoplasma encephalitis: a case report. *Eur Neurol* 1992;32:26–7.
- [3] Turgman J, Goldhammer Y, Braham J. Alexia without agraphia due to brain tumor: a reversible syndrome. *Ann Neurol* 1979;6:265–8.
- [4] Dogulu CF, Kansu T, Karabudak R. Alexia without agraphia in multiple sclerosis. *J Neurol Neurosurg Psychiatry* 1996;61:528.
- [5] Sabet YS, Blake P, Nguyen D. Alexia without agraphia in a postpartum eclamptic patient with Factor V Leiden deficiency. *Am J Neuroradiol* 2004;25:419–20.
- [6] Bhattoo HS, Rohatgi S. Transitory alexia without agraphia following head injury. *Neurol India* 2002;50:226–8.
- [7] Estanol B, Vega-Boada F, Corte-Franco G, Juarez S, Hernandez R, Garcia-Ramos G. Alexia without agraphia due to the lesion in the right occipital lobe in a left-handed man. *Rev Neurol* 1999;28:243–5.
- [8] Geschwind N, Fusillo M. Color naming defects in association with alexia. *Arch Neurol* 1966;15:137–46.
- [9] Mohr JP, Leicester J, Stoddard LT, Sidman M. Right hemianopia with memory and color deficits in circumscribed left posterior cerebral artery territory infarction. *Neurology* 1971;21:1104–13.
- [10] Geschwind N. Disconnection syndromes in animals and man. *Brain* 1965;88(237–294):585–644.
- [11] Damasio AR, Damasio H. The anatomic basis of pure alexia. *Neurology* 1983;33:1573–83; Bhattoo HS, Rohatgi S. Transitory alexia without agraphia following head injury. *Neurol India* 2002;50:226–8.
- [12] Masuhr F, Mehraein S, Einhaupl K. Cerebral venous and sinus thrombosis. *J Neurol* 2004;251:11–23.
- [13] De Bruijn SFTM, de Haan RJ, Stam J for the Cerebral Venous Sinus Thrombosis Study Group. Clinical features and the prognostic factors of cerebral venous and sinus thrombosis in a prospective series of 59 patients. *J Neurol Neurosurg Psychiatry* 2001;70:105–8.
- [14] Ameri A, Boussier MG. Cerebral venous thrombosis. *Neurol Clin* 1992;10:87–111.
- [15] Einhaupl KM, Masuhr F. Cerebral venous and sinus thrombosis—an update. *Eur J Neurol* 1994;1:109–26.
- [16] Isensee C, Reul J, Thron A. Magnetic resonance imaging of thrombosed dural sinuses. *Stroke* 1994;25:29–34.
- [17] Yuh WT, Simonson TM, Wang AM, Koci TM, Tali ET, Fisher DJ, et al. Venous sinus occlusive disease: MR findings. *Am J Neuroradiol* 1994;15:309–16.
- [18] Villringer A, Mehraein S, Einhaupl KM. Pathophysiological aspects of cerebral venous thrombosis. *J Neuroradiol* 1994;21:72–80.
- [19] Boussier MG, Chiras J, Bories J, Castaigne P. Cerebral venous thrombosis—a review of 38 cases. *Stroke* 1985;16:199–213.
- [20] Boussier MG. Cerebral venous thrombosis: diagnosis and management. *J Neurol* 2000;247:252–8.
- [21] Weih M, Junge-Hülsing J, Mehraein S, Ziemer S, Einhaupl KM. Hereditary thrombophilias in ischemic stroke and sinus vein thrombosis: diagnostic, therapy and meta-analysis. *Nervenarzt* 2000;71:936–45.
- [22] Martinelli I, Sacchi E, Landi G, Taioli E, Duca F, Mannucci PM. High risk of cerebral-vein thrombosis in carriers of a prothrombin-gene mutation and in users of oral contraceptives. *N Eng J Med* 1998;338:1793–7.

- [23] De Bruijn SFTM, Stam J, Koopmann MMW, Vandenbroucke JP for the Cerebral Venous Sinus Thrombosis Study Group. Case control study of cerebral sinus thrombosis in oral contraceptive users and in carriers of hereditary prothrombotic conditions. *BMJ* 1998;316:589–92.
- [24] De Bruijn SFTM, Stam J for the Cerebral Venous Sinus Thrombosis Study Group. Randomized, placebo-controlled trial of anticoagulant treatment with low-molecular-weight heparin for cerebral venous thrombosis. *Stroke* 1999;30:484–8.
- [25] Einhaupl KM, Villringer A, Meister W, Mahraein S, Garner C, Pelkkofer M, et al. Heparin treatment in sinus venous thrombosis. *Lancet* 1991;338:597–600.