

## Case report

# Concurrent cerebral and axillary artery occlusion: a possible source of cerebral embolization from peripheral artery thrombosis

Wei-Hsi Chen, Shun-Sheng Chen, Jia-Shou Liu\*

*Stroke Biology Research Laboratory, Department of Neurology, Chang Gung Memorial Hospital, 123 Ta Pei Road, Niao Sung Hsiang, Kaohsiung 833, Taiwan*

Received 6 February 2004; received in revised form 2 November 2004; accepted 26 November 2004

---

**Abstract**

Intracranial embolization usually arises from heart, precerebral artery or aorta but rarely the peripheral artery as retrograde upstream of embolus should be overcome. We encountered a woman who experienced a transient right arm numbness followed by a sudden onset of left hemiplegia and conscious change concurrently. Cranial computerized tomography revealed a hemorrhagic infarct at right lentiform nucleus. Angiography disclosed right axillary artery occlusion at the proximal portion without collateral circulation. Cardioaortic survey and coagulation profile were normal. Thrombectomy was done and radial flow was corrected rapidly. Post-thrombectomy heparinization did not bring complication. Therefore, a distant embolism from peripheral artery at the upper limb should be alerted for cerebral ischemia. A lower density of embolus and no-flow condition in her occluded axillary artery may facilitate the upstream embolization. Heparinization, under closed monitor, is not contraindicated for preventing restenosis after thrombectomy in case of hemorrhagic transformation in brain.

© 2004 Published by Elsevier B.V.

*Keywords:* Cerebral ischemia; Axillary artery; Embolization; Heparinization; Thrombectomy

---

**1. Introduction**

Intracranial embolization, in single or multiple, is not uncommon in cerebral ischemia. The sources usually come from cardiac embolus [1,2], carotid plaque, aortic arch atherosclerosis [3] or vertebral artery disease. A vasculopathic occlusion of peripheral artery is barely mentioned to associate with a concurrent intracranial embolization in literature. We encountered a woman who had concurrent right axillary artery occlusion and homolateral cerebral ischemia. This patient reminds the peripheral artery being a probable embolic source in the development of cerebral ischemia.

**2. Case report**

A 90-year-old woman had hypertension known for three years. On the morning of January 8, 2003 when she was

taking her breakfast, she experienced a numb and tingling sensation on her right hand. While she attempted to stand up from her chair, a few minutes later, she found left side weakness and then fell down on the ground from chair. Slurred speech and no movement of left side limbs were noted. She was sent to our hospital within 6 h. Preceding infection, recent craniofacial trauma, migraine, focal reversible neurological deficit, vigorous emotionism or illicit drug usage was denied by her.

On admission, blood pressure and pulse rate were 180/110 mmHg and 77 beats/min of the left arm but were hardly detected on the right side. Respiratory rate was 14 breaths/min and body temperature was 36.5 °C. She was oriented but lethargic. The right hand was cold and pale. Abnormal neurological signs were conjugated eyes tonic gazing to right side, dysarthria, dysphagia, and hemiplegia, hyper-reflexia, Babinski's sign and hypesthesia to pain at the left side. Middle cerebral artery syndrome was interpreted initially. Cranial computerized tomography revealed an obscuration at right corona radiata, caudate nucleus and putamen at 7 h after onset (Fig. 1A). Chest X-ray disclosed

---

\* Corresponding author. Tel.: +886 7 731 7123x3399;  
fax: +886 7 311 2516.

E-mail address: josefliu@ms15.hinet.net (J.-S. Liu).

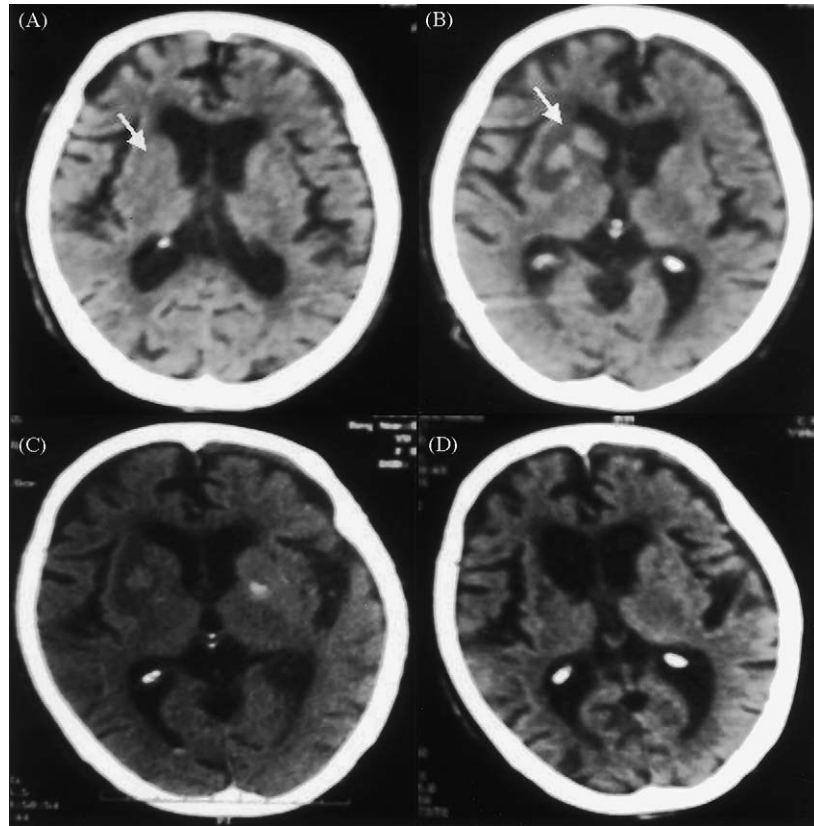


Fig. 1. An obscuration (arrow) was found at right caudate, putamen and corona radiata 7 h after onset (A), and it turned to hyperdense with perifocal edema and anterior horn compression (arrow) at 48 h later after onset (B). Hyperperfusion was considered. The perifocal edema and hyperperfusion were less severe seven days later (C). Three months after onset, infarct was resorbed (D), in association with brain degeneration and an enlargement of right anterior horn.

no active cardiopulmonary disease. Transthoracic cardiac echogram showed a hypertrophy of left ventricle and septum, but the ejection fraction and valvular movement were normal. Transesophageal cardiac echogram did not reveal patent foramen ovale or aortic arch atherosclerosis. Renal echogram did not disclose vascular stenosis. The 24-h holter analyzer showed sinus rhythm without dysrhythmia. Transfemoral arteriogram revealed a complete occlusion at the proximal portion of right axillary artery without collateral circulation (Fig. 2). No occlusion was seen in intracranial arteries (Fig. 2B and C). The luminal wall of aorta, extracranial carotid artery, subclavian and vertebral artery were not narrow. Transcranial doppler did not find an increase of systolic velocity or pulsative index in intracranial arteries.

Stroke risk factor survey [4,5] was performed, including biochemistry, hematology, serology, coagulation profile, lupus study, immunology and infection index. They were within reference range except a 2-fold increase of Venereal Disease Research Laboratory and 640-fold increase of *Treponema pallidum* hemoagglutination test. The protein C, protein S, antithrombin III, lupus anticoagulant and anti-beta2-glycoprotein I antibody were normal. Erythrocyte sedimentation rate was 12 mm. Cancer markers, including

CEA,  $\alpha$ -fetoprotein, CA-125, CA-199 and tissue polypeptide antigen, did not increase. Cerebrospinal fluid analysis showed total proteins to be 45 mg%, glucose 58 mg%, cytology 1 lymphocyte/ml, lactate 11.8 mg%, Link IgG index 0.23, and a negative Venereal Disease Research Laboratory and *Treponema pallidum* hemoagglutination test. These laboratory tests indicated an inactive syphilis and did not support coagulopathy.

Emergent thrombectomy was done immediately and heparin was given 1000 units/h intravenously for prophylaxis. Clinical sign for bleeding and activated partial thromboplastin time were carefully monitored. Radial pulse was detected at right hand rapidly after thrombectomy. The pathology of the thrombus contained fibrin, blood clots and arterial tissue, suggesting probably dissecting disease. The course of hospitalization was uneventful and she discharged with a residual left hemiparesis. The obscuration in cranial computer tomography became hyperdense suggesting hyperperfusion at 48 h (Fig. 1B). Perifocal edema was seen and the anterior horn was compressed. An improvement of perifocal edema was seen at seven days after onset (Fig. 1C). Three months later, a resorption of the infarct was noted (Fig. 1D). A repeated holter analyzer showed sinus rhythm and no atrial fibrillation six months later.

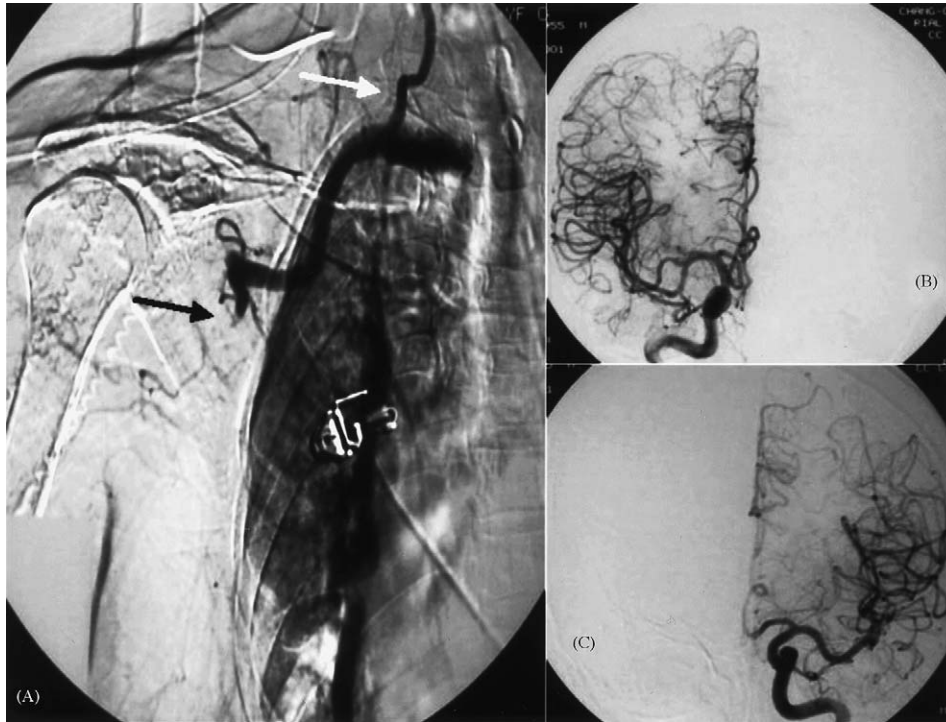


Fig. 2. Conventional angiography showed a complete occlusion of right axillary artery at thoracoacromial level (thick white arrow). A stump was seen at the occlusive site (A). Pathology showed fibrin, blood clots and arterial tissues suggesting dissecting disease. The vertebral artery (thin white arrow) and internal mammary artery were patent. There was no luminal occlusion at extracranial or intracranial carotid artery (B and C).

### 3. Discussion

Although cardiac holter has been done twice and shown not to have significant dysrhythmia in this patient, some cardioelectric disorders, such as paroxysmal atrial fibrillation, should be kept in mind due to a high unpredictability of time onset in attack and frequency in multiple embolizations.

It is extremely unusual for a concurrent occlusion of cerebral and peripheral artery arising from an embolic source other from heart, precerebral artery or aorta. We think that this uncommon concurrence does not really represent a low frequency of embolic source from the peripheral artery in cerebral ischemia in that its etiology is still unknown in over 30% of patients. Paucisymptomatology or rapid recanalization of peripheral artery occlusion may hamper the alertness in clinician or patient. In the light of an underestimation of cerebral embolization from aortic plaque in prior [2,8], we suggest that an investigation of embolic source from peripheral artery may aid for understanding the cause of cerebral ischemia, especially in whom there is a high risk of dissecting or atherogenic disease of peripheral artery.

Coagulopathy is another important cause for concurrent multiple arterial thrombosis. A concomitant nephrotic syndrome, low antithrombin III level and concurrent cerebral and femoral artery occlusion has been reported [6,7]. Indeed, a broad spectrum of coagulation disorders is seen in nephrotic syndrome and generally accepted for a tight relation with systemic thrombosis [9]. However, not all coagulation disorders

give rise to cerebral thrombosis, such as antithrombin III usually decreases in patients with nephrotic syndrome but is not a potent risk factor for cerebral ischemia [10]. In our patient, we are unable to identify any coagulopathy. One possibility is that the coagulation tests we perform are not enough or her coagulopathy is transient and recovers already before investigation.

Amar et al. [11] have reported three patients to have vertebrobasilar insufficiency rapidly after brachial or subclavian artery intervention. They propose a vascular compromise from propagative thrombosis, embolization, dissection, inappropriate ligation, excessive head rotation, hypotension, vasospasm or acute subclavian steal responsible for their ischemia. An embolization upstream has also been mentioned in this circumstance [12]. A traumatic vascular injury may potentiate procoagulation and elicit thrombosis, such as in early rethrombosis of coronary artery after recanalization. Thrombogenesis may result from: (1) a release of thromboplastin into the circulation; (2) an exposure of subintimal collagen; or (3) an activation of inflammatory proteins or platelets. Therefore, an injury of her axillary artery may induce embolization or procoagulation and that subsequently causes occlusion of her right brain. The proximity of upper limb and neck promises an easy access of embolization from axillary to carotid artery in our patient.

Obviously, one problem is how the thrombus upstreams against the arterial pressure in our patient. There is no answer in previous studies. We would like to introduce our thinking

herein. Generally, the blood density is  $1.04 \text{ g/cm}^3$  and determined by the hematocrit, hemoglobin and iron content. A thrombus rich in fibrin, platelet or lipid, such as our patient, may have a lower density and therefore, facilitates for upstream embolization. The no-flow condition in occluded artery further promotes the upstream expeditiously.

Thrombectomy rapidly corrects the radial blood flow in our patient. Heparin is usually employed for preventing restenosis after operation. Since our patient suffers hemorrhagic transformation, prophylactic heparinization is hesitated at that moment. Fortunately, there is no complication under careful monitor. Accordingly, heparinization may not be absolutely contraindicated for post-thrombectomy prophylaxis in case of hemorrhagic transformation in brain.

This patient reminds that: (1) an embolization upstream or procoagulation from peripheral artery thrombosis possibly contributes to cerebral artery occlusion and (2) heparinization is not absolutely contraindicated for post-thrombectomy prophylaxis.

## References

- [1] Kanemitsu S, Takao M, Fujinaga K, et al. A case of surgically treated left atrial myxoma following acute multiple embolism including cerebral embolism [Jpn]. *Kyobu Geka* 2001;54:147–50.
- [2] Islam MA, Khalighi K, Goldstein JE, Raso J. Paradoxical embolism—report of a case involving four organ systems. *J Emerg Med* 2000;19:31–4.
- [3] Morau D, Barthelet Y, Spilmann E, Ryckwaert Y, d'Athis F. Thrombus of the aortic arch: an unusual pathology in intensive care [Fre]. *Ann Fr Anesth Reanim* 2000;19:603–6.
- [4] Chen WH, Kao YF, Lan MY, Chang YY, Liu JS. A perturbation of antithrombin III and protein coupling associates with an increase of anti-beta2-glycoprotein I antibody in non-APS cerebral ischemia. *Blood Coagul Fibrinolysis* 2002;13:703–9.
- [5] Chen WH. Anti-beta2-glycoprotein I antibody and hypertension in cerebral ischemia. *Clin Appl Thromb Hemost* 2004;10:55–60.
- [6] Lee CH, Chen KS, Tsai FC, Chien YY, Lee N. Concurrent thrombosis of cerebral and femoral arteries in a patient with nephrotic syndrome. *Am J Nephrol* 2000;20:483–6.
- [7] Parag KB, Somers SR, Seedat YK, Byrne S, Da Cruz CM, Kenoyer G. Arterial thrombosis in nephrotic syndrome. *Am J Kidney Dis* 1990;15:176–7.
- [8] Accadia M, Ascione L, Tartaglia PF, et al. Aortic atheroma. An unknown source of ischemic stroke. *Minerva Cardioangiol* 2002;50:53–61.
- [9] Rabelink TJ, Zwaginga JJ, Koomans HA, Sixma JJ. Thrombosis and hemostasis in renal disease. *Kidney Int* 1994;46:287–96.
- [10] Chen WH, Lan MY, Chang YY, Chen SS, Liu JS. The prevalence of protein C, protein S and antithrombin III deficiency in non-APS/SLE Chinese adults with noncardiac cerebral ischemia. *Clin Appl Thromb Hemost* 2003;9:155–62.
- [11] Amar AP, Levy ML, Giannotta SL. Iatrogenic vertebrobasilar insufficiency after surgery of the subclavian or brachial artery: review of three cases. *Neurosurgery* 1998;43:1450–7.
- [12] Carney AL. Vertebral artery surgery: historical development, basic concepts of brain hemodynamics, and clinical experience of 102 cases. In: Carney AL, Anderson EM, editors. *Advances in neurology: diagnosis and treatment of brain ischemia*, vol. 30. New York: Raven Press; 1981. p. 249–82.