



ELSEVIER

Available online at [www.sciencedirect.com](http://www.sciencedirect.com)



ScienceDirect

Archives of Gerontology and Geriatrics 43 (2006) 223–232

ARCHIVES OF  
GERONTOLOGY  
AND GERIATRICS

[www.elsevier.com/locate/archger](http://www.elsevier.com/locate/archger)

## Secondary mania of vascular origin in elderly patients: A report of two clinical cases

Nages Nagaratnam<sup>\*</sup>, Ka-Kit Wong, Ilesh Patel

*Department of Medicine, Aged Care and Rehabilitation Services, Blacktown-Mount Druitt Health,  
Blacktown, NSW 2148, Australia*

Received 18 May 2005; received in revised form 30 September 2005; accepted 18 October 2005  
Available online 7 December 2005

### Abstract

The concept of secondary mania continues to be debated together with unresolved or partially resolved issues such as lateralization, localization, age of onset, disinhibition syndromes, and others. We have described two patients with secondary mania following a stroke. One had a large left hemisphere cerebral infarction and the symptoms arose about 2.5 years later, possibly triggered by a transient ischemic attack involving the right hemisphere. The other had an infarction in the right posterior artery territory extending to the thalamus and internal capsule together with infarctions in the deep border zones of both hemispheres at the level of the centrum semiovale with the manic symptoms concomitant with the onset of the event. The clinical and neuro-anatomic mechanisms that underlie the diverse locations of secondary mania are discussed. The cerebral components of secondary mania and disinhibition syndromes are very similar and it is proposed that disinhibition syndromes, secondary hypomania and secondary mania with and without psychotic symptoms are simply a continuum of severity of mood disorder and secondary mania with psychotic symptoms may be an extreme form. The concept of secondary mania in the elderly is not likely to disappear although several unresolved issues remain. For the neurophysician, geriatrician, and the psychiatrist there is much to be attained by simplifying the issues and accepting the view that secondary mania is a discrete entity.

© 2005 Elsevier Ireland Ltd. All rights reserved.

**Keywords:** Mania in old age; Secondary mania; Frontal-subcortical circuitry; Limbic system; Disinhibition syndromes; Lateralization

<sup>\*</sup> Corresponding author at: 20, Panaview Crescent, North Rocks, NSW, Australia. Tel.: +61 2 9872 1997; fax: +61 2 9872 1997.

E-mail address: [nage@mail2me.com.au](mailto:nage@mail2me.com.au) (N. Nagaratnam).

## 1. Introduction

Mania in old age has been comprehensively reviewed (Krauthammer and Klerman, 1978; Starkstein et al., 1988; Fujikawa et al., 1995; Shulman and Herrmann, 1999) but despite difficulties in the diagnosis and classification (Shulman, 2004) interest in it continues to grow. There remain unresolved issues such as whether “secondary” mania is a definite entity, the age of onset, lateralization (Liu et al., 1996; Fenn and George, 1999), localization, and mania subtypes amongst others. The term “manic syndromes” in old age has its critics because of the high occurrence of medical and neurological conditions in old people compared with the overall low incidence of late-onset mania. There were only three cases of post-stroke mania among 700 stroke patients (Starkstein et al., 1988). Establishing a causal relationship between manic symptoms and a specific medical condition can be difficult as to whether it is the cause or merely a precipitant. Neurological lesions are commonly associated with symptoms that may be diagnosed or labeled as psychiatric. Most of the early cases of secondary mania were associated with a lesion in the non-dominant hemisphere (Robinson et al., 1988). There had been, however, an increasing number of reports of secondary mania where the dominant left hemisphere in right-handed people is involved (Liu et al., 1996; Fenn and George, 1999).

We report two patients with secondary mania following cerebral vascular lesions, which highlight some of the issues in question. This succinct review emphasizes the conceptual shifts and information that have guided our contemporary view of mania in old age.

## 2. Subjects and methods

This is a retrospective study of two patients with secondary mania following stroke. Both were referred to the geriatrician because of their behavior. Both patients fulfilled the DSM-III-R criteria for mania (American Psychiatric Association, 1987) as determined by a clinical review. This broadly includes elevated mood, flight of ideas, rapid pressured speech, impaired judgment, and decreased sleep amongst others. The inclusion criteria for secondary mania were the satisfaction of the criteria of Krauthammer and Klerman (1978), namely, the presence of elevated or irritable mood together with at least two of the symptoms in the diagnosis of mania; symptoms duration of at least 1 week and no history of affective disorder and confusion. Mania was subdivided into manic episode, hypomania, mania with psychotic symptoms (hallucinations or delusions both mood congruent), and hypomania causing marked functional impairment but with no psychotic symptoms (Treatment Protocol Project, 1997). Bipolar disorder was characterized by episodes of mania and depression that can last from days to months. Routine laboratory investigations with a computed tomography (CT) scan of the brain had been done in both cases.

## 3. Results

### 3.1. Illustrative cases

A 72-year-old right-handed housewife presented with symptoms of elevated mood and disinhibition with a past history of an embolic cerebral artery infarction in the

territory of the left middle cerebral artery 3 years earlier. The family had noticed a gradual change in her mental state and was having difficulties coping with her disruptive behavior. She had no previous history of mental illness and prior to the stroke she had been in good health apart from hypertension and dyslipidemia.

Three years ago she had presented with isolated global dysphasia without hemiparesis. She was unable to understand and could not answer simple questions. A CT of the brain at the time revealed a hypodense area in the left insular region and parietal lobe consistent with recent infarction in the middle cerebral artery territory. As she was in atrial fibrillation, this incident was presumed to be cardio-embolic in origin and she was anticoagulated. The echocardiography demonstrated normal left ventricular size and function with no evidence of mural thrombus. The carotid Doppler revealed no significant disease. She had markedly elevated serum cholesterol. She recovered over the next 10 days and was discharged with mild reduction in her speech fluency. Although her comprehension appeared normal, difficulties still existed with word-finding as well as in writing both spontaneous and in response to dictation.

She was next seen about 2.5 years later after the initial event complaining of fatigue and discomfort in her left arm. She had been reasonably well but for an episode 4 months earlier when it was noticed that she was pale, vague and complained of a feeling of numbness of her left arm. CT scan of the brain had shown no new changes and neurological examination had revealed neither focal nor lateralizing signs and she recovered within a day. It was about this time that her family first began to notice subtle changes in her behavior. During this visit it was reported that she had fluctuations in her mood ranging from apathy to elation. She had been sleeping poorly and occasionally exhibited irritability, which was not a feature of her premorbid personality. Pressured speech was noted with normal comprehension. Cognitive testing using Mini-Mental State Examination (MMSE) (Folstein et al., 1975) revealed a score of 25/30.

A year later her condition had worsened and the main problems appeared to be related to changes in her behavior and mood. She was able to perform all activities of daily living but was found to be impulsive and stubborn with pressured speech and incoherency as well as aimless wandering with annoying behavior and resistant to suggestions. Her mood fluctuated from low flat to one of elation. Neurological examination was unremarkable. Her symptoms were suggestive of hypomania.

Four months later her condition continued to worsen with deterioration in her ability to care for herself. She was found to be unkempt and untidy with reports of wearing the same soiled clothes repeatedly and poor personal hygiene. She was often agitated and verbally aggressive at times. When seen for review she was found to be extremely cheerful to the point of euphoria with overtalkativeness and pressured speech. Her stream of thought was rapid with flight of ideas. The MMSE once again revealed a score of 25/30 part of which may have been due to residual language difficulties following her initial stroke. Repeated CT scan of the brain showed the same hypodense area in the left frontoparietal area with negative mass effect and ex-vacuo dilatation of the ventricular system (Fig. 1a and b). She was commenced on an atypical antipsychotic olanzapine and subsequently referred to a psychiatrist.

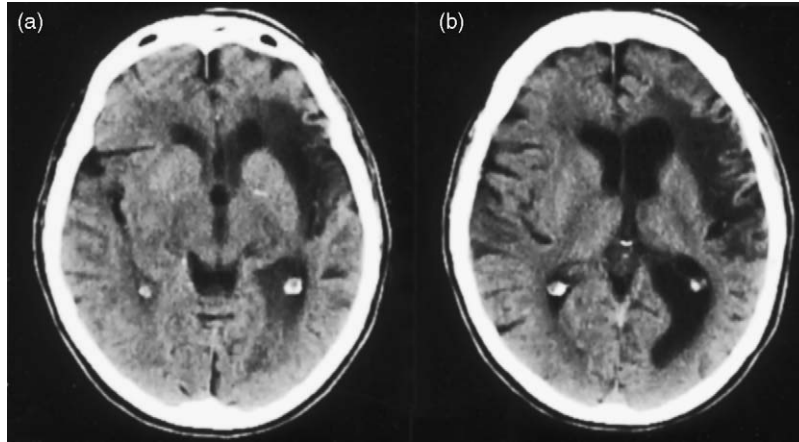


Fig. 1. (a) CT scan of the brain showing an infarction in the territory of the left middle cerebral artery involving the frontal insula cortex and parietal regions. (b) CT scan showing ex-vacuo dilatation of the ventricles in the left hemisphere secondary to long standing infarction.

A right-handed 80-year-old man was seen because of his behavior. His background included hypertension and ischemic heart disease (triple vessel disease with normal ventricular function) over 10 years culminating in coronary artery bypass grafting. Perioperatively he had suffered a cerebrovascular accident.

He was a lifelong non-smoker and a non-drinker. He had no allergies and was not a diabetic and had normal blood cholesterol levels. He had no history of mental illness or earlier stroke. Family history was positive for heart disease but negative for psychiatric or dementing illnesses.

He had a left-sided weakness, a left homonymous hemianopia, and significant left-sided neglect. His moods ranged from one of amiability to frank hostility. He struck out at the nurses. He had visual hallucinations (seeing spiders and skinned chickens hanging on the wall). He screamed loudly day and night and slept poorly and was demanding. His memory for recent and past events was normal. He displayed verbal hyperactivity and pressured speech. He was agitated, verbally aggressive and had no insight into his behavior. He was impulsive and demonstrated emotional lability. Subsequently, he had post-stroke central pain and post-stroke seizures. He had been treated with antidepressants, antipsychotics, anti-epileptics, and benzodiazepines and the medications included risperidone, haloperidol, thioridazine, clonazepam, temazepam, diazepam, and phenytoin with varying effect.

CT scan of the brain showed a large infarction in the right posterior cerebral artery territory extending from the occipital lobe to the thalamus and the genu of the internal capsule (Fig. 2a). There were other cerebral infarcts (i) in the anterior deep border zone in the right hemisphere and (ii) a small hypodense area in the anterior deep border zone in the left hemisphere both at the level of the centrum semiovale (Fig. 2b), both due to hemodynamic compromise during surgery.

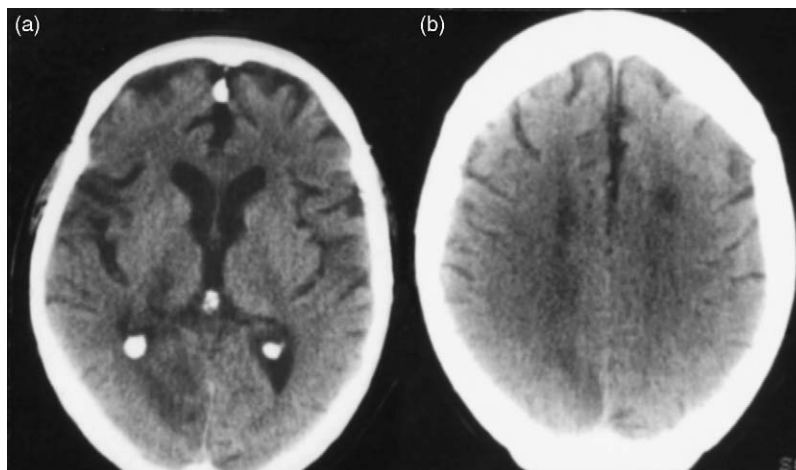


Fig. 2. (a) CT scan of the brain showing a large infarction in the territory of the right posterior cerebral artery involving the right occipital lobe and extending to the thalamus and genu of the internal capsule. (b) CT scan of the brain showing deep border zone infarcts in the right hemisphere and a smaller one in the left.

#### 4. Discussion

Shulman and Herrmann (1999) indicated three broad groups of manic syndromes in old age, namely (i) middle-age-onset depressives who after a latency of several years convert to bipolarity; (ii) mixed-aged bipolar patients; and (iii) late-onset mania (LOM) in association with a heterogeneous group of neurological disorders. Both patients in this study satisfied the criteria for secondary mania after Krauthammer and Klerman (1978). Several neurological conditions have been correlated with secondary mania. There is now a growing awareness of the influence of vascular-based LOM lending support to LOM as a distinct vascular subtype. The “vascular syndromes” are the most distinctive and can be caused by cerebral infarction (including silent cerebral infarction (SCI)), transient ischemic attack (TIA), and small vessel disease. In general 30–50% of stroke patients develop major and minor depressive disorders (Starkstein and Robinson, 1989). Fujikawa et al. (1993) studied the incidence of SCI in patients with major depression and found half the cases of late-onset mania to be secondary mania related to SCI and often associated with larger areas of brain damage as compared with late-onset depression (Fujikawa et al., 1995).

Cassidy and Carroll (2002) have recently focused on vascular factors in secondary mania and published a retrospective review of 366 bipolar patients, in particular looking at the age of onset and histories of vascular disease and risks including cholesterol levels. They noted a bipolar distribution in first age of onset for mania with an intermode of age 47. Using this age as a cut-off early onset mania comprised of 93.7% of the group whereas LOM (age > 47 years) made up 6.3%. This cut-off age also agreed with that proposed by Krishnan et al. (1997) for late mania with onset age >50 years. This bimodal distribution provides further evidence that secondary mania is a distinct clinical entity.

With post-stroke mania the strongest association is with lesions in the right hemisphere. Major depression is said to be more frequent with left anterior lesions (frontal or basal ganglia), whereas minor depression occurs with either right or left parietal-occipital lesions (Starkstein and Robinson, 1989). Post-stroke mania, however, is associated with right hemispheric lesions, which have connections with the frontal lobes (Starkstein and Robinson, 1989). But others (House et al., 1990; De Haan et al., 1995) found no difference between right and left hemispheric stroke in the association between mood symptoms and lesion location. There are also a growing number of reports of secondary mania following left hemispheric stroke (Herlihy and Herlihy, 1979; Jampala and Abrams, 1983; Starkstein et al., 1988; Turecki et al., 1993; Lui et al., 1996; Fenn and George, 1999). Case 1 in this study demonstrated mania following a dominant hemispheric infarct as evidenced by the global dysphasia she displayed at the time of her stroke.

Among reported cases mania may occur concomitantly with the stroke as in Case 2 or may be delayed for up to 2 years (Starkstein et al., 1988) or even up to 3–5 years or more (Oyewumi and Lapierre, 1981; Shukla et al., 1987). In Case 1 there appeared to be an interval of at least 2.5 years after the initial insult, but it is possible that the symptoms of mania emerged after the possible transient ischemic attack. It is known that patients with clinically silent unilateral subcortical lesions may develop neurobehavioral deficits after suffering a new, often contralateral lesion (Gold et al., 1997). A lesion may not be able to produce secondary mania by itself but may predispose to activation of secondary mania after a second lesion, or a stressful life event. Thus, it is possible that both hemispheres contributed to the emergence of mania in Case 1. Case 2 had bihemispheric lesions but the one on the right involving the territory of the posterior cerebral artery was the largest.

Case 2 had visual hallucinations and also a left-sided hemianopia and very often in patients a causal relationship between visual hallucinations and visual field defects had been recognized. The right hemisphere is said to have a certain degree of predominance in this occurrence (Lhermitte, 1983). Kolmel (1985), however, did not find any predilection of one hemisphere for patients with complex visual hallucinations experienced in the hemianopic field. Peduncular hallucinosis characterized by visual hallucinations of brightly colored objects arising from posterior cerebral artery occlusion but the exact location of the lesion remains unclear. The former seem to be a more likely explanation and it is unlikely that it is related to the mania.

The lesions in secondary mania following stroke are in the limbic or limbic-connected areas (orbito-frontal, basotemporal cortex, head of caudate and thalamus), but secondary mania has been reported after ventral pontine infarction in two patients involving the left side in one and the right in the other (Drake et al., 1990). Cummings (1985) reviewed reported cases and noted that mania was similar to orbito-frontal syndrome and could be caused by lesions in the thalamus or orbito-frontal regions. Starkstein et al. (1991) found that the main areas involved were the limbic or limbic-related areas, right orbito-frontal, basotemporal, and basal ganglia regions all of which have frontal connections. Bogousslavsky et al. (1988) suggested that a manic-like syndrome could be produced by a thalamic lesion causing an ipsilateral frontal dysfunction via deafferentation. This dysfunction manifested as hypoperfusion of the frontal lobe imaged by cerebral SPECT. Case 2 in this study had involvement of the thalamus and the genu of the internal capsule



resulting from a posterior cerebral artery territory infarct. The polar region and the paramedian territory are massively connected to the frontal structures. A capsular genu infarct could interrupt the inferior and anterior thalamic peduncles resulting in functional deactivation of the ipsilateral frontal cortex (Tatemichi et al., 1992). All the lesions were located in the right hemisphere.

The lesions that have been described with mania following left hemispheric stroke were in the fronto-temporal, frontal, temporal, and basal ganglia regions (Turecki et al., 1993). Starkstein et al. (1991) indicated that patients with right subcortical lesions tend to develop bipolar disorder whilst right cortical lesions tend to develop unipolar mania. Turecki et al. (1993) described a patient with bipolar disorder following a left basal ganglia infarction and Liu et al. (1996) a left temporal infarction. It is well known that the left medial thalamus and paramedian territory (Sandson et al., 1991; Nagaratnam et al., 1999) and left polar thalamic regions (Clarke et al., 1994) are massively connected to the frontal structures and that their damage may result in frontal lobe dysfunction.

Attention has been drawn to the clear resemblance of mania to the disinhibition syndrome (Shulman, 2004). Lesions in specific brain areas could give rise to disinhibition syndromes ranging from inappropriate social behavior or full blown mania and a significant association between disinhibition syndromes and dysfunction of the orbito-frontal and basotemporal cortices of the right hemisphere had been demonstrated (Starkstein and Robinson, 1997). Nearly all lesions producing disinhibition syndromes and secondary mania have involved the right hemisphere (Steffens and Krishnan, 1998). In two studies of five and six patients, respectively, with sexually-related behaviors (Nagaratnam et al., 1998a; Nagaratnam and Gayagay, 2002) following stroke, all had two or more of the core features of mania, namely, elated mood, aggression, irritability and hostility, decreased sleep, impulsive behavior, overtalkativeness, restlessness, and increased activity, increased sexual activity, and activity with poor attention. Their ages ranged from 54 to 91 years with a mean of 73 years. All were males but one. The lesions were located in the left putamen (2), right parieto-temporal (2), right parietal (1); right thalamus (1), left orbito-frontal (2), left dorso-lateral (1), left mesencephalo-thalamic (1), and bilateral lesions in one, with right posterior cerebral artery territory infarction and left middle cerebral artery infarction. The cerebral components of secondary mania and disinhibition syndromes are, thus, very similar.

Alexander et al. (1986) proposed five segregated circuits and each circuit linked the striatum, globus pallidus, substantia nigra, and the thalamus with topographically organized divisions of the frontal cortex. Involvement of the orbitofrontal circuit gives rise to tactlessness, disinhibition, and impulsivity. A relationship between basal ganglia and the frontal cortical areas was proposed by De Long and Georgepolous (1979) through a concept of “motor” and “complex” loops. Several functions mediated by both hemispheres interact with the limbic system. The limbic system has dense projections to the basal ganglia creating an integrated limbic-cortical system that mediates mood, motivation, and motion (Nauta, 1982). The limbic system particularly the amygdala, hypothalamus, septum, and mesencephalon together with the reticular formation with frontal cortical interaction control a person’s emotional behavior (Nauta, 1982). It is well accepted that the limbic system and the temporal lobe are closely related to a number of psychological syndromes. Secondary mania occurs with lesions affecting the orbitofrontal-subcortical circuit (Cummings and Mendez, 1984; Starkstein et al., 1987). Lesions of the temporobasal regions including the amygdala and

temporal stem also produce mania. It could be asked how similar neuroanatomical changes could give rise to syndromes whose features are not uniform. According to Cummings (1985), the occurrence of different psychological syndromes could be influenced by several factors such as genetic constitution, age of onset, personality characteristics, early life experiences, and exact location and extent of the lesion amongst others. Subcortical lesions involving the thalamus and the caudate tend to produce a bipolar type of mood disorder whereas lesions of the cortex produce mania and are not followed by a cyclic mood disorder (Starkstein et al., 1991).

Several transmitters and modulators are involved in the fronto-subcortical circuits. It has been postulated that the mechanism by which these lesions give rise to an affective disorder is due to functional excess of neurotransmitters including dopamine and noradrenaline rather than the direct anatomical damage caused by the lesions. It is well known that several transmitters contribute to the efficiency of a specific brain area and it seems that there may be more than one transmitter involved with many cases of secondary mania. This may be the reason why there is no single effective therapeutic agent.

Overall the character of the symptoms is better defined by the location rather than the particular neurotransmitter. For instance, left anterior lesions (frontal, basal ganglia) give rise to major depression whereas minor depression occurs with right or left parieto-occipital lesions (Fenn and George, 1999), obsessive-compulsive behaviors with bilateral basal ganglia (Laplane et al., 1989), and pathological crying and laughing with bi-hemispheric or other lesions (Nagaratnam et al., 1998b). In secondary mania there is a strong association with orbitofrontal (Cummings, 1985; Starkstein et al., 1991) basal ganglia (Fenn and George, 1999), thalamus (Bogousslavsky et al., 1988), frontotemporal, and temporal lesions (Liu et al., 1996).

In conclusion, there is substantial evidence to emphasize that secondary mania is a distinct clinical entity. The current state of our knowledge has created a certain stability on the consensus that the concept of secondary mania is well founded. Although nearly all lesions producing secondary mania and disinhibition syndromes involved the right cerebral hemisphere they can also be produced by left hemispheric lesions. The cerebral components of secondary mania and disinhibition syndromes are very similar and it is proposed that disinhibition syndromes, secondary hypomania, and secondary mania with psychotic symptoms are simply a continuum of severity of mood disorder and secondary mania may be an extreme form. Lesion location appears to play a critical role in the development of secondary mania and disinhibition syndromes.

## References

- Alexander, G.E., De, Long., Strick, P.L., 1986. Parallel organization of functionally segregated circuits linking basal ganglia and cortex. *J. Neurosci.* 9, 357–381.
- American Psychiatric Association, 1987. *Diagnostic and Statistical Manual of Mental Disorders*, third ed. (revised). American Psychiatric Association, Washington, DC.
- Bogousslavsky, J., Ferrazzini, M., Regli, F., Assal, G., Tanabe, H., Delaloye-Bischof, A.M., 1988. Manic delirium and frontal-like syndrome with paramedian infarction of the right thalamus. *J. Neurol. Neurosurg. Psychiatry* 51, 116–119.
- Cassidy, F., Carroll, B.J., 2002. Vascular risk factors in late onset mania. *Psychol. Med.* 32, 359–362.



- Clarke, S., Assal, G., Bogousslavsky, J., Regli, F., Townsend, D.W., Leenders, K.L., Blecic, S., 1994. Pure amnesia after unilateral left polar thalamic infarct. Topographic and sequential neurophysiological and metabolic (PET) correlations. *J. Neurol. Neurosurg. Psychiatry* 57, 27–34.
- Cummings, J.L., 1985. Organic delusions, phenomenology, anatomical evaluation and review. *Br. J. Psychiatry* 146, 184–197.
- Cummings, J.L., Mendez, M.F., 1984. Secondary mania with focal cerebrovascular lesions. *Am. J. Psychiatry* 141, 1084–1087.
- De Haan, R.J., Limburg, M., Van der Meulen, J.H.P., Jacobs, H.M., Aaronson, N.K., 1995. Quality of life after stroke: impact of stroke type and lesion location. *Stroke* 26, 402–408.
- De Long, H.R., Georgepolous, A.P., 1979. Motor functions of the basal ganglia as revealed by studies of single cell activity in the behaving primate. *Arch. Neurol.* 24, 131–140.
- Drake Jr., M.E., Pakalnis, A., Phillips, B., 1990. Secondary mania after ventral pontine infarction. *J. Neuropsychiatry Clin. Neurosci.* 2, 322–325.
- Fenn, D., George, K., 1999. Post-stroke mania late in life involving the left hemisphere. *Aust. N.Z. J. Psychiatry* 33, 598–600.
- Folstein, H.Y., Folstein, E.E., McHugh, P.P., 1975. Mini-Mental State: a practical method of grading the cognitive state of patients for the clinician. *J. Psychiatr. Res.* 12, 189–198.
- Fujikawa, T., Yamawaki, S., Touhoda, Y., 1993. Incidence of silent cerebral infarction in patients with major depression. *Stroke* 24, 1631–1634.
- Fujikawa, T., Yamawaki, S., Touhoda, Y., 1995. Silent cerebral infarctions in patients with late-onset mania. *Stroke* 26, 946–949.
- Gold, M., Nadeau, S.E., Jacobs, D.H., Adair, J.C., Rothi, L.J., Heilman, K.M., 1997. Adynamic aphasia: a transcortical motor aphasia with defective semantic strategy formation. *Brain Lang.* 57, 374–393.
- Herlihy Jr., C.E., Herlihy, C.E., 1979. Lithium and organic brain syndrome. *J. Clin. Psychiatry* 40, 455 (Letter to the Editor).
- House, A., Dennis, M., Warlow, C., Hawton, K., Molneux, A., 1990. Mood disorders after stroke and their relation to lesion location: a CT scan study. *Brain* 113, 1113–1129.
- Jampala, V.C., Abrams, R., 1983. Mania secondary to left and right hemispheric damage. *Am. J. Psychiatry* 140, 1197–1199.
- Kolmel, H.W., 1985. Complex visual hallucinations in the hemianopic field. *J. Neurol. Neurosurg. Psychiatry* 48, 21–38.
- Krauthammer, C., Klerman, G.L., 1978. Manic syndromes associated with antecedent physical illness or drugs. *Arch. Gen. Psychiatry* 35, 1333–1339.
- Krishnan, K.R.R., Hars, J.C., Blazer, D.G., 1997. MRI-defined vascular depression. *Am. J. Psychiatry* 154, 497–501.
- Laplane, D., Levasseur, M., Pillon, B., Dubois, B., Baulac, M., Mazoyer, B., Tran Dinh, S., Sette, G., Danze, F., Baron, J.C., 1989. Obsessive-compulsive and other behavioral changes with bilateral basal ganglia lesions. A neuropsychological, magnetic resonance imaging and positron tomography study. *Brain* 112, 699–725.
- Lhermitte, F., 1983. Utilization behavior and its relation to lesions of the frontal lobe. *Brain* 6, 237–255.
- Liu, C.Y., Wang, S.J., Fuh, J.L., Yang, Y.Y., Liu, H.C., 1996. Bipolar disorder following a stroke involving the left hemisphere. *Aust. N.Z. J. Psychiatry* 30, 688–691.
- Nagaratnam, N., Gayagay, G., 2002. Hypersexuality in nursing care facilities—a descriptive study. *Arch. Gerontol. Geriatr.* 35, 195–203.
- Nagaratnam, N., Tse, A., Lim, R., Chowdhury, M., 1998a. Aberrant sexual behavior following stroke. *Eur. J. Int. Med.* 9, 207–209.
- Nagaratnam, N., Wong, V., Jeyaratnam, D., 1998b. Left anterior choroidal artery infarction and uncontrollable crying. *J. Stroke Cerebrovasc. Dis.* 7, 263–264.
- Nagaratnam, N., McNeill, C., Gilhotra, J.S., 1999. Akinetic mutism and mixed transcortical aphasia following infarction of the left sided medial thalamus. *J. Neurol. Sci.* 163, 70–73.
- Nauta, W.J.H., 1982. Limbic innervation of striatum. In: Friedhoff, A.J., Chase, T.N. (Eds.), *Gilles de la Tourette Syndrome*. Raven Press, New York, pp. 41–48.
- Oyewumi, I.K., Lapierre, Y.D., 1981. Efficacy of lithium in treating mood disorder occurring after brain stem injury. *Am. J. Psychiatry* 138, 110–121.

- Robinson, R.G., Boston, J.D., Starkstein, S.E., Price, T.C., 1988. Comparison of mania and depression after brain injury: casual factors. *Am. J. Psychiatry* 145, 172–178.
- Sandson, T.A., Daffner, K.R., Carvalho, P.A., Mesulam, M., 1991. Frontal lobe dysfunction following infarction of the left-sided medial thalamus. *Arch. Neurol.* 48, 1300–1303.
- Shukla, S., Cook, B.L., Mukerjee, S., Goodwin, C., Miller, M.G., 1987. Mania following head trauma. *Am. J. Psychiatry* 144, 93–96.
- Shulman, K.I., 2004. Mania in old age: a neuropsychiatric syndrome. *Geriatrics Aging* 7, 34–37.
- Shulman, K.L., Herrmann, N., 1999. The nature and management of mania in old age. *Psychiatr. Clin. N. Am.* 22, 649–663.
- Starkstein, S.E., Robinson, E.R., 1989. Affective disorders in cerebrovascular disease. *Br. J. Psychiatry* 154, 170–182.
- Starkstein, S.E., Robinson, R.G., 1997. Mechanism of disinhibition after brain lesions. *J. Nerv. Ment. Dis.* 185, 108–114.
- Starkstein, S.E., Pearlson, G.B., Bosh, J., Robinson, R.G., 1987. Mania after brain injury: controlled study of causative factors. *Arch. Neurol.* 44, 1064–1073.
- Starkstein, S.E., Boston, J.D., Robinson, R.G., 1988. Mechanisms of mania after brain injury: 12 cases reports and review of the literature. *J. Nerv. Ment. Dis.* 176, 87–100.
- Starkstein, S.E., Fedoroff, P., Berthier, M.L., Robinson, R.G., 1991. Manic depressive and pure manic states after brain lesions. *Biol. Psychiatry* 29, 149–158.
- Steffens, D.C., Krishnan, K.R.R., 1998. Structural neuroimaging and mood disorders. Recent findings, implications for classification, and future directions. *Biol. Psychiatry* 43, 705–712.
- Tatemichi, T.K., Desmond, D.W., Prohovnik, I., Cross, D.T., Gropp, T.I., Mohr, J.P., Stern, Y., 1992. Confusion and memory loss from capsular genu infarction: a thalamocortical disconnection syndrome? *Neurology* 42, 1966–1979.
- Treatment Protocol Project, 1997. *Management of Mental Disorders*, vol. 1, second ed. Sydney, World Health Organisation Collaborating Centre for Mental Health and Substance Abuse, pp. 193–207.
- Turecki, G., De Mari, J., Porto, J.A.D., 1993. Bipolar disorder following a left basal ganglia stroke. *Br. J. Psychiatry* 163, 690.