

Hyperperfusion Syndrome After Stenting for Intracranial Vertebral Stenosis

Marco Túlio Rezende, MD; Laurent Spelle, MD, PhD; Charbel Mounayer, MD; Michel Piotin, MD; Daniel Giansante Abud, MD; Jacques Moret, MD

Background and Purpose—Hyperperfusion syndrome is a rare but well-described complication after endarterectomy or stenting in the carotid circulation.

Summary of Case—A 66-year-old man who had vertebrobasilar insufficiency refractory to medical treatment because of an intracranial right side vertebral stenosis was referred to our institution for endovascular treatment. Stenting was performed, and after 24 hours, he became extremely agitated, and this was followed by a period of apathy without focal neurological deficits. MRI showed bilateral thalamic hemorrhage.

Conclusion—To our knowledge, this is the first report of hyperperfusion syndrome with hemorrhagic presentation after intracranial vertebral artery stenting. (*Stroke*. 2006;37:e12-e14.)

Key Words: angioplasty ■ intracranial atherosclerosis ■ intracranial hemorrhage ■ reperfusion injury

A 66-year-old man presented with acute and recurrent episodes of diplopia and visual field defects associated with dysarthria and equilibrium disturbances. These episodes occurred while the patient was undergoing medical treatment consisting of acetylsalicylic acid (100 mg per day) and clopidogrel (75 mg per day), suggesting the diagnosis of vertebrobasilar insufficiency refractory to medical therapy. The neurological examination during the last ischemic event revealed mixed dysarthria and a cerebellar static and kinetic syndrome.

MRI demonstrated left occipital and cerebellar ischemic lesions of different ages but all were relatively recent. There were no abnormalities in both thalami (Figure 1). The cerebral angiogram showed 1 atherosclerotic lesion situated in the intracranial segment of the right vertebral artery, distal to the posterior inferior cerebellar artery (PICA) origin with a length of 7 mm and a stenosis of 98%, causing the reduction of the flow to the basilar artery (Figure 2A). The left vertebral artery was extremely thin at its origin and was occluded at the C2–C3 level. Thus, the left PICA territory was vascularized by the right vertebral artery. The collateral flow through the carotid system was insufficient to supply the posterior circulation.

The patient was referred to our institution for assessment and possible endovascular treatment. We decided to wait 8 weeks after the acute stroke to carry out the procedure. The patient was premedicated with a loading dose of clopidogrel (225 mg) on the day before the procedure. The neurological examination was completely normal. Endovascular stenting was performed under general anesthesia and full anticoagu-

lation therapy. Through femoral 6F access, a 6F-guiding catheter was placed inside the right vertebral artery. The lesion was crossed with a 0.014-inch guide wire and predilatated with a 3.0×20 mm VIVA balloon (Boston Scientific). Then, a 3.5×18 mm Cerebrence stent (Medtronic AVE, Inc.) was deployed at its nominal pressure of 6 atm. The immediate angiographic control showed restoration of the normal arterial diameter and left-side PICA preservation. No signs of vessel rupture, dissection, or intraluminal thrombus were visualized (Figure 2B). Computed tomography (CT) performed immediately after the procedure did not show hemorrhagic complications. The patient was neurologically intact after extubation. He was transferred to the intensive care unit for close monitoring of neurological status and blood pressure to maintain the patient in a normotensive status.

Twenty-four hours after the procedure, the patient became extremely agitated and after that, followed an apathetic period. There was no focal neurological alteration. MRI showed bilateral thalamic hemorrhages with predominance on the left side (Figure 3). The diagnosis of hemorrhage secondary to hyperperfusion was proposed. For this reason, it was decided to introduce hypotensive therapy to interrupt heparin therapy while continuing with aspirin and clopidogrel. When patient was discharged after 7 days of hospitalization, he had clinically completely recovered and was free of the neurological complications noted above.

Discussion

Available retrospective data suggest that there is an annual stroke incidence of 7% to 8% in patients with symptomatic

Received August 15, 2005; final revision received September 29, 2005; accepted October 12, 2005.

From the Department of Interventional Neuroradiology, Fondation Rothschild, Paris, France.

Reprint requests to Laurent Spelle, MD, PhD, Interventional Neuroradiology Department, Fondation Rothschild Hospital, 25 rue Manin 75940 Paris Cedex 19 –France. E-mail lspelle@fo-rothschild.fr

© 2005 American Heart Association, Inc.

Stroke is available at <http://www.strokeaha.org>

DOI: 10.1161/01.STR.0000196959.77184.49

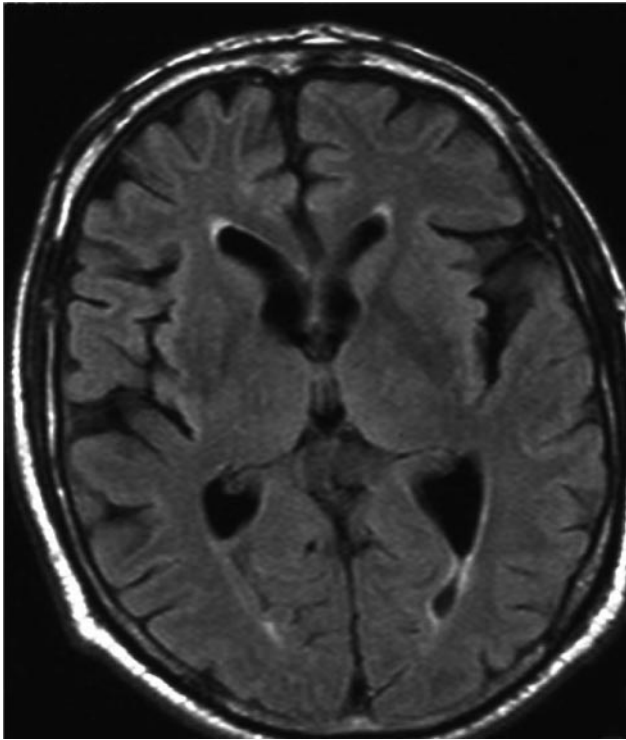


Figure 1. Axial flair MRI shows no lesions in both thalami.

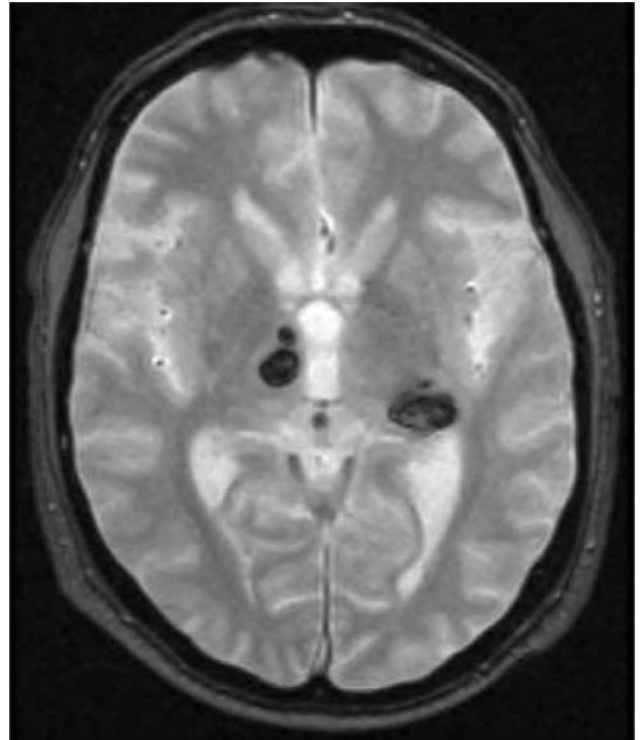


Figure 3. Axial T2 gradient-echo MRI 24 hours after the procedure shows bilateral thalamic hemorrhage.

vertebral artery stenosis.¹ The natural history of vertebrobasilar stenosis has been characterized by especially high stroke rates, and the long-term stroke-free survival in symptomatic patients is low.² The most common stroke mechanism is thrombus formation attributable to the severe stenosis with subsequent embolism. Although in some instances, hemodynamically significant stenosis without adequate collateral blood flow can also lead to low-flow ischemia and stroke.

Use of stent as a therapeutic option is supported by its capacity to act as a support for balloon angioplasty, preventing disruption of the plaque and as a covering for a plaque or an intimal flap, thus reducing the occurrence of emboli and flap recurrence. The overall stroke-free survival in the first year in patients treated with intracranial angioplasty with or without stent placement has ranged from 88% to 93% in preliminary studies.³

Hyperperfusion syndrome is a rare but well-described, potentially devastating complication after carotid endarterectomy or angioplasty and stenting.⁴ It designates the development of clinical symptoms as a result of rapidly increased cerebral blood flow in excess of that required to meet metabolic demands.⁵ It is theorized that the capillary bed beyond the stenosis is prone to perfusion breakthrough bleeding after increase of the blood flow because of the presence of impaired autoregulation. Coutts et al⁶ classified the presentation as (1) an acute focal edema (stroke-like presentation, attributable to edema immediately after revascularization), (2) acute hemorrhage, or (3) delayed classic presentation (seizures, focal motor weakness, or late intracerebral hemorrhage ≥ 24 hours after the procedure). In this series, the incidence of hyperperfusion syndrome was 3.1%

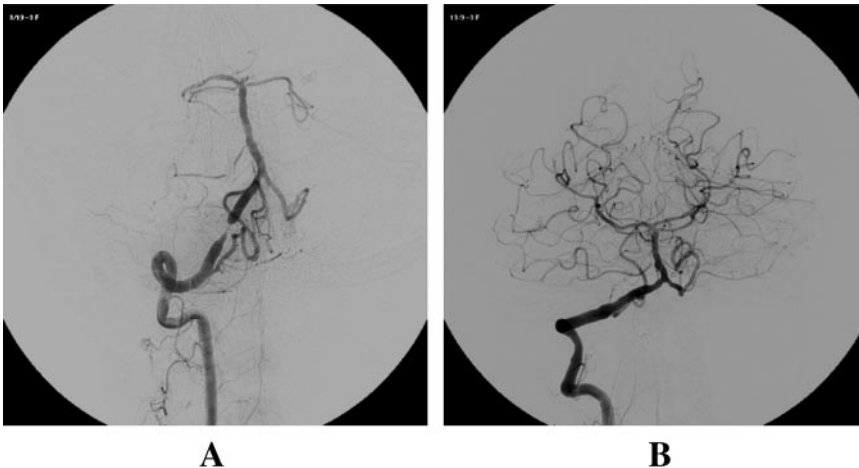


Figure 2. Right vertebral artery angiogram (anteroposterior view) before (A) and immediately after (B) angioplasty with stent placement.

after carotid endarterectomy and 6.8% after stenting. Kaku et al,⁵ using cerebral blood flow studies in patients submitted to carotid angioplasty with stent placement, concluded that in older patients, profound cerebral ischemia with impaired hemodynamic reserve is the highest risk situation for cerebral hyperperfusion phenomenon.

The first demonstration of hyperfusion syndrome with intracerebral hemorrhage after intracranial angioplasty was provided by Liu et al⁷ in a well-described case report of a fatal intracerebral hemorrhage after middle cerebral artery angioplasty. However, hyperperfusion syndrome has never been reported after intracranial stenting in the posterior circulation.

In our patient, we do not believe that the parenchymal hemorrhage was the result of a reperfusion lesion into an area of tissue infarction. Despite the history of worsening transient ischemic attacks and 1 cerebellar and occipital stroke, there were no persistent neurological deficits noted before the procedure, and CT and MRI did not reveal any ischemic lesion in the territory involved by the hemorrhagic complication. Moreover, the procedure was performed 8 weeks after the last clinical ischemic episode, and the patient was clinically intact during the 24 hours after the procedure. Postoperative angiogram did not demonstrate any vessel rupture, dissection, or intraluminal thrombus. CT scanning performed immediately after the procedure did not show hemorrhagic complications. This very early CT scan (just after the intervention) does not rule out an ischemia; but this, associated with the asymptomatic period between the end of the procedure and the clinical alterations (24 hours), favors the absence of ischemic complications related to the intervention.

At our institution, we routinely take actions to avoid or decrease the risk for hyperperfusion lesions and hemorrhagic complications after intracranial stenting. These include preprocedural MRI searching areas of subtle infarction and very strict control of blood pressure immediately after stenting.

Anticoagulation was maintained during and after the procedure (partial thromboplastin time was kept at 2.5× the

normal value) to prevent subacute vessel occlusion after stent placement. Aspirin and clopidogrel were given before the intervention, and we did not use glycoprotein IIb/IIIa inhibitors. However, there is no consensus in the literature about the best anticoagulation regimen.

Conclusion

In conclusion, hyperperfusion syndrome with hemorrhagic presentation may occur after intracranial stenting in the posterior circulation, although arterial pressure is strictly controlled. This should not discourage to apply this promising technique in the scenario of recurrent ischemic symptoms associated with high-grade intracranial vessel stenosis attributable to the lack of effective therapies and poor prognosis involving this situation. We need to achieve a better understanding of the mechanisms that promote this complication and determine precise clinical and radiological risk factors to avoid it.

References

1. Prognosis of patients with symptomatic vertebral or basilar artery stenosis. The Warfarin-Aspirin Symptomatic Intracranial Disease (WASID) Study Group. *Stroke*. 1998;29:1389–1392.
2. Qureshi AI, Suri MFK, Ziai WC, Yahia AM, Mohammad Y, Sen S, Agarwal P, Zaidat OO, Suarez JI, Wityk RJ. Stroke-free survival and its determinants in patients with symptomatic vertebrobasilar stenosis: a multicenter study. *Neurosurgery*. 2003;52:1033–1040.
3. Rasmussen PA, Perl J II, Barr JD, Markarian GZ, Katzan I, Sila C, Krieger D, Furlan AJ, Masaryk TJ. Stent-assisted angioplasty of intracranial vertebrobasilar atherosclerosis: an initial experience. *J Neurosurgery*. 2000;92:771–7785.
4. Ouriel K, Shortell CK, Illig KA, Greenberg RK, Green RM. Intracerebral hemorrhage after carotid endarterectomy: incidence, contribution to neurologic morbidity, and predictive factors. *J Vasc Surg*. 1999;29:82–89.
5. Kaku Y, Yoshimura S, Kokuzaka J. Factors predictive of cerebral hyperperfusion after carotid angioplasty and stent placement. *AJNR Am J Neuroradiol*. 2004;25:1403–1408.
6. Coutts SB, Hill MD, Hu WY. Hyperperfusion syndrome: toward a stricter definition. *Neurosurgery*. 2003;53:1053–1058.
7. Liu AY, Do HM, Albers GW, Lopez JR, Steinberg GK, Marks MP. Hyperperfusion syndrome with hemorrhage after angioplasty for middle cerebral artery stenosis. *AJNR Am J Neurodiol*. 2001;22:1597–1601.