

Sergio de Filippis
Emiliano Salvatori
Alessandro Bozzao
Luigi Maria Fantozzi
Paolo Martelletti

Migraine with aura, bipolar depression, ACM aneurysm. A case report

Received: 7 May 2004

Accepted in revised form: 21 February 2005

Published online: 8 April 2005

S. de Filippis (✉) • E. Salvatori • P. Martelletti
Regional Referral Headache Centre,
Department of Medicine,
Sant'Andrea Hospital,
II School of Medical Sciences,
University La Sapienza,
Via di Grottarossa 1035,
I-00189 Rome, Italy
e-mail: sergio.defilippis@uniroma1.it
Tel.: +39-06-80345250
Fax: +39-06-80345323

A. Bozzao • L.M. Fantozzi
UOC Neuroradiology,
Department of Diagnostic Sciences,
Sant'Andrea Hospital,
II School of Medical Sciences,
University La Sapienza,
Rome, Italy

Abstract B.D. is a 48-year-old professional woman. She has been suffering for migraine since she was 28, but she did not have serious problems until last year, when headache episodes became more frequent and it was necessary an admission to emergency room. At the beginning, the events were about 6 per month, lasting from 2 to 4 days, beating and of high intensity together with nausea, vomit, photo and phonophobia and visual aura. Looking at the anamnesis, we report a psychiatric treatment since about ten years, because of type II bipolar disorder. In spite of the psychopharmacological treatment, as the patient came in our Regional Headache Center, she talked about 7 events with aura (scintillating scotomas, emianopsia) per month, lasting 2–4 days with photo-

and phonophobia, nausea, crying crisis, anxiety. Although the neurological examination was normal, the sudden aggravation of pain symptomatology and the unresponsiveness to usual painkillers, suggested a cerebral CT and CT-angiography. CT and CT-angiography discovered the presence of an aneurysm of the right middle cerebral artery (MCA) of 4 mm diameter, with parietal irregularities. The patient was operated to reduce the hemorrhagic risk, with a positive result. One year after the operation, the patient reports a decrease of headache events with a frequency of 2 per month, lasting only a few hours, which she can now solve with COXIB.

Key words Migraine with aura • Type II bipolar disorder • MCA aneurysm

Introduction

The primary target in migraine diagnosis is to identify the main problem, i.e., the real origin of the pain. In many cases, the patient does not seem to understand the complexity of the disorder; sometimes, the headache is so troublesome, that it directly induces the patient to seek help from the physician, probably resorting to emergency room. This occurrence causes problems for the first aid

physician, who usually, to be prudent, sends the patient for quite sophisticated diagnostic exams.

According to the 2004 IHS classification, the headache associated with cerebrovascular pathology (transient ischaemia, cerebrovascular pathology, ischaemic stroke) is included in the secondary class. A pre-existent headache aggravation should be considered together with the evolution of clinical conditions.

Headache may occur suddenly or gradually, usually remaining unilateral, well located, with a low or moderate

intensity, and sometimes becoming a disabling pain in many patients.

Although aneurysms remain clinically silent until the breaking moment, sometimes they cause clear symptomatology, which should not be underestimated for obtaining an early correct diagnosis [1].

In addition to the cranial nerves' deficit, deriving from the deformity's compression on that nerve, and from the vascular problems, headache is often referred to as a pre-breaking symptom [2].

The headache can occur as a long-lasting and sometimes beating dull pain, or it could assume more tensive characteristics. Pain location can be different: unilateral, bilateral, diffused, sometimes in peri-retro-orbital region, not according to the aneurysm's position.

The co-occurrence relief is very important for the treatment: for example, in the treatment of migraine, as in our clinical case, a concomitant mental disorder can make some therapeutical opportunities preferable, but, on the other hand, it can also be restrictive. Psychiatric co-occurrence shows a more serious clinical symptomatology, a tendency to chronicity and a lower response to pharmacological treatment. It is clear that anxiety and mood trouble represent typical characteristics of the migrainous personality. Recent trials show a high incidence of major depression associated with anxiety in migraine patients.

The concomitance of several diseases can complicate the diagnosis, therefore it is important for the physician to pay attention, in order to correctly diagnose all the different components of a specific clinical disease. During the anamnesis, an accurate medical and neurological examination is important in order to have a wide and almost complete vision of the clinical case.

Only in cases of sudden symptomatology variation and the appearance of neurological signs is a diagnostic instrumental examination mandatory [3].

Clinical case

B.D. is a 48-year-old professional woman. She has been suffering from migraine since she was 28, but she did not have serious problems until last year, when headache episodes became more frequent and an admission to emergency room was necessary.

At the beginning, the events were about 6 each month, lasting at most 2 days, with quite a low intensity, but during the last year they became nearly 12 each month, lasting from 2 to 4 days, beating and of high intensity together with nausea, vomiting, photo- and phonophobia, and visual aura. Because of this symptomatology, the patient had to refer to emergency room many times (Table 1).

Looking at her anamnestic family history, we observed that her father is affected by headache, while her mother is affected by an ischaemic cardiopathy and arterial hypertension. From the pathologic anamnesis we could deduce that the patient has been in treatment in a psychiatric centre for about 10 years, because of type II bipolar disorder with lithiocarbonatum, paroxetine, lorazepam and amitriptyline. At the beginning of the pathology, she was screened with brain RMN; the result was negative.

From previous first aid exams and other neurological visits we could not find any significant result for secondary pathologies, but they showed a psychiatric co-occurrence.

In spite of the psychopharmacological treatment, when the patient came to our Regional Headache Center, she talked about 7 events with aura (shining scotomas, hemianopia) in a month, lasting 2–4 days with photo- and phonophobia, nausea, crying crisis and anxiety. This symptomatology induced us to evaluate the possibility of an organic origin of the headache, hence of its secondary nature [4].

A middle-grade hypertension emerged during a clinical examination, confirmed by a pressure holter exam. We did not find anything abnormal in the neurological exam. A CT and CT-angiography discovered the presence of an aneurysm of the MCA (Fig. 1 and Table 2).

Table 1 Clinical profile

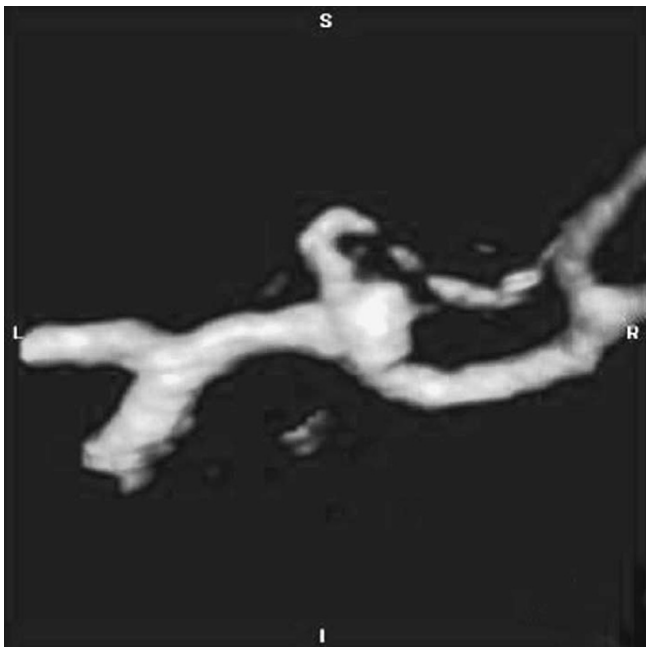
Beginning age	28 years
Event duration	2–4 days
Event frequency	12/month
Pain location	Front orbital, top
Pain type	Beating
Pain intensity	Very severe
Aggravation in physical activity	Yes

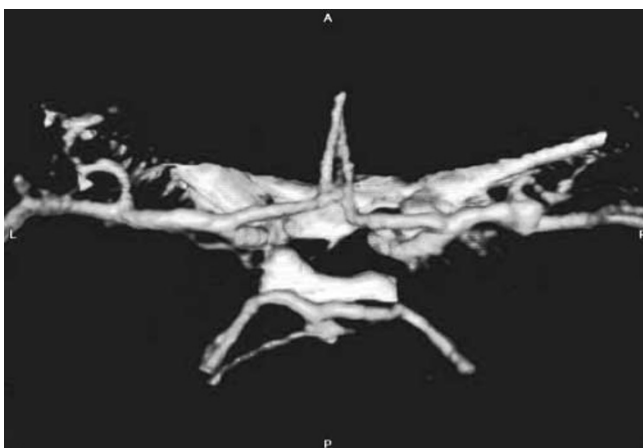

Fig. 1 Aneurysm of 4 mm in diameter located at the level of the right middle cerebral artery bifurcation

Table 2 Diagnostic profile

Clinical exam	A.P. 165/110, c.f. 72 b/m
Neurological exam	Negative
NMR hypophysis and brain	Presence of hypophysary microadenoma, small gliotic aspecific focus
Cerebral angio NMR	Presence of local aneurysmatic dilatations of 4 mm diameter near the middle right cerebral artery bifurcation
CT	Aneurysm at the middle right cerebral artery
Cerebral CT-angiography	It confirms presence of an aneurysm of middle right cerebral artery

**Fig. 2** CT after surgical intervention shows a reduction of MCA aneurysm

In migraine this occurrence is considered a confounding factor for a potential diagnostic delay [5, 6].

Despite the fact that the aneurysm diameter was inferior in respect to the dimensions indicated in the guidelines, its complex morphology with parietal irregularities placed it, in both our experience and in the literature,

among the aneurysms with breaking risk [7–11]. The patient was operated to reduce the aneurysmatic sack, with a positive result (Fig. 2).

Eighteen months after the operation, the patient still registers headache, but events have decreased, with a frequency of 2 per month, lasting a few hours, which she truncates with COXIB. She also takes carbolithium and paroxetine.

Comment

B.D. described a migraine with aura. The increase of her symptomatology and of the frequency of events led her to go more often to her physician. The psychiatric co-occurrence induced the physician to treat the bipolar disorder, avoiding the migraine symptomatology.

Conclusions

We can say that anamnesis, medical and neurological exams are definitely necessary to correctly diagnose headache. In this case, we considered it useful to suggest a cerebral CT-angiography, because an apparently tensive headache, with nausea and vomiting and a sudden aggravation of symptomatology were not clear enough to confirm the previous diagnosis. In fact, this aggravation was the predictive sign of a cerebral lesion.

The importance of CT or NMR with the study of both cerebral and extra-cerebral arteries and veins in those headaches which show clinical changes from the previous situation, is now clear [12].

Migraine is one of the most interesting clinical pathologies, because headache is the most frequent symptom and, at the same time, it could be the warning of an aneurysmatic break. In the small amount of time available in emergency room, it seems impossible to diagnose a headache, so it could be useful to improve co-operation between headache specialists and emergency room.

In that way, it could be easier to send patients, who usually resort to emergency room, to a headache centre so as to reduce costs and to have more comfortable conditions for a suitable visit. The patient will be more at ease and there will surely be less confusion taking the anamnestic history.

References

1. Pico F, Bioussé V, Chapot R, Bousser MG (2002) Aneurysm of the anterior cerebral artery disclosed by unique hemianopic scotoma. *Rev Neurol (Paris)* 158:347–350
2. Silbert PL, Mokri B, Schievink WI, Piepgras DG (1996) Cranial nerve palsy in spontaneous dissection of the extracranial internal carotid artery. *Neurology* 46:356–359
3. Ostergaard JR (1991) Headache as a warning symptom of impending aneurysmal subarachnoid haemorrhage. *Cephalalgia* 11:53–55
4. Raps EC, Rogers JD, Galetta SL, Solomon RA, Lennihan L, Klebanoff LM, Fink ME (1993) The clinical spectrum of unruptured intracranial aneurysms. *Arch Neurol* 50:265–268
5. D'Anglejan-Chatillon J, Ribeiro V, Mas JL, Youl BD, Bousser MG (1989) Migraine – a risk factor for dissection of cervical arteries. *Headache* 29:560–561
6. Duyff RF, Snijders CJ, Vanneste JA (1997) Spontaneous bilateral internal carotid artery dissection and migraine: a potential diagnostic delay. *Headache* 37:109–112
7. ISUIA Investigators (2004) The International Study of Unruptured Intracranial Aneurysms. <http://mayoresearch.mayo.edu/mayo/research/ISUIA> (last accessed 22 February 2005)
8. Bederson JB, Awad IA, Wiebers DO et al (2000) Recommendations for the management of patients with unruptured intracranial aneurysms: a statement for healthcare professionals from the Stroke Council of the American Heart Association. *Stroke* 31:2742–2750
9. Wiebers DO, Whisnant JP, Huston J 3rd et al (2003) Unruptured intracranial aneurysms: natural history, clinical outcome, and risks of surgical and endovascular treatment. *Lancet* 362:103–110
10. Molyneux A, Kerr R, Stratton I et al (2002) International Subarachnoid Aneurysm Trial (ISAT) of neurosurgical clipping versus endovascular coiling in 2143 patients with ruptured intracranial aneurysms: a randomised trial. *Lancet* 360:1267–1274
11. Laidlaw J (2004) Endovascular therapy versus surgical clipping for basilar artery bifurcation aneurysm. *J Clin Neurosci* 11:480
12. Forbes G, Fox AJ, Huston J 3rd, Wiebers DO, Torner J (1996) Interobserver variability in angiographic measurement and morphologic characterization of intracranial aneurysms: a report from the International Study of Unruptured Intracranial Aneurysms. *AJNR Am J Neuroradiol* 17:1407–1415