

Acute Intracranial Subdural Hematoma Following a Lumbar CSF Leak Caused by Spine Surgery

Daniel M. Sciubba, MD, Ryan M. Kretzer, MD, and Paul P. Wang, MD

Study Design. Case report.

Objective. To report a case of an acute intracranial subdural hematoma that formed due to cerebrospinal fluid (CSF) leak following lumbar surgery.

Summary of Background Data. Intracranial hypotension may occur when CSF is removed from the subarachnoid space. Intracranial subdural hematoma formation has been observed following significant CSF drainage during lumbar puncture or ventricular shunt placement. However, formation has been described only twice in the literature following spine surgery.

Methods. Retrospective review of the patient's medical record and head CT imaging.

Results. A 55-year-old woman underwent lumbar surgery for failed back syndrome. Intraoperatively, a dural tear was noted and repaired. One week later, she developed expressive aphasia, and CSF drainage from her lumbar wound was noted. A head CT revealed an acute intracranial subdural hematoma with mass effect. Evacuation of the hematoma occurred *via* craniotomy, and the lumbar dura was repaired intraoperatively.

Conclusions. We report the rare case of an acute intracranial subdural hematoma caused by a CSF leak following lumbar surgery. This report illustrates the potential morbidity associated with CSF leaks occurring after spinal surgery.

Key words: subdural hematoma, spine surgery, CSF leak. *Spine* 2005;30:E730–E732

Intracranial hypotension is a condition caused by decreased cerebrospinal fluid (CSF) volume that may result in orthostatic headaches, neck stiffness, nausea, vomiting, visual and auditory disturbances, changes in mental status, and seizures.^{1,2} It has been reported after myelography, lumbar puncture, ventricular shunt placement, CSF drains placed during aortic aneurysm procedures, spinal anesthesia, spine surgery, craniotomy, and spine trauma.^{1–5} In the majority of cases, symptoms resolve spontaneously without intervention. Intracranial hypotension, however, has also been associated with the development of acute subdural hemorrhage in the intracranial compartment, presumably as a result of traction on venous structures after a rapid drop in intracranial pressure.⁶

While the exact incidence is unknown, subdural hematoma formation has been reported in conjunction with dural lumbar puncture, spinal anesthesia, ventriculoperitoneal shunt placement, and myelography.^{1,2,6–10} There have been only two reports, however, of intracranial subdural hemorrhage following spine surgery, both of which were presumed to be the result of overdrainage of CSF.^{2,11} In this report, we present a case of an acute subdural hematoma occurring in the setting of an observed CSF leak following lumbar surgery.

■ Case Report

The patient is a 55-year-old woman with a history of laminectomies and posterior lumbar interbody fusion for spinal stenosis and instability at L3–L4. Her instrumentation was removed after nonunion was noted, and she developed progressive deformity and pain. She subsequently underwent an anterior L3 corpectomy with femoral allograft reconstruction and posterior L2–L4 pedicle screw fusion. Intraoperatively, a 3-mm dural tear was noted with an observed CSF leak of less than 10 mL. The tear was closed with a running 4-0 silk suture and was tested under direct visualization with an applied Valsalva breath at 40 mm Hg. No residual leak was observed at that time.

The patient's hospital course was uneventful until the seventh postoperative day when she developed intermittent confusion. Neurosurgical consultation noted a new expressive aphasia and a large amount of clear fluid actively draining from the lumbar wound. When asked, the patient acknowledged that a headache was present but could not qualify her discomfort due to her lack of fluency. She and her family denied any recent or remote history of head trauma to account for these symptoms. The rest of the neurologic examination was nonfocal: the patient was alert and able to follow commands briskly; cranial nerves II through XII were intact; motor strength was 5/5 in all major muscle groups; sensation was grossly intact to light touch and pinprick; and reflexes were 2+ throughout. Gait was not assessed. A head CT revealed a 1.2-cm acute subdural hematoma along the left frontal, parietal, and temporal lobes with associated mass effect and 2 mm of left-to-right midline shift, as well as a smaller 2-mm right frontal acute subdural hematoma (Figure 1). The patient was taken emergently to the operating room for evacuation of the large (>80 mL) left convexity subdural hematoma. No intervention occurred for the smaller right hematoma. Her aphasia resolved completely following surgery, and a head CT showed complete evacuation of the left hematoma and stable size of the right hematoma.

From the Department of Neurosurgery, Johns Hopkins University School of Medicine, Baltimore, MD.

Acknowledgment date: April 7, 2005. First revision date: May 27, 2005. Acceptance date: June 7, 2005.

The manuscript submitted does not contain information about medical device(s)/drug(s).

No funds were received in support of this work. No benefits in any form have been or will be received from a commercial party related directly or indirectly to the subject of this manuscript.

Address correspondence and reprint requests to Paul P. Wang, MD, Department of Neurosurgery, Phipps Building, Room 101, 600 North Wolfe Street, Baltimore, MD 21287; E-mail: ppwang@jhmi.edu

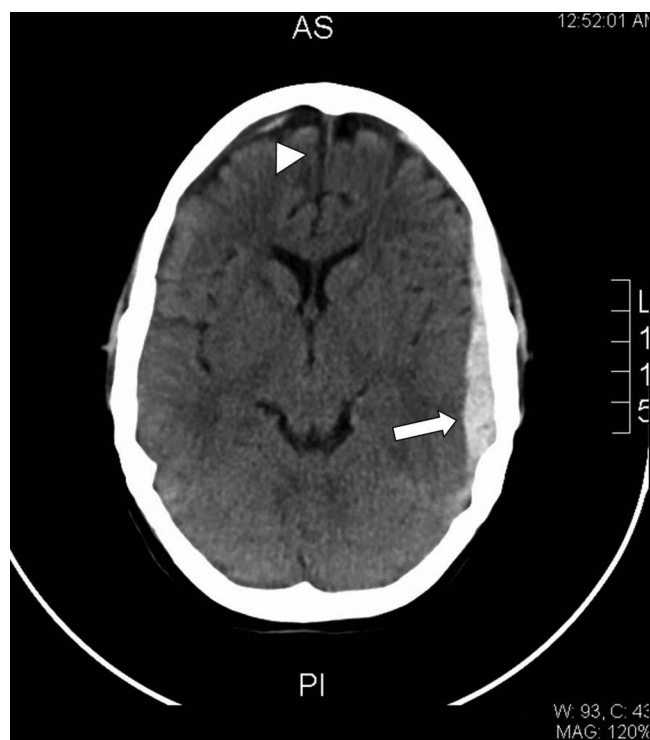


Figure 1. Noncontrast CT of the brain demonstrating a 1.2-cm-thick acute subdural hematoma along the left frontal, parietal, and temporal lobes (arrow) with 2 mm of left-to-right midline shift and a smaller 2-mm right frontal acute subdural hematoma (arrowhead).

Over the ensuing 2 days, she continued to have fluid drainage from the inferior edge of her lumbar incision, so the wound was explored by the primary service. Intraoperatively, a small CSF leak at the site of the previous dural tear was identified and repaired. The patient was discharged 5 days later with full motor strength in all extremities and no residual cognitive or language disturbances. Four weeks after discharge, the patient was neurologically intact, and her craniotomy and lumbar spine incisions were well healed. Because of her excellent clinical recovery, no repeat head CT was performed.

Discussion

Intracranial hypotension is a well-known consequence of procedures that reduce CSF volume and pressure, such as lumbar puncture, spinal anesthesia, myelography, craniotomy, and ventricular shunts.¹ The most characteristic symptom of this syndrome is headache, shown to occur in 37% of patients undergoing lumbar puncture.⁷ Such a headache typically occurs 24 to 48 hours after dural puncture, is worsened when standing, is alleviated in the supine position, and tends to be bilateral in the frontal and occipital regions. The etiology of this headache is likely due to caudal movement of the brain secondary to loss of CSF, with resultant tension on the pain-sensitive dural sinuses.^{7,12} It is thought that such headaches occur when excessive volumes of CSF are removed (approximately 250 mL/day).⁶ Such headaches are usually benign and 80% resolve within 5 days.^{7,8}

In addition to clinical symptoms, there are well-established laboratory and radiologic findings associated with intracranial hypotension. Spinal fluid opening pressure is by definition less than 60 mm H₂O, and CSF protein and lymphocyte counts may be higher than normal.^{10,13} CT and MRI scans may show caudal displacement of the brain with cerebellar tonsillar herniation and a decrease in size of the subarachnoid cisterns and cerebral ventricles. In addition, meningeal enhancement, dilated epidural veins, and pituitary enlargement have all been described and directly correlate with decreased CSF pressure.^{10,14} Characteristic signs on spine imaging include spinal epidural venous engorgement and enhancement, subdural or epidural fluid collections, and most notably, the presence of an extraspinal CSF fluid collection within the posterior soft tissues.¹⁵ Angiography, although rarely performed in such cases, may show dilated and increasingly prominent veins during the venous phase.¹⁶

Intracranial hypotension is usually a benign condition; however, a potentially fatal complication is the formation of an acute intracranial subdural hematoma. This complication has been extensively documented in cases of CSF loss secondary to dural lumbar puncture, spinal anesthesia, ventriculoperitoneal shunt placement, and myelography.^{1,2,6-10} Some series have reported subdural hematomas in 10% of all cases of intracranial hypotension, regardless of cause.¹ While the exact etiology is unknown, it is postulated that loss of CSF volume causes a drop in intracranial pressure, leading to an enlargement of the dural venous sinuses that predisposes the patient to a spontaneous subdural hematoma.¹⁵ Caudal brain displacement resulting from pressure may create tension on already enlarged venous sinuses and further predispose the patient to venous tears.⁷ It has also been hypothesized that intracranial hypotension produces small subdural fluid collections that may stretch and eventually rupture large cortical veins crossing the subdural space.⁹ Finally, predisposition to subdural hemorrhage may be exacerbated by reflex vasodilatation in response to pressure placed on pain-sensitive structures like the dura, blood vessels, and dural sinuses by the caudally displaced brain.¹²

In addition to intracranial subdural hematomas, subarachnoid hemorrhage and spinal subdural hematomas have also been described as a result of intracranial hypotension.^{8,17} Patients with a history of head trauma, cerebral atrophy, cranial vault abnormalities, arteriovenous malformations, hemorrhagic diatheses, cerebral aneurysms, meningovascular syphilis, and meningiomas may be at increased risk for such hemorrhagic complications.^{6,7} In general, a subdural hematoma should be suspected in any patient with a meningeal injury in which a headache lasts longer than 5 days, is excessively severe or persists in the supine position, or in those patients that go on to develop neurologic changes (altered mental status, focal cranial nerve, motor, or sensory examinations, *etc.*).⁶

Two other cases of acute subdural hematoma after spinal surgery have been reported in the literature. Burkhard and Duff described a patient with diffuse headache, nausea, vomiting, and dizziness following a L5–S1 discectomy for sciatica. A head CT revealed bilateral acute subdural hematomas, and the patient's headache was subsequently managed with steroids. Although a fluid collection was noted around the laminectomy site on MRI, neither a definite pseudomeningocele nor a leak at the wound site was noted.² In the second case, Hentschel *et al* described a patient with extradural metastatic breast cancer to the T5 vertebra who underwent resection and reconstruction at that level.¹¹ Seven months after the procedure, the patient became acutely obtunded and was found to have bilateral subdural fluid collections and pneumocephalus. Nuclear cisternography demonstrated a CSF-pleural fistula. Reexploration revealed a dural leak, which was closed with an intercostal muscle flap, and the patient recovered with no residual neurologic deficits.¹¹

Treatment for symptomatic intracranial hypotension includes analgesics, hydration, laying supine for at least 24 hours, the administration of caffeine and/or steroids, and the application of a blood patch for refractory cases.^{18–20} Although blood patches have been documented to decrease postdural puncture headaches, there is no evidence of their efficacy in prevention of subdural hemorrhage, even in the acute phase.^{6,7}

■ Conclusion

We have described a rare case of an acute intracranial subdural hematoma occurring in the setting of a cerebrospinal fluid leak following lumbar spine surgery. While subdural hematomas have been documented in the setting of lumbar puncture and spinal anesthesia, this case demonstrates the need for awareness of this potentially fatal complication after spine surgery. As occurred with this patient, wound exploration may thus be warranted for those patients complaining of persistent headache after surgical durotomy.

■ Key Points

- Intracranial hypotension results from the drainage of cerebrospinal fluid from the subarachnoid space.

- Acute intracranial subdural hematoma formation is a rare complication of intracranial hypotension.
- In our patient, an acute intracranial subdural hematoma resulted from a cerebrospinal fluid leak during lumbar surgery.

References

1. Francia A, Parisi P, Vitale AM, et al. Life-threatening intracranial hypotension after diagnostic lumbar puncture. *Neurol Sci* 2001;22:385–9.
2. Burkhard PR, Duff JM. Bilateral subdural hematomas following routine lumbar discectomy. *Headache* 2000;40:480–2.
3. Dardik A, Perler BA, Roseborough GS, et al. Subdural hematoma after thoracoabdominal aortic aneurysm repair: an underreported complication of spinal fluid drainage? *J Vasc Surg* 2002;36:47–50.
4. Cheung AT, Pochettino A, Guvakov DV, et al. Safety of lumbar drains in thoracic aortic operations performed with extracorporeal circulation. *Ann Thorac Surg* 2003;76:1190–6; discussion 6–7.
5. McHardy FE, Bayly PJ, Wyatt MG. Fatal subdural haemorrhage following lumbar spinal drainage during repair of thoraco-abdominal aneurysm. *Anaesthesia* 2001;56:168–70.
6. Acharya R, Chhabra SS, Ratra M, et al. Cranial subdural haematoma after spinal anaesthesia. *Br J Anaesth* 2001;86:893–5.
7. Gaucher DJ Jr, Perez JA Jr. Subdural hematoma following lumbar puncture. *Arch Intern Med* 2002;162:1904–5.
8. Wells JB, Sampson IH. Subarachnoid hemorrhage presenting as post-dural puncture headache: a case report. *Mt Sinai J Med* 2002;69:109–10.
9. de Noronha RJ, Sharrack B, Hadjivassiliou M, et al. Subdural haematoma: a potentially serious consequence of spontaneous intracranial hypotension. *J Neurol Neurosurg Psychiatry* 2003;74:752–5.
10. Garcia-Morales I, Porta-Etessam J, Galan L, et al. Recurrent subdural haematomas in a patient with spontaneous intracranial hypotension. *Cephalalgia* 2001;21:703–5.
11. Hentschel SJ, Rhines LD, Wong FC, et al. Subarachnoid-pleural fistula after resection of thoracic tumors. *J Neurosurg Spine* 2004;100:332–6.
12. Kelsaka E, Sarihasan B, Baris S, et al. Subdural hematoma as a late complication of spinal anesthesia. *J Neurosurg Anesthesiol* 2003;15:47–9.
13. Lay CM. Low cerebrospinal fluid pressure headache. *Curr Treat Options Neurol* 2002;4:357–63.
14. Reina MA, Alvarez-Linera J, Lopez A, et al. Magnetic resonance in dural post-puncture headache in patient with cerebrospinal fluid hypotension. *Rev Esp Anesthesiol Reanim* 2002;49:89–100.
15. Dillon WP, Fishman RA. Some lessons learned regarding the diagnosis and treatment of spontaneous intracranial hypotension. *AJNR Am J Neuroradiol* 1998;19:1001–2.
16. Roll JD, Larson TC 3rd, Soriano MM. Cerebral angiographic findings of spontaneous intracranial hypotension. *AJNR Am J Neuroradiol* 2003;24:707–8.
17. Guthikonda M, Schmidek HH, Wallman LJ, et al. Spinal subdural hematoma: case report and review of the literature. *Neurosurgery* 1979;5:614–6.
18. Morewood GH. A rational approach to the cause, prevention and treatment of postdural puncture headache. *Cmaj* 1993;149:1087–93.
19. DiGiovanni AJ, Dunbar BS. Epidural injections of autologous blood for postlumbar-puncture headache. *Anesth Analg* 1970;49:268–71.
20. Seebacher J, Ribeiro V, LeGuillou JL, et al. Epidural blood patch in the treatment of post dural puncture headache: a double blind study. *Headache* 1989;29:630–2.