

PREMENSTRUAL SYNDROME

Drospirenone in the treatment of severe premenstrual cerebral edema in a woman with antiphospholipid syndrome, lateral sinus thrombosis, situs inversus and epileptic seizures

SVETLANA VUJOVIĆ¹, JASNA ZIDVERC², MILOŠ STOJANOVIĆ¹, ZORANA PENEZIĆ¹, MIOMIRA IVOVIĆ¹, VLADIMIR ĐUKIĆ¹, & MILKA DREZGIĆ¹

¹Institute of Endocrinology, Clinical Center of Serbia, Beograd, Serbia and Montenegro, and ²Institute of Neurology, Clinical Center of Serbia, Beograd, Serbia and Montenegro

Abstract

We report herein the case of 32-year-old woman with situs inversus, thrombophilia, antiphospholipid syndrome and severe premenstrual syndrome (PMS) with cerebral edema and epileptic seizures prior to menstruation. Seven days prior to regular menstruation she developed severe PMS, including headache, blurred vision, epileptic seizures, urinary incontinence, craving for food, depression and irritability. Papilledema was detected. Daily hormone analyses prior to and during menstruation confirmed an ovulatory cycle with extremely high progesterone, prolactin and insulin levels in the late luteal phase. From day 29 to day 31, progesterone and insulin decreased sharply and the estradiol/progesterone ratio changed, leading to epileptic seizures and the peak of her symptoms. Diuretic treatment was administered. All symptoms disappeared during the first few days of menstruation. A novel oral contraceptive, containing ethinyl estradiol and drospirenone, an antimineralocorticoid progestogen, was given during the next cycle and hormone analyses were repeated. All symptoms were reduced significantly and no cerebral edema and epileptic seizures occurred. This is the first report of a woman with severe PMS and cerebral edema being treated successfully with an oral contraceptive containing drospirenone.

Keywords: *Premenstrual syndrome, progesterone, estradiol, cerebral edema, epileptic seizures*

Introduction

Premenstrual syndrome (PMS) has been defined as distressing physical, behavioral and psychological symptoms, not due to organic disease, which recur regularly during the same phase of each menstrual cycle and which disappear or regress significantly during the remainder of the cycle [1]. Typical physical signs include symptoms of fluid retention such as breast tenderness, swelling and abdominal bloating, weight gain, and headache affecting well-being and quality of life. Psychological symptoms include irritability, depression, reduced libido and attacks of bulimia. One consistent endocrine finding in PMS is that symptom development in the luteal phase requires ovulation [2]. PMS symptoms do not occur in anovulatory cycles, before puberty, during pregnancy or after menopause [3], yet will continue after hysterectomy if ovarian function is maintained [4]. Female-to-male transsexuals have ovulatory cycles, but no PMS due to the gradual fall of progesterone in the luteal phase [5].

Alterations in mineralocorticoid metabolism may be significant in the pathogenesis of PMS. Changes in the renin–angiotensin–aldosterone system (RAAS) play an important role during the luteal phase of the cycle. Aldosterone, the major regulator of blood volume and potassium homeostasis, acts primarily through the kidney, causing retention of sodium and loss of potassium. So, aldosterone antagonism could be of potential benefit in women with severe PMS.

Oral contraceptives (OCs) are often recommended to women with PMS, but the progestogenic properties of OCs vary depending on the molecule from which they are derived. The development of a new generation of progestogens with improved receptor selectivity profiles has been a great challenge. A fourth-generation progestogen, drospirenone, derived from spironolactone, has partial antimineralocorticoid activity and weak antiandrogen effects. The antimineralocorticoid activity is derived from direct competition with aldosterone for binding to the aldosterone receptor. Since a number of PMS symptoms appear to be related to fluid retention, it was anticipated that the

antimineralocorticoid properties of drospirenone would be particularly effective at relieving symptoms.

The objective of the present study was to evaluate the effects of a novel OC containing drospirenone on severe PMS that included epileptic seizures and intracranial hypertension.

Case report

A 32-year-old woman was the second child of healthy parents, born from a twin pregnancy. Her twin was lost during the second trimester of the pregnancy. She had menarche at 9 years of age and began to experience PMS 13 years later. During the past 9 years she had experienced seven spontaneous abortions and undergone premature childbirth. During pregnancy she had no exacerbations of PMS. Informed written consent was obtained from this patient.

X-ray and ultrasound examinations revealed situs organorum inversus completus in the thorax and abdomen, forked sixth and seventh ribs, coalesced second and third cervical vertebrae and short third, fourth and fifth metacarpal bones and phalanges. Her karyotype was normal – 46,XX. Three years previously a *prothrombin* gene mutation (*G20210A* allele), a single-nucleotide G-to-A transition at position 20 210 in the sequence of the 3'-untranslated region on chromosome 11, was discovered [6]. She was genotyped by the polymerase chain reaction method as *FVR506Q*-negative and *FII G20210A*-positive in the heterozygous state. This genetic thrombophilia has been established as an important risk factor for venous thrombosis [7]. Two years before she developed a cerebral right sinus thrombosis diagnosed by digital subtraction angiography, one of the rare clinical manifestations of the antiphospholipid syndrome [8]. The activated partial thromboplastin time (PTT) was prolonged and lupus anticoagulant was present, as were antimitochondrial antibodies. She was treated with repeated cerebrospinal fluid drainage, acetazolamide and later with intravenous heparin, followed by warfarin.

Seven days prior to each menstruation she developed typical severe PMS symptoms together with cerebral edema and epileptic seizures, and regularly spent a few days in hospital receiving emergency diuretic therapy. Therapy with diuretics (Aldactone[®] 150 mg), benzodiazepine and fluoxetine during the luteal phase failed to relieve her PMS symptoms, which persisted. This investigation was conducted for scientific rather than clinical reasons.

Clinical examination on admission revealed a woman with short stature (150 cm) who was overweight (87 kg) and with centripetal fat distribution, predominantly on the posterior neck and upper trunk. There were numerous nummular skin changes, predominantly erythematous and pruriginous, and dark older lesions with central necrosis, distributed on the posterior trunk and the legs. The diagnosis of PMS was confirmed by a prospective recording of daily symptoms using the Premenstrual Distress Questionnaire

(recording of ten most prevalent symptoms) and the Moos Menstrual Questionnaire [9]. Each symptom was scored using the scale 0 = none, 1 = mild, 2 = moderate and 3 = severe, indicating the presence of severe PMS. Her symptoms were followed up prospectively daily during the luteal phase, menstruation and first 7 days of the next cycle. Hormone analyses – follicle-stimulating hormone, luteinizing hormone, prolactin, estradiol (Figure 1), progesterone (Figure 2), testosterone and sex hormone-binding globulin (SHBG) – were performed daily. During this period she was treated with anticoagulants, with daily measurements of prothrombin time (PT) and PTT, and with diuretics, fluoxetine, benzodiazepine and biguanide. Thyroid, parathyroid and adrenal function were normal, she did not have diabetes. From day 25 of her ovarian cycle all symptoms worsened, including irritability, tiredness, mood swings, restlessness, depression, bloatedness and weight gain (from 87 to 92 kg). Prolactin levels increased from 300 to 500 mIU/l from day 25 to day 27, reaching a maximum 1 day prior to menstruation, and her progesterone levels decreased from 280 to 200 nmol/l during days 25 to 29. During the night from days 29 to 30 she had dyspnea, blurred vision, felt weak and craved food. Fundoscopic examination revealed bilateral papilledema with decreased visual acuity. At that time, from the evening to the morning, her progesterone levels decreased rapidly from 200 to 60 nmol/l and her insulin concentrations from 120 to 20 mIU/l. Computed tomography of her cranium revealed no abnormalities. One day prior to menstruation whilst asleep during night she had a grand mal epileptic seizure with urinary and fecal incontinence and transitory cardiac arrhythmia lasting 5 min. Her prolactin level reached its peak at that time, whilst she remained normoglycemic and her progesterone levels decreased from 60 to 1 nmol/l. Cerebral edema was found. Lumbar puncture revealed raised intracranial pressure with an increased pressure of 400 mmHg and she had developed a focal neurological deficit. Cyto-biochemical content of cerebrospinal fluid was normal. Oligoclonal bands were not detected in cerebrospinal fluid or serum. She was treated with diuretics. All her symptoms disappeared gradually during the first 3 days of menstruation.

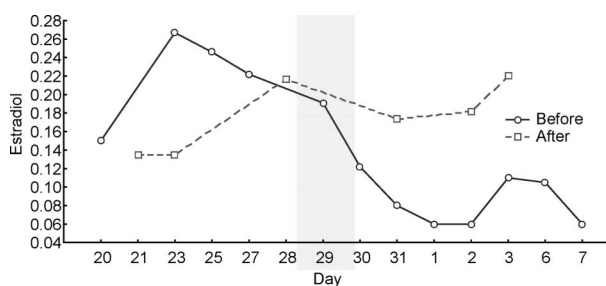


Figure 1. Estradiol level during the luteal phase (day 20–31) of one menstrual cycle and the follicular phase (day 1–7) of the next cycle, before and after administration of Yasmin[®] to the patient with severe premenstrual syndrome and cerebral edema.

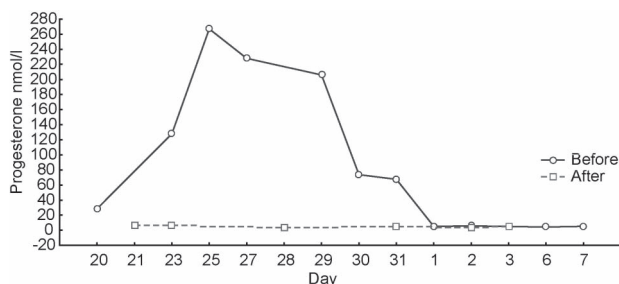


Figure 2. Progesterone levels during the luteal phase (day 20–31) of one menstrual cycle and the follicular phase (day 1–7) of the next cycle, before and after administration of Yasmin[®] to the patient with severe premenstrual syndrome and cerebral edema.

In the next cycle she received a daily oral dose of 30 μ g ethinyl estradiol and 3 mg drospirenone (Yasmin[®]; Schering AG, Berlin, Germany) on days 1–21, followed by a tablet-free period from day 22 to day 28. Effects of the treatment were monitored by means of COPE (Calendar of Premenstrual Experiences) score [10]. Daily hormone measurements showed an anovulatory cycle, with normal prolactin and insulin levels, and she lost 5 kg (from 87 to 82 kg) prior to menstruation. She experienced no PMS symptoms and had no cerebral edema or epileptic seizures.

Discussion

A case of a 32-year-old woman with lateral sinus thrombosis (possibly induced by mastoiditis), *pro-thrombin* gene mutations and antiphospholipid syndrome, epileptic seizures and raised intracranial pressure was referred by neurologists. There were two possible explanations for this case. The coincidental association of two thrombotic disorders could have been the cause of her seven spontaneous abortions and antiphospholipid antibodies could have been responsible for the thrombotic event. There are some studies demonstrating anticardiolipin antibodies in 32–40% of patients with idiopathic intracranial hypertension with normal cerebral angiograms, suggesting the possibility of a non-occlusive thrombotic pathogenesis of some causes of intracranial hypertension [11]. However, the fact that she had exacerbations every month prior to menstruation implied a possible link between hormonal fluctuations during the menstrual cycle and a variety of physical, emotional and fluid retention-related symptoms.

We confirmed severe PMS in this patient. About 20–30% of all fertile women suffer from PMS [12], of which about 43% suffer from weight gain and edema due to water retention, similar to this patient. Severe symptoms are found in 2–3% of fertile women such that, on more than two occasions within any 6 months, sufferers are unable to work during the premenstrual period and their lives are totally disrupted. The patient reported here spent 5 days each month in hospital because of intracranial

hypertension and cerebral edema associated with severe PMS.

Many studies implicate progesterone as a provoking factor in PMS. Redei and Freeman [13] found that premenstrual symptoms occur 3–5 days after the progesterone plateau, consistent with our finding. Thus a fall in progesterone may be triggering factor for PMS symptoms. In addition, increased estradiol levels during the luteal phase were found to be positively correlated with the more severe symptoms when compared with cycles in the same individuals with low luteal-phase estradiol levels [14]. Some studies did not find any differences in the plasma levels of estradiol and progesterone between women with PMS and controls [15], but levels of those hormones were measured only once in the luteal phase. Smith and colleagues [16] suggested the absence of an abnormality in dynamic ovarian function as measured by gonadotropin-releasing hormone (GnRH) stimulation. In contrast, we found a direct correlation between the progesterone fall, peaks of prolactin and insulin and epileptic seizures in our patient. Other studies have confirmed that progesterone stimulates dopamine release in striatal tissue [17] and GnRH release from hypothalamic neurons [18] but inhibits opioid receptor binding and activity and reduces meningeal release of substance P [19], thereby inhibiting the development of neurogenic edema. There is evidence that progesterone metabolites interact with the γ -aminobutyric acid (GABA) receptor subtype A and serotonergic systems, and both systems appear to be involved in the pathophysiology of PMS [20]. Activation of the GABA_A receptor makes the cell membrane permeable to chloride ions and produces strong sedating and anticonvulsive effects, as was found with our patient during the progesterone plateau. Thus, the abrupt decrease of progesterone levels could have been one of the triggering factors for epileptic seizures in our patient.

Progesterone increases hypothalamic serotonin content [21]. Several symptoms encountered in PMS resemble those of a possible serotonergic deficiency. Brzezinski and associates found fenfluramine to be effective in alleviating PMS [22]. This has been confirmed with tricyclic antidepressants that have a serotonergic profile and with selective serotonin-reuptake inhibitors (SSRIs). Pearlstein and Stone [23] found that approximately half of their subjects achieved complete remission of PMS symptoms and concluded that SSRIs should be the first-line treatment for PMS. Unfortunately, this therapy was unsuccessful in our patient.

Our patient felt depressed during the first 3 months of pregnancy but had no intracranial hypertension, problems with vision or epileptic seizures, suggesting that the fall in progesterone rather than high progesterone levels *per se* is an etiological factor for PMS. During pregnancy a large number of PMS patients report symptom

relief, perhaps due to high and non-fluctuating levels of estradiol and progesterone [24].

The sex hormones in Yasmin[®] interfere with the RAAS in two ways. First, ethinyl estradiol stimulates the production of angiotensinogen-induced increases of angiotensin II, aldosterone and body weight. Second, drospirenone antagonizes the sodium-retaining effects of ethinyl estradiol, by antiminerlocorticoid effects in the kidneys [25] inducing natriuresis that partly counteracts the suppressive effect of angiotensin II on renin concentrations. While taking Yasmin[®], our patient's body weight decreased by 5 kg during the luteal phase of the cycle. These findings are in agreement with previous studies [26]. Blood pressure in our patient remained unchanged, as was observed in other studies [27]. Aldosterone may possibly have deleterious effect on the vasculature by modifying endothelial function and affecting vascular remodeling, particularly by fibrosis. So, aldosterone antagonism could be of potential benefit in women with severe PMS.

The brain RAAS had been found to be involved in the modulation of cardiovascular and fluid–electrolyte homeostasis, generally complementary to the classical roles of the endocrine RAAS. RAAS has additionally been implicated in memory, cognition and stress, modulating the activity of the autonomic nervous system, the hypothalamic–pituitary axis, baroreflex sensitivity and vasopressin release. The brain RAAS is physically separated from the systemic endocrine RAAS by the blood–brain barrier. Circulating angiotensin II may, however, transmit effects inside the brain through areas lacking the blood–brain barrier [28]. Cerebral edema can be partly explained by effects of the angiotensin II and drospirenone counteracts it. Angiotensinogen, the only known source of angiotensin, is produced in the hypothalamus and brain stem, which are important for the central control of homeostasis. The involvement of angiotensin II in the circadian regulation of vascular tone by inducing the circadian expression of clock genes in vascular smooth muscle has been recently suggested [29]. Antisense oligodeoxynucleotides against angiotensinogen or AT1 mRNA administered into the brain reduce hypertension and may protect spontaneously hypertensive rats against cerebral ischemia [30]. Therefore, intracranial hypertension and cerebral edema could be partly explained by this mechanism.

Eriksson and co-workers [31] found that an increase of free testosterone appears to be associated with premenstrual irritability, and our study confirms this (although insignificantly). Drospirenone has antiminerlocorticoid activity eight times greater than that of spironolactone, and antiandrogenic activity five to ten times greater than that of progesterone, but less than that of cyproteron acetate [32]. Although weak, this antiandrogenic activity probably counteracted the negative effects of androgens on hair growth and skin in our patient. These changes are probably due to

increased binding to SHBG. Ethinyl estradiol increases the level of SHBG, but drospirenone does not inhibit this induction.

As a history of thromboembolic disorders and existing blood coagulation disorders are contraindications for Yasmin[®], medical supervision is recommended when Yasmin[®] is administered to obese women with epilepsy. Our patient wishes to continue treatment with Yasmin[®] because no other drugs have helped her and she cannot continue as before. The prothrombotic effects of OCs may result from changes in hemostatic parameters (an increase in procoagulant effects, a decrease in anticoagulant effects, and equivocal effects on fibrinolysis with increases in antifibrinolytic activity) [33]. The same dose of anticoagulants in the cycle with/without Yasmin[®] indicates well-maintained hemostatic equilibrium, meaning that the high rate of turnover of coagulation factors and similar activation of the coagulatory and fibrinolytic aspects of the hemostatic system do not translate into significantly increased risk of venous thromboembolism. Thus, prophylactic fractionated heparin to allow use of the pill would be the best therapeutic choice.

Conclusion

Dynamic hormonal changes prior to menstruation, with a crucial progesterone fall, can trigger instability in serotonergic homeostasis and changes in mineralocorticoid pathways leading to PMS symptoms, also including intracranial hypertension, cerebral edema and epileptic seizures. No sole role of any system can be assumed. PMS is likely to be a multifaceted syndrome with impairment in many biological parameters.

In our patient, administration of Yasmin[®] (ethinyl estradiol and drospirenone) resulted in a significant reduction in the incidence of severe PMS symptoms during all phases of the menstrual cycle, but particularly during the luteal phase. Symptoms of fluid retention (weight gain, breast tenderness, breast and abdominal swelling), negative psychological effects (comprising feelings of loneliness, sadness, tearfulness, moodiness, anxiety, irritability, restlessness), acne, food craving, and even epileptic seizures and cerebral edema improved, indicating the beneficial effect of Yasmin[®] in one woman. This appears a useful means to improve the quality of life for our patient.

References

1. Panay N, Studd J. Progesterone intolerance in the treatment of severe premenstrual syndrome. In: The 11th World Congress of Gynecological Endocrinology, 2004, Florence. London: The Parthenon Publishing Group; 2004. p 177.
2. Hammarback S, Ekholm UB, Backstrom T. Spontaneous anovulation causing appearance of cyclical symptoms in women with PMS. *Acta Endocrinol* 1991;125:132–137.
3. Studd JWW. Premenstrual syndrome. *Br Med J* 1979;1:410–415.

4. Backstrom T, Boyle H, Baird DT. Persistence of symptoms of premenstrual tension in hysterectomized women. *Br J Obstet Gynaecol* 1981;88:530–536.
5. Vujovic S. No evidence of premenstrual syndrome in female-to-male transsexuals. *Gender Dysphoria* 1992;2:56–68.
6. Poort SR, Rosental FR, Reitsma PH, Bertina RN. A common genetic variation in the 3-transected region of prothrombin gene is associated with elevated plasma prothrombin level and increase in venous thrombosis. *Blood* 1996;88:3698–3703.
7. Soria JM, Almasy L, Souto JC, Tirado I, Borell M, Mateo J, Slifer S, Stone W, Blangero J, Fountcuberta J. Linkage analysis demonstrates that the prothrombin G20210A mutation jointly influences plasma prothrombin levels and risk of thrombosis. *Blood* 2000;95:2780–2785.
8. Carhuapoma JR, Mitsias P, Levine SR. Cerebral venous thrombosis and anticardiolipin antibodies. *Stroke* 1997;28:2363–2369.
9. Moos RH. The development of a menstrual distress questionnaire. *Psychosom Med* 1968;30:853–867.
10. Mortola JF, Girton L, Beck L, Yen SS. Diagnosis of premenstrual syndrome by a simple, prospective and reliable instrument: the calendar of premenstrual experience. *Obstet Gynecol* 1990;76:302–307.
11. Leker RR, Steiner I. Anticardiolipin antibodies are frequently present in patients with idiopathic intracranial hypertension. *Arch Neurol* 1998;55:817–820.
12. Vujovic S. Ultrasonografske i funkcionalne karakteristike ovarijuma u žena sa predmenstrucionim sindromom [dissertation], Beograd: University of Beograd; 1991.
13. Redei E, Freeman EW. Daily plasma estradiol and progesterone levels over the menstrual cycle and their relation to premenstrual symptoms. *Psychoneuroendocrinology* 1995;20:259–267.
14. Hammaback S, Damber JE, Backstrom T. Relationship between symptom severity and hormone changes in women with premenstrual syndrome. *J Clin Endocrinol Metab* 1989;68:125–130.
15. Backstrom T, Sanders D, Leask R, Davidson D, Warner P, Bancroft J. Mood, sexuality, hormones and the menstrual cycle. II. Hormone levels and their relationship to the premenstrual syndrome. *Psychosom Med* 1983;45:503–507.
16. Smith MJ, Schmidt PJ, Su T-P, Rubinow DR. Gonadotropin releasing hormone-stimulated gonadotropin levels in women with premenstrual dysphoria. *Gynecol Endocrinol* 2004;19:335–343.
17. Petittlerc M, Bedard PJ, Di Paolo T. Progesterone releases dopamine in male and female rat striatum. A behavioural and microdialysis study. *Prog Neuropsychopharmacol Biol Psychiatry* 1995;19:491–497.
18. Sinchak K, Micevych PE. Progesterone blockade of estrogen activation of μ -opioid receptors regulates reproductive behaviour. *J Neurosci* 2001;21:5723–5729.
19. Limmroth U, Lee WS, Moskowitz MA. GABA-A receptor-mediated effects of progesterone, its ring-A-reduced metabolites and synthetic neuroactive steroids on neurogenic oedema in the rat meninges. *Br J Pharmacol* 1996;117:99–104.
20. Genazzani AR, Stomati M, Morittu A, Bernardi F, Monteleone P, Casarosa E, Gallo R, Salvestroni C, Luisi M. Progesterone, progestogens and the central nervous system. *Hum Reprod* 2000;15(Suppl): 14–27.
21. Walker RF, Wilson CA. Changes in hypothalamic serotonin associated with amplification of LH-surges by progesterone in rats. *Neuroendocrinology* 1983;37:200–205.
22. Brzezinski AA, Wurtman JJ, Wurtman RJ, Gleason R, Greenfield J, Nader T. D-Fenfluramine suppresses the increased calorie and carbohydrate intakes and improves the mood of women with premenstrual depression. *Obstet Gynecol* 1990;76:296–301.
23. Pearlstein TB, Stone AB. Long-term fluoxetine treatment of late luteal phase dysphoric disorder. *J Clin Psychiatry* 1994;55:332–335.
24. Corney RH, Stanton R. A survey of 658 women who report symptoms of premenstrual syndrome. *J Psychosom Res* 1991;35:471–482.
25. Oelkers W, Helmerhorst FM, Wuttke W. Effects of an oral contraceptive containing drospirenone on the rennin-angiotensin-aldosterone system in healthy female volunteers. *Gynecol Endocrinol* 2000;16:204–213.
26. Freeman EW, Kroll R, Rapkin A, Pearlstein T, Brown C, Parsey K, Zhang P, Patel H, Foegh M; PMS/PMDD Research Group. Evaluation of a unique oral contraceptive in the treatment of premenstrual dysphoric disorder. *J Womens Health Gen Based Med* 2001;10:561–569.
27. Apter D, Borsos A, Baumgartner W, Melis GB, Vexiau-Robert D, Colligs-Hakert A, Palmer M, Kelly S. Effect of an oral contraceptive containing drospirenone and ethinylestradiol on general wellbeing and fluid-related symptoms. *Eur J Contracept Reprod Health Care* 2003;8:37–51.
28. Baltatu O, Bade M. Brain rennin-angiotensin system. *Neuroendocrinology* 2003;78:253–259.
29. Nanaka E, Emoto N, Iheda K, Fukuya H, Rohman MS, Raharjo SB, Yagita K, Okamura H, Yokoyama M. Angiotensin II induces circadian gene expression of clock genes in culture of vascular smooth muscle cells. *Circulation* 2001;104:1746–1748.
30. Yamakawa H, Phillips MI, Saavedra JM. Intracisternal administration of angiotensin II AT (1) receptor antisense oligodeoxynucleotides protects against cerebral ischemia in spontaneously hypertensive rats. *Regul Pept* 2003;111:117–122.
31. Eriksson KT, Simblad C, Lispo P, Modigh K, Andersch B. Serum levels of androgen are higher in women with premenstrual irritability and dysphoria than in controls. *Psychoneuroendocrinology* 1992;17:195–204.
32. Muhn P, Fuhrmann U, Fritzscheier KH, Krattenmacher R, Schillinger E. Drospirenone: a novel progestogen with antiminerlocorticoid and antiandrogen activity. *Ann N Y Acad Sci* 1995;761:311–335.
33. Vandembroucke JP, Rosing J, Bloemenkamp KW, Middeldorp S, Helmerhorst FM, Bouma BN, Rosendaal FR. Oral contraceptives and the risk of venous thrombosis. *N Engl J Med* 2001;344:1527–1535.