

Acute Subdural Hematoma After Intra-arterial Thrombolysis for Acute Ischemic Stroke

—Case Report—

Toshinari MEGURO, Hisato HIGASHI, and Ken NISHIMOTO

Department of Neurological Surgery, Sumitomo Besshi Hospital, Niihama, Ehime

Abstract

A 79-year-old man with a cardiac pacemaker for bradycardia fell down and presented with sudden onset of right hemiplegia and aphasia. Initial computed tomography (CT) showed no cerebral infarction but angiography revealed occlusion of the left middle cerebral artery (MCA). Local intra-arterial thrombolysis with tissue plasminogen activator (tPA; tisokinase, 1,600,000 units) was performed 3 hours after the onset, and the MCA was partially recanalized. Further administration of tPA was suspended because of nosebleed. However, the patient's neurological findings did not improve. His consciousness gradually deteriorated to coma and quadriplegia with dilation of the left pupil 2.5 hours after thrombolysis. CT disclosed marked mass effect with a left acute subdural hematoma and a small intracerebral hematoma in the left frontal lobe. He underwent urgent craniotomy and removal of the subdural hematoma. The subdural hematoma originated in a frontal cerebral contusion. He died of severe brain edema 2 days after surgery. Acute subdural hematoma is a very rare complication of intra-arterial thrombolysis. Presumably he had suffered head trauma at the first onset. Evidence of head trauma should be considered a contraindication for the use of thrombolytic agents in a patient with acute stroke.

Key words: acute subdural hematoma, thrombolysis, tissue plasminogen activator, stroke, trauma

Introduction

Intra-arterial thrombolysis is an accepted treatment for selected acute ischemic stroke. The most serious complication of intra-arterial thrombolysis is intracranial hemorrhage, which mostly occurs as parenchymal hematoma or hemorrhagic infarction.^{2,3,10} Acute subdural hematoma is extremely rare. We report a case of acute subdural hemorrhage with poor outcome as a complication of intra-arterial thrombolysis.

Case Report

A 79-year-old man suddenly lost consciousness and fell down at home. He was transferred to our hospital 45 minutes later. He had undergone implantation of a cardiac pacemaker for bradycardia 12 years previously but had received no anticoagulant therapy. On admission, his consciousness was 10 (E:

4, V: 1, M: 5) on the Glasgow Coma Scale. He presented with right hemiplegia and aphasia. According to his family he had had a small nosebleed, but he did not show apparent external injuries on admission.

Initial computed tomography (CT) showed no signs of ischemic change (Fig. 1). Subsequent cerebral angiography demonstrated occlusion of the left middle cerebral artery (MCA) (Fig. 2A, B). The patient received an intravenous bolus of heparin (5,000 units). A microcatheter mounted on a guide-wire was passed through the clot to the distal side, where 80,000 units of tissue plasminogen activator (tPA; tisokinase) were delivered by hand injection. The microcatheter was then slowly withdrawn to the proximal side of the clot and another 80,000 units of the tPA were injected. By this time, 3 hours had passed from symptom onset and partial lysis of the clot had occurred (Fig. 2C, D). Unfortunately, we were forced to discontinue administration of tPA

Received December 10, 2004; Accepted May 23, 2005

Author's present address: T. Meguro, M.D., Department of Neurological Surgery, Hiroshima City Hospital, Hiroshima, Hiroshima, Japan.

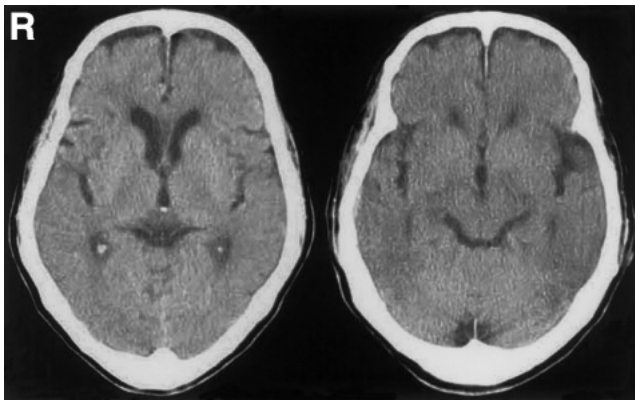


Fig. 1 Initial computed tomography scans showing no signs of ischemic change.

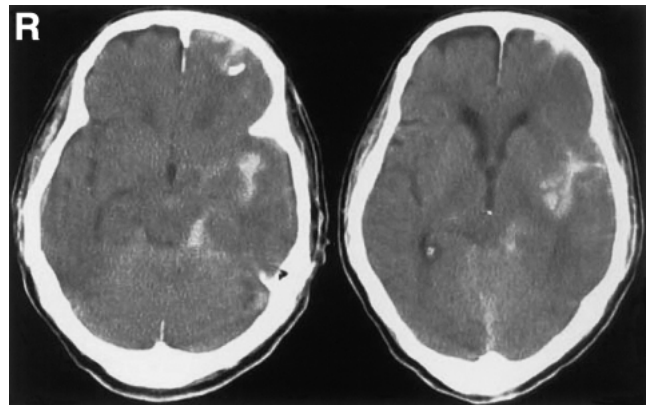


Fig. 3 Second computed tomography scans immediately after thrombolysis showing hemorrhagic infarction in the territory of the recanalized middle cerebral artery and intracerebral hemorrhage in the frontal lobe.

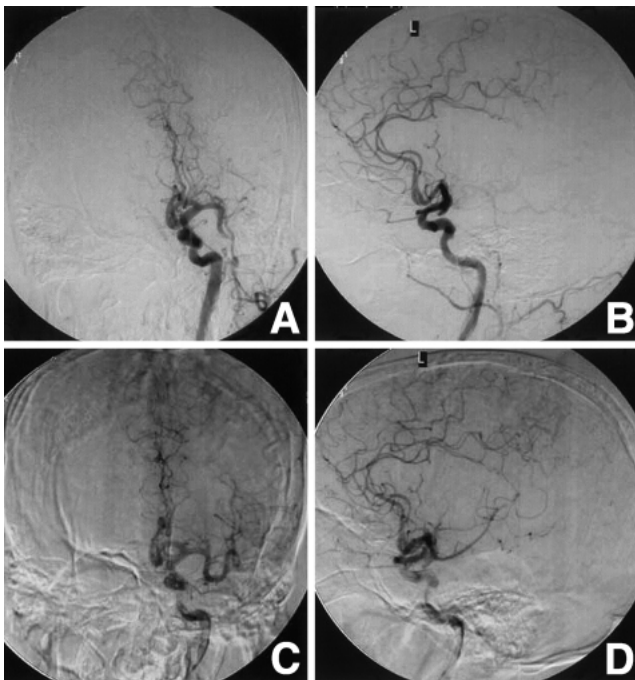


Fig. 2 Initial left carotid angiograms (A: anteroposterior view, B: lateral view) showing occlusion of the left middle cerebral artery from a cardiac embolus. Left carotid angiograms (C: anteroposterior view, D: lateral view) after thrombolysis showing partial lysis of the clot in the left middle cerebral artery.

after the initial tPA injection because he had a nosebleed. His nosebleed stopped spontaneously before long, but subcutaneous hemorrhage in his right forehead had become obvious. His neurological findings did not improve after the thrombolysis. Second CT immediately after thrombolysis showed hemorrhagic infarction in the territory of the

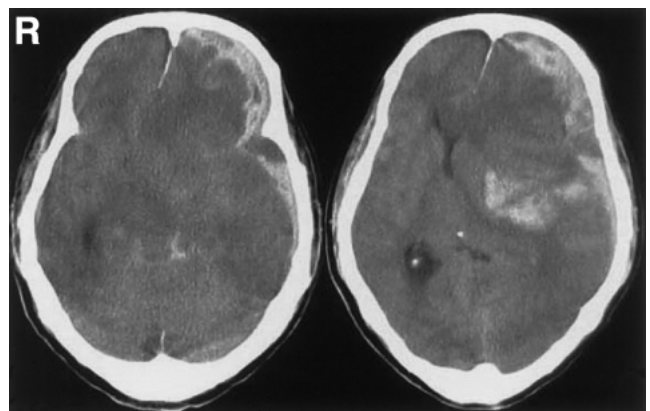


Fig. 4 Third computed tomography scans 2.5 hours after thrombolysis disclosing left acute subdural hematoma with marked mass effect and brain shift.

recanalized MCA and intracerebral hemorrhage in the frontal lobe, in which no microcatheter or guide-wire had been inserted (Fig. 3).

The patient's consciousness gradually deteriorated to coma and quadriplegia with dilation of the left pupil 2.5 hours after thrombolysis. Third CT disclosed a left acute subdural hematoma with marked mass effect and brain shift (Fig. 4). He underwent urgent craniotomy for evacuation of the subdural hematoma. A large craniotomy flap was made on the left. After evacuation of thick hematoma, the surface of the brain around the sylvian fissure was found to be edematous with partial subarachnoid hemorrhage. However, the arachnoid membrane in the

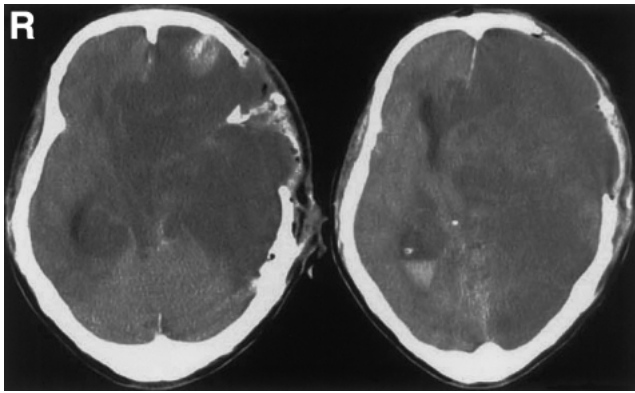


Fig. 5 Computed tomography scans 8 hours after the craniotomy demonstrating severe brain swelling with shift of the whole left cerebral hemisphere.

region was not damaged. The parenchymal and arachnoid laceration was located on the anterior surface of the frontal lobe, and communicated with the subdural hematoma.

Postoperatively, the patient showed no improvement of neurological deficit. CT 8 hours after the craniotomy demonstrated severe brain swelling with shift of the whole left cerebral hemisphere (Fig. 5). The patient died 2 days after the craniotomy.

Discussion

Intravenous administration of thrombolytic agent does not increase mortality or morbidity, despite a 2 to 2.5 fold increase in symptomatic intracranial hemorrhage.^{5,8)} A randomized trial of recombinant pro-urokinase by intra-arterial thrombolysis showed significant improvement in clinical outcome at 90 days. However, intracranial hemorrhage with neurological deterioration within 24 hours occurred in 10% of patients treated with recombinant pro-urokinase and 2% of control patients.²⁾ Only hemorrhagic infarction or parenchymal hemorrhage has been described as a complication of intravenous or intra-arterial thrombolysis for acute ischemic stroke.

Acute subdural hematoma is one of the complications of thrombolysis for acute myocardial infarction, occurring in 0.1% to 0.2% of cases of thrombolytic therapy using intravenous recombinant tPA, and is generally related to head trauma.^{4,6)} CT is essential to identify ischemic stroke, but not acute myocardial infarction. Evidence of intracranial hemorrhage on pretreatment CT is one of the most important contraindications for the use of tPA in patients with acute ischemic stroke.¹⁾

Our patient was bleeding a little at the nose when he lost consciousness, but his nosebleed had stopped, and he had no external injuries on arrival to our hospital. Initial CT unfortunately did not reveal any signs of intracranial bleeding. Cerebral contusion appeared in the patient's left frontal lobe, and acute subdural hematoma developed after the thrombolysis. CT immediately after injury does not always detect intracranial hemorrhage. Twenty-five cases of traumatic intracerebral hematoma with delayed onset, all identified with CT, were found among 775 cases of acute head injury.⁹⁾ It is possible that patients with acute ischemic stroke had suffered head trauma before onset. Late onset of intracranial hemorrhage is one of the pitfalls of thrombolysis for acute ischemic stroke, as the earlier the start of thrombolysis from onset, the better the results.

Direct percutaneous transluminal angioplasty (PTA) or clot retrieval in acute stroke is an additional or alternative option to thrombolysis for patients with acute main trunk occlusion.^{7,11,12)} Direct PTA or clot retrieval without tPA or urokinase may be better for the treatment of patients with acute ischemic stroke who might have suffered head trauma.

Acknowledgment

We would like to thank Dr. Nobuyuki Hirotsune (Department of Neurological Surgery, Hiroshima City Hospital, Hiroshima) for helpful suggestions and comments.

References

- 1) Broderick JP, Hacke W: Treatment of acute ischemic stroke: Part I: recanalization strategies. *Circulation* 106: 1563-1569, 2002
- 2) Furlan A, Higashida R, Wechsler L, Gent M, Rowley H, Kase C, Pessin M, Ahuja A, Callahan F, Clark WM, Silver F, Rivera F: Intra-arterial prourokinase for acute ischemic stroke. The PROACT II study: a randomized controlled trial. *Prolyse in Acute Cerebral Thromboembolism. JAMA* 282: 2003-2011, 1999
- 3) Gonner F, Remonda L, Mattle H, Sturzenegger M, Ozdoba C, Lovblad KO, Baumgartner R, Bassetti C, Schroth G: Local intra-arterial thrombolysis in acute ischemic stroke. *Stroke* 29: 1894-1900, 1998
- 4) Gore JM, Sloan M, Price TR, Randall AM, Bovill E, Collen D, Forman S, Knatterud GL, Sopko G, Terrin ML: Intracerebral hemorrhage, cerebral infarction, and subdural hematoma after acute myocardial infarction and thrombolytic therapy in the Thrombolysis in Myocardial Infarction Study. *Thrombolysis in Myocardial Infarction, Phase II, pilot and clinical trial. Circulation* 83: 448-459, 1991
- 5) Hacke W, Kaste M, Fieschi C, von Kummer R,

- Davalos A, Meier D, Larrue V, Bluhmki E, Davis S, Donnan G, Schneider D, Diez-Tejedor E, Trouillas P: Randomised double-blind placebo-controlled trial of thrombolytic therapy with intravenous alteplase in acute ischaemic stroke (ECASS II). Second European-Australasian Acute Stroke Study Investigators. *Lancet* 352: 1245-1251, 1998
- 6) Kase CS, Pessin MS, Zivin JA, del Zoppo GJ, Furlan AJ, Buckley JW, Snipes RG, Little John JK: Intracranial hemorrhage after coronary thrombolysis with tissue plasminogen activator. *Am J Med* 92: 384-390, 1992
- 7) Nakano S, Iseda T, Yoneyama T, Kawano H, Wakisaka S: Direct percutaneous transluminal angioplasty for acute middle cerebral artery trunk occlusion: an alternative option to intra-arterial thrombolysis. *Stroke* 33: 2872-2876, 2002
- 8) The National Institute of Neurological Disorders and Stroke rt-PA Stroke Study Group: Tissue plasminogen activator for acute ischemic stroke. *N Engl J Med* 333: 1581-1587, 1995
- 9) Ninchoji T, Uemura K, Shimoyama I, Hinokuma K, Bun T, Nakajima S: Traumatic intracerebral haematomas of delayed onset. *Acta Neurochir (Wien)* 71: 69-90, 1984
- 10) Suarez JI, Sunshine JL, Tarr R, Zaidat O, Selman WR, Kernich C, Landis DM: Predictors of clinical improvement, angiographic recanalization, and intracranial hemorrhage after intra-arterial thrombolysis for acute ischemic stroke. *Stroke* 30: 2094-2100, 1999
- 11) Ueda T, Sakaki S, Nochide I, Kumon Y, Kohno K, Ohta S: Angioplasty after intra-arterial thrombolysis for acute occlusion of intracranial arteries. *Stroke* 29: 2568-2574, 1998
- 12) Wikholm G: Transarterial embolectomy in acute stroke. *AJNR Am J Neuroradiol* 24: 892-894, 2003

Address reprint requests to: T. Meguro, M.D., Department of Neurological Surgery, Hiroshima City Hospital, 7-33 Moto-machi, Naka-ku, Hiroshima, Hiroshima 730-8518, Japan.
e-mail: tmeguron@hotmail.com