


This article was downloaded by: [The Aga Khan University]

On: 27 December 2014, At: 04:09

Publisher: Routledge

Informa Ltd Registered in England and Wales Registered Number: 1072954 Registered office: Mortimer House, 37-41 Mortimer Street, London W1T 3JH, UK



## Neurocase: The Neural Basis of Cognition

Publication details, including instructions for authors and subscription information:

<http://www.tandfonline.com/loi/nncs20>

### Pathophysiology of language switching and mixing in an early bilingual child with subcortical aphasia

Peter Mariën<sup>a b</sup>, Jubin Abutalebi<sup>c d</sup>, Sebastiaan Engelborghs<sup>a</sup> & Peter P. De Deyn<sup>a</sup>

<sup>a</sup> Department of Neurology, General Hospital Middelheim, Antwerp, and Laboratory of Neurochemistry and Behaviour, Born-Bunge Foundation, University of Antwerp, Belgium

<sup>b</sup> Department of Linguistics, Free University of Brussels, Belgium

<sup>c</sup> Centre for Cognitive Neuroscience, Psychology Department, University Vita-Salute San Raffaele, Milan, Italy

<sup>d</sup> Interdisciplinary Center for Cognitive Studies, University of Potsdam, Germany

Published online: 16 Feb 2007.

To cite this article: Peter Mariën, Jubin Abutalebi, Sebastiaan Engelborghs & Peter P. De Deyn (2005) Pathophysiology of language switching and mixing in an early bilingual child with subcortical aphasia, *Neurocase: The Neural Basis of Cognition*, 11:6, 385-398, DOI: [10.1080/13554790500212880](https://doi.org/10.1080/13554790500212880)

To link to this article: <http://dx.doi.org/10.1080/13554790500212880>

PLEASE SCROLL DOWN FOR ARTICLE

Taylor & Francis makes every effort to ensure the accuracy of all the information (the "Content") contained in the publications on our platform. However, Taylor & Francis, our agents, and our licensors make no representations or warranties whatsoever as to the accuracy, completeness, or suitability for any purpose of the Content. Any opinions and views expressed in this publication are the opinions and views of the authors, and are not the views of or endorsed by Taylor & Francis. The accuracy of the Content should not be relied upon and should be independently verified with primary sources of information. Taylor and Francis shall not be liable for any losses, actions, claims, proceedings, demands, costs, expenses, damages, and other liabilities whatsoever or howsoever caused arising directly or indirectly in connection with, in relation to or arising out of the use of the Content.

This article may be used for research, teaching, and private study purposes. Any substantial or systematic reproduction, redistribution, reselling, loan, sub-licensing, systematic supply, or distribution in any form to anyone is expressly forbidden. Terms & Conditions of access and use can be found at <http://www.tandfonline.com/page/terms-and-conditions>

# Pathophysiology of language switching and mixing in an early bilingual child with subcortical aphasia

PETER MARIËN<sup>1,2</sup>, JUBIN ABUTALEBI<sup>3,4</sup>, SEBASTIAAN ENGELBORGH<sup>1</sup> and PETER P. DE DEYN<sup>1</sup>

<sup>1</sup>Department of Neurology, General Hospital Middelheim, Antwerp, and Laboratory of Neurochemistry and Behaviour, Born-Bunge Foundation, University of Antwerp, Belgium

<sup>2</sup>Department of Linguistics, Free University of Brussels, Belgium

<sup>3</sup>Centre for Cognitive Neuroscience, Psychology Department, University Vita-Salute San Raffaele, Milan, Italy

<sup>4</sup>Interdisciplinary Center for Cognitive Studies, University of Potsdam, Germany

Acquired aphasia after circumscribed vascular subcortical lesions has not been reported in bilingual children. We report clinical and neuroimaging findings in an early bilingual boy who incurred equally severe transcortical sensory aphasia in his first language (L1) and second language (L2) after a posterior left thalamic hemorrhage. Following recurrent bleeding of the lesion the aphasic symptoms substantially aggravated. Spontaneous pathological language switching and mixing were found in both languages. Remission of these phenomena was reflected on brain perfusion SPECT revealing improved perfusion in the left frontal lobe and left caudate nucleus. The parallelism between the evolution of language symptoms and the SPECT findings may demonstrate that a subcortical left frontal lobe circuitry is crucially involved in language switching and mixing.

## Introduction

Although etiologies are similar, the relative incidences of acquired aphasia in adults and children are quite different. Cerebrovascular disorders are rare in the paediatric age group (incidence of 2–3 cases per 100,000 children per year according to Schoenberg *et al.*, 1978), and consequently, vascular acquired aphasia (AAC) is a rare phenomenon in this population.

While subcortical aphasia has been extensively studied in adults with vascular lesions (for a review see Cappa and Abutalebi, 1999), only a few childhood cases have been reported (Ferro *et al.*, 1982; Aram *et al.*, 1983; Cranberg *et al.*, 1987; Van Lieshout *et al.*, 1990; Martins *et al.*, 1993; Garg and DeMyer, 1995; Kieffer-Renaud *et al.*, 1996; Nass *et al.*, 2000). In further contrast to a long-standing tradition in the study of adult aphasia, the literature is sparse with regard to bilingual or polyglot aphasia in children (Bouquet *et al.*, 1981; Fabbro and Paradis, 1995).

Recent studies of bilingual aphasia have brought to the fore that the subcortical nuclei of the language dominant hemisphere might be implicated in pathological language

mixing (pLM) (uncontrolled mixing of elements of two languages within a single utterance) and pathological language switching (pLS) (uncontrolled alternation of utterances from one language to the other across sentence boundaries) (Aglioti *et al.*, 1993; 1996; Fabbro *et al.*, 1997; Abutalebi *et al.*, 2000). Since pLM and pLS may contribute to the insight of the neural representation of switching and language selection mechanisms in bilinguals, both phenomena have recently attracted increased interest. However, all indications for a crucial role of the subcortical nuclei in language mixing and language switching have been derived from lesion studies in adults. On the other hand, evidence from functional neuroimaging in healthy bilingual subjects pointed to the left prefrontal cortex as the main anatomical determinant of the language switching (Hernandez *et al.*, 2001) and language selection mechanism in bilinguals (Rodriguez-Fornells *et al.*, 2002; but see also Grosjean *et al.*, 2003).

On the basis of a close neurolinguistic and SPECT follow-up study we investigated an early bilingual child with subcortical aphasia and pLM and pLS due to two subcortical strokes. Neurolinguistic and SPECT results in this first case of subcortical bilingual AAC with pLM and pLS are reported with two aims: (i) to present the semiological characteristics of subcortical bilingual AAC with pLM and pLS, and (ii) to enrich the debate on the pathophysiological mechanisms underlying language switching and language mixing. The results are discussed in relation to (i) AAC data published over the past 25 years and to (ii) anatomoclinical and experimental data indicating a crucial role of the subcortical nuclei in language mixing and language switching.

---

Received 17 February 2005; accepted 13 June 2005

We are indebted to Mrs. H. Baillieux (Free University of Brussels) and I. Bats (Born-Bunge Foundation, University of Antwerp) for the photographic work. S.Engelborghs is a Ph. D fellow of the Fund for Scientific Research - Flanders (F.W.O. - Vlaanderen)

Address correspondence to Prof Peter Mariën, A.Z. Middelheim, Department of Neurology, Lindendreef 1, 2020 Antwerp, Belgium. E-mail: petermarien@skynet.be

## Case report

### *Clinical history*

A 10-year-old, right-handed boy, EM, was admitted to our hospital in May, 2002 because of coma following a short episode of agitation with vomiting. Medical history, growth and development were normal. EM was born at term after normal gestation and labor and there had been no perinatal or postnatal problems. His scholastic achievements had always been average and there was no familial history of developmental disorders or learning disabilities. As an early bilingual, EM was educated in English (L1) (parental native language) and from the age of two and a half years onwards also in Dutch (L2). He consistently communicated with his parents and nearest relatives in L1 while L2 was primarily used at school and with friends. As testified by his parents, schoolteachers and private teachers, his premorbid oral proficiency was good for both his maternal language and L2. Premorbid reading and writing skills were at age-appropriate levels in L2 in which he received scholastic education whereas EM had not received any formal education in written English.

The patient was sedated (midazolam) and intubated before arrival at our hospital. Both pupils were equally miotic and non-reactive to light. A computerized tomography (CT) scan of the brain disclosed a left thalamic hemorrhage extending into the lateral, third and fourth ventricles. As the CT scan revealed signs of obstructive hydrocephalus (dilatated lateral ventricles), an external ventricular drain was installed. In addition to the left subcortical hemorrhage, repeat CT on the first day of admission showed perilesional edema with mass-effect and mid-line shift to the right. The ventricular volume had decreased compared to the pre-shunt images. He was detubated seven days after admission. Aside from severe aphasia in both L1 and L2, the neurological examination revealed right hemiplegia with right-sided hyperreflexia and central facial nerve palsy. Brain magnetic resonance imaging (MRI) three weeks post stroke revealed edema over the entire left hemisphere with minimal midline shift to the right. In addition, a left posterior thalamic hemorrhage was shown including the pulvinar and the nucleus ventralis posterior. The nucleus medialis of the thalamus was partially involved. Residual blood was visualized in both frontal and occipital horns of the lateral ventricles. Periventricular white matter lesions were found as well (Figure 1A). Conventional four-vessel angiography demonstrated a left thalamic AVM.

Intensive physical and speech therapy, which predominantly consisted of lexical-semantic therapy, were started on a daily basis. Although no speech therapy was given in L1, L1 recuperated to premorbid proficiency levels within a fortnight. By contrast, language recovery in L2 was incomplete and fluent aphasia persisted. Neurologically, only a slight paresis of the left leg was found three months after stroke. At the beginning of October 2002, partial embolisation of the AVM was achieved.

Two months after embolisation—that is, five months after stroke—the boy was readmitted because of acute headache and marked exacerbation of motor and language symptoms when playing violin (December 2002). CT disclosed a thalamic hemorrhage with a diameter of 4.5 cm causing a slight midline shift. In addition to global aphasia in both L1 and L2 a right facial nerve paresis of central origin and a pronounced right hemiparesis were found. Within the next days global aphasia evolved to a fluent aphasia type that disrupted L1 and L2 in an equal way. In addition, the patient continuously intermingled words and clauses of L1 and L2 and inappropriately shifted from one language to the other spontaneously. Brain imaging by means of SPECT showed a relative left hemisphere hypoperfusion most pronounced in the fronto-parietal and temporal regions and in the left caudate nucleus. A perfusion defect was found in the left thalamus and the lenticular nucleus and a relative hypoperfusion of the right hemicerebellum (crossed cerebellar diaschisis-CCD) (Figure 2A)

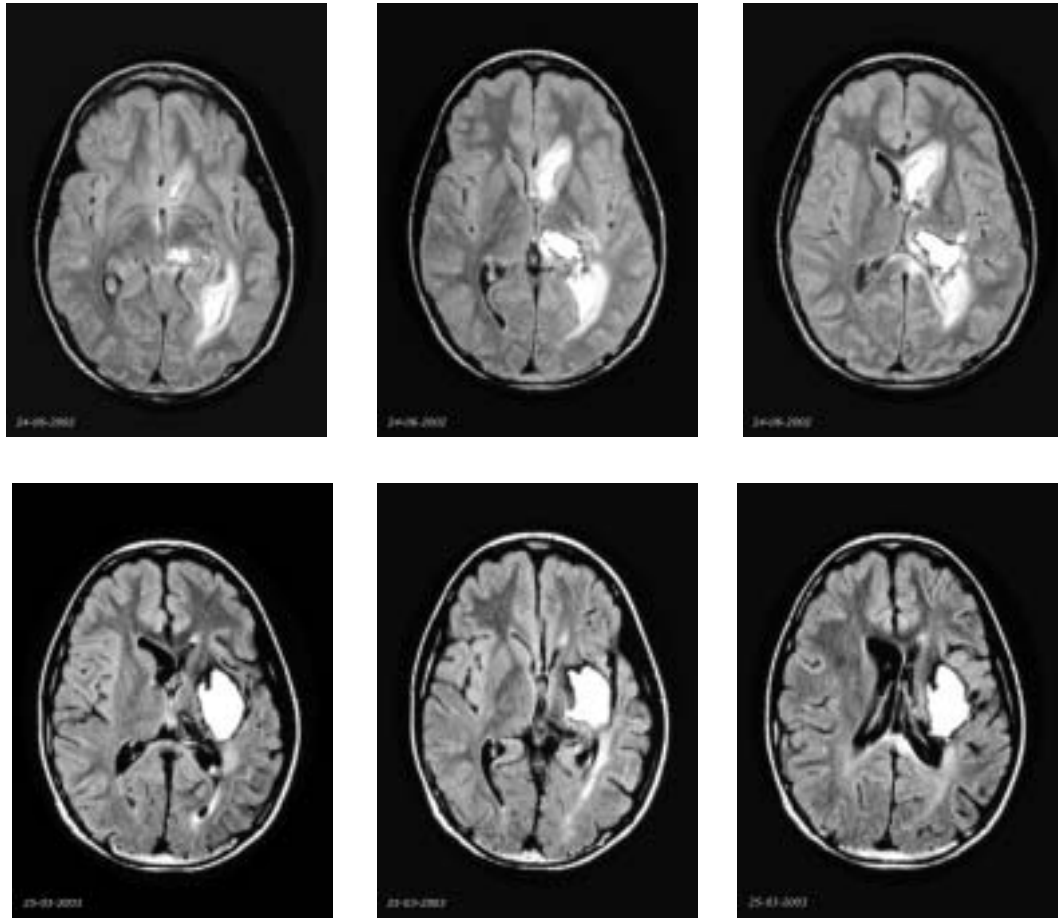
At the beginning of February 2003, partial re-embolisation of the AVM was successfully achieved and a single treatment of gamma-knife radiosurgery was performed a few weeks later. Although the patient still displayed fluent aphasia in L1 and L2, improvement was found when examined in the post-acute phase of the stroke. Spontaneous pLM and pLS remained, however, a very prominent feature of oral-verbal output. Four months after the second stroke (April 2003) repeat MRI showed destruction of the entire lateral posterior part of the left thalamus, internal capsule, putamen, claustrum, capsula extrema and posterior part of the insula. In addition, atrophy of the insular cortex and periventricular leucoencephalomalacia were found (Figure 1B).

Six months after the second stroke (June 2003) spontaneous pLM and pLS had remitted but fluent aphasia in L1 and L2 and a pronounced right hemiparesis persisted. Follow-up SPECT imaging revealed marked increase of tracer uptake in the left frontal region and a relative reperfusion of the left caudate nucleus while the perfusional deficits in the left temporal and parietal regions remained unchanged. Absence of perfusion in the left thalamus and crossed cerebellar diaschisis were again observed (Figure 2B).

## Cognitive investigations

### *Methods*

In agreement with a three epoch time-frame model of aphasia (Mazzocchi & Vignolo, 1979), we investigated language on a temporal basis. In the “acute phase” of the stroke, close behavioral follow-up and bedside screenings were performed. To avoid remote functional effects of the hemorrhagic lesion, generally accounting for the instability of the aphasia during the first two to three weeks post-onset (acute phase), more extensive language investigations were performed in the “lesion phase” at respectively seven and four



**Figure 1. A.** Brain MRI T1-weighted slices (from rostral to caudal) performed three weeks after the first stroke display a left posterior thalamic hemorrhage destroying the pulvinar and the nucleus ventralis posterior with partial involvement of the nucleus medialis. In addition, edema over the entire left hemisphere is shown with minimal midline shift to the right. Periventricular white matter lesions as well as residual blood in both frontal and occipital horns of the lateral ventricle are shown as well. **B.** Brain MRI T1-weighted slices (from rostral to caudal) performed four months after the second stroke reveal destruction of the entire lateral posterior part of the left thalamus, the internal capsule, the putamen, the claustrum, the capsula extrema and the posterior part of the insula. In addition, atrophy of the insular cortex and periventricular leucoencephalomalacia is demonstrated.

weeks after the first and second stroke. To capture various effects of recovery, language was reassessed in the “late phase”, six months after the second stroke. The neurolinguistic test battery consisted of the Aachen Aphasia Test (AAT) (Graetz *et al.*, 1992), the Boston Diagnostic Aphasia Examination (BDAE) (Goodglass & Kaplan, 1983), the Token Test (De Renzi & Vignolo, 1962), the Boston Naming Test (BNT) (Kaplan, Goodglass, & Weintraub, 1983; Mariën *et al.*, 1998), the Frenchay Aphasia Screening Test (FAST) (Enderby, *et al.*, 1986) and the Dutch-English version of the Bilingual Aphasia Test (BAT) (Bilingual Aphasia Test, Paradis, 1990).

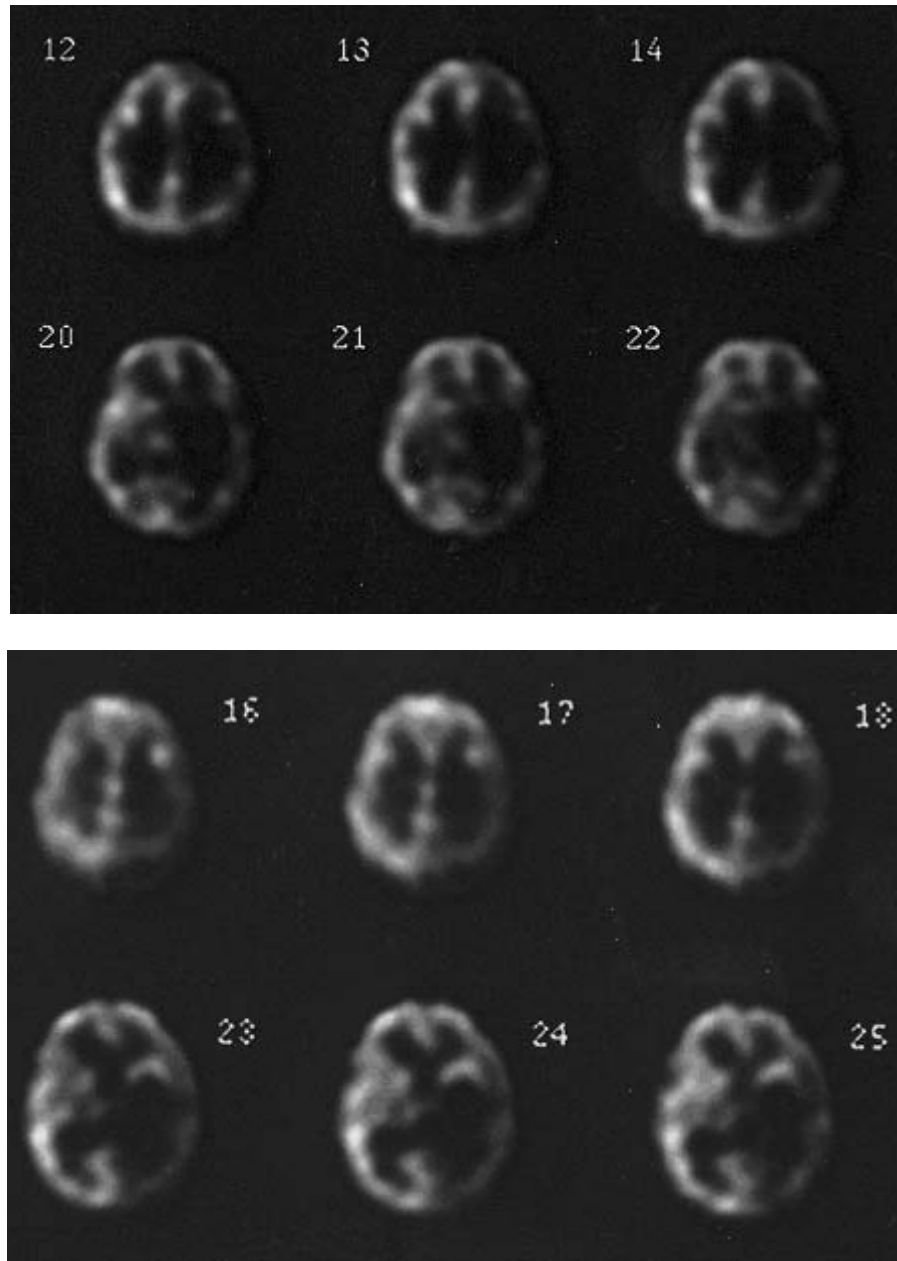
Neuropsychological investigations were performed in the lesion phase 11 weeks after the first and four weeks after the second stroke. Follow-up data were obtained in the late phase six months after the second stroke. The neuropsychological test battery comprised a selection of tests: the Wechsler Intelli-

gence Scale for Children-Revised (WISC-R), Rey’s 15 words, the Rey-Osterrieth figure, the Wisconsin Card Sorting Test (WCST) (Heaton *et al.*, 1993), the Stroop Color-Word test (Golden, 1978), the Trail Making Test and the Snijders-Oomen Non-verbal intelligence test (SON) (Snijders *et al.*, 1996). Handedness was formally assessed by means of the Edinburgh Inventory (Oldfield, 1971).

### Cognitive findings – stroke 1

#### Neurolinguistic findings

When the patient regained full consciousness, fluent aphasia disrupted L1 and L2. Failure to follow two-step verbal commands indicated that comprehension was only functional at elementary levels. Speech was markedly empty and characterized



**Figure 2.** Tc-99m-ECD SPECT performed in the acute phase (**A**) and late phase (**B**) of the second stroke. Acute phase data (top row, **A**) show a hypoperfusion of the entire left hemisphere, most pronounced in the fronto-parietal and temporal regions and in the left basal ganglia. A total absence of tracer uptake is shown in the left thalamus. Late phase results (bottom row, **B**) show a marked increase of tracer uptake in the left frontal lobe and a relative reperfusion of the left caudate nucleus. Perfusional deficits in the left temporal and parietal regions remain unchanged.

by a high incidence of inappropriate interjections and dummy words, verbal stereotypes, semantic paraphasias, perseverations, paragrammatic errors and aborted sentences. Phonemic paraphasias were rarely observed and articulation and prosody were intact. The boy could repeat bisyllabic words and short sentences but his responses contained paragrammatic disruptions, perseverations and semantic parapha-

sias. Reading, writing and mental spelling were impossible. No differences were observed between L1 and L2. Three weeks after stroke, remission of symptoms was reported for L1. As confirmed by analysis of a conversational speech sample and a selection of BDAE tests (e.g., comprehension 14/15), no language disturbances were found in L1 anymore.

Seven weeks after stroke (lesion phase), L2 was formally investigated because aphasia persisted notwithstanding intensive speech and language therapy. Table 1 displays the AAT results matching a taxonomic diagnosis of TSA.

**Neuropsychological findings**

Eight weeks after stroke neuropsychological investigations were performed (Table 2). A strong and consistent right hand preference was confirmed by the Edinburgh Inventory revealing a Laterality Quotient of +100. EM was aware of the right-sided motor disturbances and did not show symptoms of auditory, tactile or visual agnosia. Some minor visuo-spatial disturbances were found (mild left-sided choice position preference, but no visual neglect). On the constructive level, apraxic symptoms were encountered (e.g., WISC-R block design: scaled score=2). By contrast, ideational, ideomotor, dressing and bucco-labio-lingual praxis was normal. On arithmetic EM scored within the lower normal range (e.g.,

WISC-R calculation: scaled score=7). The WISC-R further revealed a deficient total IQ of 68. A significant discrepancy of 25 IQ-points was found between the verbal (VIQ=83) and severely impaired performance IQ (PIQ=58). At the verbal level the patient achieved normal scores for the subtests ‘similarities’ (scaled score=10), ‘verbal comprehension’ (scaled score=8) and ‘digit span’ (scaled score=11). Significantly lower results were found at the performance level with deviant scores for ‘block design’ and ‘substitution’.

**Summary of cognitive findings**

In the acute phase of the stroke TSA affected both maternal languages. Aphasic symptoms rapidly resolved in the untreated language (L1) but persisted in L2, irrespective of intensive lexical-semantic therapy. In addition to a decrease in general cognitive abilities, constructional apraxia and minor visuo-spatial defects were found at the neuropsychological level.

**Table 1.** AAT results: week 7 (1<sup>st</sup> stroke) and week 4 and month 4 (2<sup>nd</sup> stroke)

Aachener Aphasie Test	Score	Percentile	Max.	Mean	± 1SD
<i>Comprehension</i>	75/39/75	35/4/35	120	108.5	10.24
Auditory: words	13/9/11	6/3/4	30	26.49	3.30
Auditory: sentences	21/15/28	49/20/91	30	26.79	3.41
Total	34/24/39	24/5/35	60	53.28	6.08
Written: words	19/14/12	29/13/10	30	28.30	2.29
Written: sentences	22/1/24	67/3/76	30	26.91	3.39
Total	41/15/36	47/5/34	60	55.21	4.90
Token Test	13/40/18	81/35/72	50	2.28	2.75
<i>Spontaneous Speech</i>					
Communicative behavior	4/2/4		5	4.63	0.54
Articulation and prosody	4/4/4		5	4.63	0.67
Automatisms	5/2/4		5	4.59	0.65
Semantic structure	4/1/4		5	4.59	0.53
Phonematic structure	4/4/4		5	4.54	0.56
Syntactic structure	3/3/3		5	4.41	0.55
<i>Imposed Speech</i>					
Total repetition	135/125/145	81/71/95	150	144.1	8.07
Phonemes	28/27/30	64/56/88	30	28.91	2.09
Monosyllabic words	30/24/30	93/36/93	30	29.22	1.32
Loan- & foreign words	28/26/30	77/65/95	30	28.94	2.31
Compounds	24/25/30	72/76/98	30	28.45	2.22
Sentences	25/23/25	81/74/81	30	28.55	1.90
Total naming	77/56/100	50/35/82	120	109.3	8.42
Simple nouns	20/17/24	39/32/53	30	27.92	2.90
Color names	27/15/30	77/30/98	30	27.69	1.99
Composed nouns	11/11/18	36/36/59	30	28.04	2.61
Sentences	19/13/28	69/47/99	30	25.69	3.72
<i>Written Language</i>	76/23/67	77/26/66	90	85.52	7.63
Reading aloud	28/14/27	79/28/71	30	28.95	1.93
Composing	26/7/25	76/27/72	30	28.57	2.75
Dictational writing	22/2/15	69/25/56	30	28	3.67

Downloaded by [The Aga Khan University] at 04:09 27 December 2014

**Table 2.** Cognitive test results: lesion phase (1<sup>st</sup> & 2<sup>nd</sup> stroke) and late phase data (2<sup>nd</sup> stroke)

Cognitive Tests	Stroke 1/Stroke 2/Late Phase	Mean	±1SD
<i>Intelligence</i>			
Wechsler Global IQ (GIQ)	68 / 61 / 68	100	15
Wechsler Verbal IQ (VIQ)	83 / 62 / 80	100	15
Information	3 / 5 / 5	10	3
Comprehension	8 / 4 / 6	10	3
Digit Span	11 / 5 / 9	10	3
Arithmetic	7 / 3 / 6	10	3
Similarities	10 / 4 / 10	10	3
Vocabulary	6 / 6 / 6	10	3
Wechsler Performance IQ (PIQ)	58 / 62 / 62	100	15
Digit Symbol Substitution	1 / 1 / 1	10	3
Picture Completion	5 / 5 / 5	10	3
Block Design	2 / 5 / 4	10	3
Picture Arrangement	6 / 5 / 5	10	3
Object Assembly	4 / 5 / 6	10	3
<i>Memory</i>			
Rey's 15 words: total score	- / impossible / 43 (pct 42)		
<i>Frontal Tests</i>			
Wisconsin Card Sorting	- / normal / normal		
Stroop Colour-Word Test	- / impossible: paraphasias		
Trail Making Test: Part A	- / 42" / 48" (< pct 1)		
Part B	- / 161" / 107" (< pct 1)		
<i>Praxis Tests</i>			
Rey-Osterrieth Figure	- / apraxic / apraxic	35	3
Praxis : Ideational: it. 5 HDS	- / 10 / 10	9.79	0.17
Praxis : Ideomotor: it. 3 HDS	- / 10 / 10	9.94	0.23
Praxis : Bucco-labio-lingual	- / normal / normal		
<i>Visuo-spatial Test</i>			
SON-R (Patterns)	- / 14 / 15		

## Cognitive findings—stroke 2

### Neurolinguistic findings

In the early acute phase of the second stroke, EM could only utter the same L1 words and L1 clauses. Irrespective of the language in which he was spoken to he always answered 'yes' or 'I don't know.' Auditory-verbal comprehension was practically nil. To improve lexical-semantic processes, visual-semantic therapy in L2 was administered on a daily basis. No treatment was given in L1. Within the acute phase, global aphasia evolved to TSA in L1 and L2. Ten days after stroke the FAST showed moderately severe comprehension deficits (auditory comprehension: 7/10; written comprehension in L2: 2/5). Speech contained numerous perseverations, paraphasic errors and stereotypes. In addition, EM spontaneously switched from L1 to L2 and frequently mixed L1 and L2 elements in conversations with monolingual interlocutors even when encouraged to proceed in one language. Confrontational naming of visually presented objects revealed a strong tendency to perseverate, numerous semantic paraphasias, neologisms and dummy words. Repetition was relatively preserved. Semantic and phonological paralexias disrupted

reading of simple words. Sentence reading as well as dictatorial and spontaneous writing were impossible (FAST written expression: 0/5).

In the lesion and late phase language was more extensively tested. Table 1 displays the AAT results for L2 at respectively one and four months after the second stroke, Table 3 displays the BDAE results for L1 seven weeks and six months after the second stroke.

As shown in Tables 1 and 3, auditory-verbal comprehension was still severely deficient in both languages. In comparison with the lesion phase data of the first stroke, a significant increase of errors (+27 errors) was found on the Token Test (n=40; -13.7 SD) in L2. At the beginning of the late phase, L1 and L2 had significantly improved but mild semantic as well as syntactic comprehension deficits persisted.

Oral-verbal output in the lesion phase of the second stroke was markedly worse than in the lesion phase of the first stroke and a marked extension of symptoms was observed. Aphasia clearly affected EM's communicative abilities in both L1 and L2. Although he spoke fluently and displayed no articulatory or apraxic symptoms in either language, he could often not express his ideas even

**Table 3.** BDAE subtest summary results 7 weeks (7W) and 6 months (6M) post-onset 2<sup>nd</sup> stroke

Subtests	Raw Scores 7W – 6M	Max	Cut-off	Percentile 7W – 6M	
Severity	2 – 3	5	–	60 – 80	
Fluency	Articulatory rating	6 – 7	7	–	50 – 70
	Phrase length	7 – 7	7	–	70 – 70
	Melodic line	7 – 7	7	–	50 – 50
	Oral non-verbal agility	9 – 11	12	11	–
	Verbal agility	13 – 13	14	–	80 – 80
Auditory comprehension	Word discrimination	53 – 64	72	67	50 – 70
	Body part identification	9 – 14	20	18	30 – 45
	Commands	12 – 14	15	13	65 – 80
	Complex ideational material	3 – 6	12	8	30 – 60
Naming	Responsive naming	12 – 15	30	27	55 – 60
	Confrontation naming	70 – 96	114	–	60 – 80
	Animal naming	4 – 5	23	12	70 – 75
Oral reading	Word reading	3 – 30	30	–	40 – 90
	Oral sentence reading	2 – 6	10	8	60 – 75
Repetition	Repetition of words	9 – 9	10	9	70 – 70
	High-probability	5 – 7	8	6	70 – 80
	Low-probability	4 – 4	8	6	80 – 80
Paraphasia	Neologistic	14 – 1	40	–	10 – 50
	Literal	9 – 4	47	–	30 – 55
	Verbal	13 – 4	40	–	40 – 70
	Extended	5 – 0	75	–	20 – 50
	Mixing and switching	11 – 3	–	–	–
Automatic speech	Automatized sequences	3 – 6	8	6	40 – 60
	Reciting	Not done	–	–	–
Reading comprehension	Symbol discrimination	1 – 8	10	–	5 – 40
	Word recognition	8 – 7	8	6	80 – 60
	Comprehension of oral spelling	0 – 1	8	6	30 – 40
	Word-picture matching	8 – 9	10	–	50 – 60
	Reading sentences & paragraphs	0 – 4	10	7	10 – 50
Writing	Mechanics	2 – 3	5	–	20 – 40
	Serial writing	**	47	–	**
	Primer level dictation	**	15	–	**
	Spelling to dictation	**	10	6	**
	Written confrontation naming	**	10	7	**
	Sentences to dictation	**	12	10	**
	Narrative writing	**	5	–	**
Music	Rhythm	Not done	–	0	–

\*\* not assessed since the patient had not been trained to write English.

when guided by the interlocutor. Spontaneous oral-verbal output in both L1 and L2 was often empty and disrupted by stereotypes, perseverations, pauses indicating word-finding deficits, semantic errors (paraphasias and neologisms) and some syntactic disruptions. Again no phonological disturbances were found. In addition to a substantial aggravation of the speech symptoms as compared to the first stroke, pathological mixing in L1 and L2 as well as pathological code switching in L1 and L2 constituted a cardinal characteristic of oral speech. Aside from mixing L1 and L2 at the phonological, syntactic, lexical and morphological level, blending occurred on the morphosyntactic level as well. For instance, the perfect participle ‘geweend’ of the Dutch word ‘wenen’ (to weep,

to cry) was combined to ‘gecried’ using the Dutch prefix ‘ge’ and the English past tense form ‘cried’ (Figure 3)

Although switching sporadically occurred, the most remarkable change in the late phase consisted of a remission of spontaneous pLM and pLS. In marked contrast to the acute and lesion phase, both these phenomena occurred under the conscious control of the patient to intentionally compensate for word-finding difficulties.

In comparison with the lesion phase results of the first stroke, oral and comprehensive reading had markedly deteriorated in L2. Extended phonological jargon reflected a near complete loss of writing capacities. Mental spelling was impossible. Copying of words with the left, nonparalyzed hand was, however, normal. Writing had significantly



Ik... Globalik... Globalheb gespeeld viool en dan is het in één keer niet gegaan. En dan heb ik gespeeld piano en then I untrust it ...of the past ...I can't say ...and then ...and then ...and then ...it's going wrong ...and then ...and then ...and then ...and then ...ik heb gecried want my ...head hurted ...want ik was gevallen. And then ...and then ...my papa and mama ... (I ...I ...have played violin and then it suddenly didn't go. And then I have played piano and then I untrust it ...of the past ...I can't say ...and then ...and then ...and then ...it's going wrong ...and then ...and then ...and then ...and then ...I have cried because ...my head hurted ...because I had fallen and then ...and then ...my daddy and mommy ...)

**Figure 3.** Two-minute conversational speech sample in L2 demonstrating a pathological mix of L2 and L1 (literal translation in English marked in italics)

improved when EM was again tested at the beginning of the late phase but severe agraphia persisted. Due to a lack of information about the patient's premorbid reading proficiency level in L1, the results on the BDAE reading subtests could not be reliably interpreted. However, an improvement in the results for both oral and comprehensive reading was found in the late phase.

### Bilingual language investigations

In order to assess pLM, pLS and cross-linguistic abilities more closely, multilingual language functions were investigated

in the lesion and late phase of the second stroke by means of the BNT and part C of the BAT.

### Boston Naming Test

Because of the patient's bilingual background, an ad hoc normative BNT study was performed in 46 gender- and age-matched children from the same bilingual community in Belgium. As shown in Table 4, total BNT results differed in the lesion phase for both L1 (12/60) and L2 (25/60) from the 99% control group confidence intervals (CI). In contrast to L2, total results for L1 were normal in the late phase. However, a deviant error profile disclosed persistent naming disturbances in both L1 and L2.

**Table 4.** BNT error type classification: phase patient data compared to the results of age-matched peers with the same socio-cultural background

Error type	Week 5		Month 6		Control Group	
	English	Dutch	English	Dutch	N=18 (L1)	N=48 (L2)
	(L1) N (%)	(L2) N (%)	(L1) N (%)	(L2) N (%)	English (L1) 99% CI	Dutch (L2) 99% CI
1 Phonemic/Literal Paraphasia	<b>1 (2.0)</b>	<b>2 (5.7)</b>	0 (0)	<b>3 (10.0)</b>	0.28 ± 0.35	0.35 ± 0.23
2 Verbal Morphological Paraphasia	<b>1 (2.0)</b>	<b>2 (5.7)</b>	<b>1 (2.4)</b>	0 (0)	0.00	0.24 ± 0.18
3 Verbal Semantic Paraphasia	5 (10.4)	<b>13 (37.1)</b>	<b>11 (26.8)</b>	6 (20.0)	5.78 ± 2.08	9.37 ± 1.42
4 Unrelated word	0 (0)	0 (0)	0 (0)	0 (0)	0.28 ± 0.27	0.30 ± 0.25
5 Aborted words	0 (0)	0 (0)	0 (0)	<b>1 (3.3)</b>	0.11 ± 0.19	0.65 ± 0.31
6 Neologism/Nonword	<b>1 (2.0)</b>	0 (0)	0 (0)	<b>2 (6.7)</b>	0.17 ± 0.30	0.13 ± 0.15
7 Portemanteau Word/Semantic Neologism	<b>6 (12.5)</b>	1 (2.8)	<b>3 (7.3)</b>	1 (3.3)	2.17 ± 1.33	0.89 ± 0.48
8 Perseveration	<b>4 (8.3)</b>	<b>3 (8.5)</b>	<b>1 (2.4)</b>	<b>4 (13.3)</b>	0.00	0.00
9 Delayed Response	0 (0)	0 (0)	0 (0)	0 (0)	0.00	0.02 ± 0.06
10 Don't know responses	3 (6.25)	0 (0)	10 (24.9)	1 (3.3)	24.67 ± 5.75	8.80 ± 2.14
11 Non-specific Utterances	0 (0)	0 (0)	0 (0)	0 (0)	0.11 ± 0.19	0.02 ± 0.06
12-13 Adequate & Inadequate Circumlocutions	<b>12 (25.0)</b>	<b>13 (37.1)</b>	<b>11 (26.8)</b>	<b>8 (26.7)</b>	1.61 ± 1.85	3.81 ± 1.60
14 Code Switched Words/Foreign Words	<b>14 (29.7)</b>	1 (2.8)	4 (9.7)	<b>2 (6.7)</b>	2.56 ± 1.84	0.50 ± 0.56
15 Visual Misperceptions	0 (0)	0 (0)	2 (4.9)	2 (6.7)	1.83 ± 0.83	1.85 ± 0.51
Total number of errors (%)	48 (100)	35 (100)	41 (100)	30 (100)		
Total number correct	<b>12/60</b>	<b>25/60</b>	19/60	<b>30/60</b>	20.44 ± 3.56	33.07 ± 2.59

Legend: scores marked in italic and bold differ at 99% confidence level from normative data.

Erroneous responses were classified according to 15 different error types (see Mariën *et al.*, 1998 for an explanation). In the lesion phase EM obtained scores for L1 that differed from the 99% control group CI for the following error types: phonemic paraphasias, verbal morphological paraphasias, neologisms, semantic neologisms, perseverations, circumlocutions and language-switched words. Language switched words (14/48; 29.7%) were found to be the most frequent error type in L1. Circumlocutions (12/48; 25%) and semantic error types (verbal semantic paraphasias, semantic neologisms and neologisms = 2/48; 24.6%) accounted for the second most frequent errors. Apart from a significantly lower incidence of language-switched errors, a comparable error profile was found in L2. In the late phase, semantic errors and circumlocutions remained the most frequent error types in L1 and L2.

As shown in Table 4, language-switched words were frequently observed in L1 (n=14/48; 29.7%). In addition, six out of 12 circumlocutions in L1 consisted of L2 words. The item 'pelican', for instance, was named as 'what has a *lange bek*' (long beak). Two of the six semantic neologisms consisted of a blend of an appropriate L1 and L2 lexical morpheme. The item 'canoe' (kano or roeiboet), for instance, was named as 'roeiboet'. In L2, three out of 13 circumlocutions consisted of a mix of L1 and L2 words. Nine of 13 circumlocutions contained L2 words, 1/13 responses contained L1 morphemes. The number of language-switched responses in L1 markedly decreased from 14/48 (29.7%) to a normal result of 4/41 (9.7%) in the late phase. These language-switches were intentionally used by the patient, differently from the lesion phase, to overcome word-finding difficulties. Although the number and proportion of circumlocutions remained unchanged (respectively 12/48 and 11/41 errors), blending of L1/L2 morphemes to neologistic compounds and lexical L2 intrusions dropped from six out of 12 to two out of 11 circumlocution errors. Only two (2/30; 6.7%) language-switched words were found in L2. In contrast to L1, none of the circumlocutions in L2 contained L1 intrusions.

### Bilingual Aphasia Test

Cross-linguistic abilities were investigated by means of Part C of the Dutch-English version of the BAT. This part investigates bilingual skills in a specific pair of languages and consists of

four tasks in each direction: 1) recognition of the translation equivalent of five concrete nouns in a list of ten, 2) translation of ten nouns (5 concrete, 5 abstract), 3) translation of six sentences, and 4) grammaticality judgment of eight sentences. BAT results are displayed in Table 5.

EM correctly recognized three L1 equivalents in Task 1. Two semantic errors were made: *apple* instead of *boom* (tree) and *door* instead of *venster* (window). Conversely, he correctly recognized all L2 counterparts of the L1 words. In Task 2, he correctly translated four out of ten orally presented L2 words. Among the six erroneous responses, two were omissions, one was an L2 word, two were semantic errors in L1 (*lelijkheid* [ugliness] was translated as *dirty*, and *treurigheid* [sadness] as *upset*), and one was a mixed response (*liefde* [love] as *lovde*). Five of the ten L1 words were correctly translated in L2. Four errors were omissions and one a semantic error (*joy* [vreugde] as *gezond* [healthy]). In the sentence translation task (Task 3), 11 out of 18 word groups were correctly translated from L2 to L1. A score of 6/18 was obtained for translating L1 sentences into L2. In this task switching phenomena were present in both directions. For instance, the L2 sentence '*De leraar wacht op de leerlingen op school*' (*The teacher is waiting for the pupils at school*) was translated as '*The teacher is waiting the leerling to school*', and the L1 sentence '*I am waiting for you in my office*' (*Ik wacht op jou in mijn kantoor*) was translated as '*Ik wacht voor jou in mijn office*'. In Task 4 only two L2 sentences were judged correctly. A better performance was found for L1 (5/8). Three of five L1 sentences contained interference errors which the patient was not able to correct.

The patient's cross-linguistic abilities were also assessed in the late phase. Despite complete regression of spontaneous pLS and pLM, the persistence of translation difficulties was still shown (see Table 5). In contrast to the lesion phase in which LS occurred spontaneously, the phenomenon was only sporadically observed in the late phase to overcome word-finding difficulties in a controlled and conscious manner.

### Neuropsychological findings

Cognitive functions were evaluated in the lesion (1 month) and late (6 months) phase of the second stroke (Table 2). In

**Table 5.** Patient's cross-linguistic abilities during the lesion phase (left columns) and the late phase (right columns) as formally investigated with part C of the Bilingual Aphasia Test. Number of correct/acceptable responses are given (see text for task explanation)

	Lesion Phase		Late Phase	
	(L2→L1)	(L1→L2)	(L2→L1)	(L2→L1)
Word Recognition	3/5	5/5	3/5	5/5
Word Translation	4/10	5/10	5/10	5/10
Sentence Translation (correct word groups)	11/18	6/18	12/18	6/18
Grammatical Judgment:	2/8	5/8	2/8	5/8
1) Judging:				
2) Correcting:	1/1	2/3	1/1	1/3

comparison with the IQ data obtained in the lesion phase of the first stroke, a significant decrease of the VIQ was found (from 83 to 63). Subtest analysis revealed a regression of scaled scores with more than one standard deviation ( $1SD = \pm 3$ ) for 'comprehension' (4/20), 'digit span' (5/20), 'arithmetic' (3/20) and 'similarities' (4/20). The PIQ (62) was not different from the level obtained after the first stroke (58).

In the late phase of the second stroke the VIQ (80) improved with 18 IQ points, matching the results obtained after the first stroke. The PIQ (62) remained unchanged. Due to a severe residual paresis of the right hand, the shift of manual preference caused severe motor speed and graphomotor problems (e.g., digit symbol substitution: 1/20). Verbal memory, as shown by Rey's 15 words, normalized in the late phase. The WCST scored normal in both the lesion and late phase. Numerous paraphasic and paralexical intrusions disrupted the performance on the Stroop to such an extent that the ability to inhibit a competing and more automatic response set could not be reliably evaluated. On the trail making test a deviant performance resulted from the patient's motor incapacities. Constructional drawing apraxia was found in both the lesion and late phase (e.g., Rey-Osterrieth Figure). By contrast, ideational, ideomotor and bucco-labio-lingual praxis remained intact after the second stroke.

### Summary of cognitive findings

After remission of global aphasia in the acute phase of the second stroke, TSA was found in L1 and L2. In addition, pLM and pLS severely disrupted speech in both languages. Although TSA persisted in L1 and L2, pLM and pLS had resolved when language functions were formally reassessed in the late phase of the second stroke. Incidences of language switching only sporadically occurred in the late phase to compensate for word-finding problems in a controlled manner. On the cross-linguistic level, translation difficulties persisted in the late phase. After a marked deterioration of general cognitive skills the IQ data improved to the IQ levels obtained after the first stroke. In contrast to constructional abilities, verbal memory had normalized in the late phase of the second stroke.

### Discussion

Following vascular damage to the posterior part of the left thalamus, this early bilingual right-handed child developed TSA in both maternal languages. Aphasia rapidly resolved in L1 but persisted in L2. After the second stroke, extended subcortical damage induced equally severe and persisting TSA in L1 and L2. In addition, aphasia was prominently marked by pLS and pLM. This exceptional feature was present during the acute and lesion phase of the second stroke and disappeared in the late phase despite persistence of aphasia and translation difficulties in both languages. SPECT performed

in two phases of the second stroke reflected the remission of pLS and pLM as a re-perfusion of the left frontal cortex and left caudate nucleus while the perfusion deficits remained unaltered in left temporo-parietal areas and left thalamus. The unique constellation of symptoms and their evolution as well as the anatomo-clinical findings deserve further discussion.

### Subcortical AAC

Reviewing the literature on AAC since Woods and Teuber's landmark contribution (1978) we found that 17 out of 73 cases (23.3%) developed aphasia after a subcortical lesion. Except for one left-handed patient with subcortical right hemisphere damage (Ferro *et al.*, 1982; Martins and Ferro, 1993<sup>Case 6</sup>) all children were dextrals with left subcortical lesions. The majority of these cases ( $n = 9/16$ ) sustained circumscribed subcortical damage due to a vascular cause (Aram *et al.*, 1983<sup>Cases 1,2</sup>; Cranberg *et al.*, 1987<sup>Case 4</sup>; Martins *et al.*, 1993<sup>Cases 2,3,5,9,11</sup>; Kieffer-Renaux *et al.*, 1996). Five children contracted aphasia due to a subcortical tumor (Van Lieshout *et al.*, 1990; Nass *et al.*, 2000<sup>Cases 1,2,4,5</sup>), one child after an infectious disease (Garg and DeMyer, 1995) and one after cranial trauma (Cranberg *et al.*, 1987<sup>Case 1</sup>). In contrast to our patient, none of the children reported with subcortical lesions had a bilingual background.

As in our patient, fluent aphasia was found in only two children of the vascular group (Martins *et al.*, 1993<sup>Case 9</sup>; Kieffer-Renaux *et al.*, 1996). Martins *et al.* (1993) reported anomic aphasia in a 13-year-old right-handed girl with a left subcortical lesion associated with a left temporal hypoperfusion (no further anatomical details provided). The aphasia resolved in the lesion phase, three months post-stroke. Kieffer-Renaux *et al.* (1996) described a seven-year-old right-handed girl with TSA and dysarthria after a posterior thalamic vascular lesion. After a follow-up of six months, aphasic and dysarthric symptoms were still present.

In most of the 73 AAC cases we reviewed, neuropsychological functions were not thoroughly investigated. Because most of the original descriptions neither documented cognitive disturbances on a temporal basis nor specified the time post-onset of the reported findings, the available data did not allow analysis in a time-frame model. However, in three out of the nine cases with vascular subcortical AAC intelligence was assessed (Aram *et al.*, 1983<sup>Case 1</sup>; Cranberg *et al.*, 1987<sup>Case 4</sup>; Kieffer-Renaux *et al.*, 1996). The patient of Cranberg *et al.* (1987<sup>Case 4</sup>) obtained low results at both the verbal and performance level. A significant discrepancy between a normal VIQ and superior PIQ was found in two cases (Aram *et al.*, 1983<sup>Case 1</sup>; Kieffer-Renaux *et al.*, 1996). Aside from a general cognitive decline, our patient displayed the reverse pattern with a significantly lower PIQ than VIQ after the first and second stroke. Following the observation that the non-dominant hemisphere was structurally intact, it seems plausible to assume that the pathological PIQ data rather resulted from distortion of higher skills such as speed of information

processing than from non-dominant hemisphere dysfunctioning. In two out of the three cases in which elementary arithmetic was examined, acalculia was reported (Martins *et al.*, 1993<sup>Case 9</sup>; Kieffer-Renaux *et al.*, 1996). Calculation was intact in the patient of Aram *et al.* (1983<sup>Case 1</sup>) and our patient. Absence of visuo-spatial neglect was reported by Martins *et al.* (1993) in all five cases. In our patient a slight choice position preference indicated visuo-spatial problems although no additional symptoms of right-sided neglect were objectified. Specific reference to oral apraxia was made in one case (Aram *et al.*, 1983<sup>Case 1</sup>). As in our patient, oral apraxia was absent in this patient. None of the nine cases were examined for ideomotor, ideational and constructional praxis, gnostic functions, concentration, frontal lobe functioning and memory. Our patient, however, showed persistent constructional apraxia, concentration difficulties and transient verbal memory disturbances. Frontal lobe functions as well as gnostic functions and ideomotor and ideational praxis were intact.

Although neuropsychological impairments associated with vascular subcortical AAC have not been systematically investigated, the different combinations of associated neuropsychological disorders and their evolution during longitudinal follow-up deserve further prospective research, as they may offer a unique opportunity to uncover the role of the subcortical structures in cognition.

### **Acquired aphasia in bilingual children**

During the past 25 years, only two children with bilingual AAC have been reported (Bouquet *et al.*, 1981; Fabbro and Paradis, 1995). Both patients incurred nonfluent aphasia after a cortico-subcortical lesion. Bouquet *et al.* (1981) reported polyglot Broca aphasia in an early bilingual Italian-Servo-Croatian four-year-old boy with a traumatic left cortico-subcortical temporo-parietal lesion. Selective recovery in his mother-tongue (Italian) was reported while Servo-Croatian recovered later and to a lesser extent. The authors ascribed selective recovery to Pitres' rule, that is, preferential recovery of the language to which the patient was premorbidly more exposed (Pitres, 1895). In the second study, Fabbro and Paradis (1995) reported a bilingual Friulian-Italian seven-year-old right-handed girl who developed bilingual aphasia after a left fronto-temporal ischemic infarction that slightly encroached upon the basal ganglia. After one week of verbal mutism, non-fluent aphasia with agrammatism was found in Italian (L2). Friulian (L1) only started to recover two months after stroke.

Our patient, who presented TSA in L1 and L2, is the first bilingual AAC case reported with fluent aphasia. In agreement with Bouquet *et al.*'s (1981) observations, selective recovery in his mother tongue (L1) took place after the first stroke although aphasic symptoms were solely treated in L2 and EM was more exposed to L2. After the second insult, both languages were equally distorted. In contrast to the first stroke a parallel and incomplete recovery of TSA in L1 and L2 was found. The core feature of the language deficit after

the second stroke consisted of pLS and pLM. In-depth bilingual neurolinguistic evaluations revealed frequent intrusions of L2 words in imposed L1 tasks whereas during spontaneous speech in monolingual settings pLS and pLM occurred in both directions without a preferential use of a given language. Both these phenomena occurred spontaneously and were not under conscious control. Conversely, in the late phase of the second stroke, when pLS and pLM had disappeared, EM seldom used the non-target language, either in naming tasks or in spontaneous speech. Moreover, he was fully aware and explained the sporadic use of the non-target language to circumvent word-finding difficulties in the target language. Translation difficulties as studied by means of the BAT were present in the lesion phase and late phase of the second stroke. At the single word level, translation from L1 to L2 and vice versa seemed to be equally affected. Impaired sentence translation abilities in both directions were found in the lesion and late phase. Cross-linguistic assessments further revealed two particularities: 1) a better performance for L1 during grammatical judgment tasks (in both the lesion and late phase), and 2) significantly fewer L1 intrusions in L2 naming. The former observation may be related to so-called 'age of acquisition effects', that is, to the fact that grammatical processing in early bilinguals is generally better in the native language (Weber-Fox & Neville, 1996). On the other hand, the latter observation might relate to so-called 'exposure-effects' implying that lexical selection is easier in the language to which the bilingual is more exposed. Green (1986; 1998) explained this effect in terms of a lower activating threshold for the retrieval of lexical items in the language to which the bilingual is more exposed. EM was more exposed to L2 which may explain both the lower occurrence of L1 lexical intrusions in L2 naming tasks and the high prevalence of L2 intrusions in L1 naming tasks.

### **(Pathological) language switching and language mixing**

In young bilingual infants language mixing and switching frequently occur as a kind of natural 'relief-phenomenon' when the linguistic target is more easily available in the other language. The most straightforward interpretation for the apparent disregard of the integrity of the different language systems is that young children are unaware of the language-to-be-selected violation rule (Bialystok, 2001). During the maturational course, the two systems separate and the child realizes that language choice matters (Volterra & Taeschner, 1978). At the end of the differentiation process—which is situated around age four—mixing and switching are exceptional. However, among some bilingual communities, or when one linguistic system dominates the other, as in the case of unbalanced bilinguals, both phenomena may take place under conscious control (controlled LM and LS). Hence, bilinguals may intentionally combine elements of different languages to efficiently achieve successful communication.

By contrast, mixing and switching reflect pathological communicative behavior when spontaneously used in conversations with interlocutors who do not understand the language to which the bilingual switches. Although various aspects of the alternating use of two or more linguistic languages have been extensively studied in proficient adult bilinguals (Green, 1986, 1998; Thomas and Allport, 2000; Toribio, 2001; Moreno *et al.*, 2002; Wei, 2002) and polyglot aphasics (Perecman, 1989; Muñoz *et al.*, 1999; Fabbro, 1999; Abutalebi *et al.*, 2000), mixing and switching have not been reported in aphasic children with consolidated language acquisition for both languages. After the second stroke, the most striking feature of bilingual aphasia in our patient was the development of uncontrolled mixing and switching (spontaneous pLM and pLS). In the acute and lesion phase both phenomena occurred at different linguistic levels and in both directions, without preferential use of L1 or L2. In the late phase, spontaneous pLM and pLS resolved and language mixing and switching only sporadically occurred as a means to compensate for residual word-finding disturbances.

Whether the cognitive system underlying language switching and mixing is specific to language, and hence peculiar to bilinguals and polyglots, or part of a general cognitive system responsible for executive, decision-making and attentional functions, regulating the switching between various behavioral patterns (Paradis, 1995) remains an issue to be elucidated. Recently, Fabbro *et al.* (2000) postulated that language switching may be part of a more general system underlying the selection of different behaviors. This assumption was based on the authors' observations that their patient with a left frontal lobe tumor did not show any linguistic deficits other than compulsive language switching. In our patient close behavioral observations (normal comportment) as well as formal neuropsychological assessments (normal WCST) ruled out additional frontal lobe dysfunctioning. As a consequence, spontaneous switching behaviors in our patient were strictly confined to the language domain, indicating the existence of a selective neuroanatomical counterpart of the cognitive system controlling the correct selection of language in bilinguals. However, little is known about its neural substrate and the pathophysiological mechanisms of pLM and pLS.

### ***The neural counterpart of the language switching and mixing faculty***

In most of the early contributions, the parietal (Herschmann and Poetzl, 1920; Poetzl, 1925; 1930; Leischner, 1948) and frontal lobe (Stengel and Zelmanowitz, 1933; Zatorre, 1989) of the language dominant hemisphere were held responsible for language switching. Recent clinical research has indicated that the subcortical nuclei of the language dominant hemisphere might be crucially implicated in language switching and mixing (Aglioti *et al.*, 1993; 1996; Fabbro *et al.*, 1997;

Abutalebi *et al.*, 2000). The patient reported by Aglioti *et al.* (1993; 1996) was unable to switch between languages after a left basal ganglia lesion. In this patient, rigid fixation on one language entailed selective language recovery. Fabbro *et al.* (1997) reported translation difficulties and spontaneous pLM in a patient with a left thalamic lesion, and Abutalebi *et al.* (2000) observed spontaneous pLS and pLM in a polyglot patient with a lesion of the head of the left caudate nucleus. Our patient displayed both pathological fixation under the form of selective recovery after the first stroke, and spontaneous pLS and pLM after the second stroke. These observations underscore that subcortical damage may result in different types of dysfunction in the mechanisms of controlling language selection.

Based on the circuitry model of Alexander and Crutcher (1990), Fabbro *et al.* (1997) outlined several subcortical-cortical circuits in language processing: 1) an 'anterior loop' for language planning comprising the prefrontal cortex, the caudate nucleus, the globus pallidus and the ventral anterior thalamic nucleus; 2) an 'anterior motor loop' for articulation, build-up by the sensory-motor cortex, the putamen, the globus pallidus, the ventral lateral thalamic nucleus, and the sensory motor cortex; 3) a 'posterior loop' for lexical selection that consists of the temporo-parietal cortex and the pulvinar; 4) a 'temporo-prefrontal loop' for language comprehension passing through the caudate nucleus, the globus pallidus and the ventral anterior thalamic nucleus; and 5) two 'speech initiation and production loops' connecting the temporal cortex, the caudate nucleus, the globus pallidus and dorso-median thalamic nucleus with the supplementary motor area and anterior cingulum. Abutalebi *et al.* (2000) postulated that the selection of a target language may be under the control of the anterior cortical-subcortical circuit and that the left basal ganglia may supervise language output. This hypothesis is in line with the above-illustrated cortical-subcortical circuitry outlined for monolingual speech by Fabbro *et al.* (1997). In our opinion and based on the inhibitory control model for language selection proposed by Green (1986; 1998), the role of the language planning route (the anterior cortical-subcortical circuit) would be in bilinguals that of controlling the selection of items in the target language by inhibiting items of the non-target language. The study of Fabbro *et al.* (2000) may confirm this hypothesis. These authors reported a bilingual patient with a left frontal lesion who developed in the absence of any other linguistic impairment compulsive switching between languages. However, in addition to left frontal damage, the MRI scans provided by the authors also reveal involvement of left subcortical structures—the striatum, in particular.

That the anterior loop may be the neural counterpart of the language switching and mixing faculty is strongly supported by the SPECT findings in our case. During the late phase of the second stroke, reperfusion of the left frontal lobe and caudate nucleus paralleled the remission of spontaneous pLS and pLM while perfusional deficits in the posterior language areas of the left hemisphere remained unchanged. In our

opinion, the combination of clinical and SPECT follow-up findings presented here is the strongest evidence ever reported in favor of the existence of a neuroanatomical device controlling the complex mechanism of language selection in bilinguals.

Evidence supporting the hypothesis of a left subcortical-frontal lobe system as the main anatomical determinant of the language selection control mechanism has recently been provided by functional neuroimaging studies in healthy subjects. Hernandez *et al.* (2001) performed an fMRI study with early Spanish-English bilinguals who had to name objects in one language or switch between languages. Increased activity was found in the dorsolateral prefrontal cortex for the switching condition relative to the non-switching condition. Rodriguez-Fornells *et al.* (2002) investigated the neural correlates of lexical access of visually presented words in the target language (Spanish). fMRI results of the early high proficient bilinguals (Catalan-Spanish) were compared to those obtained in a group of Spanish monolinguals. Selective activation of the left anterior prefrontal region (Brodmann areas 45 and 9) was only observed in the group of bilinguals and according to the authors, correlated with the inhibition of the non-target language (Catalan) (but see for interpretation also Grosjean *et al.*, 2003).

In our patient, the persistence of translation disturbances after remission of spontaneous pLS and pLM offers an opportunity to disentangle the neural system underlying language translation from the language selection control mechanism. While spontaneous pLS and pLM seem to be subserved by the anterior loop, it seems plausible to assume that translation capacities depend on the posterior loop, or 'lexical selection route'. Indeed, translation requires the appropriate selection of the correct item in the target language through 'controlled' retrieval mechanisms, whereas spontaneous pLS and pLM result from dysfunction of a neural mechanism responsible for the inhibition of the non-target language in spontaneous speech. Evidence supporting the 'posterior loop theory' for language translation presented here might be derived from a recent PET study (Price *et al.*, 1999) which showed that language translation relative to a non-translation condition strongly activates left temporo-parietal and subcortical areas.

## Conclusions

In this early bilingual child with vascular subcortical TSA, remission of spontaneous pLS and pLM correlated with SPECT findings revealing a reperfusion of the left frontal cortex and caudate nucleus. This parallelism between neuro-linguistic functional neuroimaging data strongly suggests that both pLS and pLM resolved with functional restoration of the anterior loop of the subcortico-cortical circuitry of language processing. As a result, our findings for the first time demonstrate that the anterior subcortico-cortical loop, which is supposed to subserve language planning, may contain the neuroanatomical device responsible for the control of language selection in bilinguals.

## Abbreviations

AAC = acquired aphasia in children; AVM = arteriovenous malformation; L1 = English; L2 = Dutch; TSA = transcortical sensory aphasia; pLS = pathological language switching; pLM = pathological language mixing; Tc-99 m-ECD SPECT = technetium-99 m labeled ethylene cysteine dimer single-photon emission computerized tomography

## References

- Abutalebi J, Miozzo A, Cappa SF. Do subcortical structures control 'language selection' in polyglots? Evidence from pathological language mixing. *Neurocase* 2000; 6: 51–56.
- Aglioti S, Beltramello A, Girardi F, Fabbro F. Neurolinguistic and follow-up study of an unusual pattern of recovery from bilingual subcortical aphasia. *Brain* 1996; 119: 1551–1564.
- Aglioti S, Fabbro F. Paradoxical selective recovery in a bilingual aphasic following subcortical lesion. *NeuroReport* 1993; 4: 1359–1362.
- Alexander GE, Crutcher MD. Functional architecture of basal ganglia circuits: Neural substrates of parallel processing. *Trends in Neuroscience* 1990; 13: 266–27.
- Aram DM, Rose DF, Rekatte HL, Whitaker HA. Acquired capsular/striatal aphasia in childhood. *Archives of Neurology* 1983; 40: 614–617.
- Bialystok E. *Bilingualism in Development. Language, literacy, & cognition.* Cambridge: Cambridge University Press, 2001.
- Bouquet F, Tuvo F, Paci M. Afasia traumatica in un bambino bilingue nel 5° anno di vita. *Neuropsichiatria Infantile* 1981; 235–236: 159–169.
- Cappa SF, Abutalebi J. Subcortical Aphasia. In: F, Fabbro, editor. *The concise encyclopedia of language pathology.* Pergamon Press: Oxford (UK), 1999; 319–327.
- Cranberg LD, Filley CM, Hart EJ, Alexander MP. Acquired aphasia in childhood: Clinical and CT investigations. *Neurology* 1987; 37: 1165–1172.
- De Renzi E, Vignolo LA. The token test: a sensitive test to detect receptive disturbances in aphasia. *Brain* 1962; 85: 665–678.
- Enderby P, Wood V, Wade D. *Frenchay Aphasia Screening Test.* NFER-Windsor: England, 1986.
- Fabbro F. *The neurolinguistics of bilingualism.* Hove, East Sussex, UK: Psychology Press, 1999.
- Fabbro F., Paradis M. Acquired aphasia in a bilingual child. In: M, Paradis, editor. *Aspects of bilingual aphasia.* Oxford: Elsevier Science Ltd., 1995; 67–83.
- Fabbro F, Peru A, Skrap M. Language disorders in bilingual patients after thalamic lesions. *J Neurolinguistics* 1997; 10: 347–367.
- Fabbro F, Skrap M, Aglioti S. Pathological switching between languages following frontal lesion in a bilingual patient. *Journal of Neurology, Neurosurgery, and Psychiatry* 2000; 68: 650–652.
- Ferro JM, Martins I, Pinto F, Castro-Caldas A. Aphasia following right striato-insular infarction in a left handed child: a clinico-radiological study. *Developmental Medicine and Child Neurology* 1982; 24: 173–182.
- Garg BP, DeMyer WE. Ischemic thalamic infarction in children: Clinical presentation, etiology, and outcome. *Pediatric Neurology* 1995; 13: 46–49.
- Golden JC. *Stroop Color and Word Test.* Chicago IL: Stoelting Co, 1978.
- Graetz P, De Bleser R, Willmes K. *Akense Afasietest.* Lisse: Swets & Zeitlinger, 1990.
- Green DW. Control, activation, and resource: A framework and a model for the control of speech in bilinguals. *Brain and Language* 1986; 27: 210–223.
- Green DW. Mental control of the bilingual lexico-semantic system. *Bilingualism: Language and Cognition* 1998; 1: 67–81.
- Grosjean F, Li P, Munte TF, Rodriguez A. Imaging bilinguals: When the neurosciences meet the language sciences. *Bilingualism: Language and Cognition* 2003; 6: 159–165.

- Heaton RK, Chelune GJ, Talley JL, Kay GG, Curtis G. Wisconsin Card Sorting Test (WCST) Manual Revised and Expanded. Odessa, FL: Psychological Assessment Resources, 1993.
- Hernandez AE, Dapretto M, Mazziotta J, Bookheimer S. Language switching and language representation in Spanish – English bilinguals: An fMRI study. *NeuroImage* 2001; 14: 510–520.
- Herschmann H, Poetzl O. Bemerkungen ueber die Aphasie der Polyglotten. *Zentralblatt Neurologie* 1920; 39: 114–128.
- Huber W, Stachowiak FJ, Poeck K, Kersensteiner M. Die Wernicke Aphasie. Klinisches Bild und Überlegungen zur neurolinguistischen Struktur. *Journal of Neurology* 1975; 210: 77–97.
- Kaplan E, Goodglass H, Weintraub S. The Boston Naming Test. Philadelphia: Lea and Febiger, 1983.
- Kieffer-Renaux V, Jambaqué I. Séquelles à long terme d'une aphasie thalamique chez l'enfant. *ANAE* 1996; 39–40: 159–162.
- Leischner A. Readings on aphasia in bilinguals and polyglots. In: M., Paradis, editor. On the aphasia of multilinguals 1948. Montreal, Didier, 1983; 456–502. .
- Mariën P, Mampaey E, Vervaeke A, Saerens J, Deyn PP De Normative data for the Boston Naming Test in native Dutch-speaking Belgian elderly. *Brain and Language* 1998; 65: 447–467.
- Martins I, Ferro J. Acquired childhood aphasia: a clinico-radiological study of 11 stroke patients. *Aphasiology* 1993; 7: 489–495.
- Mazzocchi F, Vignolo LA. Localisation of lesions in aphasia: Clinical CT scan correlations in stroke patients. *Cortex* 1979; 15: 627–654 .
- Moreno EM, Federmeier KD, Kutas M. Switching languages, switching *palabras* (words): An electrophysiological study of code switching. *Brain and Language* 2002; 80: 188–207.
- Muñoz ML, Marquardt TP, Copeland G. A comparison of the code-switching patterns of aphasics and neurologically normal bilingual speakers of English and Spanish. *Brain and Language* 1999; 66: 249–274.
- Nass R, Boyce L, Leventhal F, Levine B, Allen J, Maxfield C, Salsberg D, Sarno M, George A. Acquired aphasia in children after surgical resection of left-thalamic tumors. *Developmental Medicine and Child Neurology* 2000; 42: 580–590.
- Paradis M. Bilingual Aphasia Test (Dutch-English version). Hinsdale NJ: Lawrence Erlbaum, 1990.
- Paradis M. The Assessment of Bilingual Aphasia. Hillsdale, NJ, Erlbaum, 1987.
- Paradis M. Aspects of bilingual aphasia. Oxford: Pergamon Press, 1995.
- Perecman E. Language processing in the bilingual: Evidence from language mixing. In: Hyltenstam K, Obler LK, editors. Bilingualism across the lifespan. Cambridge (Mass.): Cambridge University Press, 1989; 227–244.
- Pick A. Forgesetzte Beiträge zur Pathologie des sensorischen Aphasie. *Archiv für Psychiatrie und Nervenkrankheiten* 1909; 37: 216–241.
- Poetzl O. Ueber die parietal bedingte Aphasie und ihren Einfluss auf das Sprechen mehrerer Sprachen. *Zeitschrift fuer die gesamte Neurologie und Psychiatrie* 1925; 99: 100–124.
- Poetzl O. Aphasie und Mehrsprachigkeit. *Zeitschrift fuer die gesamte Neurologie und Psychiatrie* 1930; 124: 145–162.
- Price CJ, Green D, von Studnitz R. A functional imaging study of translation and language switching. *Brain* 1999; 122: 2221–2236.
- Rodriguez-Fornells A, Rotte M, Heinze HJ, Noesselt T, Münte TF. Brain potential and functional MRI evidence for how to handle two languages with one brain. *Nature* 2002; 415: 1026–1029.
- Schoenberg BS, Mellinger JF, Schoenberg DG. Cerebrovascular disease in infants and children: A study of incidence, clinical features, and survival. *Neurology* 1978; 28: 763–768.
- Snijders JT, Tellegen PJ, Winkel M, Laros JA. Snijders-Oomen nietverbale intelligentietest. Son-R 25-7 Lisse: Swets & Zeitlinger, 1996.
- Stengel E, Zelmanowicz J. Ueber polyglotte motorische Aphasie. *Zeitschrift fuer die gesamte Neurologie und Psychiatrie* 1933; 149: 292–311.
- Tanabe H, Ikeda M, Murasawa A, Yamadak K, Yamamoto H, Nakagawa Y, Nishimura T, Shiraishi J. A case of acquired conductive aphasia in a child. *Acta Neurologica Scandinavia* 1989; 80: 314–318. .
- Thomas MSC, Allport A. Language switching costs in bilingual visual word recognition. *Journal of Memory and Language* 2000; 43: 44–66.
- Toribio AJ. On the emergence of bilingual code-switching competence. *Bilingualism: Language and Cognition* 2001; 4: 203–231.
- Van Lieshout P, Renier W, Eling P, De Bot K, Slis I. Bilingual language processing after a lesion in the left thalamic and temporal regions. *Brain and Language* 1990; 38: 173–194.
- Volterra V, Taeschner T. The acquisition and development of language by bilingual children. *Journal of Child Language* 1978; 4: 311–326.
- Weber-Fox CM, Neville HJ. Maturational constraints on functional specialisation for language processing: ERP and behavioral evidence in bilingual speakers. *Journal of Cognitive Neuroscience* 1996; 8: 231–256.
- Wei L. The bilingual mental lexicon and speech production process. *Brain and Language* 2002; 81: 691–707.
- Zatorre RJ. On the representation of multiple languages in the brain: old problems and new directions. *Brain and Language* 1989; 36: 127–147.