

Severe Carbon Monoxide Poisoning Treated by Hyperbaric Oxygen Therapy—A Case Report

A. Sinkovič

Department of Medical Intensive Care, General Hospital Maribor, Maribor, Slovenia

F. M. Smolle-Juettner

Thorax Surgery and Hyperbaric Surgery, University Surgical Clinic Graz, Austria

B. Kronic and M. Marinšek

Department of Medical Intensive Care, General Hospital Maribor, Maribor, Slovenia

Carbon monoxide (CO) poisoning is an important cause of mortality and late neurological sequelae such as memory loss, personality changes, psychosis, dementia, and so on. The benefits of hyperbaric oxygen (HBO) therapy are still discussed, but the majority of trials recommend it in severe cases with coma and/or hemodynamic instability, irrespective of carboxyhemoglobin (COHb) level, to prevent permanent neurological deficits. We present a 35-yr-old woman who underwent accidental CO poisoning. Although breathing 100% oxygen by mask during transfer to the hospital, she was in deep coma, hypotensive, cyanotic, and hypoxic (arterial pO₂ 7.41 kPa, HbO₂ 87.8%), with serum COHb 26.7% on hospital admission. Orotracheal intubation, mechanical ventilation, iv fluids, dobutamin, and norepinephrine were administered. COHb level decreased to 17.2% within 1 h. To prevent severe neurological sequelae, the patient was transferred as soon as possible to an HBO center 60 km distant to perform HBO therapy twice at 3.0 and once at 2.2 atm within 24 h. After the second HBO session, the patient regained consciousness, and respiratory failure and shock resolved. She was transferred to our hospital and discharged few weeks later with discrete paresis of peripheral nerves, discrete ischemic brain lesions on computed tomography (CT) scan, and moderately abnormal electroencephalogram (EEG) without cognitive disturbances. She was able to resume her daily activities. We conclude that in severe CO poisoning, normobaric oxygen therapy and resuscitation by fluids, inotropic agents, and catecholamines is essential for survival, but additional HBO therapy seems to prevent major neurological sequelae.

Carbon monoxide (CO) poisoning, either intentional or accidental, is associated with increased morbidity and mortality of poison victims (Piantadosi, 1999; Gorman et al., 2003; Ernst & Zibrak, 1998).

CO is a product of the incomplete combustion of carbon compounds, especially in closed space units. Concentration of CO in normal atmosphere is less than 0.001%, but in gas heating circuits it is found even up to 30%, in vehicle exhaust fumes up to 20%, and in explosions and fires up to 60%. The main sources of CO poisoning are defective heating systems, open fireplaces, fires, and explosions. Steel workers and firefighters are at highest risk for accidental CO poisoning. Intentional CO poisoning is

most often suicidal and is mostly due to inhalation of car exhaust fumes in closed spaces (Piantadosi, 1999; Gorman et al., 2003; Ernst & Zibrak, 1998; Von Jaeger et al., 2000).

CO poisoning causes tissue hypoxia and direct cellular damage. Tissue hypoxia is the consequence of hemoglobin's high affinity for CO, 200 to 300 times greater than for oxygen, resulting in carboxyhemoglobin (COHb) and impaired release of oxygen at the cellular level with cellular hypoxia. Tissue hypoxia causes hyperventilation and thereby further increase of inhalation of CO (Piantadosi, 1999; Gorman et al., 2003; Ernst & Zibrak, 1998; Von Jaeger et al., 2000).

The most important target organs of CO poisoning are the central nervous system and the cardiovascular system. The initial clinical signs and symptoms seem directly proportional to blood COHb concentration, which correlates directly with the concentration of inhaled CO (Piantadosi, 1999; Gorman et al., 2003; Ernst & Zibrak, 1998; Von Jaeger et al., 2000). Early clinical signs of mild CO poisoning are: headache, fatigue,

Received 27 April 2005; accepted 3 August 2005.

Address correspondence to Asst. Prof. Andreja Sinkovič, MD, PhD, Department of Medical Intensive Care, General Hospital Maribor, Ljubljanska 5, SI-2000 Maribor, Slovenia. E-mail: andreja.sinkovic@guest.arnes.si

vertigo, and weakness, but in more severe poisoning syncope, unconsciousness, even deep coma, convulsions with or without tachycardia or arrhythmias, hypotension and shock, respiratory failure, coagulopathy, renal failure, and rhabdomyolysis occur. In severe poisoning, blood COHb concentrations are usually >25%. In 25–50% of severely poisoned victims with blood COHb >25%, delayed neuropsychiatric syndrome, consisting of cognitive and personality changes and/or parkinsonism and/or dementia and/or psychosis, is observed after initial apparent recovery from acute intoxication. Recovery from delayed neuropsychiatric syndrome occurs in 50–75% of patients within 1 yr (Piantadosi, 1999; Gorman et al., 2003; Ernst & Zibrak, 1998; Von Jaeger et al., 2000).

Emergency treatment comprises removal of the victim from the source of CO followed by 100% normobaric oxygenation, which significantly shortens the half-life of COHb from 5 h to 60 min. Hyperbaric oxygenation at a pressure of 3 atm eliminates COHb at a half-time of 20 min (Von Jaeger et al., 2000). An additional effect of HBO is the prevention of reperfusion injury—in this case reoxygenation injury—by interaction with the release of cellular mediators. Moreover, the peroxidation of lipids that is a typical sequelae of CO intoxication causing damage to the myelin sheaths is terminated by HBO (Piantadosi, 1999; Gorman et al., 2003; Ernst & Zibrak, 1998; Von Jaeger et al., 2000; Weaver, 1999; Weaver et al., 2002; Dean et al., 1993). Last but not least, CO binding to cytochrome oxidase is disrupted by HBO and cerebral edema is reduced (Gorman et al., 2003; Thom & Elbuken, 1991).

Although the results of hyperbaric oxygen (HBO) therapy are still being discussed, the majority of authors recommend it in severe cases with coma and/or hemodynamic instability, irrespective of the COHb level at the time of admission, to prevent permanent neurological deficits (Piantadosi, 1999; Gorman et al., 2003; Ernst & Zibrak, 1998; Von Jaeger et al., 2000; Weaver, 1999; Weaver et al., 2002; Dean et al., 1993). In one of the recent randomized clinical studies by Weaver et al. in 2002 it was demonstrated that 3 HBO treatments within 24 h reduced the risk for delayed cognitive sequelae after acute CO poisoning in spite of disadvantages such as transport of critically ill patients to the HBO center and the risk of barotrauma or seizures (Weaver et al., 2002). Our objective is to present the significance of early HBO therapy in a critically ill poisoned victim, transferred to an HBO center within the first 24 h of severe carbon monoxide poisoning to prevent delayed neuropsychiatric syndrome.

CASE REPORT

A 35-yr-old woman (body weight 65 kg, height 170 cm), who was a nonsmoker without any history of previous lung or cardiovascular disease, was found unconscious in a barn heated by a defective gas stove at about 7 a.m. She and her husband, who was found dead, had been seen alive at about 10 p.m. of the previous night, when they went to feed animals in the stable, as reported by their children. When found, the woman was in a

deep coma, breathing shallowly. The rescuers suspected acute severe CO poisoning, removed her immediately from the barn, and gave her 100% oxygen by non-rebreathing face mask. She was immediately transferred to the hospital. On hospital admission at 8 a.m. she was in a deep coma with blood pressure 75/40 mm Hg (mean 50 mm Hg), heart rate 120/min, cyanosis, and hyperventilation. Pulmonary rales over the lungs were normal, but accelerated heart sounds without murmurs were heard by auscultation. On the left gluteal region a 5 × 10 cm large red edema was noticed. On admission, continuous electrocardiographic (ECG) monitoring was initiated and central intravenous and systemic arterial lines were inserted. A chest roentgenograph (Figure 1) revealed minor infiltrates in the lower left lung. Admission laboratory data are displayed in Table 1. COHb on admission was 26.9% and confirmed the tentative diagnosis of severe acute CO poisoning. As severe respiratory failure with hypoxemia was present, mechanical ventilation (CMV, FiO₂ 100%) was started after orotracheal intubation and prior 5 mg iv midazolam. Dobutamine (5 μg/kg/min) and norepinephrine (33 μg/kg/min) were administered intravenously due to hemodynamic instability in spite of iv infusion of fluids. Intravenous aminopenicillin was started to prevent lung infection. Adequate diuresis was achieved after hemodynamic stabilization and administration of 40 mg furosemide iv. Alkalinization of the urine was done to prevent acute renal failure due to rhabdomyolysis, which was suspected clinically and confirmed by increased

TABLE 1
Clinical and laboratory data

Clinical and laboratory data	On admission	After 72 h
Systolic/diastolic/mean blood pressure (mm Hg)	75/40/50	125/60/80
Pulse (per minute)	120	95
Glasgow coma scale	3–5	15
Arterial pH, BE (mmol/L), bicarb (mmol/L), pCO ₂ (kPa), pO ₂ (kPa), HbO ₂ (%)	7.39, –4.8, 18.0, 4.08, 7.41, 87.8%	7.45, + 2.5, 25.6, 5.01, 18.0, 99.2%
Respiratory index	53	219.4
Serum carboxyhemoglobin level (%)	26.9	—
Red blood cell count (10 ¹² /L)	4.39	3.19
Leukocyte count (10 ⁹ /L)	14.98	7.99
Platelets (10 ⁹ /L)	274	169
Serum lactate (mmol/L)	5	1
Serum myoglobin (μmol/L)	3000	1051
Hemoglobin (g/L)	133	96
Hematocrit (%)	39.2	29.2
Serum potassium (mmol/L)	5.96	3.76
Serum sodium (mmol/L)	135	145
Serum albumin (g/L)	45	—
CRP (mg/L)	14	88

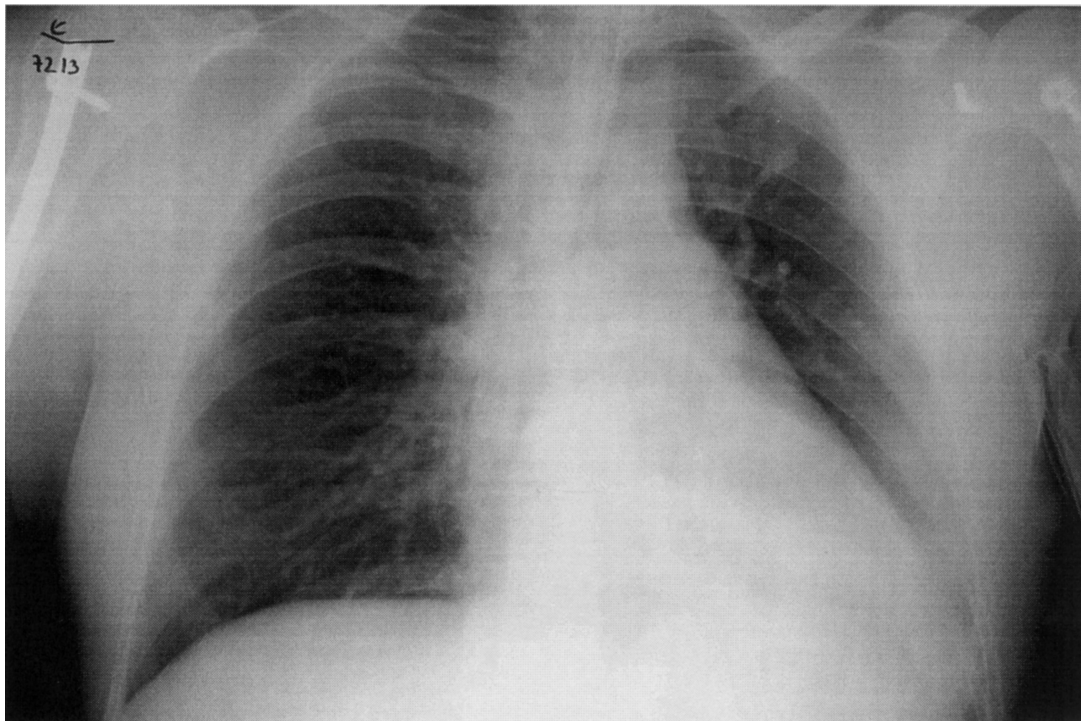


FIG. 1. Chest roentgenograph on admission.

myoglobin level. COHb decreased to 17.2% within 1 h, but the patient still needed iv. infusion of fluids, dobutamine, and norepinephrine to maintain adequate (>65 mm Hg) mean systemic arterial blood pressure. According to signs of severe CO poisoning with persisting deep coma, hemodynamic compromise, and COHb level >25% on admission, the patient was at high risk for adverse outcome, including delayed neurological sequelae. To prevent this, we decided to start HBO therapy, which is available at a 60-km-distant HBO center, where the critically ill poison victim was transferred 4 h after admission. During transport she was mechanically ventilated with normobaric 100% oxygen, receiving continuous iv infusion of fluids, dobutamine, and norepinephrine to maintain normotension. The first HBO therapy at 3 atm was performed immediately after admission and was repeated 2 times within the next hours—once at 3.0 atm and once at 2.2 atm in an 8-h interval. After the first 2 HBO treatments at 3 atm the patient gained consciousness, and respiratory failure and shock resolved. Spontaneous breathing, extubation, and discontinuation of iv dobutamine and norepinephrine followed. She was transferred and readmitted to our hospital after the third HBO treatment at 2 atm, which took place about 20 h after initial admission to our hospital. She was oriented, breathing spontaneously, and receiving 60% oxygen by mask. Laboratory tests and clinical data are displayed in Table 1. Some weeks after the acute event several tests were performed to evaluate the neurological outcome. An electromyograph (EMG) after 2 wk revealed peroneal paresis due to lesion of peroneal, tibial, and ischiadic nerves. On brain computed tomography

(CT) scan 3 wk later, discrete ischemic lesions in the area of basal ganglia were found. EEG after 3 wk was moderately abnormal with bilateral frontotemporal intermittent theta and delta activity, accentuated by hyperventilation, but further psychiatric evaluation did not show any cognitive disturbances. She was discharged 4 wk after the acute event and resumed her daily activities as housewife and farmer. After 1 yr discrete peroneal paresis persisted.

DISCUSSION

The results of studies regarding the use of HBO therapy in CO poisoning are controversial, although the majority of studies support its use in severe cases with hemodynamic compromise in order to improve survival and to prevent late neuropsychiatric sequelae (Weaver et al., 2002; Hampson et al., 1996; Gilmer et al., 2002). The mechanism of the development of delayed neuropsychiatric syndrome is not fully understood. Tissue hypoxia seems not to be the only mechanism. It is speculated that postischemic reperfusion injury, reversible demyelination of central nervous system lipids due to lipid peroxidation, damage to the blood–brain barrier triggering edema, and oxidative stress play important roles. Moreover, animal experiments have shown binding of CO to the cytochrome oxidase, which would trigger further damage at the cellular level (Piantadosi, 1999; Gorman et al., 2003; Ernst & Zibrak, 1998; Thom & Elbuken, 1991).

Weaver et al. (2002) demonstrated in a double-blind randomized trial that 3 HBO treatments within 24 h of acute severe

symptomatic CO poisoning reduce the risk for cognitive dysfunction 6 wk and 12 m after the poison event. There are several possible mechanisms for the beneficial effect of HBO therapy in this setting. Besides elimination of CO at a half-time of 20 min under 3 atm, preservation of ATP activity, modulation of ischemia–reperfusion injury, and termination of lipid peroxidation seem important as well. During HBO with the patient breathing 100% O₂ at elevated ambient pressure, oxygen dissolves in the plasma. This is why reoxygenation of tissues is effectuated immediately once HBO has been started, irrespective of the actual COHb value. Moreover, HBO reduces cerebral edema and breaks up the binding of CO to the cytochrome oxidase (Piantadosi, 1999; Gorman et al., 2003).

In our patient the onset of acute CO poisoning was most likely several hours before admission to the hospital, and HBO treatments started approximately 15 to 16 h after the suspected beginning of acute CO poisoning. Although the patient was critically ill with respiratory and cardiovascular failure and deep coma on admission, her status improved dramatically within 20 h of therapy. In spite of discrete changes on CT scan, EEG, and EMG, her psychiatric status was normal and she could resume her daily activities.

The results of the study by Weaver et al. (2002) concluded that 3 sessions of HBO therapy as early as 24 h after acute CO poisoning efficiently prevent late neurological deficits. In our case we observed that early HBO therapy preserved cognitive function, but lesions in peripheral nerves, including nervus peroneus, ischiadicus, and tibialis, persisted, confirmed by EMG. Our case report suggests that HBO therapy improves late neurological outcome in acute severe CO poisoning if performed within 24 h of acute intoxication in addition to symp-

tomatic therapy such as iv infusion of fluids, iv dobutamine, norepinephrine, and mechanical ventilation with 100% oxygen.

REFERENCES

- Dean, B. S., Verdile, V. P., and Krenzelok, E. P. 1993. Coma reversal with cerebral dysfunction recovery after repetitive hyperbaric oxygen therapy for severe carbon monoxide poisoning. *Am. J. Emerg. Med.* 11(6):616–618.
- Ernst, A., and Zibrak, J. 1998. Carbon monoxide poisoning. *N. Engl. J. Med.* 339(22):1603–1682.
- Gilmer, B., Kilkenny, J., Tomaszewski, C., and Watts, J. A. 2002. Hyperbaric oxygen does not prevent neurologic sequelae after carbon monoxide poisoning. *Acad. Emerg. Med.* 9(1):1–8.
- Gorman, D., Drewry, A., Huang, Y. L., and Sames, C. 2003. The clinical toxicology of carbon monoxide. *Toxicology* 187(1):25–38.
- Hampson, N. B., Simonson, S. G., Kramer, C. C., and Piantadosi, C. A. 1996. Central nervous system oxygen toxicity during hyperbaric treatment of patients with carbon monoxide poisoning. *Undersea Hyperbaric Med.* 23:215–219.
- Piantadosi, C. A. 1999. Diagnosis and treatment of carbon monoxide poisoning. *J. Respir. Care Clin. North Am.* 5(2):221–263.
- Thom, S. R., and Elbaken, M. E. 1991. Oxygen-dependent antagonism of lipid peroxidation. *Free Radical Biol. Med.* 10(6):413–426.
- Von Jaeger, K., Rusculte, H., Heine, J., and Piepenbrock, J. 2000. Carbon monoxide poisoning. *Anaesthesiol Reanim* 25(3):74–77.
- Weaver, L. K. 1999. Hyperbaric oxygen in carbon monoxide poisoning. *Br. Med. J.* 319(7217):1083–1084.
- Weaver, L. K., Hopkins, R. O., Chan, K. J., Churchill, S., Elliot, C. G., Clemmer, T. P., Orme, J. F., Thomas, F. O., and Morris, A. H. 2002. Hyperbaric oxygen for acute carbon monoxide poisoning. *N. Engl. J. Med.* 347(14):1057–1067.