

Double Dissociation of Hangul and Hanja Reading in Korean Patients with Stroke

Miseon Kwon^a Jong S. Kim^a Jae-Hong Lee^a Hyeonsub Sim^b Kichun Nam^c
Heasuk Park^d

^aDepartment of Neurology, Asan Medical Center, University of Ulsan College of Medicine, ^bInterdisciplinary Program of Communication Disorders, Ewha Womans University, ^cDepartment of Psychology, Korea University, ^dDepartment of Rehabilitation, Severance Hospital, Yonsei University, Seoul, Republic of Korea

Key Words

Dyslexia · Hangul · Hanja · Phonogram · Ideogram ·
Double dissociation · Stroke

Abstract

The orthographic system of the Korean language consists of both phonogram (Hangul) and ideogram (Hanja). We report 2 patients who revealed selective impairment in reading either of orthographies after the brain damages. YJ, a 67-year-old man, showed Broca's aphasia and severe apraxia of speech after a stroke in the left inferior parietal lobe. He demonstrated predominant difficulties in reading phonogram. KS, a 51-year-old woman, had an intracerebral hemorrhage in the left parietal lobe. She showed anomic aphasia and a selective impairment on reading ideogram. These findings support the notion that recognition of visual words is processed in different ways depending on the characteristics of orthographic systems.

Copyright © 2005 S. Karger AG, Basel

Introduction

The Korean orthographic system consists of both phonogram (Hangul) and ideogram (Hanja). Hangul has simple and regular correspondences between phonemes and graphemes. Hanja (Chinese letters), in contrast, has complex and irregular relations between phonemes and graphemes. Japanese language has a similar orthographic system consisting of Kana (phonogram) and Kanji (ideogram) which correspond to Hangul and Hanja, respectively. However, there are some differences between Korean and Japanese languages. The Korean orthographic system depends much less on the ideogram compared to the Japanese system. Most of Korean sentences can get through without any use of ideogram, which is very difficult in Japanese. Also, the same ideogram in the Japanese language can be read in different ways according to its meaning or phonation, which is not the case in Korean.

Double dissociation between phonogram and ideogram has been reported in Japanese patients based on the selective impairment of Kanji or Kana reading after a stroke [1–9]. According to these studies, the lesions of the patients with profound difficulties in Kana (phonogram) involved the middle to superior temporal lobe or the pa-

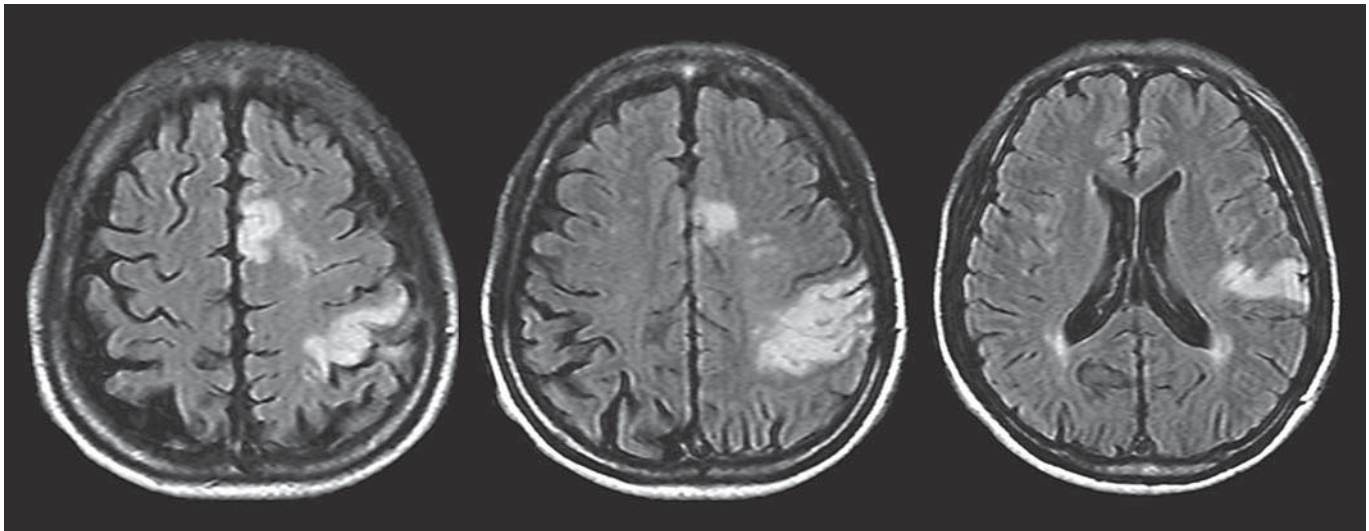


Fig. 1. Fluid-attenuated inversion recovery MRI shows an infarct involving the left postcentral gyrus, inferior parietal lobule and posterior insula (after Talairach mapping). A small cortical infarct is also seen in the left medial frontal lobe.

rietal lobe including the angular gyrus [1, 2, 6, 7], whereas the lesions associated with prominent difficulties in Kanji (ideogram) were usually located in the middle to inferior temporal lobe [2–5, 7–9].

So far, no cases of double dissociation between the reading of Hangul and Hanja in Korea have been reported. The subjects of a few studies on the Korean orthographic system were normal persons [10, 11] or were those who had impairment on Hanja reading only [12]. We, therefore, report 2 patients with predominant impairments of either Hangul or Hanja reading after brain damage.

Patients and Methods

Patients

YJ, a 67-year-old right-handed hypertensive man with a master's degree, was admitted to the Department of Neurology, Asan Medical Center, due to language disturbances and right hemiparesis. Two days before admission, he was on his way back to Korea from a business trip. When he arrived at the airport, his colleague noticed that YJ developed impaired verbal communication and had difficulty in filling out the customs declaration form. The next day, he developed weakness in his right arm and leg. He was admitted to our Department 2 days after the onset of the initial symptoms. On examination, he was alert and had aphasia, mild right facial paresis and right hemiparesis. Brain MRI performed 4 days after the onset revealed an infarct that probably involved the left medial frontal and parietal areas (fig. 1).

The other patient, KS, was a 51-year-old, right-handed normotensive homemaker with a high school degree. She was admitted to another hospital due to the loss of consciousness after a sudden onset of vomiting on waking up one morning. She had recurrent vomiting and fell into a semicomatose state. Brain CT showed intracerebral hemorrhage in the left parieto-occipital lobe. Fourteen hours after the onset, a left temporoparietal craniotomy was performed to evacuate the hematoma. Ruptured arteriovenous malformation was found and the nidus was resected. Brain MRI performed 24 days after the onset revealed an extensive lesion mainly involving the left parietal lobe (fig. 2).

Methods

The Korean test for differential diagnosis of aphasia (KTDDA) was administered to assess receptive and expressive language ability. For the evaluation of reading Hanja and Hangul, three sets of tests were prepared. Each set included 10 high-frequency words of one or two syllables. Thus, each part of the test included 20 items: 10 for Hanja and 10 for Hangul. For set A of the test, each word was printed on a card and presented to the patient who was asked to read it aloud. For set B, 20 cards were prepared, each showing a line drawing of an object along with 5 written words in Hangul or Hanja. The patient was asked to point to the word that matched the object. For set C, 5 words from the word list were printed on each card and presented to the patient. Then, the patient was asked to point at the word said by the examiner. For statistical analyses, we used the χ^2 test to examine the difference between the patients, and the McNemar test to compare Hangul and Hanja reading of each subject. The statistical test was performed using the SPSS program (version 12.0), and p value <0.05 was regarded as significant.

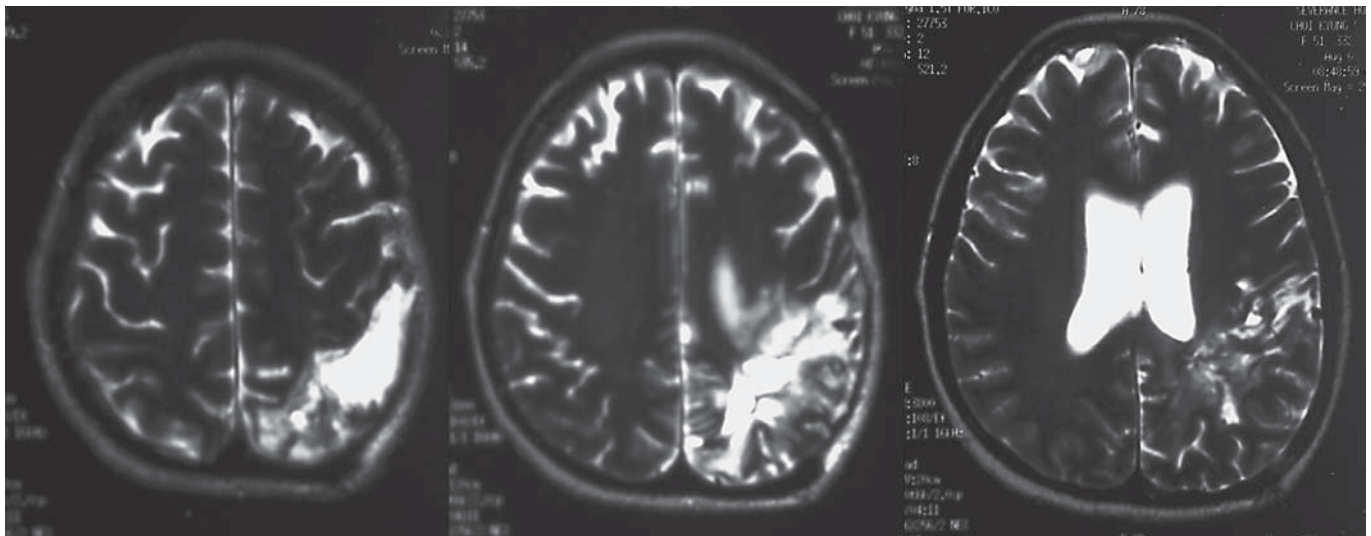


Fig. 2. T₂-weighted MRI shows a lesion mainly involving the left parietal lobe.

Results

The results of the KTDDA administered to YJ 13 days after the onset revealed that spontaneous speech was non-fluent, combined with severe apraxia of speech but without evidence of dysarthria. His speech was limited to a couple of syllables and filled with fillers, paraphasias and neologism with severe perseverative errors. Repetition (0/26) of a syllable or a word, confrontation (0/20) and generative naming (0/40) were not possible. Auditory comprehension ability was relatively intact at word (20/20) and simple sentence (10/10) levels. However, his ability to follow complex verbal direction was severely impaired (3/10). Based on this evaluation, his language deficit was classified as Broca's type of aphasia with moderate to severe severity.

Interestingly, he demonstrated more prominent difficulty in Hangul than in Hanja on performing both set B and set C of the reading test (fig. 3). On set B, he had more significant difficulty ($p < 0.05$) in performing the task with Hangul (4/10) than with Hanja (10/10). On set C, the number of correct responses was 7 out of 10 items when presented in Hanja, but 5 out of 10 items when presented in Hangul. The difference, however, was not statistically significant. Because he could not read aloud any of the words in set A in either orthographies due to his aphasia and apraxia of speech, the result of set A could not be clearly interpreted.

In the case of KS, the KTDDA was administered 42 days after the onset of her symptoms. Her spontaneous

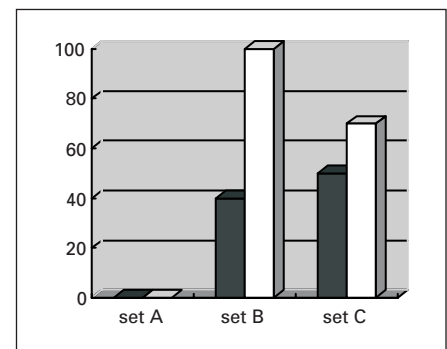


Fig. 3. Percentage of the correct responses in YJ. ■ = Hangul; □ = Hanja.

speech and prosody were considered intact. However, intermittent hesitation and phonemic paraphasias were observed, which was associated with word finding difficulties. There was no evidence of dysarthria or apraxia of speech. Repetition of spoken words and sentences was mildly impaired; most of the errors were rephrases of the inflectional words in the sentences. Confrontation naming ability was disturbed not only in low-frequency words (5/10) but also in high-frequency words (8/10). Generative naming ability was preserved in terms of semantic condition (categorical naming: 20/20), but was moderately to severely impaired in phonemic condition (6/20). Auditory comprehension ability was preserved at word (20/20) and simple sentence (10/10) levels. However, her

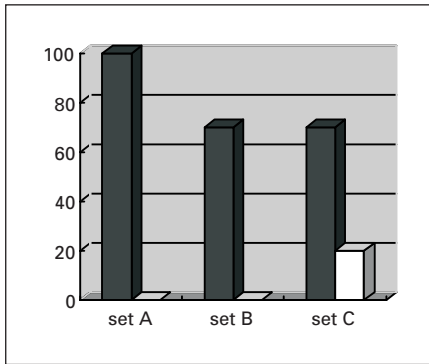


Fig. 4. Percentage of the correct responses in KS. ■ = Hangul; □ = Hanja.

auditory comprehension was mildly impaired when following complex verbal directions (7/10). The results of the evaluation suggested a mild anomic type of aphasia.

On the reading evaluation, KS showed findings contradictory to those of YJ. She showed a selective reading impairment in Hanja (fig. 4). In set A, she was not able to read Hanja (0/10), but did not have any problems in reading Hangul aloud (10/10; $p < 0.01$). Also, she missed all items in Hanja (0/10) in set B, when asked to match an object to a written word. When tested in Hangul, however, she responded correctly to 7 out of 10 items ($p < 0.05$). For set C, the number of correct responses was 2 out of 10 in Hanja and 7 out of 10 in Hangul, which was not significantly different. In the comparison of Hangul and Hanja reading between YJ and KS, there was a significant difference in written-visual association ($p < 0.01$, set B).

Regarding the lesion analysis of YJ, MRI T_1 images were spatially normalized to a standard MRI T_1 template using the SPM2 implemented in Matlab 6.5 (Mathworks Inc., Natick, Mass., USA). The coordinates of the infarcts in the left hemisphere were transformed using the non-linear transform of MRI to standard Talairach brain atlas coordinates. The results showed that the involved areas were the left postcentral gyrus, insula, inferior parietal lobule and the cingulate gyrus (fig. 1). In the case of KS, the intracerebral hemorrhage in the left parietal lobe was extensive, and there was craniotomy-related damage. We did not perform the lesion analysis using the template because it was considered unreliable in the presence of the extensive lesion and craniotomy-related damage.

Discussion

We reported 2 patients who demonstrated a selective reading impairment depending on the orthographic characteristics in the Korean language. KS showed more prominent difficulties in Hangul than in Hanja, while YJ showed the opposite characteristics. These results suggest that anatomic substrates mediating the recognition of phonogram and ideogram may be different in the Korean language as in the Japanese language, and support the dual route model in the reading process [13, 14]. It may be hard to assess exact deficits especially in Hanja reading in Korean patients because the premorbid knowledge of Hanja is different depending on the educational background of each individual. However, the materials used in our tests consisted of the basic and frequently used words, and it would be highly unlikely that anyone with a high school education cannot understand those simple words either in Hangul or Hanja.

In a previous study in Japanese patients, impairment of reading ideogram has been shown to be related to the lesion occurring in the left occipitotemporal area, particularly the posterior inferior temporal cortex [2–5, 7–9]. The anatomical correlation of the impaired phonogram, however, is not that straightforward. The lesions in the left angular gyrus [6, 7], left posterior middle temporal gyrus [7], left posterior inferior temporal lobe, lateral occipital lobe [2] and left superior temporal lobe and angular gyrus [1] were shown to be associated with more prominent difficulty in reading phonogram (Kana) than ideogram. Based on these results, it has been hypothesized that anatomical pathways mediating a reading processing for ideogram and phonogram are different: the ventral pathway (posterior part of the middle and inferior temporal gyri) for ideogram reading and the dorsal pathway (inferior parietal lobe) for phonogram reading [15].

In our study, the lesion in YJ affected the left postcentral gyrus, insula, inferior parietal lobule and cingulate gyrus. The left inferior temporal lobe known to mediate ideogram reading remained intact. His symptoms were primary deficits in reading Hangul with relatively intact ability for the Hanja reading. Therefore, these findings seem to agree with the previous results in the Japanese studies. YJ also showed comparatively lower performance in set C than set B of the test in Hanja, which was not observed in Hangul. He would have modality-specific difficulty in reading ideogram. However, this assumption could not be investigated further because the patient refused to have additional tests.

In KS, the lesion primarily involved was the left parietal lobe despite a selective impairment in reading ideogram. This observation is in contrast to previous results where deficits in ideogram reading were usually related to the inferior temporal lobe lesions [2–5, 7–9]. Perhaps the surgical procedure (left temporoparietal craniotomy) damaged a part of the inferior temporal lobe. However, with the presence of the extensive lesion, it would be difficult to make a clear anatomical-clinical correlation in this case.

Early researches on visual word recognition presumed that accessing phonological representation is the primary route to understanding written words. The ‘phonic mediation theory’ uses this assumption and suggests that the reading of written words is processed the same way, transferring graphemes to phonological codes despite their orthographic differences [13, 16]. In an alternative view, Patterson et al. [14] proposed the dual route model in the processing of orthography. In this model, the lexical route directly accesses the meaning of skilled or deep orthogra-

phies. On the other hand, phonological route is necessary to mediate phonological code and to convert graphemes to phonemes.

It has been criticized that previous reports correlating particular impairment patterns to the brain lesion of the patient seemed oversimplified [17]. Sugishita et al. [17] argued that impairment of high cortical functions such as reading phonogram or ideogram might not be directly linked to the damaged structure. The authors postulated that complex cognitive functions accomplished through many interfaces on various stages of mental process related to the neural network, and that it may be too risky to match the cognitive dysfunction directly with the damaged area of the brain. However, double dissociation in cognitive dysfunction of some patients is undeniable evidence that two functions are processed in two different pathways. Our results also suggest that a double dissociation between the processing of phonogram and ideogram is present in Korean patients, supporting the dual route system in the recognition of written words.

References

- Hayashi MM, Ulatowska HK, Sasanuma S: Subcortical aphasia with deep dyslexia: a case study of a Japanese patient. *Brain Language* 1985;25:293–313.
- Kawahata N, Nagata K, Shishido F: Alexia with agraphia due to the posterior inferior temporal lobe lesion-neuropsychological analysis and its pathogenetic mechanisms. *Brain Language* 1988;33:296–310.
- Kawamura M, Hirayama K, Hasegawa K, Takahashi N, Yamamura A: Alexia with agraphia of Kanji (Japanese morphograms). *J Neurol Neurosurg Psychiatry* 1987;50:1125–1129.
- Mochiukai H, Ohtomo R: Pure alexia in Japanese and agraphia without alexia in Kanji: the ability dissociation between reading and writing in Kanji vs. Kana. *Arch Neurol* 1988;45:1157–1159.
- Sasanuma S: Kanji versus Kana processing in alexia with transient agraphia: a case report. *Cortex* 1974;10:89–97.
- Yamatori A: Ideogram reading in alexia. *Brain* 1975;98:231–238.
- Yamatori A, Motomura N, Endo M, Mitani Y: Category-specific alexia and a neuropsychological model of reading (in Japanese). *Higher Brain Funct Res* 1985;5:23–27.
- Soma, Y, Sugishita M, Kitamura K, Maruyama S, Imanaga H: Lexical agraphia in the Japanese language: pure agraphia for Kanji due to left posteroinferior temporal lesions. *Brain* 1989; 112:1549–1561.
- Sakurai Y, Takeuchi S, Takada T, Horiuchi E, Nakase H, Sakuta M: Alexia caused by a fusiform or posterior inferior temporal lesion. *J Neurol Sci* 2000;178:42–51.
- Lee KM: Functional MRI comparison between reading ideographic and phonographic scripts of one language. *Brain Language* 2004;91:245–251.
- Lee DH, Lee HJ, Lee EJ, Moon CH, Yoo JW, Na DK, Nam KC: A fMRI study of word recognition in Chinese and Korean. *Korean J Commun Disord* 2001;6:105–130.
- Kwon JC, Lee HJ, Chin J, Lee YM, Kim H, Na DL: Hanja Alexia with agraphia after left posterior inferior temporal lobe infarction: a case study. *J Korean Med Sci* 2002;17:91–95.
- Caplan D: *Language: Structure, Processing and Disorders*. Cambridge, MIT, 1996.
- Patterson KE, Marshall KC, Coltheart M: *Surface Dyslexia: Cognitive and Neuropsychological Studies of Phonological Reading*. London, Lawrence Erlbaum Associates, 1985.
- Iwata M: Kanji versus Kana: neuropsychological correlates of the Japanese writing system. *Trends Neurosci* 1984;7:290–293.
- Ellis AW, Young AW: *Human Cognitive Neuropsychology*. London, Lawrence Erlbaum Associates, 1987.
- Sugishita M, Otomo K, Kabe S, Yunoki K: A critical appraisal of neuropsychological correlates of Japanese ideogram (Kanji) and phonogram (Kana) reading. *Brain* 1992;115:1563–1585.

Copyright: S. Karger AG, Basel 2005. Reproduced with the permission of S. Karger AG, Basel.
Further reproduction or distribution (electronic or otherwise) is prohibited without permission
from the copyright holder.