

Evaluation of cerebral dyschromatopsia using color afterimage

Shinichi Koyama^{a,c}, Machiko Kezuka^b, Haruo Hibino^c, Hiroyuki Tomimitsu^b and Mitsuru Kawamura^{a,d}

^aDepartment of Neurology, Showa University School of Medicine, ^bAoyama Hospital, Tokyo, ^cDepartment of Engineering, Chiba University, Chiba and ^dCREST, Japan Science and Technology Corporation, Saitama, Japan

Correspondence and requests for reprints to Shinichi Koyama, PhD, Department of Neurology, Showa University School of Medicine, 1-5-8 Hatanodai, Shinagawa-ku, Tokyo 142-8666, Japan

Tel: +81 3 3784 8781; fax: +81 3 3783 6230; e-mail: skoyama@med.showa-u.ac.jp

Sponsorship: S.K. was supported by Japan Society for Promotion of Science. M.K. was supported by CREST, and Grant-in-Aid for Scientific Research on Priority Areas – Higher-Order Brain Functions – from MEXT. This study was also supported in part by a Showa University Grant-in-Aid for Innovative Collaborative Research Projects and a Special Research Grant-in-Aid for Development of Characteristic Education from MEXT.

Received 9 September 2005; revised 9 November 2005; accepted 11 November 2005

Cerebral dyschromatopsia is traditionally evaluated by color discrimination tests such as the Farnsworth–Munsell 100 Hue Test. These tests are also used to evaluate color-perception deficits caused by eye disease, and they do not tell us whether color perception is impaired in the eye or in the brain. Here, we used color afterimage to isolate color-perception deficits in the brain from those in the eyes, in a patient with cerebral dyschromatopsia. The

results showed that the patient perceived color afterimage of yellow and blue with abnormal duration and chromaticity. On the other hand, the patient performed normally on the Farnsworth–Munsell 100 Hue Test. We conclude that the color afterimage test would be useful to evaluate color perception in the brain. *NeuroReport* 17:109–113 © 2006 Lippincott Williams & Wilkins.

Keywords: cerebral dyschromatopsia, color afterimage, Farnsworth–Munsell 100 Hue Test, Ishihara Test, panel D-15

Introduction

Cerebral dyschromatopsia is a disturbance in color perception caused by lesions in the ventral occipital cortex. It frequently accompanies scotoma in the upper visual field [1,2], and many patients with cerebral achromatopsia also have prosopagnosia [3].

Cerebral dyschromatopsia is traditionally evaluated by color discrimination tests, such as the Farnsworth–Munsell 100 Hue Test and its 15 Hue variant, Panel D-15. Although the Farnsworth–Munsell 100 Hue and Panel D-15 Tests have been very useful for the evaluation of cerebral dyschromatopsia, two problems remain. First, these tests are designed to evaluate impaired color vision caused by eye disease, and not to differentiate between deficits caused by damage in the eye and deficits caused by damage in the brain. Second, some patients with cerebral dyschromatopsia may be able to perform normally on traditional color perception tasks: even if colors become less clear after brain damage, normal color discrimination tasks may be possible by perceiving small differences between colors.

One alternative method to evaluate patients' ability to see colors may be measuring the duration and chromaticity of the color afterimage of red, green, yellow, and blue [4]. Color afterimage is perceived when we view a certain color (adaptation color) for a certain period and see a neutral color immediately after disappearance of the adaptation color. According to Hering's opponent color theory [5], there

are three pairs of opponent colors (red vs. green, yellow vs. blue, and white vs. black), and adaptation to one color leads to the afterimage of its opponent color. The opponent theory is supported by the finding of opponent cells in the retinal ganglion cells [6,7], and double-opponent cells in the visual cortices [8]. Functional imaging studies in humans also support this theory [9]. Color afterimage may be useful to evaluate cerebral dyschromatopsia because a certain type of color afterimage is known to be generated in the brain [10,11], so we can observe color vision in the brain directly.

We attempted to examine color afterimage in a 58-year-old man who had a stroke in a focal region in the occipital cortex. The patient first claimed that visual scenes appeared yellowish and/or brownish to him at the onset of the stroke, but he claimed that the symptom disappeared 6 months later. After he reported that the symptoms disappeared, he performed normally in the well known color tests such as the Farnsworth–Munsell 100 Hue Test. His color perception was examined further, using color afterimage.

Methods

Case history

The patient (H.N.) was a 58-year-old left-handed male. After he was admitted to the hospital in October 2003 because of infarction in the right occipital cortex and the right cerebellum, he started to claim that visual scenes appeared

yellowish and brownish to him (Fig. 1a). Neuropsychological testing showed that he performed normally on the Raven Color Matrix (29/36), Wechsler Adult Intelligence Scale-Revised (VIQ 105, PIQ 95, IQ 101), and Kohs Block Design Test (IQ 98). He was able to recognize photographs of famous people (the Japanese prime minister, etc.) very easily and did not claim difficulty in face recognition. Neurological testing showed that he had upper-left and upper-right quadrants and he had a scotoma in the lower left visual field. He had motor ataxia in the right upper limb. The fundi of his eyes were examined and no eye disease such as cataract or glaucoma was found. His visual acuity was 20/17 in both eyes. His medical record showed that he had infarctions in the left occipital cortex in 1998 and 2000. Magnetic resonance images indicated a lesion in the lingual and fusiform gyri around the collateral sulcus, as well as in the posterior part of the parahippocampal gyrus in the left hemisphere (Fig. 1b). In the right hemisphere, a lesion was indicated in the paracalcarine cortex, anterior lingual gyrus and the cuneus.

Conventional color tests

A series of color tests were administered to H.N. between October 2004 and February 2005, 1 year after he first reported the symptom that visual scenes seemed to be yellowish and brownish. At this time, he reported that the symptom disappeared. After H.N. reported that the symptom disappeared, he was asked to simulate what he saw while he had abnormal color perception by adjusting the color balance of a picture (Fig. 1a). Interestingly, in the right picture in Fig. 1a, he reduced the amount of blue and cyan whereas he increased the amount of red, green, and yellow, suggesting that he could hardly perceive blue while his dyschromatopsia was severe.

After reporting the disappearance of dyschromatopsia, H.N. performed normally on the Ishihara Test (no errors) and Panel D-15 (one minor error). His performance in the Farnsworth-Munsell 100 Hue Test was within the normal range (0–5 error scores in all hues) in both eyes.

Color afterimage test

In addition to the above tests, H.N. participated in a color aftereffect test in October 2004, December 2004, and February 2005. Three age-matched male study participants also took part in the test. Written, informed consent was obtained from all participants. The experiment was performed in compliance with relevant laws and the institutional guidelines of Showa University School of Medicine.

In the testing room, artificial sunlight illumination was used to maintain the illumination around the computer at 550 lux. The participant's head was placed on a chin rest. The stimulus was presented on a 15-inch liquid crystal display of Macintosh G4 Powerbook, and the viewing distance was 57 cm. In each trial, a color square ($3.8^\circ \times 3.8^\circ$) was presented in the center of the display (Fig. 2). A black fixation cross ('+') was presented in the center of the display, on the color square. The color of the square was red, green, yellow, or blue, and the background color was white. After the participants viewed the stimulus for a certain period (10 or 15 s), the color square disappeared and the whole display became white, with the black fixation cross in the center of the display. The

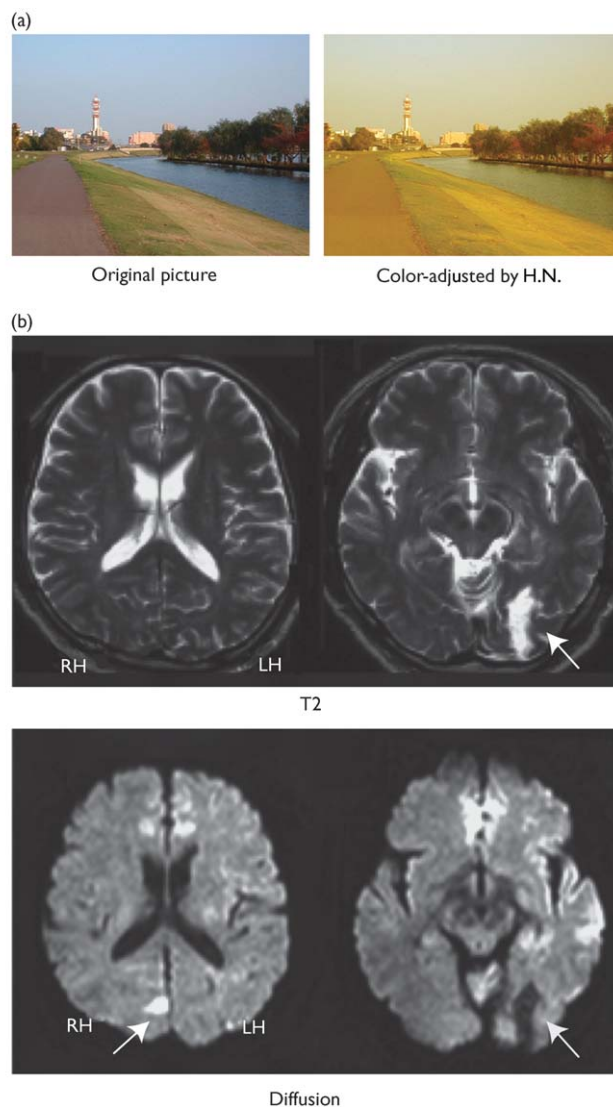


Fig. 1 (a) H.N.'s perception of a natural scene. (b) Magnetic resonance imaging (MRI) pictures of H.N. MRI pictures showed that lesions were in the left lingual and fusiform gyri around the collateral sulcus, and the posterior part of the parahippocampal gyrus (indicated by arrows). In the right hemisphere, the lesion was in the paracalcarine cortex: anterior lingual gyrus and the cuneus (indicated by an arrow). Although T2 and diffusion tensor images were taken from the identical slices, the lesion in the right hemisphere was visible only in the diffusion tensor images. RH, right hemisphere; LH, left hemisphere.

participant pressed a button when he started seeing the afterimage and when the afterimage disappeared. The durations of the afterimage were recorded automatically by the computer.

The experiment consisted of four blocks. A block had 12 trials and only one color was used in the block. At the end of the block, the participant was asked to choose the color of the afterimage from a color circle.

Results

Figure 3a shows the duration of the afterimage for H.N. and the normal control. The durations for each stimulus color

(in seconds) was scaled by the duration for yellow, that is, (duration of afterimage of a color)/(duration of afterimage of yellow), for each participant for each condition. Therefore, the data plot for yellow is one for all conditions. In H.N., the duration of the afterimage of yellow was shorter than those of red and green. In contrast, the duration of the afterimage of blue was longer than red and green. In the 15-s condition, the duration of the afterimage for blue was three times longer than that of yellow. The durations of the afterimage of red and green were quite similar. On the other hand, in the controls, the duration of the afterimage was almost the same for all colors.

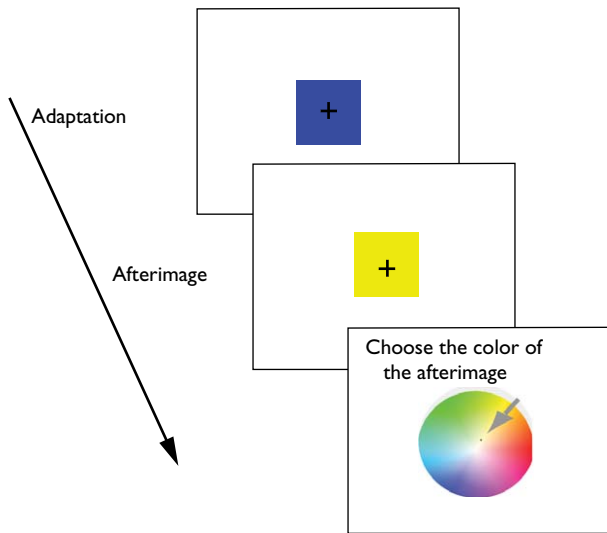


Fig. 2 Summary of the task.

Figure 3b illustrates the chromaticity of the afterimages of each color for H.N. and the normal control. In H.N., chromaticity of the afterimages was very similar for all stimulus colors, and the chromaticity for all colors was

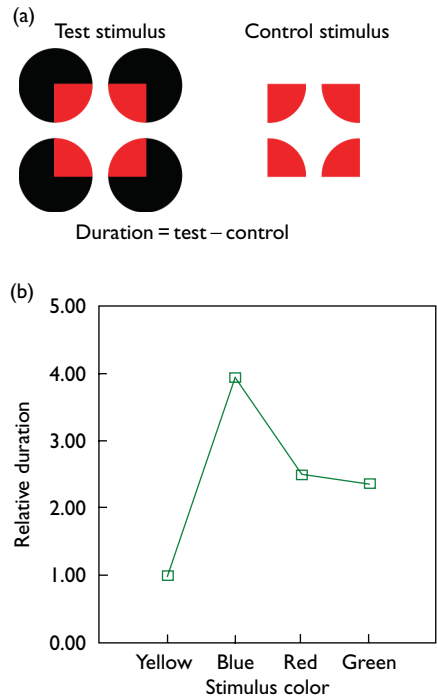


Fig. 4 (a) Test and control stimuli. Here, duration of the afterimage was defined as 'duration of the afterimage for the test stimulus' minus 'duration of the afterimage for the control stimulus'. (b) Results were similar to those in the first color afterimage test.

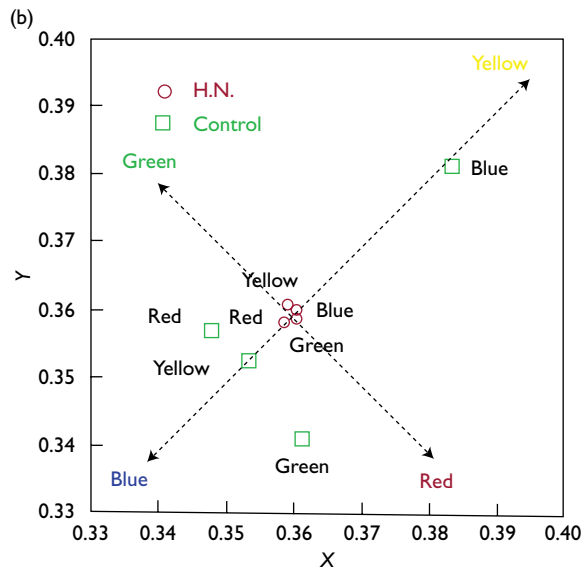
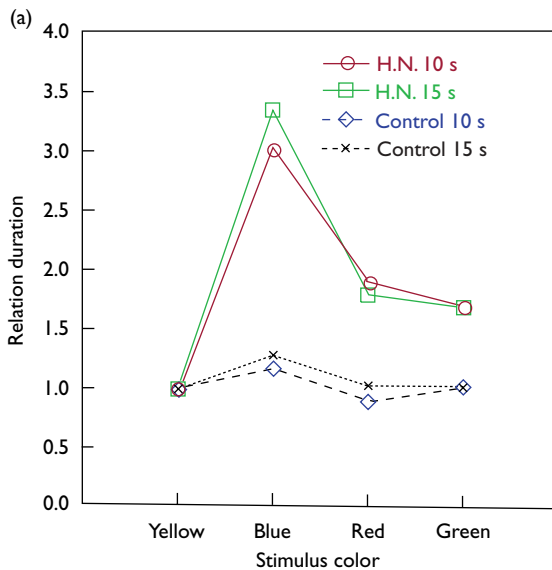


Fig. 3 Duration and chromaticity of the afterimage for each color. (a) In H.N., the duration of the afterimage for blue (i.e. duration seeing yellow afterimage) was three times longer than that for yellow (i.e. duration seeing blue afterimage). The results indicate selective impairment in the blue–yellow system. In the normal control, the duration of the afterimage was similar for all colors. (b) Chromaticity of the afterimages in the CIE (International Commission on Illumination) color coordinates. The color names near the arrows (printed in colors) indicate colors in the coordinates, and the crossing of the arrows indicate white. Color names (printed in black) near the red circles and the green squares indicate the stimulus colors.

located near the chromaticity of white. On the other hand, in the controls, the color of the afterimage was seen more clearly and they were complimentary colors of the stimulus colors.

Next, we asked whether the abnormality in the duration of the color afterimage was caused by the lesions in the occipital cortex. As a study showed that color afterimage occurs as a result of the retinal adaptation [12], it is possible that the abnormality in the color afterimage occurred in the retina. In order to see whether the abnormal duration of the color afterimage in H.N. was associated with the lesions in the brain, we replicated the above experiment using illusory figures (Varin figure, Fig. 4a) in which we perceive illusory filled-in colors on a white background. The color afterimage of the illusory square in the Varin figure should be generated in the brain [10,11], as only white is presented to the retina. The procedures in this test were the same as those in the above test except that there was only one condition in which the adaptation stimulus was presented for 10s. The durations of afterimages of the Varin figures (Fig. 4a left) and the control stimuli (Fig. 4a right) were recorded; we defined the afterimage of the illusory square as the 'duration for Varin figures' minus 'duration for the control stimuli'. The results from the original experiment were replicated by the second experiment using the illusory figures (Fig. 4b).

Discussion

The results from the color afterimage test indicated that the balance between the neural mechanisms for yellow and blue were impaired in this patient. The afterimage of blue was prolonged whereas that of yellow was shortened. The results suggest that the neural mechanisms for blue, which should be active after adaptation to yellow, was weakened by the brain damage. On the other hand, the balance between the neural mechanisms for red and green was relatively preserved. The results were replicated by illusory figures, suggesting that the visual cortex is at least partially involved in the generation of the abnormal duration of the afterimage, as the perception of the illusory color should be generated in the brain [10,11]. Those results were consistent with the fact that the patient reduced the amount of blue whereas he increased the amount of yellow while adjusting color balance in the picture. Measuring the duration and the chromaticity of the color afterimage may be a useful diagnostic tool for cerebral dyschromatopsia, because (1) we could see the activity balance between the neural mechanisms for the four colors in the brain, and (2) it could detect color perception disorder that was not detected by the Farnsworth–Maunsell 100-Hue Test.

Why was the color afterimage experiment able to detect abnormality that was not detected by the 100 Hue Test? One possibility is that the color afterimage test directly measures sensitivity to a color, whereas the 100 Hue Test measures discriminability between colors. In other words, even if colors become less clear to a patient after the brain is damaged, he/she may still be able to perform color discrimination tasks by seeing small differences between colors. On the other hand, color afterimage disappears very quickly when the color is not clear.

We hypothesized that the patient developed abnormal color perception because of the bilateral damage in the paracalcarine cortex including the right cuneus and the lingual gyrus and the left lingual and fusiform gyri.

The location of the lesion was consistent with that of the other patients with cerebral dyschromatopsia [1,3,13]. The patient had a quadrantanopsia in the upper visual field, which was also consistent with the previously reported cases [1]. Furthermore, it was shown that neurons in those visual cortexes respond to color by single-unit recording [8,14,15] and functional magnetic resonance imaging studies [9,16–20].

Conclusion

It was concluded that H.N. developed cerebral dyschromatopsia after the most recent stroke in the very small region in the cuneus and the lingual gyri in the right hemisphere. His color perception recovered significantly and abnormality could be detected only in the duration and chromaticity of color afterimage, suggesting that the color afterimage test can be a useful diagnostic tool for cerebral dyschromatopsia.

Acknowledgements

The authors thank Nami Ihori, Juro Kawachi, Hidehiko Komatsu, Akira Midorikawa, Atsushi Mizobuchi, Yoshiko Nakagawa, Tatsuya Sato, Summer Sheremata, Junichi Shiota, Atsunobu Suzuki, and Nahoko Yoshimura, for comments on the earlier version of the manuscript.

References

- Meadows JC. Disturbed perception of colours associated with localized cerebral lesions. *Brain* 1974; **97**:615–632.
- Zeki S. A century of cerebral achromatopsia. *Brain* 1990; **113**:1721–1777.
- Bouvier SE, Engel SA. Behavioral deficits and cortical damage loci in cerebral achromatopsia. *Cereb Cortex* 2005 [Epub ahead of print].
- Chan D, Crutch SJ, Warrington EK. A disorder of colour perception associated with abnormal colour after-images: a defect of the primary visual cortex. *J Neurol Neurosurg Psychiatry* 2001; **71**:515–517.
- Hering E. *Outlines of a theory of the light sense [in German]*. Translated by Hurvich LM, Jameson D. Cambridge, Massachusetts: Harvard University Press; 1964.
- De Monasterio FM, Gouras P, Tolhurst DJ. Trichromatic colour opponency in ganglion cells of the rhesus monkey retina. *J Physiol* 1975; **251**:197–216.
- Raynauld JP. Goldfish retina: sign of the rod input in opponent color ganglion cells. *Science* 1972; **177**:84–85.
- Livingstone M, Hubel D. Anatomy and physiology of a color system in the primate visual cortex. *J Neurosci* 1984; **4**:309–356.
- Schluppeck D, Engel SA. Color opponent neurons in V1: a review and model reconciling results from imaging and single-unit recording. *J Vis* 2002; **2**:480–492.
- Sasaki Y, Watanabe T. The primary visual cortex fills in color. *Proc Natl Acad Sci USA* 2004; **101**:18251–18256.
- Shimojo S, Kamitani Y, Nishida S. Afterimage of perceptually filled-in surface. *Science* 2001; **293**:1677–1680.
- Craik F. Origin of visual after images. *Nature* 1940; **145**:512.
- Tanaka Y, Kitahara K, Nakadomari S, Kumegawa K, Umahara T. Analysis with magnetic resonance imaging of lesions in cerebral achromatopsia. *Nippon Ganka Gakkai Zasshi* 2002; **106**:154–161.
- Hanazawa A, Komatsu H, Murakami I. Neural selectivity for hue and saturation of colour in the primary visual cortex of the monkey. *Eur J Neurosci* 2000; **12**:1753–1763.
- Zeki S. Colour coding in the cerebral cortex: the reaction of cells in monkey visual cortex to wavelengths and colours. *Neuroscience* 1983; **9**:741–765.
- Beauchamp MS, Haxby JV, Jennings JE, DeYoe EA. An fMRI version of the Farnsworth–Maunsell 100-Hue Test reveals multiple color-selective areas in human ventral occipitotemporal cortex. *Cereb Cortex* 1999; **9**: 257–263.

17. Beauchamp MS, Haxby JV, Rosen AC, DeYoe EA. A functional MRI case study of acquired cerebral dyschromatopsia. *Neuropsychologia* 2000; **38**:1170-1179.
18. Engel S, Zhang X, Wandell B. Colour tuning in human visual cortex measured with functional magnetic resonance imaging. *Nature* 1997; **388**:68-71.
19. Hadjikhani N, Liu AK, Dale AM, Cavanagh P, Tootell RB. Retinotopy and color sensitivity in human visual cortical area V8. *Nat Neurosci* 1998; **1**:235-241.
20. Sakai K, Watanabe E, Onodera Y, Uchida I, Hato H, Yamamoto E, *et al.* Functional mapping of the human colour centre with echo-planar magnetic resonance imaging. *Proc R Soc Lond B Biol Sci* 1995; **261**:89-89.