

Original Letters

β -Ureidopropionase Deficiency Presenting with Febrile Status Epilepticus

*Birgit E. Assmann, †Andre B. P. Van Kuilenburg, *Felix Distelmaier, †Nico G. G. M. Abeling,
*Thorsten Rosenbaum, ‡Jörg Schaper, †Marinus Duran, and *Ertan Mayatepek

*Department of General Pediatrics, University Children's Hospital, Duesseldorf, Germany; †Academic Medical Center, Laboratory for Genetic Metabolic Diseases, Amsterdam, The Netherlands; and ‡Institute of Diagnostic Radiology, University Hospital, Duesseldorf, Germany

Summary: β -Ureidopropionase is the third enzyme in the catabolic pathway of uracil and thymine. To date, only three other patients are reported with this inborn error of metabolism. We report the clinical presentation of a male patient who presented at the age of 4 months after an ALTE-like event (ALTE = acute life-threatening event) with febrile status epilepticus. Such a clinical presentation has not been reported before in this condition. Diagnosis was based on biochemical, enzymatic and molecular studies. MRI (magnetic resonance imaging) at the age of 11 months demonstrated large subdural hematomata and global supratento-

rial atrophy. At that time the patient showed severe psychomotor retardation with muscular hypotonia, extremely limited visual contact and poorly controlled epilepsy.

Conclusions: Pyrimidine degradation defects should be included in the differential diagnosis of convulsions, (febrile) status epilepticus, psychomotor retardation and possibly also ALTE-like events. **Key Words:** Status epilepticus— β -Ureidopropionase deficiency— β -Aminoisobutyrate— β -Alanine—ALTE.

β -Ureidopropionase is the third enzyme in the catabolic pathway of uracil and thymine. It catalyzes the cleavage of ureidopropionate and ureidoisobutyrate to β -alanine and β -aminoisobutyrate, respectively. So far, three patients with deficiency of this enzyme have been reported (1,2). We have identified the fourth patient with β -ureidopropionase deficiency whose clinical presentation was completely different from that of the previously reported patients.

The boy was the second child of nonconsanguineous German parents with an unremarkable history. At age 4 months, he was found breathing at a slow rate and with his head covered by his blanket. The day before, mild, afebrile rhinitis had been noted. At admission, he first appeared clinically normal apart from a fever of 39.5°C and tachycardia. While the detailed history was being taken, he suddenly became cyanotic without obvious cause. With supplementary oxygen, the child became alert but was sweating with hectic limb movements. He

was transferred to intensive care. One hour after admission, the first seizure, focal with secondary generalization, occurred and subsided spontaneously.

Initial laboratory investigations revealed moderate metabolic acidosis and hyperlactatemia. CSF showed mildly elevated protein and 27 white cells/ μ l. C-Reactive protein (CRP) was persistently normal. Initially, transaminases as well as creatine kinase (CK) were highly elevated with a maximum level on day 3. Additionally, coagulation parameters were abnormal.

Left focal status epilepticus then developed and did not respond to diazepam, pyridoxine, or phenytoin (PHT). Pyridoxalphosphate or folic acid was not administered. After intubation and ventilation, thiopental was introduced (≤ 10 mg/kg/h). Midazolam was added because of persisting multifocal jerks and spikes in the EEG. Dexamethasone was given for a 48-h period. Antibiotic and antiviral treatment was started. Impaired coagulation caused gastric bleeding, which subsided after infusion of fresh frozen plasma. No infectious agent could be identified. All initially abnormal laboratory parameters normalized rapidly. After 10 days of ventilation with an anticonvulsive treatment consisting of phenobarbitone, thiopental, and midazolam, he was extubated. Intermittent myoclonic

Accepted July 24, 2005.

Address correspondence and reprint requests to Dr. B. Assmann at Department of General Pediatrics, University Children's Hospital, Moorenstrasse 5, D-40225 Duesseldorf, Germany. E-mail: birgit.assmann@uni-duesseldorf.de

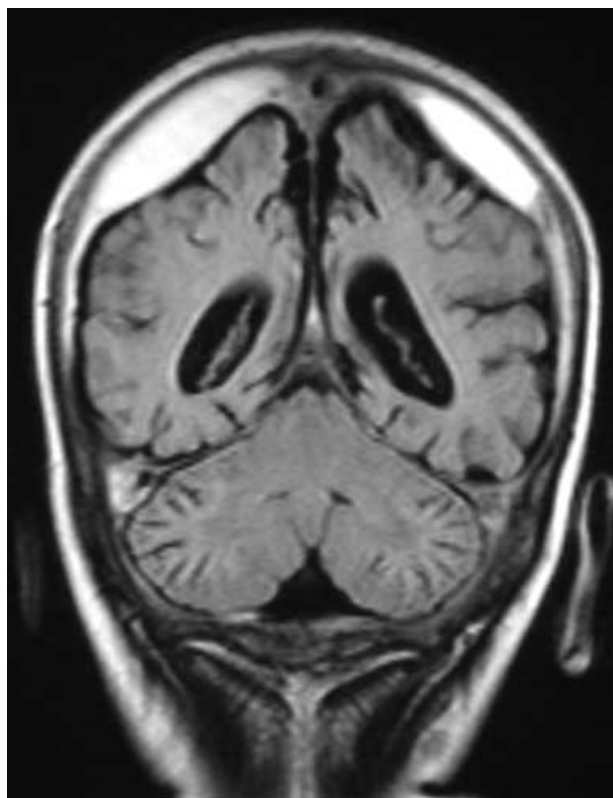


Fig. 1. Magnetic resonance imaging, fluid-attenuated inversion recovery, coronal view: Bilateral subdural hematoma and atrophy of the parietal lobes.

seizures were still present, although not all jerks observed clinically showed accompanying spikes on the EEG. PHT was added to phenobarbitone shortly after extubation.

Brain MRI 1 week later demonstrated marked contrast enhancement of the cortex as a consequence of an impaired blood–brain barrier. All changes were compatible with severe hypoxic brain damage. Despite further anticonvulsive treatment (phenobarbitone in combinations with vigabatrin, topiramate, levetiracetam, and intermittent benzodiazepine), polytopic myoclonic jerks continued. Fundoscopy revealed mild pallor of the optic nerve. No visual fixation was seen, and the blink reflex was absent. At 9 months, he still was severely hypotonic with few spontaneous movements and no visual contact. EEG persistently showed abnormal background activity and sharp slow waves, especially from both frontotemporal regions. Head growth was decelerated. At 11 months, limited visual contact and spontaneous motor activity reappeared. Myoclonic and other seizures persisted. MRI demonstrated large subdural hematomata and progressive supratentorial atrophy (Fig. 1).

Biochemical investigations in urine during the first 24 hours of admission by HPLC-MS-MS (3,4) revealed increased dihydrouracil (69 mmol/mol creatinine; controls, 6.3 ± 5.3), dihydrothymine (169 mmol/mol creatinine; controls, 3.1 ± 2.1), ureidopropionate (691 mmol/mol cre-

atinine; controls, 11.0 ± 9.2), and ureidoisobutyrate (548 mmol/mol creatinine; controls, 1.8 ± 2.3), suggesting a β -ureidopropionase deficiency (2). Ureidopropionase activity was undetectable in hepatocytes (<0.17 nmol/mg/h; controls, 69 ± 37) (2). DNA analysis revealed homozygosity for an IVS8-1G>A mutation (2).

Although fever is well known to trigger seizures, the question arose whether the patient's status epilepticus was the consequence of acute hypoxic brain damage during an "acute life-threatening event" (ALTE). However, he immediately recovered to complete alertness with just some additional oxygen, which is atypical for children just after severe cerebral hypoxia. The sudden cyanosis during admission also remained obscure. In retrospect, a convulsive event is the most likely explanation, although all further seizures showed tonic, clonic, and myoclonic elements. ALTE usually describes ill-defined events in which infants become hypoxic. Reasons may be metabolic (e.g., in case of severe hypoglycemia). In many children, nonmetabolic causes such as acute hyperthermia or mechanical obstruction of airways are alternative causes of ALTE. His status epilepticus was unusually difficult to treat. This prompted us to investigate for inborn errors of metabolism. Urinary pyrimidine metabolites suggested β -ureidopropionase deficiency.

A further unexpected finding was the vast subdural hematomata at age 11 months, which had not been present at day 17 of the acute illness. Gastric bleeding was present only on day 1; coagulation studies normalized in due course, and clinically, no acute events during the following months were observed. No evidence of nonaccidental injury was found. We hypothesize that the progressive brain atrophy was the cause: tension exerted on the subdural veins caused some to rupture. This phenomenon has been described in the context of adrenocorticotrophic hormone (ACTH) therapy for West syndrome (5). Therefore we do not think that a direct causal link to the metabolic defect is present, as can be suspected in some other metabolic diseases such as glutaric aciduria type I or Menkes disease.

At present, four patients with ureidopropionase deficiency, including our patient, are known. Molecular and biochemical data of those have been reported recently (2). No relation between the metabolite concentration and the reported clinical abnormalities was noted. The first patient showed different neurologic symptoms with primary developmental delay, dystonia, and delayed myelination as hallmarks (1). The two other patients did have seizures (2). In addition to those patients, one asymptomatic newborn from Japan was found during a pilot newborn screening study (6). If newborn screening for this disorder were performed, the ratio of asymptomatic to symptomatic cases might increase.

Differential diagnosis may include other inborn errors of metabolism like organic acidurias or some urea cycle defects, which can, however, be easily excluded by analysis of organic and amino acids, ammonia, orotic acid,

and acylcarnitines. All these parameters were found to be within normal ranges in our patient.

In conclusion, in patients with unexplained convulsions, psychomotor retardation, or ALTE-like events, screening for inborn errors of metabolism should include analysis of urinary pyrimidines, especially for β -ureidopropionate and ureidoisobutyrate as most important indicators.

REFERENCES

1. Assmann B, Göhlich-Ratmann G, Bräutigam C, et al. Presumptive ureidopropionase deficiency as a new defect in pyrimidine catabolism found with in vitro H-NMR spectroscopy. *J Inher Metab Disord* 1998;21:1.
2. Van Kuilenburg AB, Meinsma R, Beke E, et al. β -Ureidopropionase deficiency: an inborn error of pyrimidine degradation associated with neurological abnormalities. *Hum Mol Genet* 2004;13:2793–2801.
3. Van Lenthe H, van Kuilenburg AB, Ito T, et al. Defects in pyrimidine degradation identified by HPLC-electrospray tandem mass spectrometry of urine specimens or urine-soaked filter paper strips. *Clin Chem* 2000;46:1916–1922.
4. Van Kuilenburg AB, van Lenthe H, van Cruchten A, et al. Quantification of 5,6-dihydrouracil by HPLC-electrospray tandem mass spectrometry. *Clin Chem* 2004;50:236–238.
5. Ito M, Miyajima T, Fujii T, et al. Subdural hematoma during low-dose ACTH therapy in patients with West syndrome. *Neurology* 2000;54:2346–2347.
6. Ohse M, Matsuo M, Ishida A, et al. Screening and diagnosis of beta-ureidopropionase deficiency by gas chromatographic/mass spectrometric analysis of urine. *J Mass Spectrom* 2002;37:954–962.