

## CASE REPORT

# Intracranial vertebral artery dissection mimicking acute peripheral vertigo

ARATA HORII, KAORU OKUMURA, TADASHI KITAHARA, & TAKESHI KUBO

*Department of Otolaryngology, Osaka University Medical School, Osaka, Japan*

### Abstract

When diagnosing and treating patients with acute vertigo, the clinician must differentiate brain lesions from benign peripheral disorders. We here report a rare case of acute vertigo caused by intracranial vertebral artery dissection mimicking peripheral disease. A 67-year-old man presented with spontaneous nystagmus and moderate ataxia preceded by neck pain. No other neurological signs were observed, suggesting acute peripheral vertigo. However, magnetic resonance imaging (MRI) demonstrated a cerebellar infarction. Simultaneous magnetic resonance angiography (MRA) showed no flow void of the left vertebral artery and contrast-enhanced MRA demonstrated a double lumen sign, suggesting that vertebral artery dissection was a cause of infarction. The clinical course was favorable without anticoagulation drugs, which are sometimes contraindicated because of the potential risk of subarachnoid hemorrhage. Vertebral artery dissection can cause cerebellar infarction in patients without vascular risk factors mimicking acute peripheral vertigo. Careful history regarding the neck pain is important and MRA in combination with MRI can replace angiography in diagnosing this disorder.

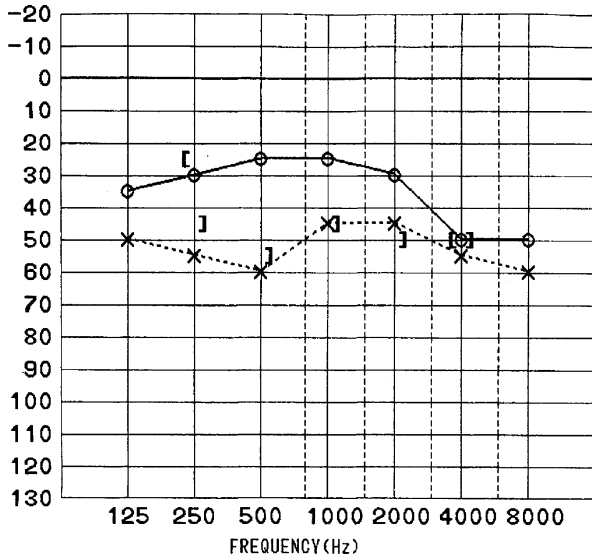
**Keywords:** *Vertebral artery dissection, vertigo, MRI, MRA, intracranial, neck pain, anticoagulation*

### Introduction

When diagnosing and treating patients with acute vertigo/dizziness, the clinician must differentiate brain lesions from benign peripheral vestibular disorders. The most frequent and important central diseases manifesting vertigo/dizziness are cerebellar hemorrhage and Wallenberg's syndrome (lateral medullary syndrome). These diseases usually cause not only vertigo/dizziness but also severe headache and disturbance of sensation, respectively. We here report an unusual case of cerebellar infarction caused by vertebral artery dissection mimicking acute peripheral vertigo. It should be emphasized that magnetic resonance angiography (MRA) is a safe and useful modality to detect dissection as a cause of cerebellar infarction and that anticoagulation drugs are sometimes contraindicated because of the potential risk of subarachnoid hemorrhage in the treatment of intracranial vertebral artery dissection.

### Case report

A 67-year-old man presented with a 5-day history of acute vertigo and dizziness. He had no risk or complications of vascular diseases such as diabetes mellitus or myocardial infarction. He underwent a computed tomography (CT) scan of the brain at the onset of dizziness, which demonstrated no abnormal findings. On examination, his consciousness was clear and he responded appropriately to questions with good orientation. All vital signs were normal. Otologic and neurologic examination revealed spontaneous nystagmus beating on the right side, moderate gait ataxia, and left sensorineural hearing loss of 48.8 dB (Figure 1). Other cranial nerves were intact and no focal signs were found. No cerebellar signs such as an adiadochokinesis or poor performance of finger to nose test were found. A careful history was taken and revealed that 6 hours before the onset of vertigo, he had left posterior headache and neck pain when turning his neck and that he had



	AVE. 4		AVE. 6	
	AIR	BONE	AIR	BONE
R	26.3dB	-	30.8dB	-
L	48.8dB	48.8dB	49.2dB	49.2dB

Figure 1. Pure tone audiometry showed left sensorineural hearing loss of 48.8 dB; however, this had been present for several years and was not changed by the onset of vertigo.

had left hearing loss for several years. We initially thought that he was suffering from acute vertigo of left peripheral origin such as vestibular neuritis and started an infusion and bed rest after admission to our hospital. However, bithermal caloric testing did not indicate a peripheral lesion; the canal paresis percentage (CP% = inter-ear difference of caloric response) was just 20%. In order to rule out a brain lesion, he underwent magnetic resonance imaging (MRI) and MRA, which demonstrated an infarction of the left cerebellar hemisphere (Figure 2A) and no flow void of the left vertebral artery (Figure 2B),

respectively. Contrast-enhanced MRA demonstrated a double lumen sign of the affected artery at the entry level of the subarachnoid space (Figure 3), indicating intracranial vertebral artery dissection. Angiography was not performed due to his poor renal function and the risk of enlargement and progression of dissection. He was not treated with anticoagulation drugs; however, his clinical course was favorable. Spontaneous nystagmus disappeared 12 days after the onset. Six months later, he had no symptoms, although MRA still showed no flow void of the left vertebral artery.

**Discussion**

Dissection of the carotid or vertebral arteries is rare, accounting for just 2% of all ischemic attacks [1]. Vertebral artery dissection is characterized by the sudden onset of craniocervical pain followed by delayed or progressive infarction [1]. This pain is related to a nociceptor stimulation of vascular wall due to dissection. Except for spontaneous dissections with cystic medial degenerations and fibromuscular dysplasia, vertebral artery dissection is most often caused by sudden mechanical injury to the vertebral artery from rotational contusion [2]. Therefore, it is noteworthy that vertebral artery dissection can occur in patients without vascular risk factors as in our case and the age profile is younger than for thrombotic or embolic infarction [1]. To date, there have been just a few reports describing sudden vertigo as the first symptom of vertebral artery dissection [3,4]. As in our case, vertebral artery dissection manifests only as acute vertigo/dizziness without other neurological signs and preceded by neck pain.

Oto-neurological examination of our patient showed spontaneous nystagmus beating on the right

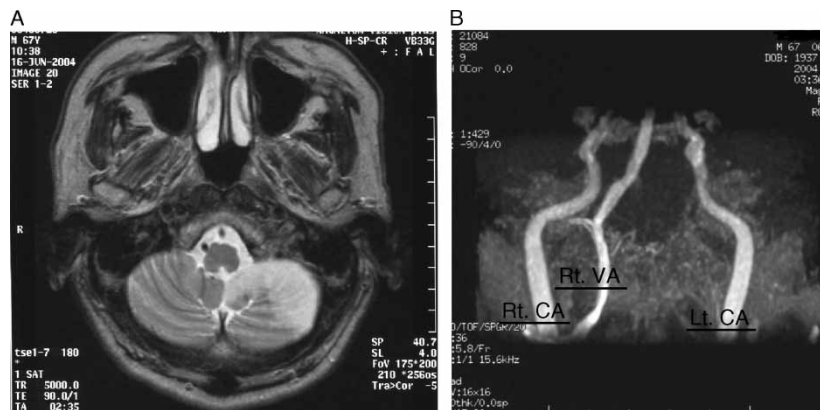


Figure 2. T2-weighted magnetic resonance imaging (A) and magnetic resonance angiography (B). T2-weighted MRI showed a high intensity area in the left cerebellar hemisphere (A) and MRA showed no flow void in the left vertebral artery, suggesting cerebellar infarction due to vertebral artery dissection (B). Rt. CA, right carotid artery; Rt. VA, right vertebral artery; Lt. CA, left carotid artery.

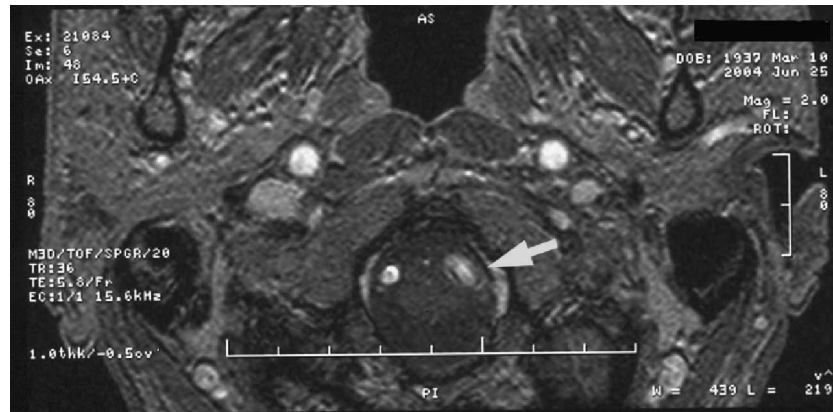


Figure 3. Contrast-enhanced magnetic resonance angiography (CE-MRA). Double lumen sign of the left vertebral artery was shown in CE-MRA (arrow), indicating vertebral artery dissection.

side along with left sensorineural hearing loss. No other neurological signs were observed, mimicking acute peripheral vestibular vertigo. Although careful history revealed that he had had hearing loss for several years, we initially suspected peripheral vertigo, such as vestibular neuritis, rather than central vertigo. The spontaneous nystagmus lasted for 12 days, which is relatively long compared with that seen in peripheral vertigo. No changes in hearing after onset and caloric testing (CP% = 20%) also did not support a peripheral disorder such as acute circulatory shutdown of the labyrinthine artery. We supposed that the gait ataxia was due to the infarction of cerebellar hemisphere. It is uncertain why this patient showed spontaneous nystagmus, even though the lesion did not extend to the vestibulo-cerebellum such as flocculus and vermis. There still remains a possibility that the appearance and disappearance of spontaneous nystagmus were due to transient ischemia of the brainstem vestibular nuclei, which could not be detected by MRI.

MRI demonstrated an infarction of the left cerebellar hemisphere. Intramural hematoma can sometimes be detected in T1-weighted images of MRI as a sign of artery dissection [5]. Simultaneous MRA was important to detect vertebral artery dissection as a cause of infarction. In our case, MRA showed no flow void in the affected vertebral artery and contrast-enhanced MRA demonstrated a double lumen sign. These are signs of artery dissection and MRA can replace angiography, particularly in at-risk patients, as suggested previously [6].

In the treatment of extracranial artery dissection, cerebral ischemia probably results from secondary thrombotic and embolic complications of the dissection rather than hemodynamic mechanisms, and thus anticoagulation has been recommended [1]. However, in cases of intracranial artery dissection, as in our case, subarachnoid bleeding can occur,

making anticoagulation a potential risk [7,8]. As our patient experienced only vertigo/dizziness, anticoagulation drugs were not used in order to prevent secondary hemorrhage. Fortunately, the symptoms finally disappeared without this treatment.

In conclusion, vertebral artery dissection can cause cerebellar infarction mimicking acute peripheral vertigo in patients without vascular risk factors. Careful history regarding craniocervical pain following neck rotation is important in diagnosing vertebral artery dissection. MRI and MRA are safe and useful approaches to detect ischemic changes in the cerebellum and dissection of the vertebral artery, respectively. It should be noted that the use of anticoagulation drugs is controversial and is sometimes contraindicated in the treatment of intracranial vertebral artery dissection.

### Acknowledgements

We thank Drs A. Uno and K. Teramoto for helpful discussions.

### References

- [1] Dziewas R, Konrad C, Drager B, Evers S, Besselmann M, Ludemann P, et al. Cervical artery dissection – clinical features, risk factors, therapy and outcome in 126 patients. *J Neurol* 2003;250:1179–84.
- [2] Schievink WI. Spontaneous dissection of the carotid and vertebral arteries. *N Engl J Med* 2001;344:898–906.
- [3] Strome SE, Hartshorn DO, Carroll WR, Shepard N, Disher MJ. Otologic manifestations of vertebral artery dissection. *Otolaryngol Head Neck Surg* 1997;116:262–4.
- [4] Bonkowsky V, Steinbach S, Arnold W. Vertigo and cranial nerve palsy caused by different forms of spontaneous dissections of internal and vertebral arteries. *Eur Arch Otorhinolaryngol* 2002;259:365–8.
- [5] Iwama T, Andoh T, Sakai N, Iwata T, Hirata T, Yamada H. Dissecting and fusiform aneurysms of vertebro-basilar systems. MR imaging. *Neuroradiology* 1990;32:272–9.

- [6] Hosoya T, Watanabe N, Yamaguchi K, Kubota H, Onodera Y. Intracranial vertebral artery dissection in Wallenberg syndrome. *AJNR Am J Neuroradiol* 1994;15:1161–5.
- [7] Kitanaka C, Tanaka J, Kuwahara M, Teraoka A, Sasaki T, Takakura K, et al. Nonsurgical treatment of unruptured intracranial vertebral artery dissection with serial follow-up angiography. *J Neurosurg* 1994;80:667–74.
- [8] Arnold M, Nedeltchev K, Sturzenegger M, Schroth G, Loher TJ, Stepper F, et al. Thrombolysis in patients with acute stroke caused by cervical artery dissection: analysis of 9 patients and review of the literature. *Arch Neurol* 2002;59:549–53.

Copyright of *Acta Oto-Laryngologica* is the property of Taylor & Francis Ltd and its content may not be copied or emailed to multiple sites or posted to a listserv without the copyright holder's express written permission. However, users may print, download, or email articles for individual use.

Copyright of *Acta Oto-Laryngologica* is the property of Taylor & Francis Ltd and its content may not be copied or emailed to multiple sites or posted to a listserv without the copyright holder's express written permission. However, users may print, download, or email articles for individual use.