

Osman Kizilkilic
Sait Albayram
Özgür Kasapcopur
Ismail Mihmanli
Naci Kocer
Civan Islak

MRI findings of hypoxic cortical laminar necrosis in a child with hemolytic anemia crisis

Received: 18 February 2002
Revised: 28 June 2002
Accepted: 7 October 2002
Published online: 22 November 2002
© Springer-Verlag 2002

O. Kizilkilic · S. Albayram · I. Mihmanli
N. Kocer · C. Islak (✉)
Department of Radiology,
Division of Neuroradiology,
Cerrahpasa Medical Faculty,
34300 Istanbul, Turkey
e-mail: cislak@istanbul.edu.tr
Tel.: +90-212-5861586
Fax: +90-212-5884884

Ö. Kasapcopur
Department of Pediatrics,
Cerrahpasa Medical Faculty,
34300 Istanbul, Turkey

Abstract We present magnetic resonance imaging findings of a 5-year-old girl who had a rapidly installing hemolytic anemia crisis induced by trimethoprim–sulfomethoxazole, resulting in cerebral anoxia leading to permanent damage. Magnetic Resonance imaging revealed cortical laminar necrosis in arterial border zones in both cerebral hemispheres, ischemic changes in subcortical white matter of left cerebral hemisphere, and in the left putamen. Although cortical laminar necrosis is a classic entity in adulthood related to conditions of energy depletions, there are few reports available in children. A wide review of the literature is also presented.

Keywords Hypoxic encephalopathy · Hemolytic anemia · Cortical laminar necrosis · MRI

Introduction

In most type of anemias in the long term, compensatory mechanisms preserve brain oxygenation, but if anemia settles in a very short time, these compensatory mechanisms cannot be enough or in time, and it occasionally causes cerebral ischemia. In this report, we present a case of acutely settled hemolytic anemia that resulted in global cerebral hypoxia/anoxia and permanent damage. In rapidly settled anemia, such as hemolytic crisis, neurologic functions should be closely observed and every effort should be made in preserving enough oxygen supply to the brain. If there is any alteration of consciousness or appearance of convulsion observed during such a crisis, anemic-type hypoxia/anoxia should be kept in mind in differential diagnosis. Magnetic resonance imaging is the method of choice for demonstrating the lesions and making differential diagnosis.

Case report

We present a 5-year-old girl who had been surgically treated for lumbar meningocele in immediate neonatal period. Urinary tract infection and bilateral grade-4 hydronephrosis and neurogenic bladder appeared a year later. Recurrent urinary infection necessitated repeated antibiotic treatment. Last time she admitted to the hospital with suffering of fever while she was under trimethoprim–sulfomethaxazol (TMP–SMX) prophylaxis regimen for nearly 6 months. Body temperature was 38.7°C. Leukocytosis and urine data confirmed urinary infection and third-line ceftriaxone was added to TMP–SMX. Neurologic examination was normal.

On the third day of admission, hematuria and automatic mastication were observed. She had a generalized tonic–clonic seizure and she deteriorated. At the same time, blood data showed hemolysis and hemoglobin (Hb) level of 3.2 g/dl. Urine analysis revealed profound hemoglobinuria and microscopic hematuria. Direct Coombs test was positive. Hemolytic uremic syndrome (HUS), which is a disease of infancy and early childhood, was excluded by absence of thrombocytopenia, hypertension, and acute renal failure. The glucose-6-phosphate dehydrogenase level (8.7 U/g hemoglobin) was normal (6.4–15.6 U/g hemoglobin).

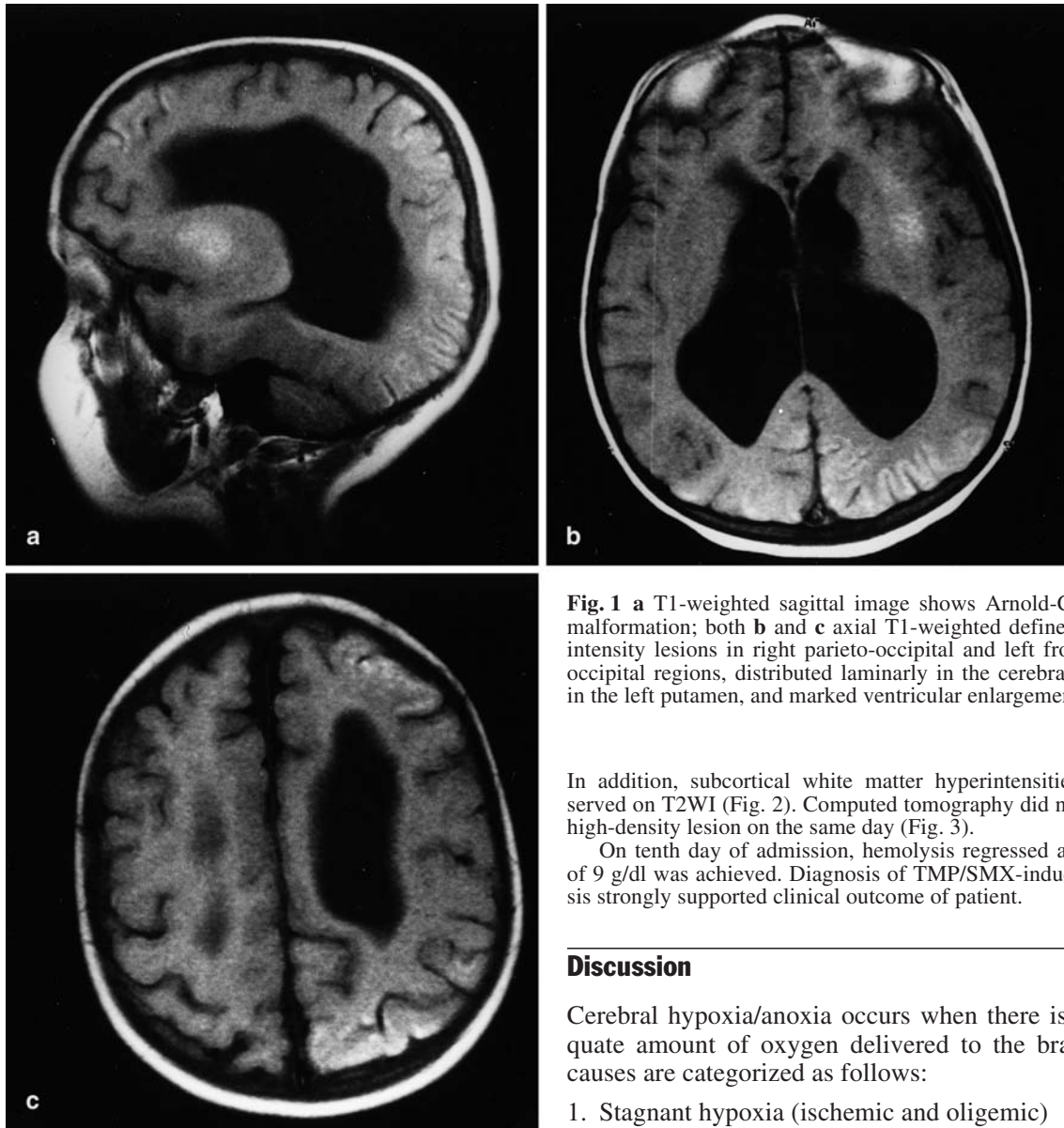


Fig. 1 a T1-weighted sagittal image shows Arnold-Chiari type-I malformation; both b and c axial T1-weighted define show high-intensity lesions in right parieto-occipital and left fronto-parieto-occipital regions, distributed laminarly in the cerebral cortex and in the left putamen, and marked ventricular enlargement

In addition, subcortical white matter hyperintensities were observed on T2WI (Fig. 2). Computed tomography did not show any high-density lesion on the same day (Fig. 3).

On tenth day of admission, hemolysis regressed and Hb level of 9 g/dl was achieved. Diagnosis of TMP/SMX-induced hemolysis strongly supported clinical outcome of patient.

Discussion

Cerebral hypoxia/anoxia occurs when there is an inadequate amount of oxygen delivered to the brain and its causes are categorized as follows:

1. Stagnant hypoxia (ischemic and oligemic)
2. Hypoxic hypoxia (airway obstruction, drowning, reduced inspired oxygen content)
3. Anemic hypoxia (carbon monoxide intoxication)
4. Histotoxic hypoxia affecting cellular respiratory enzymes (cyanide intoxication)

Although hypoglycemia is not a hypoxemic condition, since hypotension is usually associated with hypoglycemia and results in hypoxia, hypoglycemia is classified as the fifth group of cerebral hypoxia/anoxia. All types of cerebral hypoxic/anoxic conditions are generally associated with one type of anoxia or another. For example, in hypoxemic hypoxia, hypotension usually occurs and stagnant-type hypoxia follows [1].

Neurologic involvement can also be seen in HUS, which may cause acute hemolysis and has classical triad of microangiopathic hemolytic anemia, thrombocytopenia

Hemolytic anemia induced by TMP-SMX was the final diagnosis with these data.

Both TMP-SMX and ceftriaxone immediately stopped after these hemolytic findings. Antibiotic regimen changed with imipenem-cilastatin combination. Packed red blood cells transfused to patient with dosage of 10 cc/kg. Intravenous supportive treatment maintained blood pressure in normal limits. Anti-epileptic treatment was given and seizure stopped but consciousness never came back. She underwent cranial MR imaging on fifth day of deterioration because of extended unconsciousness. Sagittal T1-weighted images (T1WI) were revealed Arnold-Chiari type I coupled with high signal intensity lesions in the right parieto-occipital, left fronto-parieto-occipital, in the arterial border-zone distributed laminarly in the cerebral cortex, and in the left putamen (Fig. 1). The cerebellum and brain stem were normal. T2-weighted images (T2WI) revealed that some of these lesions were hypointense and some of these lesions were hyperintense compared with the normal cortex.

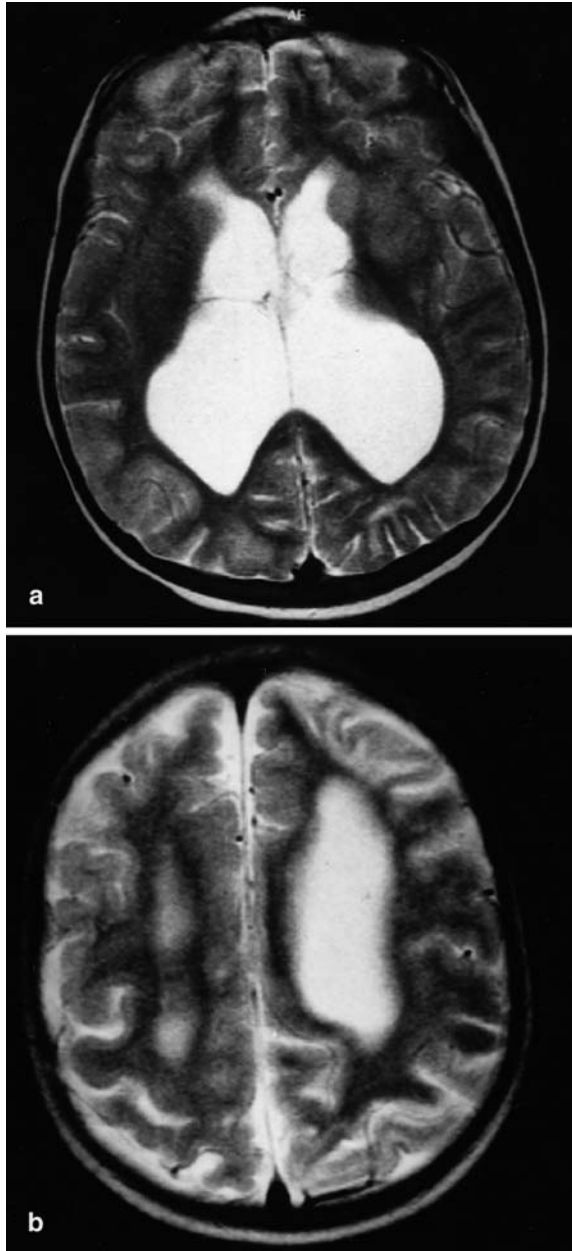


Fig. 2a, b T2-weighted axial MRI depicts the same lesions. Instead of cortical signal intensity, widespread hyperintensity on T1WI and T2WI is shown: both hypointense and hyperintense (dominant on left parietal lobe) lesions in the same areas. White matter involvement in subcortical region, and left putaminal ischemic changes, are seen as hyperintensities on T2WI. Prominent ventricular enlargement is also seen

nia, and uremia. Pathologic examination of brain in patients who die of HUS and neurologic dysfunction shows microthrombi in cerebral vessels and nonspecific changes or cerebral edema. Although the HUS is not a radiologic diagnosis, cerebral MRI findings of HUS include

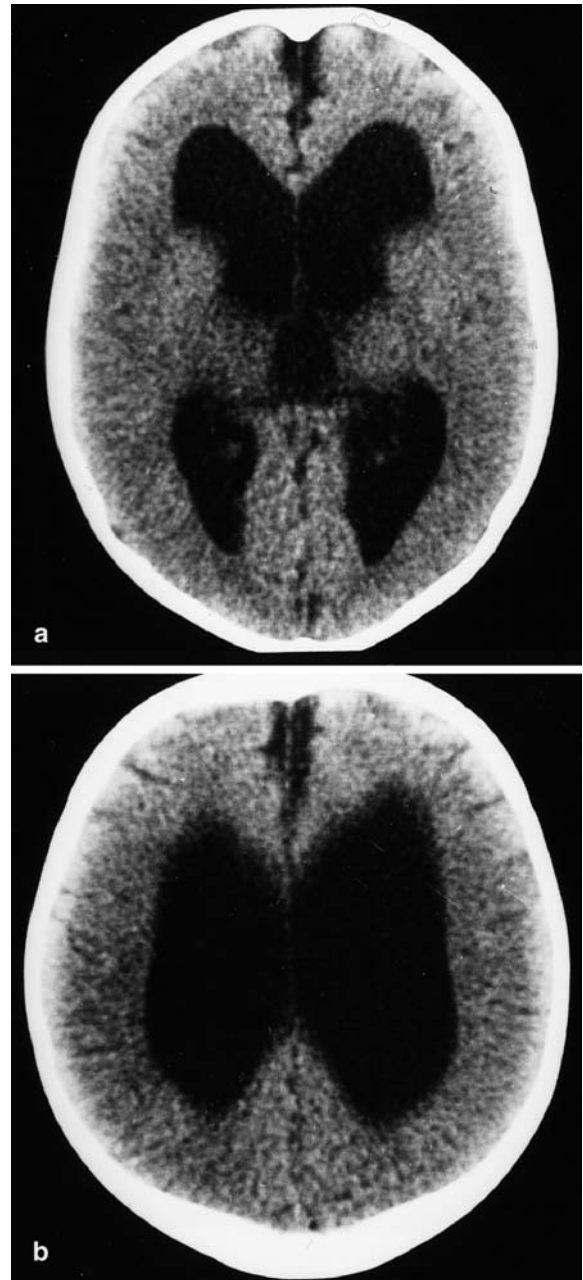


Fig. 3a, b Axial CT images reveal absence of high-density lesions in same areas

high signal intensity on both T1WI and T2WI, in lentiform nucleus, in the internal–external–extreme capsule, which indicates infarct with focal hemorrhage. Low signal intensity on T1- and high signal intensity on T2WI in the splenium of the corpus callosum also could be seen [2, 3]. The distributions of these lesions are different from those in our patient. Lesions in HUS are infarctions due to thrombi in microvessels, such as perforating arteries, which supply affected brain regions.

Although the sulfonamides are accepted as safe drugs, their list of possible adverse reactions is very long. They may cause a number of allergic reactions, from relatively minor skin rashes to severe or even life-threatening reactions. Their hematologic complications, which include agranulocytosis, hemolytic and megaloblastic anemia and thrombocytopenia, are usually dose related and frequently seen in patients with glucose-6-phosphate dehydrogenase deficiency. Although TMP-SMX rarely causes hemolysis in normal subjects, it was thought to be the cause of hemolysis in our patient and also glucose-6-phosphate dehydrogenase deficiency [4, 5]. This serious hemolysis resulted in deep anemia in very short time.

Anemia refers to low blood Hb level from whatever cause. Although oxygen carrying capacity of blood is compromised in anemia, in the mid- and long term, the compensatory mechanisms preserve adequate tissue oxygenation [1, 6]. The most prominent of such mechanisms is augmentation of cerebral blood flow (CBF). Regulation of CBF is a function of cerebral perfusion pressure (CPP) and cerebrovascular resistance (CVR). The CVR is synergistically mediated by chemical and neurogenic factors. Cerebral perfusion pressure is a function of mean arterial blood pressure and intracranial pressure. Any change in these variables will induce autoregulatory responses. Hematocrit also plays an important role for CBF regulation, and since it is the major determinant of blood viscosity any decrease in hematocrit level is associated with an increase in CBF and CBV. The increase of CBF is also related to active cerebrovascular dilation in response to reduced oxygen delivery and hypercapnia and improved rheology [6].

In chronic anemias, despite the very low Hb levels, sufficient oxygen supply to the brain is maintained. But if the Hb level decreases in a short time, or very rapidly as occurred in our patient, compensatory mechanisms cannot be enough or in time and cerebral hypoxia/anoxia may ensue reversible or irreversible cerebral ischemic changes [1]. There is no threshold value defined for Hb level below which cerebral hypoxia/anoxia may occur. Young and co-workers reported [7] a 2-year-old child with cerebral anoxia in whom Hb level of 4 g/dl and carotid stenosis were detected. In our patient, although no additional diseases were found, by the onset of hemolytic crisis Hb level had decreased from 9.8 to 3.2 g/dl within less than 6 h probably precluding the compensatory mechanisms from taking place or making them insufficient.

The clinical findings of cerebral ischemia vary with age and it tends to present with seizures, unconsciousness, and fever in children younger than 10 years [8]. In this patient, the beginning of the seizures after acute hemolytic crisis suggests that acute anemia resulting in anoxia was the triggering mechanism. Although the seizures stopped and normal blood pressure was main-

tained, unconsciousness was extended probably due to permanent brain damage.

In the cerebral global hypoxic/anoxic conditions cerebral cortex is the most commonly affected region and the white matter is completely or relatively spared. This observation can be explained by the fact that the white matter is metabolically less active than cortex [9, 10, 11]. Other explanations are found in the distribution of excitatory amino acid synapses and local physicochemical factors at cellular level and in vascular depositions. The distribution of ischemic lesions of brain can also be explained by the selective vulnerability of different regions. Basal ganglia are commonly affected probably due to their end-artery-type vascularization and lack of anastomoses and their high metabolic activity. Cerebral cortex in borderline area is also affected since it is metabolically active and the farthest point from the vascular supply. In addition, some other probable unknown factors determine the type and place of ischemic lesions in different etiologic pathologies and age groups.

In the present patient anemic type of global hypoxia/anoxia led to necrosis and demyelination in the watershed distribution of cerebral arteries. The lesions were in frontal, parietal, and occipital lobes, and in the left putamen. The cortical lesions were distributed with a gyri-form pattern in the bases of the sulci and were marked in the arterial watershed zones. These characteristics are compatible with the radiologic findings of cortical laminar necrosis [2, 3, 11, 12].

Hyperintense cortical lesions associated with cerebral ischemia on unenhanced T1WI may represent methemoglobin/hemorrhage, paramagnetic substances, fat tissue, calcification, high protein concentration, and cortical laminar necrosis [13]. Boyko et al. reported that cortical T1-weighted hyperintense lesions in cases of brain infarction histopathologically presented as cortical laminar necrosis without hemorrhage or calcification [14]. Computed tomography did not reveal any high-density lesion so we thought that T1-weighted hyperintense lesions did not reflect calcification or hemorrhage. Cortical laminar necrosis can be histologically defined as pan-necrosis including neurons, glia, and blood vessels in the affected area. One possible result of pan-necrosis is protein degradation. As T1 shortens, protein degradation is very closely related to the MR signals [13]. Takahashi et al. reported hypointensity on T2WI with a poor clinical outcome [11]. Although protons in proteins do not usually contribute to the MR signals, the protein concentration and amount of free water may influence the T1 and T2 relaxation characteristics [14].

Fluid-attenuated inversion recovery (FLAIR) sequences have been found to be normal in the first month of cortical lesions. Since we had enough data with conventional sequences, we did not perform FLAIR sequence in this patient. The FLAIR images are superior for detecting brain infarction, especially of cortical lesions. On the other hand, diffusion-weighted MR imag-

ing has been shown to be highly sensitive for the diagnosis of cerebral infarction in the acute stage, which was not available in our institution previously.

Although we have no pathologic proof, lesions demonstrated on MRI may be compatible with deposition of fat-laden macrophages and protein degradation at the necrosis site, whereas the same lesions were seen as both hypointense and hyperintense on T2WI due to protein–water content interrelation and deposition of fat-laden macrophages.

Cortical laminar necrosis comprises ischemic neuronal changes and the gliotic reaction. It is accompanied by the laminar deposition of fat-laden macrophages. It is likely that the high signal intensity lesions in our patient reflect necrosis of cortical neurons and the resultant tissue necrosis. Identification of cortical laminar necrosis witnesses the global nature of ischemia rather than local factors.

Conclusion

In most types of anemias in the long term, compensatory mechanisms preserve brain oxygenation. Unless anemia takes place in a very short time and results in very low Hb levels, it rarely causes cerebral ischemia. Therefore, in rapidly settled anemias, such as hemolytic crisis, neurologic functions should be closely observed and every effort should be done in preserving enough oxygen supply to the brain. Although it is rare, if any alteration of conscious or appearance of convulsion is observed during such a crisis, anemic-type hypoxia/anoxia should be kept in mind. This appears to be the case especially when Hb level decreases below 4 g/dl. Magnetic resonance imaging is the method of choice, not only for demonstrating the lesions but also for making differential diagnosis.

References

1. Auer RN, Benveniste H (1997) Hypoxia and related conditions. In: Graham DI, Lantos PL (eds) *Greenfield's neuropathology*, vol 1, 6th edn. London, pp 263–314
2. Sheth KJ, Swick HM, Haworth N (1986) Neurological involvement in hemolytic uremic syndrome. *Ann Neurol* 19:90–93
3. Ogura H, Takaoka M, Kishi M et al. (1998) Reversible MR findings of hemolytic uremic syndrome with mild encephalopathy. *Am J Neuroradiol* 19:1144–1145
4. Gribble MJ, Puterman ML (1993) Prophylaxis of urinary tract infection in persons with recent spinal cord injury: a prospective, randomized, double blind, placebo-controlled study of trimethoprim–sulfamethoxazole. *Am J Med* 95:141–152
5. Mitchell AA, Lacouture PG, Sheehan JE, Kauffman RE, Shapiro S (1988) Adverse reactions in children leading to hospital admission. *Pediatrics* 82:24–49
6. Werner C, Kochs E, Hoffman WE (1997) Cerebral blood flow and metabolism. In: Albin MS (ed) *Textbook of neuroanesthesia with neurosurgical and neuroscience perspectives* McGraw-Hill, New York, pp 21–61
7. Young RSK, Rannels DE, Hilmo A, Gerson JM, Goodrich D (1983) Severe anemia in childhood presenting as transient ischemic attacks. *Stroke* 14:622–623
8. Barkowich AJ (2000) Toxic and metabolic brain disorders. In: *Pediatric neuroimaging*. Lippincott Williams and Wilkins, Philadelphia, pp 71–157
9. Jensen MC, Brant-Zawadzki MN, Jacobs BC (1999) Ischemia. In: Stark DD, Bradley WG (eds) *Magnetic resonance imaging*, vol 3, 3rd edn. Mosby, St. Louis, pp 1264–1266
10. Van der Knaap MS (1995) Delayed posthypoxic leukoencephalopathy of maturity. In: *Magnetic resonance imaging of myelin, myelination and myelin disorders*. Springer, Berlin Heidelberg New York, pp 387–392
11. Takahashi S, Higano S, Ishii K, Matsumoto K, Sakamoto K, Iwasaki Y, Suzuki M (1993) Hypoxic brain damage: cortical laminar necrosis and delayed changes in white matter at sequential MR imaging. *Radiology* 189:449–456
12. Sawada H, Udaka F, Seriu N, Shindou K, Kameyama M, Tsujimura M (1990) MRI demonstration of cortical laminar necrosis and delayed white matter injury in anoxic encephalopathy. *Neuroradiology* 32:319–321
13. Komiyama M, Nakajima H, Nishikawa M, Yasui T (1998) Serial observation of cortical laminar necrosis caused by brain infarction. *Neuroradiology* 40:771–777
14. Boyko OB, Burger PC, Shelburne JD, Ingram P (1992) Non-heme mechanisms for T1 shortening: pathologic, CT, and MR elucidation. *Am J Neuroradiol* 13:1439–1445