

TABLE 1. Variants identified in the protein-coding sequence of *SLC18A2*, the gene for *VMAT2*

Exon	Position	Variant	Amino acid	DATATOP (chroms)	DATATOP (frequency)
2	n.v				
3	65	G/A	Synonymous	1	0.001
	83	T/G	Synonymous	33	0.037
	5' +23-24	del	Noncoding	33	0.037
4	n.v				
5	5'-29	G/A	Noncoding	1	0.001
	25	C/G	A→G	1	0.001
	38	T/C	Synonymous	1	0.001
6	3' +15	T/C	Noncoding	6	0.007
7.8.9	748	C/T	T→M	1	0.001
	73' +14	C/T	Noncoding	1	0.001
	73' +52	C/T	Noncoding	35	0.039
	73' +54	T/C	Noncoding	107	0.119
	73' +71	A/C	Noncoding	104	0.116
	85'-9	A/G	Noncoding	2	0.002
10	5'-75-80	del	Noncoding	1	0.001
	5'-66	T/A	Noncoding	1	0.001
	5'-54	C/T	Noncoding	1	0.001
	3' +53	C/T	Noncoding	6	0.007
11.12	115'-59	T/G	Noncoding	12	0.013
	11 5'-31	T/C	Noncoding	1	0.001
	12 3' +20	C/T	Noncoding	15	0.017
13	n.v				
14	n.v				
15	n.v				
16	n.v				

Only protein coding exons (2-16) were screened. Positions refer to nucleotide positions within the sequence of the exon or relative to the 5' and 3' end of the exon.
n.v., no variants.

References

1. Liu Y, Edwards RH. The role of vesicular transport proteins in synaptic transmission and neural degeneration. *Annu Rev Neurosci* 1997;20:125-156.
2. Langston JW, Irwin I. MPTP: current concepts and controversies. *Clin Neuropharmacol* 1986;9:485-507.
3. Rochet JC, Outeiro TF, Conway KA, et al. Interactions among alpha-synuclein, dopamine, and biomembranes: some clues for understanding neurodegeneration in Parkinson's disease. *J Mol Neurosci* 2004;23:23-34.
4. PSG. DATATOP: a multicenter controlled clinical trial in early Parkinson's disease. Parkinson Study Group. *Arch Neurol* 1989;46:1052-1060.
5. Glatt CE, DeYoung JA, Delgado S, et al. Screening a large reference sample to identify very low frequency sequence variants: comparisons between two genes. *Nat Genet* 2001;27:435-438.
6. Burman J, Tran CH, Glatt C, Freimer NB, Edwards RH. The effect of rare human sequence variants on the function of vesicular monoamine transporter 2. *Pharmacogenetics* 2004;14:587-594.
7. Lin Z, Walther D, Yo XY, Li S, Drgon T, Uhl GR. *SLC18A2* promoter haplotypes and identification of a novel protective factor against alcoholism. *Hum Mol Genet* 2005;14:1393-1404.

Symptomatic Vascular Dystonia in Celiac Disease

Celiac disease (CeD) is a gluten-induced enteropathy characterized by malabsorption, structural abnormality of the intestine, and occurrence of IgG antigliadin antibodies. Ataxia and neuropathy are the most frequent neurological symptoms, occurring in 6% of patients with CeD,¹ which may precede gastrointestinal manifestations.² Furthermore, there are two reports of isolated cerebral vasculitis in CeD^{3,4} and also one report of hemidystonia as a late symptom of CeD.⁵

A 43-year-old woman complained of neck stiffness, left arm and leg weakness, and attentional deficits for 2 weeks. A space-occupying hypodensity adjacent to the frontal horn of the right lateral ventricle was accidentally revealed by computer tomography (CT; Fig. 1A). Neurological investigation exhibited segmental fixed dystonia with dominantly laterocollis to the left, as well as dystonia in the left arm and slight left-sided hemiparesis. Neuro-

Published online 26 January 2006 in Wiley InterScience (www.interscience.wiley.com). DOI: 10.1002/mds.20791

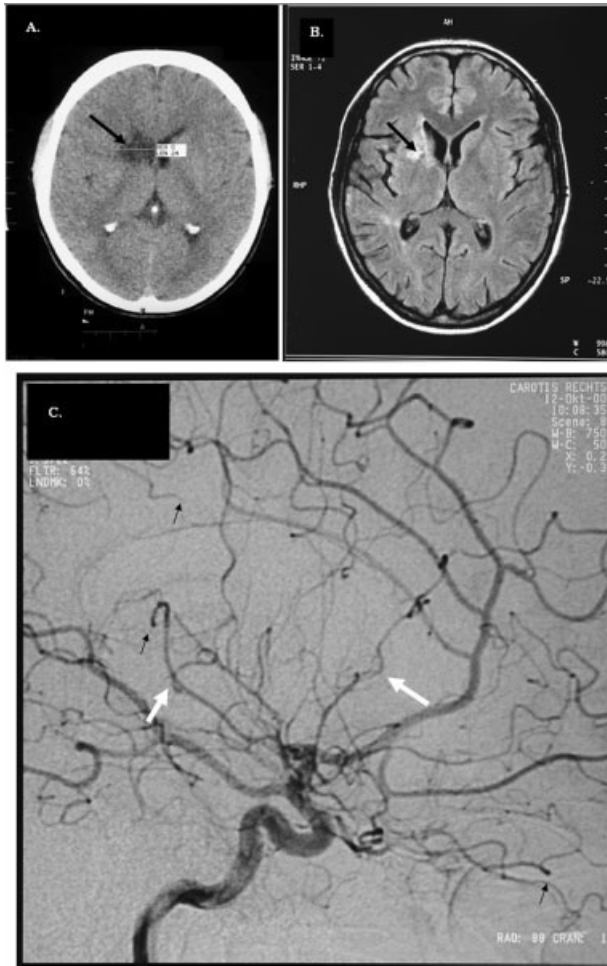


FIG. 1. Cerebral CT, MRI, and angiography scans. **A:** CT scan. Hypodense lesion in the right temporal lobe. **B:** FLAIR imaging. Signal-intense lesion in the caudate nucleus, the internal capsule, and the lenticular nucleus. **C:** Cerebral digital subtraction angiography (right carotid artery, sagittal view) revealing multiple typical signs of cerebral vasculitis, including nonspecific multifocal segmental dilations and narrowing (white arrows) affecting all three major vascular territories. Furthermore, there are multiple occlusions (black arrows).

psychological examination revealed slight attentional deficits. T2-weighted and FLAIR cranial magnetic resonance imaging (MRI) showed a right-sided hyperintense lesion in caudate nucleus, internal capsule, and lenticular nucleus (Fig. 1B). Cerebral digital subtraction angiography confirmed the diagnosis of a cerebral vasculitis showing multiple stenoses and occlusions of small vessels in both middle artery territories as well as stenoses of the trifurcation of the left middle cerebral artery and the main stem of the right medial cerebral artery (Fig. 1C).

After a diagnosis of isolated cerebral vasculitis was made, high-dose methylprednisolone was given (starting dose 500 mg/day, then decreasing stepwise). Segmental dystonia improved significantly within 4 to 5 weeks. Only slight dystonia of the left hand and attentional deficits remained. Five weeks later, MRI showed size reduction of the right hyperintense striatocapsular affection. After first signs of steroid-induced

Cushing syndrome developed, therapy was changed to cyclophosphamide, according to the scheme by Austin and colleagues,⁶ applied every 3 month in a total of 12 pulses.

Twelve weeks after onset of segmental dystonia, the patient complained of diarrhea, sickness, and weight loss of 4 kg within 5 months. Tests for a specific gastrointestinal infection were negative. Duodenal biopsy revealed a pronounced villous atrophy and cellular infiltrates typically found in CeD. Anti-gliadin and antiendomysial antibodies were elevated (anti-gliadin IgA > 100.0 U/mL [normal: < 11.0 U/mL]; anti-gliadin IgG > 100.0 U/mL [normal: < 11.0 U/mL]; antiendomysial IgA > 110.0 U/L [normal: < 4.0 U/L]). After the patient had been treated with a gluten-free diet for 12 weeks, all gastrointestinal symptoms resolved within 4 weeks. Since establishment of a diet and immunosuppressive therapy, dystonic symptoms improved and never reappeared. Six months after beginning of this therapy, anti-gliadin antibodies were decreased but still abnormal (anti-gliadin IgA 38.8 U/mL [normal: < 11.0 U/mL]; anti-gliadin IgG 582.0 U/mL [normal: < 11.0 U/mL]).

In the present CeD patient with acutely occurring symptomatic vascular segmental dystonia due to an ischemic lesion from isolated cerebral vasculitis, neurological symptoms became overt before manifestation of the typical enteropathy of CeD. CeD prevalence is reported only 1% in normal population⁷ and isolated cerebral vasculitis is very rare. Prevalence of isolated cerebral vasculitis is reported as 1% of all cerebrovascular diseases.⁸ It could be suggested that the present case only demonstrates an accidental coincidence of CeD and isolated cerebral vasculitis. Because of the clear temporal concurrence of dystonia due to a vasculitic lesion and CeD and improvement of dystonia after combined dietetic and immunosuppressive therapy, a causative relationship between them may be possible. CeD-induced inflammation is not, however, confined to the gut, as activated HLA-restricted gliadin-specific T cells and anti-gliadin antibodies are found systemically.^{9,10} In some cases, anti-gliadin antibodies can even be detected in the cerebrospinal fluid.¹¹ Cerebral postmortem studies in CeD revealed inflammatory processes with perivascular cuffing with CD4⁺ and CD8⁺ cells primarily seen in the cerebellum,¹² but also in other cerebral structures. The pathophysiological mechanisms underlying an early CNS manifestation as well as cerebral vasculitis in CeD remain unclear.

Our case demonstrates that symptomatic vascular dystonia due to cerebral vasculitis may also be an early manifestation of CeD and occur prior to the typical enteropathy of CeD.

Matthias Wittstock, MD*

Department of Neurology

University of Rostock

Rostock, Germany

*E-mail: matthias.wittstock@med.uni-rostock.de

Annette Grossmann, MD

Institute of Diagnostic and Interventional Radiology

University of Rostock

Rostock, Germany

Erwin Kunesch, MD

Department of Neurology

University of Rostock

Rostock, Germany

Reiner Benecke, MD
 Department of Neurology
 University of Rostock
 Rostock, Germany

References

1. Holmes GK. Neurological and psychiatric complications in coeliac disease. In: Gobbi G, Andermann F, Naccarato S, Banchini G, editors. *Epilepsy and other neurological disorders in coeliac disease*. London: John Libbey; 1997. p 251–264.
2. Muller AF, Donnelly MT, Smith CM, Grundman MJ, Holmes GK, Toghill PJ. Neurological complications of celiac disease: a rare but continuing problem. *Am J Gastroenterol* 1996;91:1430–1435.
3. Rush PJ, Inman R, Bernstein M, Carlen P, Resch L. Isolated vasculitis of the central nervous system in a patient with celiac disease. *Am J Med* 1986;81:1092–1094.
4. Özge A, Karakelle A, Kaleagasi H. Celiac disease associated with recurrent stroke: a coincidence or cerebral vasculitis? *Eur J Neurol* 2001;8:373–374.
5. Fung VS, Duggins A, Morris JG, Lorentz IT. Progressive myoclonic ataxia associated with celiac disease presenting as unilateral cortical tremor and dystonia. *Mov Disord* 2000;15:732–734.
6. Austin HA, Klippel JH, Balow JE, et al. Therapy of lupus nephritis: controlled trial of prednisone and cytotoxic drugs. *N Engl J Med* 1986;314:614–619.
7. Dubé C, Rostom A, Richmond SY, et al. The prevalence of celiac disease in average-risk and at-risk western European populations: a systematic review. *Gastroenterology* 2005;128:S57–S67.
8. Caplan LR. *Stroke: a clinical approach*, vol. 2, Boston: Butterworth-Heinemann; 1993.
9. Sollid LM, Thorbs E. HLA susceptibility genes in celiac disease: genetic mapping and role in pathogenesis. *Gastroenterology* 1993; 105:910–922.
10. Jensen K, Sollid LM, Scott H, et al. Gliadin-specific T cell response in peripheral blood of healthy individuals involve T cells restricted by the coeliac disease associated DQ2 heterodimer. *Scand J Immunol* 1995;42:166–170.
11. Chinnery PF, Reading PJ, Milne D, et al. CSF antigliadin antibodies and the Ramsay Hunt syndrome. *Neurology* 1997;49:1131–1131.
12. Hadjivassiliou M, Grünewald R, Sharack B, et al. Gluten ataxia in perspective: epidemiology, genetic susceptibility and clinical characteristics. *Brain* 2003;126:685–691.

Primary Focal Lingual Dystonia

Dystonic involvement of the tongue is a well recognized feature of tardive dystonia as well as oromandibular dystonias, both primary and secondary.¹ However, primary focal lingual dystonia (PFLD) has only rarely been described.^{2–4} We present the case of a patient with speech-induced PFLD and discuss the clinical characteristics, treatment variables, and outcome of this rare disorder.

A 39-year-old, right-handed, Caucasian male postal worker was first evaluated for involuntary tongue movements. The patient's complaints developed over a few weeks 2 years prior to presentation when his tongue "curled" with any attempt to speak, causing slurred speech. The symptoms were not present

during mastication or swallowing. Although no alcohol dependence was reported, stress caused symptom exacerbation.

After causes of secondary lingual dystonia were excluded, including tardive dyskinesia, Wilson's disease, and neuroacanthocytosis, the patient started and gradually increased trihexyphenidyl treatment to 10 mg a day with mild (~20%) improvement. The patient also reported considerable improvement with the use of jaw clenching during speaking. Personal history was remarkable for diabetes mellitus type II (treated with a combination of rosiglitazone and metformin) and hypertension (treated with amlodipine). Family history was negative for neurological disease.

The only positive findings on neurological examination were a dysarthric speech consistent with lingual dystonia that improved with jaw clenching, considered by us to be a sensory trick. There were no involuntary movements of the neck or extremities. His gait, extraocular movements, visual fields, strength, sensory, cerebellar, and reflex testing were normal.

The patient did not receive botulinum toxin injections and was satisfied with the combination of trihexyphenidyl and the use of his sensory trick.

Although PFLD is a rare disorder, we accessed the National Library of Medicine (PubMed) and EMBASE databases with the subject headings "lingual dystonia" and identified three additional cases of PFLD.^{2–4} There were 2 men (including our case) and 2 women with an age range of 32 to 50 years. Dystonia developed over a period of a few weeks in all cases and was always speech-induced. Two types of dystonic contractions were reported: tongue protrusion in two cases and tongue retraction in the other two. One case of tongue protrusion also had lateral tongue displacement. Like our case, 2 of the 3 other cases experienced benefit from sensory tricks. Anticholinergic therapy was successful in all patients, with results ranging from mild to marked. In 2 cases with marked response to anticholinergic treatment, remission was maintained after the anticholinergic was discontinued. Blitzer and colleagues⁵ have argued against using botulinum toxin injections in patients with focal lingual dystonia because it can cause intolerable dysarthria, dysphagia, or spasmodic pain of the tongue. We did not use botulinum toxin in our case.

Secondary forms of focal lingual dystonia or tremor have been associated with trauma, especially with electrical injuries.⁶ PFLD should be differentiated from paroxysmal disorders of the tongue that are not task-specific and not associated with speaking.^{7,8} In the cases reported ($n = 3$), the spasms of the tongue were unilateral, tonic, lasted less than 1 minute, were not clearly associated with precipitants (such as speech), and an underlying etiology could not be determined. Other forms of focal facial dystonia induced by speaking have been described, but these were not limited to the tongue.

Spiridon Papapetropoulos, MD, PhD
 Carlos Singer, MD*

Division of Movement Disorders
 Miller School of Medicine, Department of Neurology
 University of Miami
 Miami, Florida, USA

*E-mail: csinger@med.miami.edu