

Brief Communication

“Erratic” complex partial status epilepticus as a presenting feature of MELAS

Davide Corda *, Giulio Rosati, Giovanni A. Deiana, GianPietro Sechi

Neurological Clinic, University of Sassari, Sassari, Italy

Received 14 November 2005; revised 15 December 2005; accepted 21 December 2005

Available online 10 February 2006

Abstract

Patients with the syndrome of mitochondrial encephalopathy, lactic acidosis, and strokelike episodes (MELAS) may rarely present with complex partial status epilepticus (CPSE) at clinical onset. We report on a 38-year-old woman with MELAS presenting with multifocal CPSE and periodic lateralized epileptiform discharges (PLEDs) on EEG during her first strokelike episode. CT scan documented a right temporo-parieto-occipital strokelike lesion. EEG showed prolonged seizure discharges with alternating focus over the temporo-occipital and frontotemporal regions of the right hemisphere; moreover, right frontotemporal PLEDs were evident when the seizure activity was localized in the temporo-occipital region. The electroclinical status and CT findings normalized gradually on carbamazepine therapy. The four other patients with MELAS described in the literature as presenting with CPSE showed unifocal epileptic discharges on EEG. We report for the first time a case in which multifocal CPSE is the presenting feature of MELAS. Our findings document the multifocality of neuronal hyperexcitability in the context of the cerebral strokelike lesion in this syndrome.

© 2006 Elsevier Inc. All rights reserved.

Keywords: Erratic status epilepticus; Complex partial status epilepticus; Mitochondrial, Encephalopathy, Lactic acidosis, and Strokelike episodes; MELAS

1. Introduction

Epilepsy is a common manifestation of the syndrome of mitochondrial encephalopathy, lactic acidosis, and stroke-like episodes (MELAS) and, in some cases, may be the presenting feature [1]. A wide variety of seizure types have been described; however, the occurrence of complex partial status epilepticus (CPSE) at the clinical onset of this mitochondrial encephalopathy has rarely been reported [1–3]. This is probably related to the ambiguity of clinical signs and symptoms of CPSE, which could easily lead to misinterpretation [1]. Moreover, a consensus has not been reached regarding the typical EEG correlates of CPSE. Indeed, classic uni- or multifocal seizure discharges and paroxysmal lateralized epileptiform discharges (PLEDs) have been described in association with CPSE [4,5].

We studied a case of late-onset MELAS presenting with “erratic” CPSE and PLEDs on EEG, on the occasion of the first brain CT-documented strokelike episode. Serial clinical, EEG, and CT findings of the patient were analyzed, and the other reported cases in which CPSE was the presenting feature of MELAS are reviewed.

2. Case history

A 38-year-old, right-handed woman presented to this neurological ward for episodic vomiting, confusion, behavioral disturbances, dysarthria, and auditory hallucinations lasting for about a week. Medical history was remarkable for headache, insulin-dependent diabetes mellitus, and paroxysmal tachycardia, which had been variously diagnosed in six family members (mother, four brothers, one sister). Neurological examination revealed dysarthria, left homonymous hemianopsia, external ophthalmoparesis, and left, last evident hemi-hypoesthesia. Attentional deficit,

* Corresponding author. Fax: +39079228423.

E-mail address: gpsechi@uniss.it (D. Corda).

irritability, and disorientation for time, place, and person were present.

Brain MRI revealed a hyperintense cortical–subcortical lesion in the right temporo-parieto-occipital region; moreover, basal ganglia calcifications and diffuse mild cortical atrophy were apparent. Ictal EEG disclosed the coexistence in the right hemisphere, on a mild slowing of background activity in the theta range, of frequent seizure discharges at about 12 Hz, lasting from 17 to 60 seconds, with a temporo-occipital focus, and broad bi- and polyphasic PLEDs at about 1–2 Hz, with a frontotemporal focus (Fig. 1A). Administration of diazepam 10 mg intravenously induced some blunting of epileptic discharges and PLEDs without definite clinical improvement. Then, she was given carbamazepine (CBZ) 100 mg three times daily per os. In the following days, “erratic” focal epileptic discharges shifting from the right frontotemporal to the temporo-occipital region were observed on EEG. In particular, EEG 4 days later showed frequent right frontotemporal seizure spike-wave discharges at about 2.5 Hz, whereas the right temporo-occipital ictal activity had disappeared (Fig. 1B1). At that time, clinical status was characterized mainly by attentional deficit and confusion. Intravenous diazepam (10 mg) first stopped the frontotemporal seizure discharges, then stopped the PLED-like discharges that had replaced the

seizure discharges for about 60 seconds (Fig. 1B2), with a definite improvement in clinical status for about 1 hour. CBZ was increased to 600 mg daily (serum levels between 7.3 and 8.2 $\mu\text{g/ml}$) (EMIT system).

On Day 17 after admission, the patient deteriorated, becoming increasingly drowsy and irritable. Brain CT revealed an increase in edema in the lesion involving the right temporal, parietal, and occipital lobes (Fig. 2A). EEG demonstrated persistence of seizure activity in the right temporo-occipital region; theta activity and intermittent PLEDs without a clear focus were also visible over the right hemisphere. That same day we introduced idebenone therapy (180 mg daily per os) after considering the possibility she had mitochondrial encephalomyopathy, because of the repeated findings of increased plasma lactate values (4.8–5.7 mmol/L) and the suggestive clinical and history features. The diagnosis was confirmed by the analysis of mitochondrial DNA from peripheral lymphocytes, which indicated the presence of the A3243G point mutation typically associated with MELAS in the patient and all affected relatives.

In the following days, clinical status began to improve gradually. The patient appeared more alert, oriented, and responsive. Neurological examination did not demonstrate the left homonymous hemianopsia, and the attentional

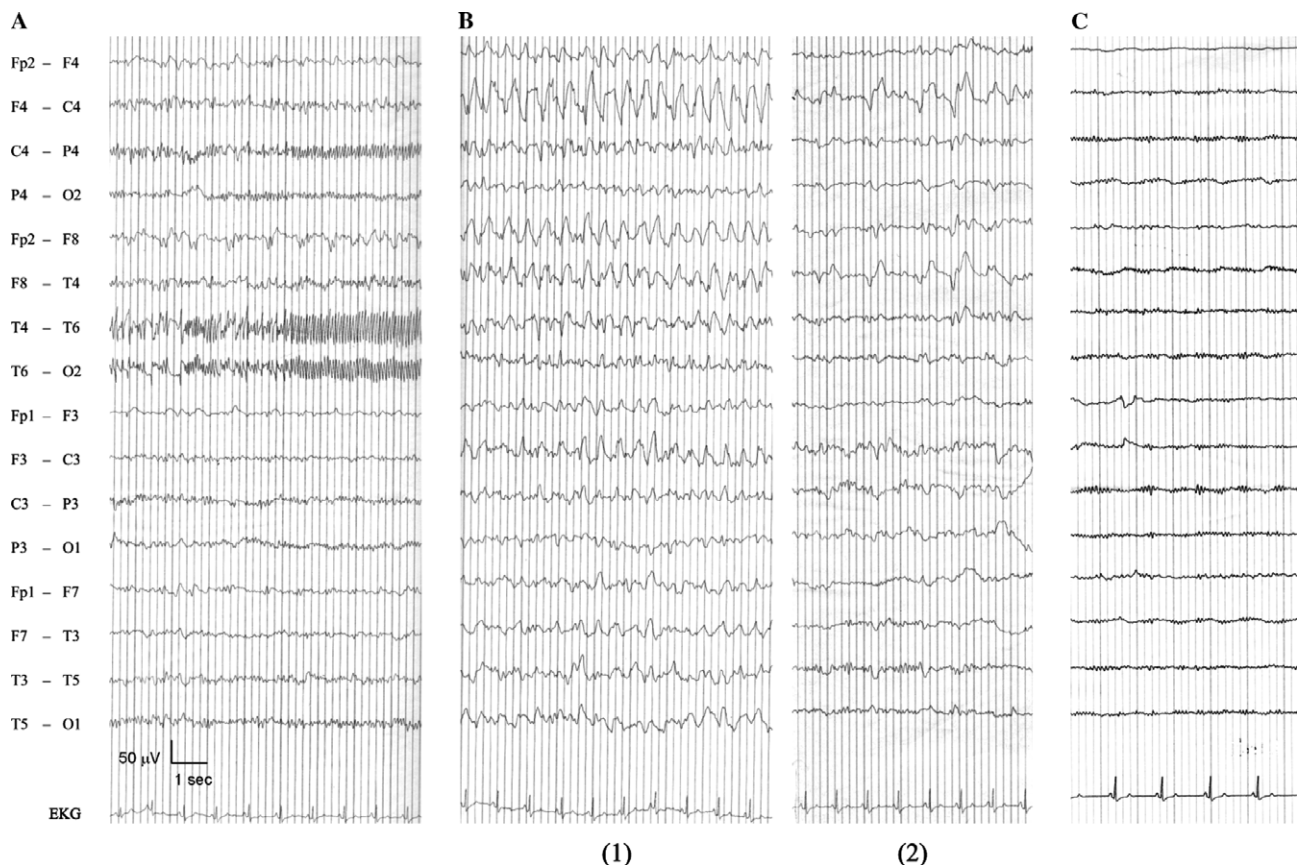


Fig. 1. Ictal EEG recordings showing “erratic” seizure discharges from the temporo-occipital region (A) to the frontotemporal region (B1) in the right hemisphere. Frontotemporal PLEDs are also evident in (A) (Fp2–F8, F8–T4). In (B2) are shown PLED-like discharges replacing the frontotemporal epileptic discharges during diazepam infusion. Two months later, EEG was normal (C).

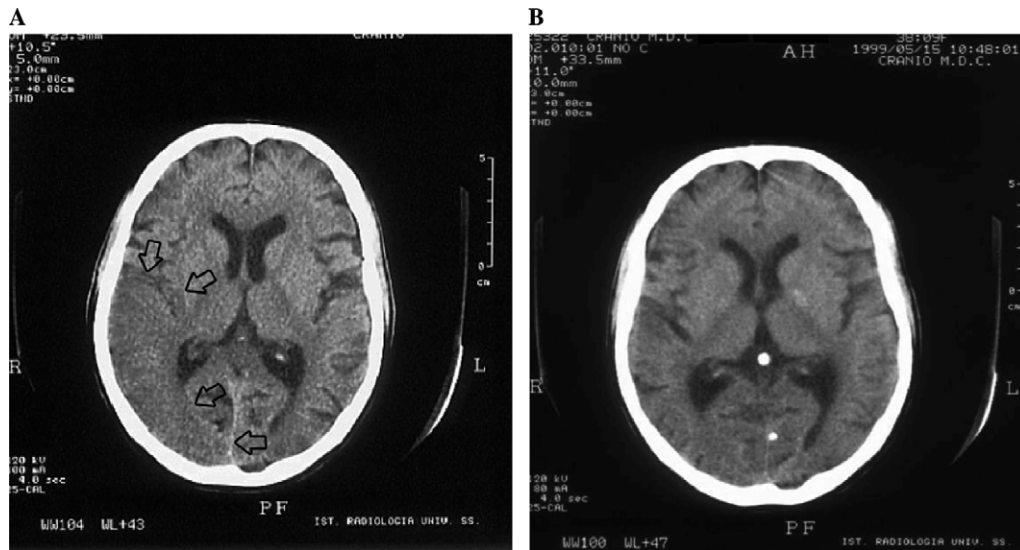


Fig. 2. (A) Brain CT scan showing a strokelike lesion involving the right temporal, parietal, and occipital lobes (arrows). (B) A brain CT scan 2 months later did not show the lesion.

deficit was markedly improved. EEG showed episodic PLEDs in the right temporoparietal region on a mild slowing of background activity. Brain CT a few days later showed a decrease in edema.

The patient was discharged on Day 33: aphasia, hemianopsia, and left hemi-hypoesthesia were remarkably improved and disappeared subsequently; external ophthalmoparesis persisted for about a month. EEG showed only a mild slowing of background activity over the right hemisphere without PLEDs or seizure discharges. Subsequent EEG recordings, about 2 months later, were normal (Fig. 1C).

Brain CT performed 2 months later (Fig. 2B) did not show the lesion previously seen on the right hemisphere.

3. Discussion

In the literature, we have been able to find only four other cases in which CPSE was the presenting feature of

MELAS and for which sufficient descriptions of the ictal clinical and EEG characteristics were available to permit a comparison with our case (Table 1) [1–3]. The altered level of consciousness with or without cognitive and behavioral changes and unaccompanied by frank stereotyped motor automatisms or reactive automatisms appears to be the clinical feature common to these cases. The real incidence of CPSE as a presenting feature in MELAS remains to be ascertained. The contemporary occurrence of focal seizure discharges and complex partial seizures in several cases of MELAS reported in the literature [6–8] suggests that CPSE may fairly frequently be a presenting feature of MELAS.

With respect to the EEG correlates of CPSE in MELAS, in the cases reported in the literature, only unifocal epileptic discharges were observed on EEG, whereas in our patient, multifocal “erratic” epileptic discharges were observed in the same cerebral hemisphere. “Erratic” status epilepticus has been reported classically in newborn infants

Table 1

Cases in which CPSE was reported as the presenting feature of MELAS: demographic and ictal clinical and EEG findings

Reference	Sex	Age	Ictal clinical pattern	Ictal EEG pattern
Leff et al., 1998 [1]	Male	52	Slurring of speech, twitching in the left arm, confusion, drowsiness	Right posterior temporal PLEDs evolving into seizure discharges of sharp waves and spikes
Araki et al., 2001 [2]	Male	37	Fluctuating consciousness disturbance, conjugated eye deviation to the left	Right parieto-temporo-occipital, high-amplitude, rhythmic sharp waves
Fedderson et al., 2003 [3]	Male	43	Aggressive confusional state	Right parietal sharp waves and rhythmic theta and delta waves alternating with periodic polymorphic complexes in a waxing and waning manner
	Female	57	Aggressive confusional state, headache, aphasia	Left occipital waxing and waning repetitive sharp waves and polymorphic complexes
Present case	Female	38	Vomiting, confusion, irritability, dysarthria, auditory hallucinations	“Erratic” right temporo-occipital spike discharges alternating with homolateral frontotemporal spike-wave discharges and frontotemporal PLEDs

with severe acute encephalopathy [9] and rarely in adults with postanoxic–ischemic encephalopathy [10]. The pathophysiology seems related to a peculiar combination of damage in the cerebral structures responsible for propagation and generalization of epileptic activity (e.g., commissural fibers, cortex, thalamus) [10,11]. In our patient, apparently, the seizure activity in the frontotemporal region inhibited analogous activity in the temporo-occipital region, whereas this latter activity coexisted with frontotemporal PLEDs. Several points led us to consider PLEDs as an ictal phenomenon [12], although there are no definitive data in favor of this hypothesis [13]. However, because PLEDs reflect persistent abnormally enhanced neuronal activities [13,14], in this patient the frontotemporal region seems more excitable compared with the temporo-occipital region, with an apparently different degree of activation of frontotemporal epileptic discharges, from a continuous spike–wave discharge at about 2.5 Hz (more activation) to PLEDs at 1–2 Hz (less activation). The gradual evolution from focal epileptic discharges to PLEDs has also been reported in previous studies [15]. In particular, in our patient the documented rapid evolution from continuous epileptic discharges to PLED-like discharges during diazepam infusion supports the possibility that PLEDs are caused by excessive γ -aminobutyric acid inhibition, which interrupts the epileptic discharges, making them discontinuous and periodic. Depth electrode studies in patients with partial complex seizures and multifocal epileptogenic zones have frequently demonstrated a leading zone capable of driving the discharge of the others with a great variety of interconnections [5]. In our patient, the complex relationship between the seizure foci on EEG recordings is unclear and may be related to the incomplete functioning of the interconnecting fibers between different cortical areas due to the impaired oxidative metabolism in neuronal cells typical of MELAS. Moreover, in our patient, the occurrence of at least two seizure foci documents the multifocality of neuronal hyperexcitability in the context of the cerebral stroke-like lesion in MELAS with possible different expression of the regional electrical pattern on EEG.

References

- [1] Leff PA, McNabb AW, Hanna MG, Clarke CRA, Lerner AJ. Complex partial status epilepticus in late onset MELAS. *Epilepsia* 1998;39:438–41.
- [2] Araki T, Suzuki J, Taniwaki Y, et al. A case of MELAS presenting as complex partial status epilepticus. *Rinsho Shinkeigaku* 2001;41:487–90.
- [3] Feddersen B, Bender A, Arnold S, Klopstock T, Noachtar S. Aggressive confusional state as a clinical manifestation of status epilepticus in MELAS. *Neurology* 2003;61:1149–50.
- [4] Kaplan PW. Nonconvulsive status epilepticus. *Neurology* 2003;61:1035–6.
- [5] Chauvel P, Dravet C. The HHE syndrome. In: Roger J, Bureau M, Dravet C, Genton P, Tassinari CA, Wolf P, editors. *Epileptic syndromes in infancy, childhood and adolescence*. London: John Libbey; 2002. p. 247–63.
- [6] Fujimoto S, Mizuno K, Shibata H, et al. Serial electroencephalographic findings in patients with MELAS. *Pediatr Neurol* 1999;20:43–8.
- [7] Torbergson T, Mathiesen E, Aalsly J. Epilepsy in a mitochondrial disorder. *J Neurol Neurosurg Psychiatry* 1991;54:1073–6.
- [8] Sharfstein SR, Forrest Gordon M, Libman RB, Malkin ES. Adult-onset MELAS presenting as herpes encephalitis. *Arch Neurol* 1999;56:241–3.
- [9] Vigeveno F, Gregory S. Status epilepticus in the pediatric age. *J Pediatr Neurosci* 1987;3:213–4.
- [10] Bortone E, Bettoni G, Giorgi C, Murgese A, Stocchetti M, Mancina D. Adult postanoxic “erratic” status epilepticus. *Epilepsia* 1992;33:1047–50.
- [11] Celesia GG, Grigg MM, Ross E. Generalized status myoclonicus in acute anoxic and toxic-metabolic encephalopathies. *Arch Neurol* 1988;45:781–4.
- [12] Franck G, Sadzot B, Salmon E, et al. Regional cerebral blood flow and oxygen uptake rate in human focal epilepsy and status epilepticus. In: Delgado-Escueta AV, Ward Jr AA, Woodbury DM, Porter RJ, editors. *Advances in neurology*, vol. 44: Basic mechanisms of the epilepsies: molecular and cellular approaches. New York: Raven Press; 1986. p. 935–48.
- [13] García-Morales I, García MT, Galán-Dávila L, et al. Periodic lateralized epileptiform discharges: etiology, clinical aspects, seizures, and evolution in 130 patients. *J Clin Neurophysiol* 2002;19:172–7.
- [14] Lee BI, Schauwecker DS. Regional cerebral perfusion in PLEDs: a case report. *Epilepsia* 1988;29:607–11.
- [15] Garzon E, Fernandes RMF, Sakamoto AC. Serial EEG during human status epilepticus. Evidence for PLEDs as an ictal pattern. *Neurology* 2001;57:1175–83.