



# Early neurologic complications of pulmonary arteriovenous malformation in a newborn: an indication for surgical resection

Alessandro Borsellino<sup>a,\*</sup>, Claudio Giorlandino<sup>b</sup>, Saverio Malena<sup>c</sup>, Alessandro Trucchi<sup>a</sup>, Roberta Cilio<sup>d</sup>, Piero Bagolan<sup>a</sup>

<sup>a</sup>Department of Medical and Surgical Neonatology, Bambino Gesù Children Hospital, 00165 Rome, Italy

<sup>b</sup>Department of Obstetrics and Gynaecology, Artemisia Medical Center, 00198 Rome, Italy

<sup>c</sup>Department of Radiology, Bambino Gesù Children Hospital, 00165 Rome, Italy

<sup>d</sup>Department of Neurology, Bambino Gesù Children Hospital, 00165 Rome, Italy

## Index words:

Pulmonary arteriovenous malformation;  
Prenatal diagnosis;  
Neurologic symptoms

**Abstract** A case report of a neonate with pulmonary arteriovenous malformation is described. The anomaly was prenatally diagnosed, and family history was positive for Rendu-Osler-Weber syndrome. Because neurologic symptoms developed during the second week of life, surgical resection was deemed the best curative option to avoid further embolic events and reoccurrence of the lesion. Previous reports detailing coil embolization therapy for pulmonary arteriovenous malformation are discussed.

© 2006 Elsevier Inc. All rights reserved.

Pulmonary arteriovenous malformations (PAVMs) are often silent until adulthood. In very few cases, symptoms develop in the newborn period. These include congestive heart failure, dyspnea, and hemorrhage, whereas neurologic symptoms have never been reported so early in life. The case of a newborn, with an antenatal diagnosis of PAVM, who presented at 2 days of life with seizures due to paradoxical embolism, is reported. Surgical resection of the lesion was preferred to embolotherapy to minimize the risk for further paradoxical embolisms.

## 1. Case report

A patient was referred to our facility with a 39-week gestational age fetus that had been documented to have both right lung and liver abnormalities on a screening obstetric ultrasound.

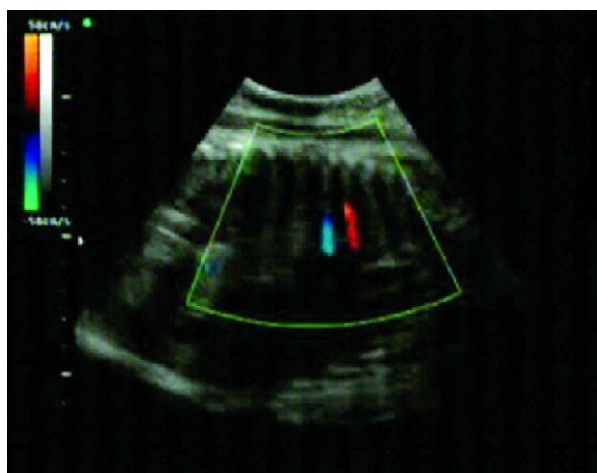
An ultrasound with color flow Doppler documented a PAVM in the right lung (Fig. 1) and a vascular lesion, presumably hemangioma, in the right lobe of the liver. Family history was positive for Rendu-Osler-Weber (ROW) syndrome in the father.

A 3.740-g male infant was then delivered by cesarean birth, with normal Apgar scores (8 at 1 minute and 10 at 5 minutes). Physical examination revealed a bruit over the right thorax, whereas neither hepatomegaly nor vascular lesions of the skin or mucous membranes were detected. Chest radiograph showed a right lower lobe opacity. Magnetic resonance imaging ruled out cerebral anomalies,

Presented at the 52nd Annual Congress of British Association of Paediatric Surgeons, Dublin, Ireland, July 12–15, 2005.

\* Corresponding author. Department of Medical and Surgical Neonatology, Bambino Gesù Children Hospital, Piazza S. Onofrio 4, 00165 Rome, Italy.

E-mail address: alessandroborsellino@virgilio.it (A. Borsellino).



**Fig. 1** Prenatal color Doppler ultrasound showing 2 voluminous abnormal vessels in the right lung.

whereas magnetic resonance angiography (MRA) documented a PAVM in the right lower lobe supplied by an artery arising from the right pulmonary artery (Fig. 2). Similarly, the abdominal lesion was consistent with a vascular anomaly involving the seventh and the eighth segments of the liver.

On the second day of life, the neonate experienced 2 episodes of seizures, which promptly subsided after phenobarbital administration. A few days later, an MRA of the brain documented multiple small lesions consistent with embolic events, which were most likely due to paradoxical emboli from the PAVM.

To minimize the risk for further paradoxical emboli, a formal lobectomy was deemed preferable to transcatheter coil embolization of the PAVM. A right thoracotomy was performed, and the right lower lobe was resected. Histologic examination showed a PAVM involving central portion of the lobe with atelectasis of adjacent parenchyma.

Postoperative course was uneventful. Three months later, a magnetic resonance imaging showed total regression of the hepatic and cerebral lesions.

At 1 year of follow-up, the child is thriving well without neurologic sequelae, and anticonvulsant therapy was discontinued 6 months after the operation.

## 2. Discussion

Pulmonary arteriovenous malformations rarely become symptomatic at birth. To date, 10 cases of affected newborns have been reported by Allen et al [1] and a series of 17 cases by Ravasse et al [2]. Other authors [3,4] reported single cases of neonatal PAVM treated by coil embolization as Grady et al [5] first did in 1994.

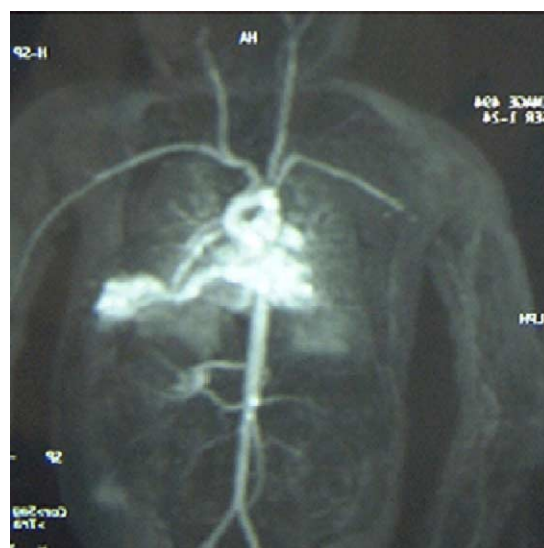
The most common sign for symptomatic babies is central cyanosis due to a hemodynamically significant right-to-left shunt. Congestive heart failure, dyspnea, and hemorrhage

can also occur, whereas neurologic symptoms, caused by paradoxical embolism through the PAVM, have been reported only among older patients [1].

In our case, the unique presenting sign was seizures, which occurred during the second week of life. This occurred while the diagnostic workup was in progress because of the antenatal diagnosis of PAVM and positive family history for ROW syndrome, a disorder that is inherited as an autosomal dominant trait. Such early neurologic symptoms lead us to believe that the risk for paradoxical embolism could be increased by embolotherapy because brain embolism has been previously reported after this procedure in a pediatric patient with ROW syndrome [6].

Lee and colleagues [7] in 1997 reported an extended follow-up of adult patients treated for large PAVM by transcatheter embolization. Of the 45 patients treated, 84% achieved long-term resolution of the PAVM (mean follow-up, 4.7 years), but among these patients in whom recanalization of an originally occluded feeding artery or interval growth of an accessory vessel had occurred, 2 patients (4.4%), affected with ROW syndrome, experienced a stroke in the interval between their initial and their second embolization. For this type of patient, labeled as “high risk,” Lee et al [7] recommend diligent follow-up consisting of chest x-ray and arterial blood gas measurement at 1 month and 1 year after occlusion and spiral computed tomography every 3 to 5 years thereafter to monitor possible growth of small PAVMs. We question if such follow-up would be advisable throughout life, from the neonatal age to adulthood.

Moreover, the radiation dose received by a small baby during the embolization remains a matter of concern. Bennhagen et al [3] reported a 5% increased risk for developing fatal cancer in an infant who underwent 5 transcatheter coil embolization procedures for a huge PAVM involving all segments of the right lung. In this case,



**Fig. 2** Visualization at MRA of PAVM in the right lung supplied by abnormally enlarged vessel arising from the right pulmonary artery.

pneumonectomy was precluded by concomitant left pulmonary hypoplasia. They also advocate surgical resection if the PAVM involves a single pulmonary lobe, with clear delineation from unaffected lobes, because afferent vessels can redilate or new vessels can be recruited, thus accounting for reoccurrence of the vascular malformation.

This must be considered when reviewing the 2 neonatal cases reported by Grady et al [5] and Koppen et al [4], with a follow-up of only 6 and 9 months, respectively. Eventually, none of the reported neonates treated by embolization had previously experienced neurologic symptoms.

To the best of our knowledge, this marks the first report of a solitary, antenatally diagnosed PAVM, presenting with early neurologic symptoms. We suggest that the lack of long-term follow-up in the pediatric population and radiation dose concerns should advise against any attempt of transcatheter coil embolization of PAVM confined to a single pulmonary lobe in small babies affected with ROW syndrome, especially if neurologic symptoms have already developed.

## References

- [1] Allen SW, Whitfield JM, Clarke DR, et al. Pulmonary arteriovenous malformation in the newborn: a familial case. *Pediatr Cardiol* 1993;14: 58-61.
- [2] Ravasse P, Maragnes P, Petit T, et al. Total pneumonectomy as a salvage procedure for pulmonary arteriovenous malformation in a newborn: report of one case. *J Pediatr Surg* 2003;38:254-5.
- [3] Bennhagen RG, Holje G, Laurin S, et al. Coil embolization of a neonatal pulmonary arteriovenous malformation. *Pediatr Cardiol* 2002;23: 235-8.
- [4] Koppen S, Korver CRW, Dalinghaus M, et al. Neonatal pulmonary arteriovenous malformation in hereditary haemorrhagic telangiectasia. *Arch Dis Child Fetal Neonatal Ed* 2002;87:F226-7.
- [5] Grady RM, Sharkey AM, Bridges ND. Transcatheter coil embolisation of a pulmonary arteriovenous malformation in a neonate. *Br Heart J* 1994;71:370-1.
- [6] Mager HJ, Overtoom TT, Mauser HW, et al. Early cerebral infarction after embolotherapy of a pulmonary arteriovenous malformation. *J Vasc Interv Radiol* 2001;12(1):122-3.
- [7] Lee DW, White RI, Egglin TK, et al. Embolotherapy of large pulmonary arteriovenous malformations: long-term results. *Ann Thorac Surg* 1997;64:930-40.