

# Respiratory chain deficiency in a female with Aicardi-Goutières syndrome

Christine Barnérias MD;  
 Irina Giurgea MD, Department of Paediatrics;  
 Lucie Hertz-Pannier MD PhD, Paediatric Radiology Service;  
 Nadia Bahi-Buisson MD PhD, Department of Paediatrics;  
 Nathalie Boddaert MD PhD, Paediatric Radiology Service;  
 Pierre Rustin PhD;  
 Agnès Rotig PhD, INSERM U-393;  
 Isabelle Desguerre MD, Department of Paediatrics;  
 Arnold Munnich MD PhD, Department of Genetics and  
 INSERM U-393;  
 Pascale de Lonlay\* MD PhD, Department of Paediatrics,  
 Hôpital Necker-Enfants Malades, Paris, France.

\*Correspondence to last author at Service de Maladies Métaboliques, Hôpital Necker-Enfants Malades, 149, rue de Sèvres 75743 Paris Cedex 15, France. E-mail: pascale.delonlay@nck.aphp.fr

Aicardi-Goutières syndrome (AGS) is an early-onset progressive encephalopathy characterized by calcifications of the basal ganglia, white matter abnormalities, chronic cerebrospinal fluid (CSF) lymphocytosis, and/or a raised level of CSF interferon (INF)- $\alpha$ . We report a female with mitochondrial respiratory chain deficiency fulfilling the criteria of AGS. Disease onset was in the first year of age with seizures and psychomotor regression. To date, at 4 years of age, she presents a severe encephalopathy, increased INF- $\alpha$  in the CSF, and calcifications of basal ganglia on computerized tomography. Cerebral magnetic resonance imaging showed bilateral and symmetric hypersignal of the posterior white matter. A complex I deficiency of the mitochondrial respiratory chain was found in skeletal muscle, which was associated with a complex IV deficiency in cultured skin fibroblasts. The question of whether this oxidative phosphorylation deficiency is primary or secondary in AGS is open to debate. We suggest giving consideration to systematic evaluation of the mitochondrial respiratory chain in skeletal muscle and skin fibroblasts of other AGS patients.

Aicardi-Goutières syndrome (AGS) is a genetically heterogeneous condition of hitherto unknown mechanism characterized by an early onset, progressive encephalopathy with calcifications of basal ganglia, white matter abnormalities, cerebrospinal fluid (CSF) lymphocytosis, and/or raised level of CSF interferon (INF)- $\alpha$  (Tolmie et al. 1995, McEntagart et al. 1998). Here, we report on mitochondrial respiratory chain deficiency in a child fulfilling the criteria of AGS. Whether respiratory chain deficiency is primary or secondary to cytokine abnormalities currently observed in AGS is still questionable. Whatever the mechanism, it is of particular interest to assess mitochondrial phosphorylation in other AGS patients.

## Case report

A female born to non-consanguineous parents after a term pregnancy and normal delivery (birthweight: 3250g, length: 51cm, head circumference: 34cm) developed peripheral hypertonia and axial hypotonia in the first year of life. Generalized seizures uncontrolled by valproate first occurred at the age of 16 months, followed by psychomotor regression and failure to thrive (weight  $-2$  SD, length  $-0.5$  SD, head circumference  $-1.5$  SD). Poor head control, poor eye contact, and brisk tendon reflexes were noted at 20 months of age. Social responsiveness was present but poor. Mild liver enlargement with elevated serum transaminases was observed ( $4 \times$  Normal). CSF proteins and white cell count were normal (0.15g/l, 3 cells respectively). CSF lactate (2.3mmol/l, normal below 2; CSF lactate/pyruvate ratio 24)

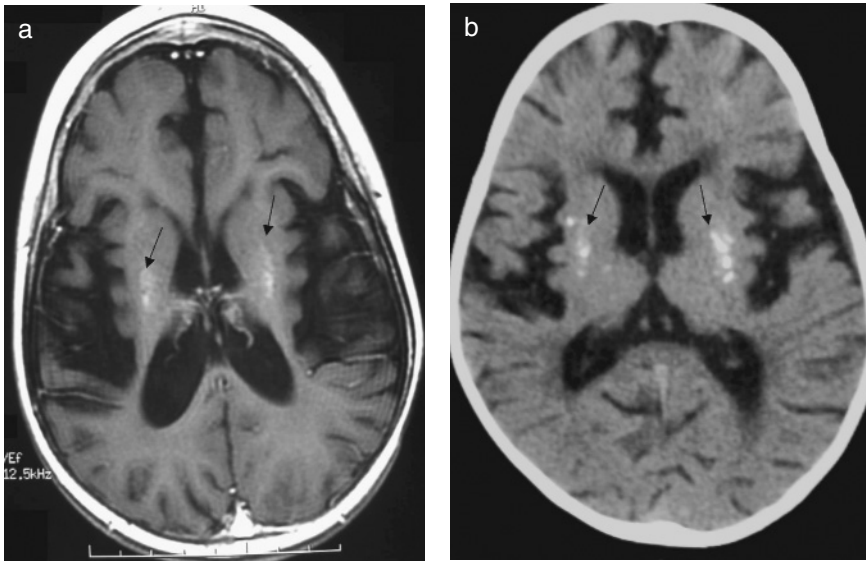
See end of paper for list of abbreviations.

and CSF INF- $\alpha$  were increased (6UI/l, normal range below 2). Plasma amino acids and urinary organic acids were normal. Electroretinogram, visual evoked potentials, and heart ultrasound were also normal. An elder brother presented with learning disability\*, cerebellar ataxia, and muscular weakness at the age of 10 years. Plasma levels of lactate and amino acids and urinary organic acids were normal.

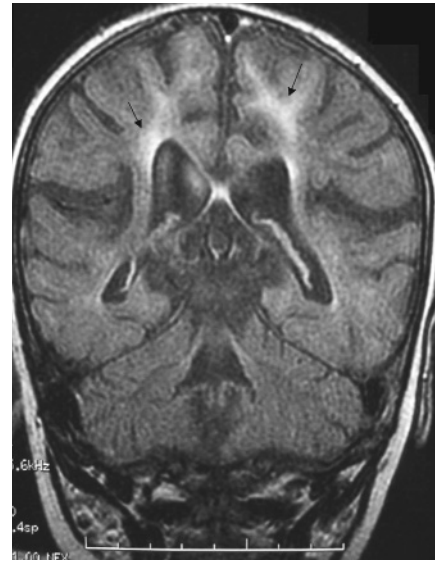#### Method

Lactate, pyruvate, and ketone bodies were determined by the enzymatic method and urinary organic acids by gas chromatograph. Deltoid muscle (120mg) was obtained under local anaesthetic and mitochondria were prepared according to standard procedures. NADH ubiquinone reductase

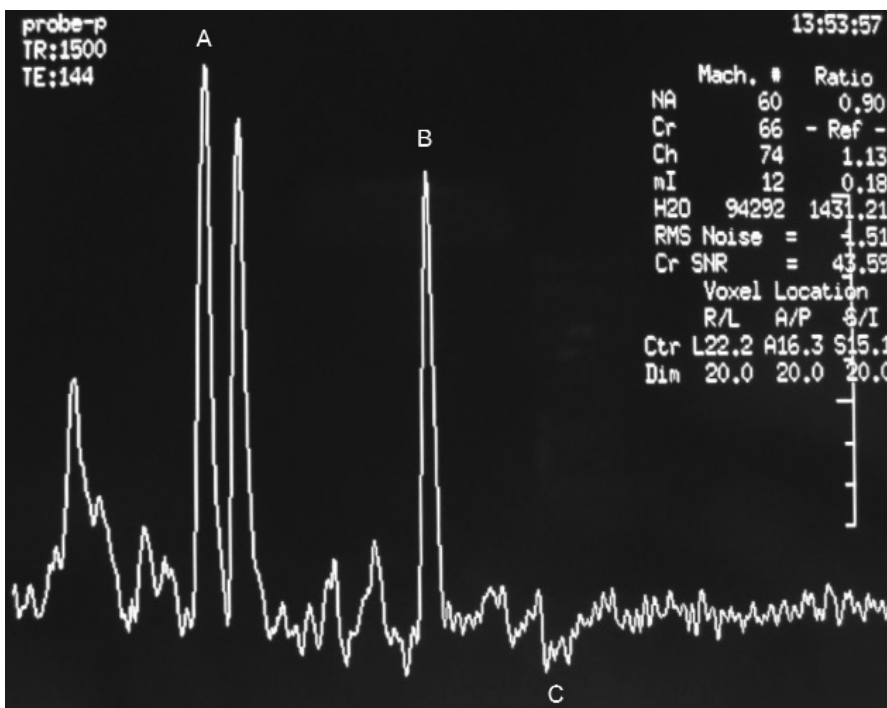
\*US usage: mental retardation.



**Figure 1:** Calcifications in basal ganglia (arrows), and cortico-subcortical atrophy. (a) Axial magnetic resonance imaging, T<sub>1</sub>-weighted. (b) Computerized tomography.



**Figure 2:** Bilateral hypersignals of the white matter (arrows), particularly in posterior regions (Coronal magnetic resonance imaging, FLAIR).



**Figure 3:** MR spectroscopy (Monovoxel, point-resolved spectroscopy sequence, echo times = 144ms) of basal ganglia shows (a) slight decrease of N-acetyl aspartate, (b) slight increase of choline, and (c) a small peak of lactate.

(NQR), fumarase, citrate synthase, lactate dehydrogenase, cytochrome c oxidase (COX), and succinate cytochrome reductase (SCCR) activities were spectrophotometrically measured according to Rustin et al. (1994). Polarographic studies were performed as described previously (Rustin et al. 1994). For histochemistry, the muscle specimen was immediately frozen in liquid nitrogen-cooled isopentane and cross-sectional sections (10 $\mu$ ) were stained with hematoxylin-eosin, modified Gomori trichrome, and different histochemical stains. Histochemical staining for COX was performed using a modified method. Skin fibroblasts were grown in the medium RPMI 1640 (Gibco) supplemented with 10% foetal calf serum, 2mM glutamine, 2.5mM pyruvate, 200 $\mu$ M uridine, 100 $\mu$ g streptomycin, and 100U/ml penicillin at 37°C under standard conditions (Rustin et al. 1994). The screening for mtDNA deletions and mutations was carried out as described (Rustin et al. 1994).

## Results

CT and T<sub>1</sub>-weighted magnetic resonance (MR) images of the female at 2 years old showed calcifications of the basal ganglia, ventricular dilatation, and cortical atrophy (Fig. 1). FLAIR MRI showed bilateral and symmetric hyperintensities of the posterior white matter (Fig. 2). MR spectroscopy showed a small lactate peak in the basal ganglia (Fig. 3). The MRI of the elder brother showed bilateral hypersignals of the white matter and cerebellar hypoplasia.

Polarographic studies showed a low pyruvate oxidation in skeletal muscle mitochondria-enriched fractions of the female compared with controls (Table I). All activity ratios involving complex I (e.g. pyruvate oxidation, NADH cytochrome c reductase [NCCR] activity) were significantly abnormal and consistent with a 50–60% deficiency of complex I in her skeletal muscle. Accordingly, spectrometric studies showed a 50% decrease of complex I activity in her skeletal muscle biopsy (Table I). A similar complex I deficiency was identified in cultured skin fibroblasts, which was moreover associated with a decreased activity of complex IV (Table I). Histochemical analysis of the skeletal muscle showed partial atrophy of type II fibres and mild lipid vacuoles. COX histochemical staining revealed a heterogeneously weak COX activity in a few muscle fibres. A complex IV deficiency was identified in cultured skin fibroblasts of the elder brother.

Neither large-scale rearrangement nor common mtDNA mutations (A3243G, T10158C, T10191C, T12706C, G13513A, A13514G, T14487C) were found in skeletal muscle.

## Discussion

Here, we report on respiratory chain enzyme deficiency in a patient fulfilling the criteria of AGS. The patient presented with severe encephalopathy, liver enlargement, and elevated serum transaminases. White cell count was normal but INF- $\alpha$  was increased in the CSF. Calcifications of the basal ganglia were noted on the CT and cerebral MRI showed bilateral and symmetric hypersignal of the posterior white matter abnormality.

Because clinical presentation of AGS was consistent with the sequelae of a congenital infection, INF- $\alpha$  was first assessed and increased CSF INF- $\alpha$  levels in the absence of infection was consistent with AGS (Kuijpers 2002, Lebon et al. 2002). This condition is genetically heterogeneous with one locus (AGS1) on chromosome 3p21 (Crow 2002, Crow et al. 2000). Two other conditions are clinically related to

AGS, namely Cree encephalitis and the pseudo-TORCH syndrome. Cree encephalitis differs from AGS by the presence of systemic immune abnormalities with an apparent susceptibility to infections while pseudo-TORCH syndrome differs from AGS by an early-onset microcephaly with neonatal liver dysfunction, thrombocytopenia, and a normal white cell count in the CSF (Crow et al. 2003). Yet, it is important to remember that these features have been observed in several patients diagnosed as AGS. For this reason, neither CSF pleiocytosis nor elevated CSF INF- $\alpha$  levels are regarded as mandatory for diagnosis of AGS, particularly in late childhood. Our Azevedo-Martins (2003) patient fulfilled inclusion criteria of AGS with liver disturbances.

The question of whether respiratory chain deficiency was primary or secondary in our patient is open to debate. On the other hand, mitochondrially-derived reactive oxygen species are known to play a critical role in the activation of the cytokine-sensitive transcription factor NF-KappaB. This could denote a primary role for the oxidative phosphorylation defect. Moreover, liver dysfunction as well as leukodystrophy found in our patient are common findings in respiratory

**Table I: Spectrophotometric analysis of mitochondrial respiratory chain activities**

	<i>Patient value</i>	<i>Control values (n=80) range; mean (SD)</i>
<b>Muscle mitochondria</b>		
Activities (nmol/min/mg protein)		
Pyruvate oxidase	<b>8</b>	19–51
Succinate oxidase	40	31–93
Duroquinol oxidase	51	51–145
NADH ubiquinol reductase	<b>15</b>	39–100
SCCR1	19	112–367
QCCR	682	500–1539
COX	366	372–1240
Activity ratios		
Succ ox/pyr ox	<b>5.3</b>	1.9 (0.7)
DQ ox/succ ox	1.3	1.7 (0.2)
COX/NQR	<b>41</b>	10.8 (2.0)
COX/SCCR	2.7	3.2 (0.3)
COX/QCCR	0.47	0.50 (0.08)
<b>Cultured fibroblasts</b>		
Activities (nmol/min/mg protein)		
Pyruvate oxidase	7	7–11
Succinate oxidase	12	10–21
NADH ubiquinol reductase	<b>15</b>	16–35
SCCR	33	29–57
QCCR	84	64–107
COX	<b>138</b>	191–344
Activity ratios		
DQ ox/succ ox	1.3	1.7 (0.2)
COX/NQR	9.5	10.4 (1.2)
COX/SCCR	<b>4.1</b>	6.3 (0.7)
COX/QCCR	<b>0.3</b>	0.6 (0.03)

Substrate oxidation was measured polarographically. SCCR, succinate cytochrome c reductase (complex II and III); QCCR, ubiquinol cytochrome c reductase (complex III); COX, cytochrome c oxidase (complex IV); Succ, succinate; ox, oxidase; pyr, pyruvate; DQ, duroquinol; NQR, NADH ubiquinone reductase (complex I). Abnormal values are indicated in **bold** characters.

chain deficiencies (Schuelke et al. 1999, de Lonlay-Debeney et al. 2000). Conversely, respiratory chain deficiency could be regarded as a secondary event in AGS, as cytokines are known to down-regulate mitochondrial gene expression with a reduction in cellular ATP levels (Lou et al. 1994, Lewis et al. 1996) and to mediate organ inflammation leading to mitochondrial dysfunction (Kaneda et al. 2003). Moreover, IFN- $\alpha$  has been shown to depress mitochondrial respiration in vitro, by depleting mitochondrial transcription factor A (Inagaki et al. 1997). However, none of the genes involved in cytokine pathways has been identified at the 3p23 locus.

Whatever the mechanisms of the oxidative phosphorylation defect, this observation should prompt the investigation of oxidative phosphorylation in AGS and conversely the assessment of CSF IFN- $\alpha$  in respiratory chain deficiency. We suggest, therefore, that genetic disorders of the mitochondrial respiratory chain should be regarded as a possible cause or consequence of AGS.

DOI: 10.1017/S001216220600048X

Accepted for publication 12th May 2005.

#### References

- Azevedo-Martins AK, Lortz S, Lenzen S, Curi R, Eizirik DL, Tiedge M. (2003) Improvement of the mitochondrial antioxidant defense status prevents cytokine-induced nuclear factor-kappaB activation in insulin-producing cells. *Diabetes* **52**: 93–101.
- Crow Y. (2002) The genetics of Aicardi-Goutieres syndrome. *Eur J Paediatr Neurol* **6** (Suppl A): A33–35; discussion A37–39, A77–86.
- Crow YJ, Black DN, Ali M, Bond J, Jackson AP, Lefson M, Michaud J, Roberts E, Stephenson JB, Woods CG, Lebon P. (2003) Cree encephalitis is allelic with Aicardi-Goutieres syndrome: implications for the pathogenesis of disorders of interferon alpha metabolism. *J Med Genet* **40**: 183–187.
- Crow YJ, Jackson AP, Roberts E, van Beusekom E, Barth P, Corry P, Ferrie CD, Hamel BC, Jayatunga R, Karbani G, Kalmanchev R, Kelemen A, King M, Kumar R, Livingstone J, Massey R, McWilliam R, Meager A, Rittey C, Stephenson JB, Tolmie JL, Verrips A, Voit T, van Bokhoven H, Brunner HG, Woods CG. (2000) Aicardi-Goutieres syndrome displays genetic heterogeneity with one locus (AGS1) on chromosome 3p21. *Am J Hum Genet* **67**: 213–221.
- de Lonlay-Debeney P, von Kleist-Retzow JC, Hertz-Pannier L, Peudenié S, Cormier-Daire V, Berquin P, Chretien D, Rotig A, Saudubray JM, Baraton J, Brunelle F, Rustin P, Van Der Knaap M,

- Munnich A. (2000) Cerebral white matter disease in children may be caused by mitochondrial respiratory chain deficiency. *J Pediatr* **136**: 209–214.
- Inagaki H, Matsushima Y, Ohshima M, Kitagawa Y. (1997) Interferons suppress mitochondrial gene transcription by depleting mitochondrial transcription factor A (mtTFA). *J Interferon Cytokine Res* **17**: 263–269.
- Kaneda M, Kashiwamura S, Ueda H, Sawada K, Sugihara A, Terada N, Kimura-Shimmyo A, Fukuda Y, Shimoyama T, Okamura H. (2003) Inflammatory liver steatosis caused by IL-12 and IL-18. *J Interferon Cytokine Res* **23**: 155–162.
- Kuijpers TW. (2002) Aicardi-Goutieres syndrome: immunophenotyping in relation to interferon-alpha. *Eur J Paediatr Neurol* **6** (Suppl. A): A59–64; discussion A65–66, A77–86.
- Lebon P, Meritet JF, Krivine A, Rozenberg F. (2002) Interferon and Aicardi-Goutieres syndrome. *Eur J Paediatr Neurol* **6** (Suppl. A): A47–53; discussion A55–58, A77–86.
- Lewis JA, Huq A, Najarro P. (1996) Inhibition of mitochondrial function by interferon. *J Biol Chem* **271**: 13184–13190.
- Lou J, Anderson SL, Xing L, Rubin BY. (1994) Suppression of mitochondrial mRNA levels and mitochondrial function in cells responding to the anticellular action of interferon. *J Interferon Res* **14**: 33–40.
- McEntagart M, Kamel H, Lebon P, King MD. (1998) Aicardi-Goutieres syndrome: an expanding phenotype. *Neuropediatrics* **29**: 163–167.
- Rustin P, Chretien D, Bourgeron T, Gerard B, Rotig A, Saudubray JM, Munnich A. (1994) Biochemical and molecular investigations in respiratory chain deficiencies. *Clin Chim Acta* **228**: 35–51.
- Schuelke M, Smeitink J, Mariman E, Loeffen J, Plecko B, Trijbels F, Stockler-Ipsiroglu S, van den Heuvel L. (1999) Mutant NDUFB1 subunit of mitochondrial complex I causes leukodystrophy and myoclonic epilepsy. *Nat Genet* **21**: 260–261.
- Tolmie JL, Shillito P, Hughes-Benzie R, Stephenson JB. (1995) The Aicardi-Goutieres syndrome (familial, early onset encephalopathy with calcifications of the basal ganglia and chronic cerebrospinal fluid lymphocytosis). *J Med Genet* **32**: 881–884.

#### List of abbreviations

AGS	Aicardi-Goutières syndrome
ATP	Adenosine triphosphate
COX	Cytochrome c oxidase
CSF	Cerebrospinal fluid
GC	Gas chromatography
INF- $\alpha$	Interferon alpha
SCCR	Succinate cytochrome reductase

## Erratum

### 'Balancing certainty and uncertainty in clinical medicine'

Hayward

DMCN Vol **48**: 74–77

We would like to correct an error that was printed in the above mentioned article:

p 77: The sentence should have read: 'This article is based on Professor Hayward's inaugural lecture as Professor of Paediatric Neurosurgery, delivered at the Institute of Child Health...' and not 'This article is based on Professor Hayward's inaugural lecture as President of the Royal College of Paediatrics and Child Health at the Institute of Child Health...'

We sincerely apologize for this error.

DOI: 10.1017/S001216220600051X