

Case report

Classical pituitary tumour apoplexy: Clinical features, management and outcomes in a series of 24 patients

Annie S. Dubuisson^{a,*}, Albert Beckers^b, Achille Stevenaert^a

^a Department of Neurosurgery, University Hospital of Liège, Liège, Belgium

^b Department of Endocrinology, University Hospital of Liège, Liège, Belgium

Received 7 October 2005; received in revised form 13 January 2006; accepted 16 January 2006

Abstract

We retrospectively analysed the incidence, clinical presentation, endocrinological and radiological findings, medical and surgical management of pituitary apoplexy in our department (single-centre study), having a large experience in pituitary surgery.

Among 1540 pituitary lesions, 24 patients presented with pituitary apoplexy. Their charts were retrospectively reviewed. The symptoms included headache (92%), nausea and vomiting (54%), visual deficit (50%), oculomotor paresis (54%) and/or an altered mental state (42%). Skull X-rays ($n = 14$) demonstrated an enlarged sella turcica in all cases; CT-scan and/or MRI always revealed a sellar and suprasellar expanding lesion. Panhypopituitarism was present on admission in 70% of the patients. Urgent therapeutic management included high-dose cortisone treatment in all but one patients and CSF drainage in three. Three patients were treated conservatively. Nine patients were operated on rapidly, within hours or a few days because of severe visual deficit and/or altered level of consciousness. Nineteen patients were operated by the trans-sphenoidal approach; one of them required a second operation by craniotomy. There were two deaths related to the illness and one to an ill-defined reason at 4 months. Among the other patients 95% made a good recovery. All but two patients required a substitutive treatment with adrenal (83%), thyroid (68%), gonadal (42%) and/or growth (16%) hormones. The preoperative visual deficits recovered in all but one patients (92%) whereas the oculomotor pareses improved in all but two patients (85%).

In conclusion, pituitary tumour apoplexy is a rare event, complicating in our series 1.6% of 1540 pituitary adenomas. Even in severe cases, complete recovery is possible if the diagnosis is rapidly obtained and adequate management is initiated in time. Surgical results after trans-sphenoidal approach are in the majority of cases very satisfactory.

© 2006 Elsevier B.V. All rights reserved.

Keywords: Pituitary adenoma; Pituitary apoplexy; Pituitary diseases; Sella turcica; Trans-sphenoidal approach; Cabergolin

1. Introduction

Pituitary apoplexy (PA) is one of the most serious, life-threatening complications of pituitary adenoma. The term PA should be reserved for those cases with the abrupt onset of typical symptoms and signs including headache, nausea and vomiting, visual disturbances, oculomotor paresis, drowsiness, confusion and/or coma. From 1968 to 2004, 1540 patients were seen in our department for a pituitary lesion.

Among these patients, 24 presented with fulminating symptoms from ischemic or hemorrhagic infarction of the pituitary mass. We present the detailed clinical picture of these 24 patients and discuss their management.

2. Materials and methods

2.1. Patient population

From 1968 to 2004, 24 cases of PA were retrospectively reviewed among 1540 pituitary lesions seen by the senior author (AS). Data collected included the age and sex of the patient, past medical history, clinical presentation,

* Corresponding author at: Department of Neurosurgery, Centre Hospitalier Universitaire (B35), Domaine Universitaire du Sart Tilman, 4000 Liège, Belgium. Tel.: +32 4 3667208; fax: +32 4 3667737

E-mail address: A.Dubuisson@chu.ulg.ac.be (A.S. Dubuisson).

preoperative neurological, endocrinological and ophthalmological status, and postoperative outcome.

2.2. Endocrine evaluation

Standard blood evaluations were performed in emergency in all patients (ionogram, glycemia, blood cell count, etc.). Moreover, anterior pituitary functions were assessed in 20 patients. The following hormonal dosages were obtained: serum prolactin (PRL), growth hormone (GH), insulin-like growth factor (IGF1), thyroid stimulating hormone (TSH), adrenocorticotrophic hormone (ACTH), luteinizing hormone (LH), follicle stimulating hormone (FSH), free thyroxine (T4), free triiodothyronine (T3), serum cortisol and urinary free cortisol. Dynamic endocrine testing was done in eight cases using injection of thyroid releasing hormone (TRH), luteinizing hormone-releasing hormone (LHRH) and insulin tolerance test.

2.3. Radiological studies

Neuroradiological studies included skull X-rays in the antero-posterior and lateral planes in 14 patients. Computerized tomography (CT) was performed in 16 patients. Twelve patients were studied by MRI. Angiograms were done in seven patients and pneumoencephalograms in five before the era of CT-scan.

2.4. Surgical procedure

Twenty-one patients were submitted to surgery, using the trans-sphenoidal ($n=19$) and/or cranial ($n=3$) approaches. The operative findings were collected from the operative note, as well as the surgical therapeutic procedure.

2.5. Postoperative follow-up

Relief of preoperative symptoms and occurrence of postoperative complications were noted from the charts. All patients underwent a postoperative ophthalmological examination. A repeated endocrinological work-up was done at 7–10 days postoperatively. The yearly follow-up in the pituitary diseases clinics was noted in the charts of 20 patients.

3. Results

3.1. Clinical presentation

There were 16 males and eight females, ranging in age from 23 to 87 years (mean: 56). There were 25 episodes of PA, including two episodes in a single patient. Six patients had a known pituitary adenoma; two of them had been operated on by a trans-sphenoidal ($n=1$) or cranial ($n=1$) operation, respectively, 5 and 15 years before the apoplectic episode, which thus developed in a recurrent adenoma. Another patient

had undergone bilateral adrenalectomy for Cushing's disease 5 years previous to PA and developed a Nelson syndrome. PA occurred in three patients with a prolactinoma a few weeks after a treatment by cabergolin was started. Other predisposing factors included arterial hypertension ($n=4$), Von Willebrand disease ($n=1$) and anticoagulant or antiaggregant therapy ($n=3$).

The clinical data are summarized in Table 1. The most common symptoms were headache ($n=22$), nausea and vomiting ($n=13$), visual disturbances ($n=12$, including two patients with bilateral blindness), oculomotor pareses ($n=13$) and/or decreased level of consciousness ($n=10$, including three comatous patients). A meningeal syndrome was noted in four patients. A lumbar puncture done in two of these and in three other patients revealed signs of subarachnoid haemorrhage (presence of 45–1170 red blood cells).

3.2. Endocrine evaluation

Fourteen of the 20 studied patients were found to have panhypopituitarism; three patients had a partial pituitary insufficiency (gonadotroph, 1; gonadotroph + thyreotroph, 1; thyreotroph + corticotroph, 1) and three other patients had no insufficiency. None had diabetes insipidus. Two patients had mild hyponatremia.

3.3. Radiological studies

On skull X-rays, the sella was enlarged in all ($n=14$) patients with erosion of the sellar floor and dorsum sellae in two cases. CT-scan was performed at day 1 in five cases, at days 2–4 in five cases, at days 6–7 in two cases, between weeks 2 and 4 in three cases and beyond 1 month in the last two cases. It visualized a sellar lesion in all 16 studied cases and a suprasellar extension in 14 cases, which appeared predominantly hyperdense in 13 cases, isodense in two cases examined at days 6 and 12 and hypodense in one case examined on day 20. MRI performed at day 1 (two cases), between days 3 and 7 (five cases), between days 13 and 25 (three cases) and at month 3 (one case) showed an intra- and suprasellar expanding mass in all studied cases (Figs. 1 and 2). The largest diameter of the lesions ranged between 15 and

Table 1
Clinical presentation of 24 patients with pituitary tumour apoplexy

	N	%
Acute headache	22	92
Nausea/vomiting	13	54
Visual deficit	12	50
Oculomotor deficit	13	54
Complete III palsy	9	
Ptosis	7	
VI palsy	1	
Altered mental state	10	42
Hyperthermia	3	13
Seizure	1	4

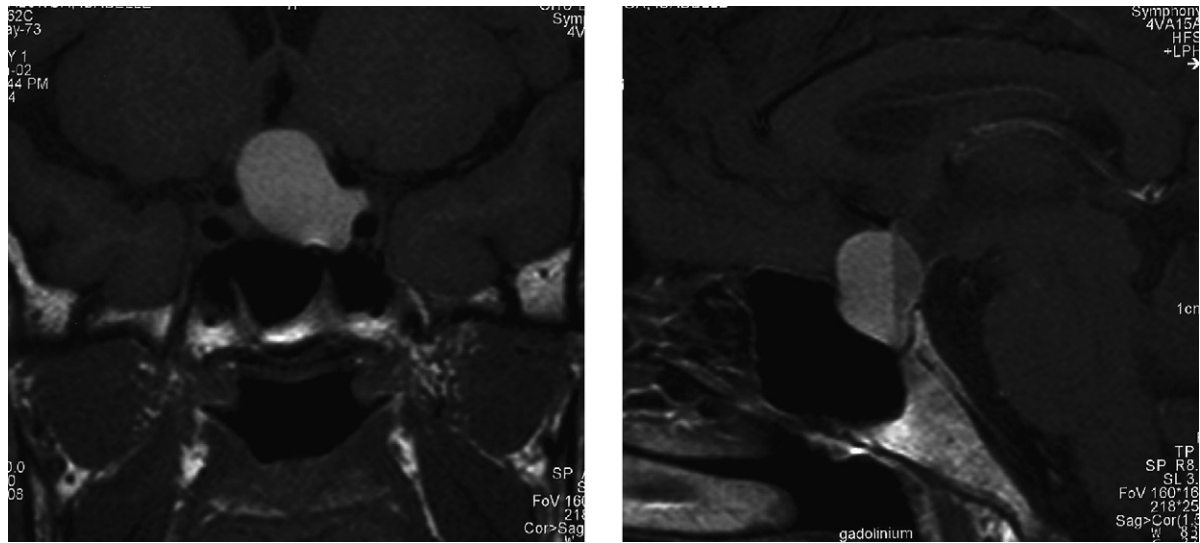


Fig. 1. T1-weighted MRI examination in the coronal (left) and sagittal (right, patient in dorsal decubitus) planes. The patient, a 29-year-old woman, had hyperprolactinemia diagnosed 1 year before. She was treated with clomiphene for sterility. She complained of headache at the end of their pregnancy and developed a severe visual deficit at post-partum day 15. MRI obtained a few days later diagnosed a probably cystic macroadenoma with signs of semi-recent haemorrhage giving rise to a fluid level. The patient was operated at day 27 by a trans-sphenoidal approach. A cystic adenoma with haemorrhagic fluid was removed. Normal anterior pituitary tissue was recognized in the right part of the sella. Pathological examination concluded to a prolactin-secreting adenoma. The patient made a perfect recovery (WHO 0), with normalization of her vision and maintenance of a normally functioning pituitary gland.

47 mm. On T1-weighted images the lesion appeared hyperintense in 10 cases (two heterogeneously) and isointense in one case, with slight contrast enhancement in 8 out of 10 cases. T2-weighted images (seven cases) showed signs of

haemorrhage in all cases. Globally a diagnosis of an expanding sellar mass was obtained in all (19) cases examined by CT-scan or MRI. Ventricular haemorrhage with supratentorial ventricular dilatation was seen in one patient. Carotid

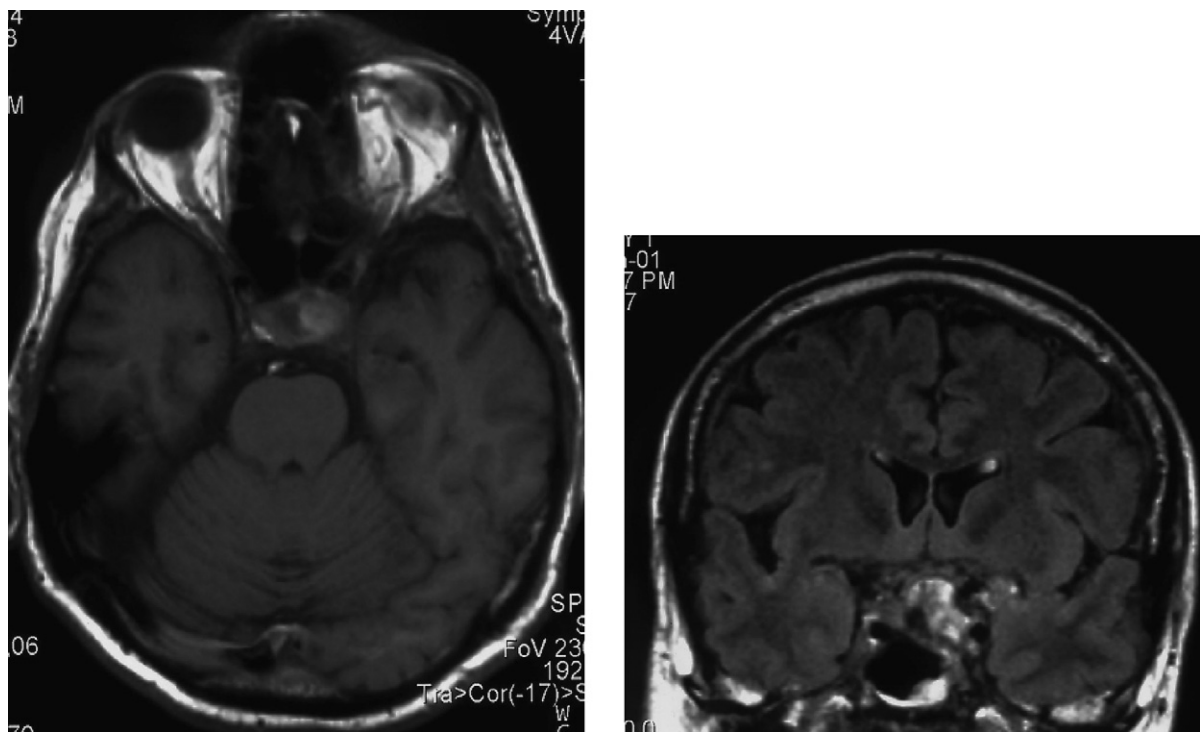


Fig. 2. T1-weighted MRI examination in the axial (left) and coronal (right) planes. This 63-year-old man suddenly developed severe headache and vomiting, followed 24 h later by right oculomotor palsy. Brain CT-scan was normal. MRI diagnosed a pituitary adenoma extending toward the suprasellar area and right cavernous sinus. The patient was operated at day 19 by a trans-sphenoidal approach. A necrotic adenoma was removed. Pathological examination concluded to a non-secreting necrotic adenoma. The patient recovered well (WHO 1), with normalization of oculomotor function. A chronic substitutive treatment with cortisone, thyroid and gonadic hormones was required.

Table 2
Relevant data of three patients treated by conservative therapy

Sex, age	F, 87	F, 80	M, 34
Symptoms	Left ophthalmoplegia	Diplopia Bitemporal hemianopsia	Headache
X-ray and endocrine examination	Huge non-secreting macroadenoma	Huge non-secreting macroadenoma	Gonadotrophin-secreting macroadenoma ^a
Reasons for conservative treatment	Refusal of operation	Admission in resolute phase	Headache only
Medical treatment	Hydrocortison cabergolin	Hydrocortison thyroxin cabergolin	Analgesics cabergolin
Outcome	Clinical cure of PA adenoma stabilized	Clinical cure of PA adenoma stabilized	Clinical cure of PA adenoma cured

^a Diagnosis suggested by elevated blood levels of LH/FSH.

artery angiograms (seven patients) ruled out the presence of an aneurysm, showed a severe vasospasm of carotid arteries in one case and signs of a suprasellar mass in six cases. Using pneumoencephalography (five patients), a suprasellar extension of the lesion was found in three cases.

3.4. Treatment management

All but one patients received high-dose cortisone therapy as soon as the diagnosis was obtained. Three patients in severe clinical condition with hydrocephalus and/or ventricular haemorrhage on CT-scan underwent placement of CSF drainage by a ventricular frontal catheter before ($n=2$) or concomitantly ($n=1$) to the pituitary surgery. Three patients were treated with medical means only, with analgesics, hormonal substitutive therapy and a dopaminergic agent (Table 2). The remaining 21 patients underwent surgery. In seven patients, rapid surgical decompression, within a few to 48 h from admission, was performed due to severe neurological deficit, including visual deficit and/or disturbance of consciousness. Two other patients were operated on within the first week of presentation. In the other 12 cases presenting with a less dramatic clinical picture, surgical intervention was undertaken later, at 2–4 weeks (seven patients), 4–8 weeks (three patients) and 2–3 months (two patients) post PA.

3.5. Surgical procedure

Nineteen patients were operated on via the trans-sphenoidal route. The sphenoid sinus was invaded by the tumour in five cases; the sellar floor was perforated in nine cases. The dura mater was found bluish and under tension ($n=9$), non-existent ($n=1$) or thickened ($n=1$). Upon dura

opening, soft tissue issued from the sellar compartment; the hemorrhagic ($n=7$) or necrotic ($n=7$) adenomatous tissue was easily aspirated in most cases; in only one case was it “sclerofibrotic” and hard to remove: operation for this patient done 99 days after PA disclosed a scarred fibrous tissue with areas of old haemorrhage. Normal pituitary tissue was non-recognized in six patients and was reduced to a thin layer in six. Data are lacking in the remaining nine. The sellar floor was reconstructed with vomer bone pieces; the sphenoid sinus was packed with abdominal fat and biological glue in five patients due to CSF perioperative fistula.

Nasal tampons were left for the 3–5 first following days.

Three patients were operated on by a right frontal craniotomy: the first patient of the series was a woman who had undergone bilateral adrenalectomy for Cushing’s disease in 1963; she developed a Nelson syndrome and PA in 1968 and was operated in emergency by craniotomy. Another acromegalic patient had been operated on in 1973 by craniotomy; the recurrent hemorrhagic pituitary adenoma causing PA was approached by the same craniotomy in 1978. Apart from these two cases, all patients with PA have been operated on by the trans-sphenoidal route. In one patient, a complementary cranial operation was performed 9 days after an emergent trans-sphenoidal approach to remove a remaining huge suprasellar extension.

3.6. Pathology

The pathological data are listed in Table 3. Eight patients were operated on before the immunostaining techniques became available in our institution: no adenoma was recognized within the necrotic tissue in three; a fibroconnective tissue with hemosiderin deposits was seen in another and a

Table 3
Pathological data of 21 patients operated on for pituitary tumour apoplexy

	Without immunohistology $N=8$	With immunohistology $N=13$
Fibroconnective tissue	1	0
Necrotic tissue (no adenoma recognized)	3	0
Pituitary adenoma	4 (“chromophobe”: 4 ^a)	13 (non-secreting: 6, gonadotroph: 2, corticotroph: 2 (1 silent), lactotroph: 2, ? (necrosis): 1)

^a Three of the four “chromophobe” adenomas were probably secreting GH, prolactin and ACTH (Nelson syndrome), respectively.

“chromophobe” adenoma in the remaining four. However, the adenoma was probably in three of the later secreting GH, ACTH and PRL, respectively, as the patients had clinically an obvious acromegalic and Cushing’s syndrome or marked hyperprolactinemia. Immunostaining techniques were used for the most recently operated 13 patients. A pituitary adenoma was diagnosed in all cases, either non-secreting ($n=6$) or secreting prolactin ($n=2$), gonadotrophin ($n=2$) or ACTH ($n=2$). One adenoma was entirely necrotic, preventing identification of the cell type.

3.7. Postoperative evolution

Eight of the 10 patients who were confused, drowsy or comatous at presentation regained a normal mental state; one comatous patient with severe ICA vasospasm died at 4 days postoperatively; the 10th patient remained in a vegetative state and died at 3.5 months postoperatively. One 69-year-old patient had an uneventful postoperative course but died 4 months later after having been admitted in another hospital because of cardiopulmonary distress. No autopsy was performed in any of these three patients.

The preoperative visual disturbances (12 patients) recovered in all but one patients whereas the oculomotor pareses (13 patients) improved in all but two patients.

Six patients developed a transient diabetes insipidus; during the early postoperative period all patients were given cortisone and 10 received thyroid hormones.

One patient with persisting hydrocephalus required a VP shunt. Two patients received postoperative “routine” conventional radiotherapy in 1968 and 1972, respectively; postoperative radiotherapy was done in a third patient in 1978 because PA had occurred in a recurrent GH-secreting adenoma. A well-documented adenoma residue has been treated by stereotactic radiotherapy (X-knife) in one patient whereas a non-secreting adenoma residue is being followed by yearly MRI in another patient.

At the 12-month follow-up ($n=20$ –17 operated and three medically treated), 19 patients yielded a normal life or had a lightly diminished daily activity (WHO score 0–1). Two patients recovered a normal pituitary function; the other 18 live patients required replacement therapy with cortisone ($n=16$), thyroid hormone ($n=14$), testosterone ($n=8/16$ male patients) and growth hormone ($n=3$).

4. Discussion

4.1. Incidence and definition of pituitary apoplexy

Pituitary apoplexy (PA) is in our experience a rare event. Its incidence in the large series of pituitary adenomas observed in our department during a 35-year period is 1.6%. A similar low incidence occurs in the large series of Bills et al. (1.9%) [1], Fraioli et al. (2.8%) [2] and Onesti et al. (2%) [3] while a much higher incidence, up to 13%, is

reported by others [4–10]. This extreme variability in the incidence of PA among various series is probably mainly explained by different criteria used in its definition. In our retrospective analysis of clinical records, we only considered the classical, “full-blown” syndrome, evolving within hours to 1 or 2 days. Patients presenting a pituitary macroadenoma may occasionally complain of headache and/or visual disturbances evolving in a subacute or chronic mode. The clinical picture of PA differs by the acuteness of the symptoms: all patients in our series sought medical emergent attention because of acute, disabling symptoms and were all immediately admitted to the hospital. PA is a clinical diagnosis, with symptoms and signs of an acutely expanding mass in the sellar, para- and/or supra-sellar compartments. The presence of hemorrhagic and/or necrotic areas in a pituitary adenoma on CT-scan or MRI and/or histological slices is commonly seen in otherwise pauci- or even asymptomatic patients [2,4,9,10]. We do not favour the use of terms such as subclinical PA, asymptomatic PA or minor PA syndromes for these patients [3,11,12].

4.2. Precipitating factors

PA can occur in a healthy pituitary gland. Most often PA develops in a either known or unknown pituitary adenoma. The term pituitary tumour apoplexy could be used in those cases linked with a pituitary adenoma. PA rarely occurs in a non-adenomatous pituitary lesion such an abscess, a metastatic tumour or a lymphocytic hypophysitis [13–16]. The majority of our patients presented a pituitary adenoma. Numerous reports have emphasized the association of PA with a variety of precipitating events including pituitary stimulation tests or hormonal therapy with gonadotrophin-releasing hormone agonists, treatment with bromocriptine, treatment by anticoagulants for diagnostic or therapeutic procedures, thrombocytopenia, head trauma or recent surgery [4,6,11,16–51]. In large series, treatment with dopaminergic agonists or anticoagulants appear the two most common factors predisposing to PA. We personally observed an apoplectic episode in three patients receiving anticoagulating or antiaggregant therapy, in one patient with Von Willebrand disease and in three patients with a prolactin-secreting adenoma following cabergolin treatment. Bromocriptine treatment has been often incriminated in the development of PA [4,6,24,39]. On the other hand cabergolin has to our knowledge not been reported yet as a predisposing factor. Most apoplectic episodes in our and other series occur without immediate provocation.

4.3. Clinical picture and diagnosis of Pituitary apoplexy

The preponderance of male patients (67% in our series) is observed in some series [1,5,9,52–55]. The clinical manifestations of PA in our 24 patients included severe sudden headache (92%), nausea and vomiting (54%), visual disturbances (50%), ptosis/ophtalmoplegia (54%) and/or a

confused mental state (42%). Symptoms of meningeal irritation are present when blood gains access to the suprasellar cisterns through a dilated diaphragmatic aperture; the chemical meningitis provokes headache, fever, nuchal rigidity and photophobia [56]. ICA vasospasm due to subarachnoid hemorrhage can develop and if severe lead to ischemic symptoms or even death [36]. PA often occurs in young and middle-aged patients with a mean age in our series of 56 years [1,3,10,19,53–55,57]. The clinical picture of PA in patients of this age group mimicks a subarachnoid hemorrhage from aneurysmal rupture, a much more common pathology than PA. A simple skull X-ray will often suggest the diagnosis, by revealing increased sella turcica volume. PA occurred in five patients of our series in the period 1968–1973, before the era of CT-scan. Skull X-rays yielded the diagnosis of a pituitary expanding mass, which was confirmed by pneumoencephalography and/or carotid arteriography. Nowadays, patients suspected of PA are best studied by CT-scan and MRI [14,19,58] (respectively, 16 and 11 patients in our series). In the majority of cases the lesion appeared spontaneously hyperdense on CT-scan and hyperintense on T1- and T2-weighted MRI. Features of haemorrhage and/or infarction are well demonstrated by MRI, allowing a positive diagnosis of PA. If available MRI is the initial emergency diagnostic procedure. MRI, if necessary using diffusion techniques, is more sensitive than CT-scan in the acute stage of PA. When both MRI and CT-scan are unavailable, diagnosis can be established if standard X-rays show an enlarged sella in a patient suspected of suffering PA. Cerebral angiography used in the past to rule out an aneurysm is usefully replaced by MRI and MR angiography, which is also able to show vasospasm. We have not observed thickening of sphenoid sinus mucosa in any of 11 MRI examinations as did Arita et al. [19].

4.4. Conservative and/or operative management

PA always represents a medical emergency. Panhypopituitarism was present on admission in 14 of the 20 studied patients. All but one patients benefited from high-dose hydrocortisone replacement therapy which is the most urgent treatment measure. Sporadic cases of PA cure by isolated medical treatment have been reported [42,59–62]. Three patients in our series of PA presented a benign course with resolution of symptoms by medical treatment alone. On the contrary, three patients in extremely serious condition on presentation underwent placement of CSF drainage. PA has been managed as a surgical pituitary emergency (operation within 48 h of admission) in seven patients (33%) because of severe visual or oculomotor deficits (five patients) or coma (two patients). Two further patients were operated on within the first week of presentation. A significant better outcome of visual deficits and pituitary dysfunction has been reported in those patients decompressed within the first week [1,12,52,54,63]. The remaining patients in our series (52%) were operated on later because they presented with a non-dramatic clinical course and significantly improved with medical treatment. The trans-

sphenoidal approach has been since 1971 the one of choice for pituitary diseases in our department. This route used in 19 patients of the present series has allowed good tumour exposure, easy removal of hemorrhagic and necrotic tissue even when marked suprasellar extension was present. In only one case was a second operation necessary, by craniotomy.

4.5. Pathological findings

The pathological examination of our surgical specimens often diagnosed areas of necrosis and/or haemorrhage in adenomatous tissue. The specimen was entirely necrotic in a few cases while in one case lately operated on the tissue appeared fibroconnective with deposits of hemosiderin. In most series PA appears to occur more often in a non-secreting adenoma [1,3,6,19,53–55]. In our series half of the adenomas studied by immunohistochemistry were secreting; three other cases studied by conventional histological techniques were probably functional as well. Similarly to the series of Bonicki et al. [4], ours thus includes more secreting than non-secreting pituitary adenomas. Autopsy was performed in two patients reported in the literature who died at respectively, 2 and 4 days after PA [25,36]. Macroscopic and microscopic examination of the brain revealed marked cerebral edema, a diffuse subarachnoid hemorrhage, a large hemorrhagic pituitary adenoma with suprasellar extension, necrosis and petechial bleeding in the hypothalamus and uni or bilateral compression or thrombosis of cavernous sinus.

4.6. Outcome

PA can be fatal, from massive subarachnoid haemorrhage or from secondary systemic complications [22,64,65]. On the contrary, complete recovery is possible in very severe cases if therapeutic measures are initiated in time [50,61]. In our series two patients operated on in extremely severe condition died at 4 days and 3.5 months. A third patient had an uneventful postoperative course but died at 4 months from an ill-defined cardiopulmonary problem. This gives a mortality rate of 12.5% in this series whereas the rate is around 0.7% for the large series of 1540 pituitary lesions treated in our department. Follow-up of the remaining 21 patients of the present series (mean 5.5 years) shows restoration of a normal mental state in 100%, of normal vision in 92% of the preoperatively affected patients while 85% of the preoperative oculomotor pareses are improved or resolved. All patients but one yield a normal life; most need a long-term adrenal (80%), thyroid (70%), gonadal (40%) and/or growth hormone (15%) replacement therapy.

In conclusion, true tumour pituitary apoplexy is in our experience a classical but rare complication of pituitary adenoma as we encountered only 24 cases out of 1540 observed pituitary adenomas (1.6%) in a 35-year period. Most cases occur in a previously undiagnosed pituitary adenoma. The clinical symptoms evolve within hours to 1 or 2 days; they include headache, nausea and vomiting, visual and/or

oculomotor deficits, confusion, drowsiness or even coma. The radiological diagnosis is nowadays provided essentially by CT-scan, usually done emergently and of course MRI if possible. After medical stabilization including in particular cortisone treatment, surgical decompression of the sellar and suprasellar areas is indicated as soon as possible in case of severe visual or oculomotor deficit and/or altered consciousness. The potential for restitution of pituitary activity is another reason for advocating timely surgical intervention. The trans-sphenoidal approach allows good functional results in the majority of cases. Panhypopituitarism, present at admission in the majority of patients, will often require a long-term substitutive therapy by adrenal, thyroid, gonadal and/or growth hormones.

References

- [1] Bills DC, Meyer FB, Laws ER, Davis DH, Ebersold MJ, Scheithauer BW, et al. A retrospective analysis of pituitary apoplexy. *Neurosurgery* 1993;33(4):602–9.
- [2] Fraioli B, Esposito V, Palma L, Cantore G. Hemorrhagic pituitary adenomas: clinicopathological features and surgical treatment. *Neurosurgery* 1990;27(5):741–8.
- [3] Onesti ST, Wisniewski T, Post KD. Clinical versus subclinical pituitary apoplexy: presentation, surgical management and outcome in 21 patients. *Neurosurgery* 1990;26(6):980–6.
- [4] Bonicki W, Kasperkik-Zaluska A, Koszewski W, Zgliczynski W, Wilawski J. Pituitary apoplexy: endocrine, surgical and oncological emergency. Incidence, clinical course and treatment with reference to 799 cases of pituitary adenomas. *Acta Neurochir* 1993;120: 118–22.
- [5] Carral San Laureano F, Gavilan Villarejo I, Olveira Fuster G, Ortego Rojo J, Aguilar Diosdado M. Pituitary apoplexy: retrospective study of 9 patients with hypophyseal adenoma. *Ann Med Interne* 2001;18(11):582–6.
- [6] da Motta LA, de Mello PA, de Lacerda CM, Neto AP, da Motta LD, Filho MF. Pituitary apoplexy. Clinical course, endocrine evaluations and treatment analysis. *J Neurosurg Sci* 1999;43(1):25–36.
- [7] Deb S. Clinical significance of pituitary apoplexy. *J Indian Med Assoc* 1998;96(10):302–3.
- [8] Milazzo S, Toussaint P, Proust F, Touzet G, Malthieu D. Ophthalmologic aspects of pituitary apoplexy. *Eur J Ophthalmol* 1996;6(1):69–73.
- [9] Mohr G, Hardy J. Hemorrhage, necrosis and apoplexy in pituitary adenomas. *Surg Neurol* 1982;18:181–9.
- [10] Wakai S, Fukushima T, Teramoto A, Sano K. Pituitary apoplexy: its incidence and clinical significance. *J Neurosurg* 1981;55:187–93.
- [11] Bhattacharya A, Tymms DJ, Naqvi N. Asymptomatic pituitary apoplexy after aortocoronary bypass surgery. *Int J Clin Pract* 1999;53(5):394–5.
- [12] Sha C, Gao P, Yang Y, Xie H, Wang X, Liu S. Diagnosis and treatment of subclinical pituitary apoplexy: report of 21 cases. *Chung-Hua Wai Ko Tsa Chih* 2002;40(10):755–7.
- [13] Kingdon CC, Sidhu PS, Cohen J. Pituitary apoplexy secondary to an underlying abscess. *J Infect* 1996;33(1):53–5.
- [14] Piotin M, Tampieri D, Rufenacht DA, Mohr G, Garant M, Del Carpio R, et al. The various MRI patterns of pituitary apoplexy. *Eur Radiol* 1999;9(5):918–23.
- [15] Dan NG, Feiner RI, Houang MT, Turner JJ. Pituitary apoplexy in association with lymphocytic hypophysitis. *J Clin Neurosci* 2002;9(5):577–80.
- [16] Lee MS, Pless M. Apoplectic lymphocytic hypophysitis. Case report. *J Neurosurg* 2003;98(1):183–5.
- [17] Acar F, Mertol T. Pituitary apoplexy following laparoscopic cholecystectomy. *Acta Neurochir* 2004;146(11):1275–6.
- [18] Alzetani A, Fisher C, Costa R, Ohri SK. Ptosis postcardiac surgery: a case of pituitary apoplexy. *Ann Thorac Surg* 2002;73(1): 300–1.
- [19] Arita K, Kurisu K, Tominaga A, Sugiyama K, Ikawa F, Yoshioka H, et al. Thickening of sphenoid sinus mucosa during the acute stage of pituitary apoplexy. *J Neurosurg* 2001;95(5):897–901.
- [20] Chen Z, Murray AW, Quinlan JJ. Pituitary apoplexy presenting as unilateral third cranial nerve palsy after coronary artery bypass surgery. *Anesth Analg* 2004;98(1):46–8.
- [21] Cohen A, Kishore K, Wolansky L, Frohman L. Pituitary apoplexy occurring during large volume liposuction surgery. *J Neuroophthalmol* 2004;24(1):31–3.
- [22] Dokmetas HS, Selcuklu A, Colak R, Unluhizarci K, Bayram F, Kelestimir F. Pituitary apoplexy probably due to TRH and GnRH stimulation tests in a patient with acromegaly. *J Endocrinol Invest* 1999;22(9):698–700.
- [23] Engel G, Huston M, Oshima S, Beck C, Harsh G, Rosenthal MH, et al. Pituitary apoplexy after leuprolide injection for ovum donation. *J Adolesc Health* 2003;32(1):89–93.
- [24] Foppiani L, Piredda S, Guido R, Spaziante R, Giusti M. Gonadotrophin-releasing hormone-induced partial empty sella mimicking pituitary apoplexy in a woman with a suspected non-secreting macroadenoma. *J Endocrinol Invest* 2000;23(2):118–21.
- [25] Fuchs S, Beeri R, Hasin Y, Weiss AT, Gotsman MS, Zahger D. Pituitary apoplexy as a first manifestation of pituitary adenoma following intensive thrombolytic and antithrombotic therapy. *Am J Cardiol* 1998;81(1):110–1.
- [26] Hernandez Morin N, Huet D, Hauteceuvre M. Two cases of non-functional gonadotroph adenoma pituitary apoplexy following Gn-RH-agonist treatment revealing gonadotroph adenoma and pseudopituitary apoplexy after GnRH administration. *Ann Endocrinol* 2003;64(3):227–31.
- [27] Hiroi N, Ichijo T, Shimojo M, Ueshiba H, Tsuboi K, Miyachi Y. Pituitary apoplexy caused by luteinizing hormone-releasing hormone in prolactin-producing adenoma. *Intern Med* 2001;40(8):747–50.
- [28] Lee DH, Chung MY, Chung DJ, Kim JM, Lee TH, Nam JH, et al. Apoplexy of pituitary macroadenoma after combined test of pituitary function. *Endocr J* 2000;47(3):329–33.
- [29] Lennon M, Seigne P, Cunningham AJ. Pituitary apoplexy after spinal anaesthesia. *Br J Anaesth* 1998;81(4):616–8.
- [30] Liu JK, Nwagwu C, Pikus HJ, Couldwell WT. Laparoscopic anterior lumbar interbody fusion precipitating pituitary apoplexy. *Acta Neurochir* 2001;143(3):303–6.
- [31] Masago A, Ueda Y, Kanai H, Nagai H, Umemura S. Pituitary apoplexy after pituitary function test: a report of two cases and review of the literature. *Surg Neurol* 1995;43:158–65.
- [32] Matsuura I, Saeki N, Kubota M, Murai H, Yamaura A. Infarction followed by hemorrhage in pituitary adenoma due to endocrine stimulation test. *Endocr J* 2001;48(4):493–8.
- [33] Mattke AF, Vender JR, Anstadt MR. Pituitary apoplexy presenting as Addisonian crisis after coronary artery bypass grafting. *Tex Heart Inst J* 2002;29(3):193–9.
- [34] Miranda M, Barros L, Knopfmacher M, Augusto EC, Jacomossi A, Cukiert A, et al. Pituitary apoplexy followed by endocrine remission. Report of two cases. *Arq Neuro-psiquiatr* 1998;56(3A):449–52.
- [35] Morsi A, Jamal S, Silverberg JD. Pituitary apoplexy after leuprolide administration for carcinoma of the prostate. *Clin Endocrinol* 1996;44(1):121–4.
- [36] Okuda O, Umezawa H, Miyaoka M. Pituitary apoplexy caused by endocrine stimulation tests: a case report. *Surg Neurol* 1994;42:19–22.
- [37] Oo MM, Krishna AY, Bonavita GJ, Rutecki GW. Heparin therapy for myocardial infarction: an unusual trigger for pituitary apoplexy. *Am J Med Sci* 1997;314(5):351–3.

- [38] Otsuka F, Kageyama J, Ogura T, Makino H. Pituitary apoplexy induced by a combined anterior pituitary test: case report and literature review. *Endocr J* 1998;45(3):393–8.
- [39] Pinto G, Zerah M, Trivin C, Brauner R. Pituitary apoplexy in an adolescent with prolactin-secreting adenoma. *Horm Res* 1998;50(1):38–41.
- [40] Reznik Y, Chapon F, Lahlou N, Deboucher N, Mahoudeau J. Pituitary apoplexy of a gonadotroph adenoma following gonadotrophin releasing hormone agonist therapy for prostatic cancer. *J Endocrinol Invest* 1997;20(9):566–8.
- [41] Riedl M, Clodi M, Kotzmann H, Hainfellner JA, Schima W, Reitner A, et al. Apoplexy of pituitary macroadenoma with reversible third, fourth and sixth cranial nerve palsies following administration of hypothalamic releasing hormones: MR features. *Eur J Radiol* 2000;36(1):1–4.
- [42] Rotman-Pikielny P, Patronas N, Papanicolaou DA. Pituitary apoplexy induced by corticotrophin-releasing hormone in a patient with Cushing's disease. *Clin Endocrinol* 2003;58(5):545–9.
- [43] Sanno N, Ishii Y, Sugiyama M, Tagagi R, Node Y, Teramoto A. Subarachnoid haemorrhage and vasospasm due to pituitary apoplexy after pituitary function tests. *Acta Neurochir* 1999;141(9):1009–10.
- [44] Skljarevski V, Khoshyomm S, Fries TJ. Pituitary apoplexy in the setting of coronary angiography. *J Neuroimaging* 2003;13(3):276–9.
- [45] Suga T, Kagawa S, Goto H, Yoshioka K, Hosoya T. A case of pituitary adenoma progressing to pituitary apoplexy on the occasion of cerebral angiography. *No Shinkei Geka* 1996;24(5):475–9.
- [46] Szabolcs I, Kesmarki N, Bor K, Czirjak S, Dohan O, Slovik F, et al. Apoplexy of a pituitary macroadenoma as a severe complication of preoperative thyrotrophin-releasing hormone (TRH) testing. *Exp Clin Endocrinol Diabetes* 1997;105(4):234–6.
- [47] Tasdemiroglu E, Zuccarello M, Tew JM. Recovery of vision after transcranial decompression of pituitary apoplexy characterized by third ventricular hemorrhage. *Neurosurgery* 1993;32(1):121–4.
- [48] Uchiyama H, Nishizawa S, Satoh A, Yokoyama T, Uemura K. Post-traumatic pituitary apoplexy: two case reports. *Neurol Med-Chir* 1999;39(1):36–9.
- [49] Watson SL, Francis IC, Coroneo MT. Pituitary apoplexy presenting with an orbital bruit. *Clin Exp Ophthalmol* 2002;30(4):305–7.
- [50] Wiesman M, Gliemroth J, Kehler U, Missler U. Pituitary apoplexy after cardiac surgery presenting as deep coma with dilated pupils. *Acta Anaesthesiol Scand* 1999;43(2):236–8.
- [51] Wongpraparut N, Pleanboonlers N, Suwattee P, Rerkpattanapipat P, Turtz A, Moster M, et al. Pituitary apoplexy in a patient with acute myeloid leukaemia and thrombocytopenia. *Pituitary* 2000;3(2):113–6.
- [52] Agrawal D, Mahapatra AK. Visual outcome of blind eyes in pituitary apoplexy after trans-sphenoidal surgery: a series of 14 eyes. *Surg Neurol* 2005;63:42–6.
- [53] Lubina A, Olchovsky D, Berezin M, Ram Z, Hadani M, Shimon I. Management of pituitary apoplexy: clinical experience with 40 patients. *Acta Neurochir* 2005;147(2):151–7.
- [54] Randeve HS, Schoebel J, Byrne J, Esiri M, Adams CB, Wass JA. Classical pituitary apoplexy: clinical features, management and outcome. *Clin Endocrinol* 1999;51(2):181–8.
- [55] Semple PL, Webb MK, de Villiers JC, Laws ER. Pituitary apoplexy. *Neurosurgery* 2005;56:65–73.
- [56] Brouns R, Crols R, Engelborghs S, De Deyn PP. Pituitary apoplexy presenting as chemical meningitis. *Lancet* 2004;364(9433):502.
- [57] Biousse V, Newman NJ, Oyesiku NM. Precipitating factors in pituitary apoplexy. *J Neurol Neurosurg Psychiatry* 2001;71(4):542–5.
- [58] Rogg JM, Tung GA, Anderson G, Cortez S. Pituitary apoplexy: early detection with diffusion-weighted MR imaging. *AJNR* 2002;23(7):1240–5.
- [59] Brisman MH, Katz G, Post KD. Symptoms of pituitary apoplexy rapidly reversed with bromocriptine. case report. *J Neurosurg* 1996;85(6):1153–5.
- [60] Kamiya Y, Jin-NO Y, Tomita K, Suzuki T, Ban K, Sugiyama N, et al. Recurrence of Cushing's disease after long-term remission due to pituitary apoplexy. *Endocr J* 2000;47(6):793–7.
- [61] Schatz NJ, Job OM, Glaser JS. Spontaneous resolution of pituitary adenoma after apoplexy. *J Neuroophthalmol* 2000;20(1):42–4.
- [62] Wickers M, Kristof RA, Springer W, Schramm J, Klingmuller D. Pituitary apoplexy with spontaneous cure of acromegaly and its possible relation to Gd-DTPA-administration. *Acta Neurochir* 1997;130(10):992–4.
- [63] Verrees M, Arafah BM, Selman WR. Pituitary tumor apoplexy. Characteristics, treatment and outcomes. *Neurosurg Focus* 2004;16(4):E6.
- [64] Lange M, Woenckhaus M, Segiet W, Oeckler R. A rare fatal course of disease in a patient with spontaneous pituitary apoplexy. Case report and literature review. *Neurosurg Rev* 1999;22(2-3):163–9.
- [65] Wohaibi MA, Russell NA, Ferayan AA, Awada A, Jumah MA, Omojola M. Pituitary apoplexy presenting as massive subarachnoid hemorrhage. *J Neurol Neurosurg Psychiatry* 2000;69(5):700–1.