

ICP or cryptococcal brainstem vasculitis. It may be that antifungal regimen was inadequate and control of ICP is vital. However, in our case it was difficult to justify the transfer to neurosurgical ICU, as there were clear signs of improvement.

At the same time this case illustrates dramatic and sometimes fatal course of cryptococcal meningitis as presenting feature in AIDS. Patient's GCS deterior-

ated without any preceding cardiorespiratory event, seizures or prolonged duration of loss of airway with risk of aspiration. Clinically, terminal event suggests catastrophic brain stem pathology which could either be due to raised ICP or cryptococcal vasculitis [2]. Unfortunately autopsy was not performed.

### Drawing double images: a case of anosognosia for diplopia

M. Lepore<sup>a</sup>, M. Conson<sup>b</sup>, D. Grossi<sup>b</sup> and L. Trojano<sup>b</sup>

<sup>a</sup>*Stazione Climatica Bianchi, Portici; and*  
<sup>b</sup>*Department of Psychology, Second University of Naples, Caserta, Italy*

Correspondence: Luigi Trojano, Department of Psychology, Second University of Naples, Via Vivaldi 43, 81100 Caserta, Italy (tel./fax: +39 0823 274774; e-mail: luigi.trojano@unina2.it).

**Keywords:** diplopia, drawing, visual awareness, visual neglect

Received 22 September 2004  
Accepted 16 January 2005

Sir,

Squint and diplopia usually follow brainstem damage, but have been rarely reported after purely cortical lesions [1]. Diagnosis of diplopia mainly rests on subjective reports: virtually all patients criticize their deficit [2]. We report for the first time a patient with left neglect and binocular diplopia who was not aware of his visual defect.

A 76-year-old right-handed lawyer presented an haemorrhagic stroke in the right middle and superior temporal gyri and in the posterior parietal lobule (Fig. 1). On admission in a rehabilitation unit, 1 month after stroke, the patient showed left hemiparesis and hemianaesthesia, without visual field loss as assessed by Goldmann perimetry. Standard orthoptic measures demonstrated corrected-to-normal visual acuity, no limitations of ocular movements, binocular diplopia, and divergent squint on the Cover test. In ecological settings the patient sometimes asked for 'duplicated' objects close to him

and never admitted his errors, even upon repeated confutation. However, during the clinical interview the patient spontaneously stated that he was in the hospital because of paresis on his left side, due to a cerebrovascular accident.

At that time, a neuropsychological assessment showed moderate left extrapersonal neglect (3/21 left-sided omissions on a line cancellation and 36/54 on a star cancellation task; 14 mm mean rightward displacement on 20-cm horizontal line bisection), without defects of verbal short-term memory and learning (word and digit span, Rey's 15-word test, story recall test), or of abstract thinking (abstract verbal reasoning test, cognitive estimation test), in reference to Italian age- and education-adjusted normative data. On copying drawings the patient often omitted left-sided elements, and showed a systematic tendency to draw figures or their elements twice. An extended copying task under binocular or monocular viewing (30 geometrical drawings per condition) demonstrated consistent 'double drawing' in the binocular viewing condition only, in both visual hemifields (Fig. 2). The patient always judged his performance as adequate; when he was shown his own wrong reproductions together with the respective models under monocular viewing, he provided vague or confabulatory explanations of his mistakes (e.g. 'this was not the model', or 'when I'm tired, I often am in straits'), in a fashion similar to that described in patients affected by anosognosia for cortical blindness (Anton's syndrome).

Diplopic subjects perceive each visual stimulus doubled, but they usually acknowledge that one is a 'false' image and can depict it under request [1,3]. Our patient showed spontaneous 'duplicated' drawing, a finding not reported so far. This behaviour was abolished by left or

### References

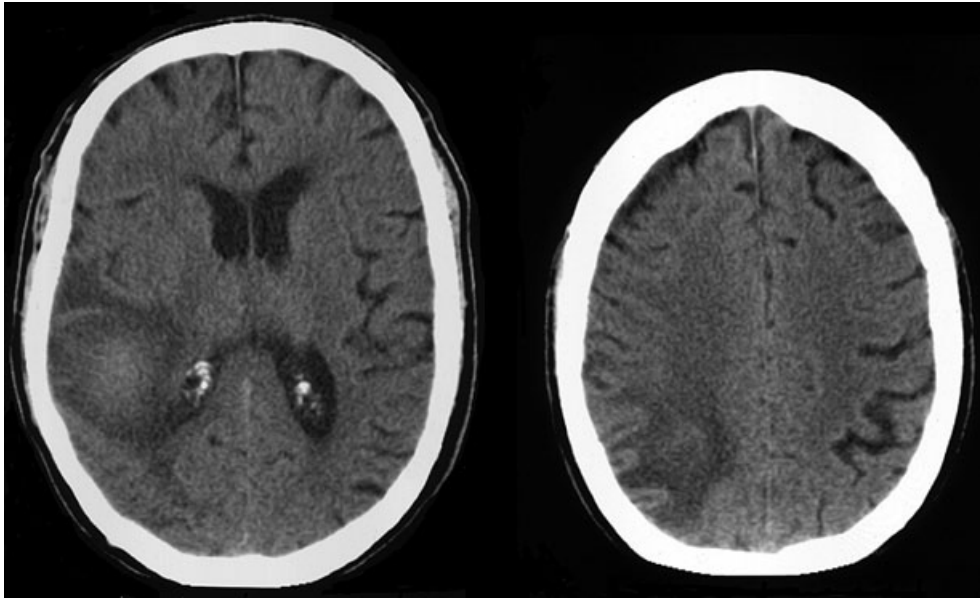
1. Angstwurm K, Sokolowska-Koehler W, Stadelmann C, Schielke E, Weber JR. Fulminant cryptococcal meningitis as presenting feature in a patient with AIDS. *European Journal of Neurology* 2004; **11**: 353–354.
2. Lan SH, Chang WN, Lu CH, Lui CC, Chang HW. Cerebral infarction in chronic meningitis: a comparison of tuberculous meningitis and cryptococcal meningitis. *The Quarterly Journal of Medicine* 2001; **94**: 247–253.

right eye patching, allowing us to exclude other positive pathologies of vision [4] and neglect-related perseverations [5]. Therefore, 'double drawing' could be ascribed to anosognosia for binocular diplopia. Such a defect would explain the lack of self-report of diplopia in right-damaged patients with cortical squint [1].

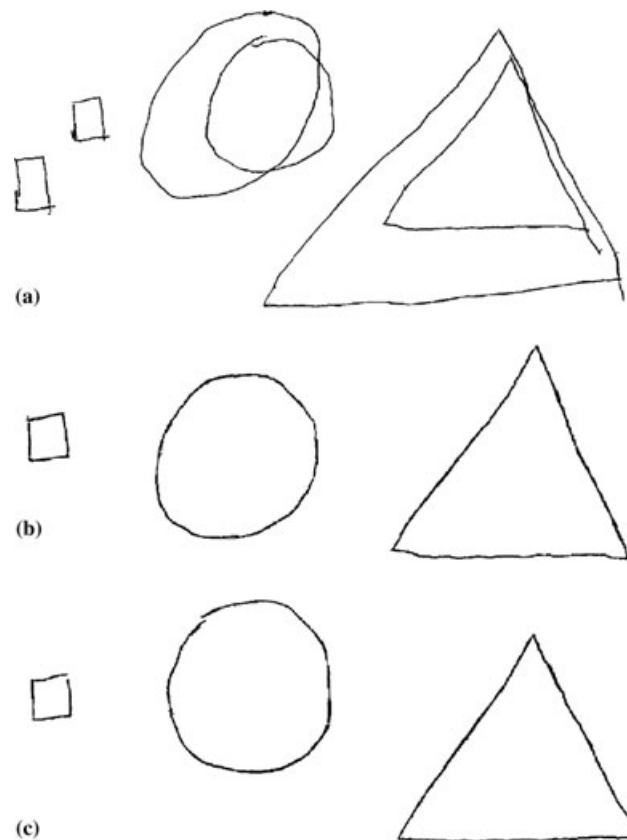
In our patient unawareness for diplopia was not related to a general intellectual impairment or to affective/motivational denial, as the patient did not deny his disabling left motor defect. A disorder at higher levels of visual processing [6], and, more specifically, a defect in conscious processing of visual information (first-order explanation; see Ref. [7]) could better explain the present findings. We could also speculate that the right temporo-parietal lesion made our patient unable to comprehend his defective processing of binocular information. Functional neuroimaging studies demonstrate that a wide neural network, including regions outside the visual cortex, contribute to the conscious visual experience [8,9]. The present findings would support the role of non-visual cortex in awareness of visual impairments.

### References

1. Flower MS, Wade DT, Richardson AJ, Stein JF. Squints and diplopia seen after brain damage. *Journal of Neurology* 1996; **243**: 86–90.
2. Lee MS, Volpe NJ. Double vision. *Curr Treat Options Neurol* 2001; **3**: 383–388.
3. Jones MR, Waggoner R, Hoyt WF. Cerebral polyopia with extrastriate quadrantanopia: report of a case with magnetic resonance documentation of V2/V3 cortical infarction. *Journal of Neuro-Ophthalmology* 1999; **19**: 1–6.
4. Ffytche DH, Howard RJ. The perceptual consequences of visual loss: 'positive' pathologies of vision. *Brain* 1999; **122**: 1247–1260.



**Figure 1** CT-images showing the patient's hemorrhagic lesion involving the right middle and superior temporal gyri and the posterior parietal lobule.



**Figure 2** Patient's graphic productions on the extended copying task: in the binocular viewing condition (a) the patient always drew figures or their elements twice, sometimes side by side or one above the other, sometimes partially overlapping them; in monocular left (b) or right (c) viewing conditions he performed flawlessly.

5. Rusconi M, Maravita A, Bottini G, Vallar G. Is the intact side really intact? Perseverative responses in patients with unilateral neglect: a productive manifestation. *Neuropsychologia* 2002; **40**: 594–604.
  6. Bisiach E, Vallar G, Perani D, Papagno C, Berti A. Unawareness of disease following lesions of the right hemisphere: anosognosia for hemiplegia and anosognosia for hemianopia. *Neuropsychologia* 1986; **24**: 471–482.
  7. Schacter DL. Toward a cognitive neuropsychology of awareness: implicit knowledge and anosognosia. *Journal of Clinical and Experimental Neuropsychology* 1990; **12**: 155–178.
  8. Rees G. Neuroimaging of visual awareness in patients and normal subjects. *Current Opinion in Neurobiology* 2001; **11**: 150–156.
  9. Vuilleumier P, Sagiv N, Hazeltine E, *et al.* Neural fate of seen and unseen faces in visuospatial neglect: a combined event-related MRI and event-related potential study. *Proc Natl Acad Sci USA* 2001; **98**: 3495–3500.
-