

Meningeal Hemangiopericytoma Manifesting as Massive Intracranial Hemorrhage

—Two Case Reports—

Jun MARUYA, Yasuhiro SEKI, Kenichi MORITA, Keiichi NISHIMAKI,
and Takashi MINAKAWA

Department of Neurosurgery, Akita Red Cross Hospital, Akita

Abstract

Meningeal hemangiopericytoma is rare, and only seven cases have manifested as intracranial hemorrhage. We treated two patients with meningeal hemangiopericytoma manifesting as life-threatening massive intracerebral hemorrhage. **Case 1:** A 66-year-old woman presented with consciousness disturbance and left hemiparesis. Computed tomography showed a mass lesion in the right frontal parasagittal region and massive hematoma in the brain tissue at the medial border of the lesion. Immediate evacuation of the hematoma was performed. Postoperative magnetic resonance imaging revealed a well-enhanced mass lesion with small intratumoral hemorrhage. The tumor was removed totally through a bilateral frontal craniotomy. The postoperative course was uneventful. The histological diagnosis was meningeal hemangiopericytoma. Radiotherapy was not performed. **Case 2:** A 59-year-old man presented with consciousness disturbance. Computed tomography showed a mass lesion in the right frontotemporal convexity region and massive hematoma in the brain tissue at the medial border of the lesion. His neurological condition was refractory to any treatment and the clinical diagnosis of brain death was confirmed. Autopsy was performed and the histological diagnosis was meningeal hemangiopericytoma. Meningeal hemangiopericytoma manifesting as intracranial hemorrhage is quite rare, but carries the risk of life-threatening massive bleeding from the tumor.

Key words: meningeal hemangiopericytoma, intracranial hemorrhage, complete excision, radiotherapy

Introduction

Hemangiopericytoma is a rare vascular tumor arising from the pericytes of Zimmermann, which are modified smooth-muscle cells surrounding the capillary vessels.¹⁸⁾ Meningeal hemangiopericytoma is another rare, highly vascular tumor accounting for <1% of all central nervous system tumors.¹⁰⁾ This neoplasm is considered to be malignant, recurs in 50% to 80% of cases in series of 20 or more patients, and metastasizes in 14% to 30%.⁸⁾ Meningeal hemangiopericytoma was initially believed to be a meningioma variant (angioblastic meningioma, hemangiopericytic type), but genetic analysis has shown no relationship to meningiomas.¹³⁾ The current classification of the World Health Organization has eliminated the term angioblastic meningioma in

favor of hemangiopericytoma.¹⁵⁾

Brain tumor manifesting as intracranial hemorrhage is a well-known phenomenon.²⁰⁾ However, hemangiopericytoma is rarely associated with hemorrhage, both in the central nervous system and in extraneural sites.¹⁾ Meningeal hemangiopericytoma manifesting as intracranial hemorrhage has been reported in only seven cases.^{1,4,5,9,16,21)} We treated two patients with meningeal hemangiopericytoma manifesting as life-threatening massive intracranial hemorrhage.

Case Reports

Case 1: A 66-year-old woman was admitted to our hospital because of consciousness disturbance and left hemiparesis on December 4, 1999. She had a history of gastric cancer 30 years before admission, but no history of cardiovascular disease or trauma. About 1 month prior to admission, she complained

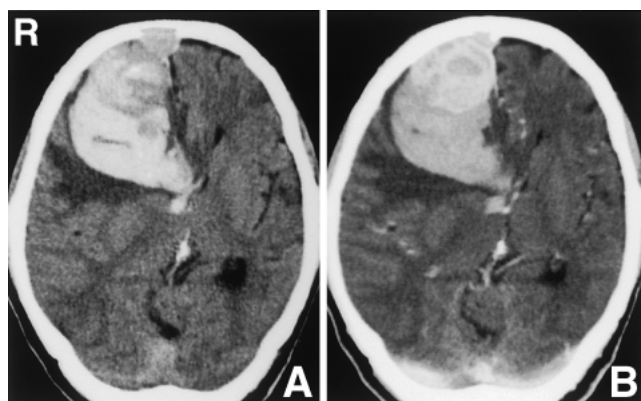


Fig. 1 Case 1. Computed tomography scan showing a $5 \times 3 \times 5.5$ cm high density lesion in the right frontal parasagittal region (A), which was enhanced after injection of contrast medium (B), and massive hematoma in the brain tissue at the medial border of the lesion. Marked perifocal edema, midline shift, and bone defect of the internal table of the calvaria are also seen.

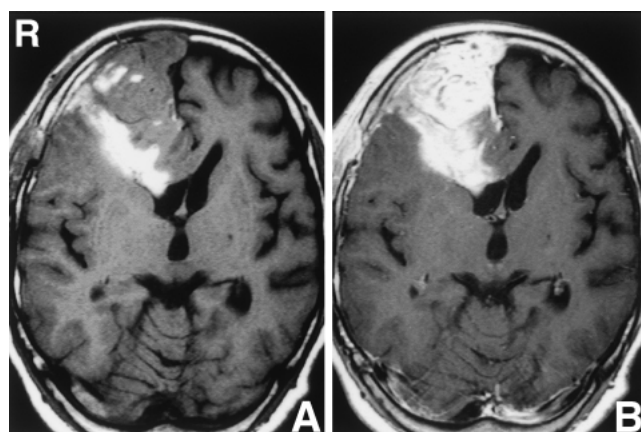


Fig. 2 Case 1. T₁-weighted magnetic resonance images after the first operation (A) and with contrast medium (B) demonstrating a well-enhanced mass lesion extending into the superior sagittal sinus. Small intratumoral hemorrhage and bone defect of the internal table of the calvaria are seen.

of memory disturbance. She suffered onset of gait disturbance and urinary incontinence on the day before admission, and sudden onset of headache and consciousness disturbance on the day of admission.

Neurological examination revealed left hemiparesis and Glasgow Coma Scale (GCS) score of 13/15. Computed tomography (CT) showed a $5 \times 3 \times 5.5$ cm high density lesion in the right frontal parasagittal region, which was enhanced after injection of contrast medium, and massive hematoma in the brain tissue at the medial border of the lesion. Marked perifocal edema and midline shift were also recognized (Fig. 1).

Immediate evacuation of the massive intracerebral hematoma only was performed, because her neurological condition was deteriorating rapidly and there was no time for further examinations such as angiography or magnetic resonance (MR) imaging. Postoperatively, her consciousness disturbance and left hemiparesis improved promptly and mental dullness was gradually ameliorated. MR imaging demonstrated a well-enhanced mass lesion extending into the superior sagittal sinus. Small intratumoral hemorrhage and bone defect of the internal table of the calvaria were recognized (Fig. 2). Angiography revealed occlusion of the superior sagittal sinus and supply from the left anterior and posterior falxian arteries and right frontopolar artery (Fig. 3).

Tumor resection was performed via a bilateral frontal craniotomy on December 16, 1999. The

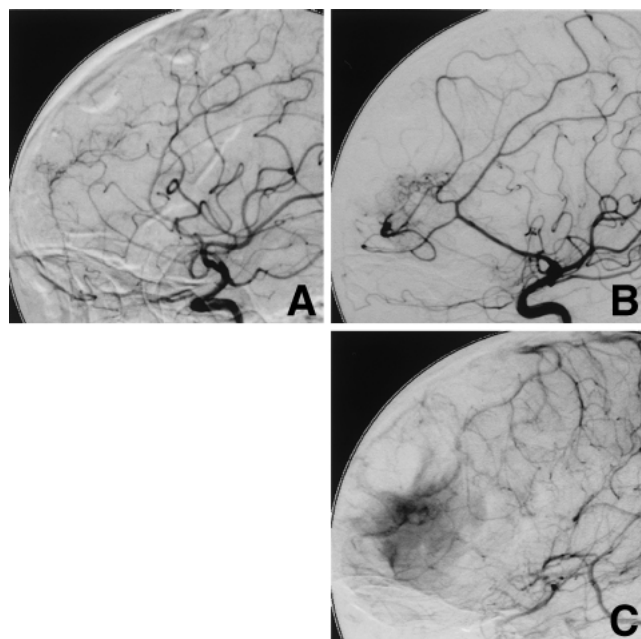


Fig. 3 Case 1. A: Left internal carotid angiogram after evacuation of the hematoma showing blood supply from the left anterior and posterior falxian arteries. B, C: Right internal carotid angiograms after evacuation of the hematoma showing the main blood supply from the right frontopolar artery (B) and occlusion of the superior sagittal sinus (C).

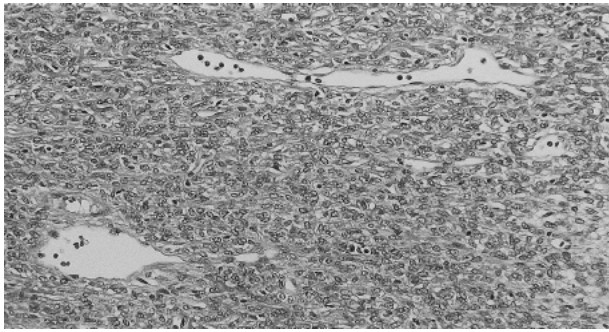


Fig. 4 Case 1. Photomicrograph showing a highly cellular and vascular tumor consisting of compact neoplastic cells and a "staghorn" vessel. Hematoxylin and eosin stain, $\times 400$.

tumor was elastic and soft, and bled easily on touch especially near the dural attachment. The hemorrhagic falx-based extra-axial mass was completely removed with the attached falx, dura, and skull. The defects of the dura and skull were repaired with pericranium and titanium mesh, respectively.

Histological examination revealed a highly cellular and vascular tumor consisting of compact neoplastic cells and a "staghorn" vessel (Fig. 4). Reticulin stain showed most of the individual cells were wrapped in reticulin with marked accentuation of the vascularity. Acute hemorrhage from the tumor was recognized near the attachment site to the dura, which was particularly abundant in dilated tumor vessels. Histologically discernible tumor invasion of the dura was not evident. Immunohistochemical staining demonstrated sporadic positive staining for vimentin in the tumor cells. Immunohistochemical staining for epithelial membrane antigen, keratin, carcinoembryonic antigen, and S-100 protein were all negative. The histological diagnosis was meningeal hemangiopericytoma.

Radiotherapy was not performed. The postoperative course was uneventful and she was discharged. Five years postoperatively, she had had no neurological deficit and was free of any evidence of local recurrence or metastasis.

Case 2: A 59-year-old man was admitted to the emergency room 40 minutes after the onset of consciousness disturbance on May 15, 2001. He had a history of hypersplenism 17 years before admission, but no history of trauma. He was not receiving anticoagulant therapy.

Neurological examination revealed a fixed, dilated right pupil and GCS score of 4/15. CT showed a 4×2.4 cm isodense lesion in the right frontotem-

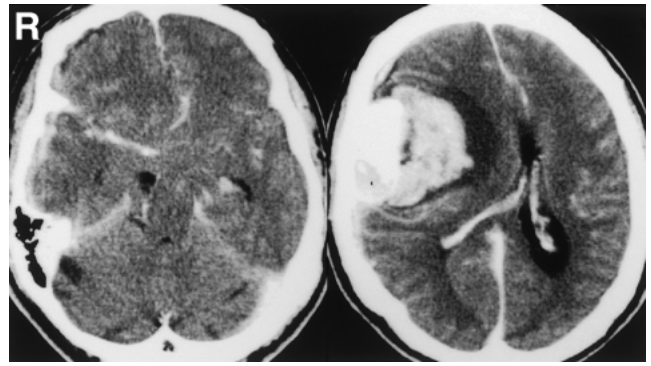


Fig. 5 Case 2. Computed tomography scans showing a 4×2.4 cm well-enhanced mass lesion in the right frontotemporal convexity region, and massive hematoma in the brain tissue at the medial border of the lesion. Subarachnoid hemorrhage and acute subdural hematoma are also recognized. Marked midline shift is seen and the basal cistern is not visible.

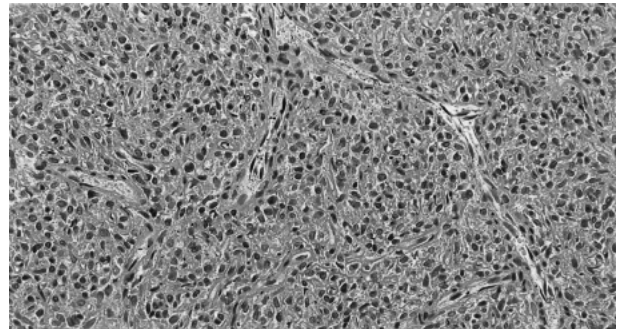


Fig. 6 Case 2. Photomicrograph showing diffuse proliferation of polygonal and spindled tumor cells with ovoid nuclei between blood vessels occasionally showing the "staghorn" shape. Hematoxylin and eosin stain, $\times 400$.

poral convexity region, which was enhanced after injection of contrast medium, and massive hematoma in the brain tissue at the medial border of the lesion. Blood collections were also present in the subdural and subarachnoid spaces. Marked midline shift was recognized and the basal cistern was not visible (Fig. 5).

Endotracheal intubation, mechanical ventilation, and rapid intravenous infusion of 800 ml mannitol were performed. Despite active intervention, the bilateral pupils became dilated and fixed. His neurological condition was refractory to any other medical treatment and the clinical diagnosis of brain

Table 1 Summary of nine cases of meningeal hemangiopericytoma manifesting as intracranial hemorrhage

Author (Year)	Age/Sex	Site of tumor	Type of hemorrhage	Treatment	Outcome
McDonald and Terry (1969) ¹⁶⁾	3 days/M	rt parietal	subdural	conservative	dead
Wyler et al. (1973) ²¹⁾	6 mos/M	lt parieto-occipital	intracerebral	removal & radiotherapy	GR
Feldman et al. (1991) ⁹⁾	34 yrs/M	lt temporoparieto-occipital	intracerebral	removal & radiotherapy	GR
Cervoni et al. (1993) ⁵⁾	55 yrs/M	rt parietal	subarachnoid	removal & radiotherapy	GR
Brunori et al. (1997) ⁴⁾	43 yrs/M	peritorcular	intratumoral*	removal & radiotherapy	SD
	22 yrs/M	lt parasagittal falx	intratumoral*	removal & radiotherapy	SD
Ajani et al. (2003) ¹⁾	28 yrs/M	rt frontal	subdural*	removal & radiotherapy	GR
Present Case 1	66 yrs/F	rt frontal parasagittal	intracerebral*	removal	GR
Present Case 2	59 yrs/M	rt frontotemporal	intracerebral*	conservative	dead

*Life-threatening massive hemorrhage. GR: good recovery, SD: severely disabled.

death was confirmed on May 22, 2001.

Autopsy was performed on May 29, 2001. The reddish tan, solid tumor originated from the right frontotemporal portion of the meninges and was associated with hemorrhage from the posterior portion of the tumor. Histological examination revealed diffuse proliferation of polygonal and spindle tumor cells with ovoid nuclei between blood vessels occasionally showing the "staghorn" shape (Fig. 6). The histological diagnosis was meningeal hemangiopericytoma. Acute hemorrhage from the tumor was identified near the attachment site to the dura, which was particularly abundant in dilated tumor vessels. No histologically discernible tumor invasion of the dura was recognized.

Discussion

Only seven cases of meningeal hemangiopericytoma associated with subarachnoid,⁵⁾ subdural,^{1,16)} intratumoral,⁴⁾ and intracerebral hemorrhage^{9,21)} have been reported (Table 1). However, some previous patients with angioblastic meningioma manifesting as intracranial hemorrhage actually might have had hemangiopericytoma.^{5,22)} The relationship of the subdural hematoma to the hemangiopericytoma is questionable in one case¹⁶⁾ as the hematoma was located beneath a fracture line and the tumor was discovered only at autopsy. Eight of the nine patients with meningeal hemangiopericytoma manifesting as intracranial hemorrhage including our patients were males and under 60 years of age. The hemorrhage was subarachnoid in one case, subdural in two cases, intratumoral in two cases, and intracerebral in four cases, but commonly presented as combinations of these types. Massive intracranial hemorrhage resulted in rapid neurologi-

cal deterioration and required emergent surgery in five cases including our cases (Table 1). Two cases of massive intratumoral hemorrhage associated with recurrent tumor with concomitant acute clinical deterioration have been reported. Both patients had received radiotherapy and weakening of malformed tumor vessels is likely in these cases.⁴⁾ Both our patients also suffered life-threatening massive intracerebral hemorrhage and one died before surgery. The other case was acute subdural and intratumoral hemorrhage from a right frontoparietal tumor causing acute clinical deterioration.¹⁾

The etiopathogenic factors involved in hemangiopericytoma and meningioma manifesting as intracranial hemorrhage include: erosion, distortion, and/or distension of the blood vessels caused by tumor growth; intense vascularity of the tumor and change in the structure of the vessel walls; and endothelial proliferation, which leads to obliteration of vessels and distal necrosis with consequent bleeding.⁵⁾ Weakening of malformed tumor vessels induced by radiotherapy may have been the cause of bleeding in some cases.⁴⁾ In both of our cases, we speculate that bleeding occurred from the dilated tumor vessels near the dural attachment, since the tumor near the dural attachment bled extremely at operation in our Case 1 and histologically apparent hemorrhage was identified there in both cases. Bleeding from a highly vascular lesion such as hemangiopericytoma may be expected, but in fact is very rare. Coagulatory changes in meningioma, induced by humoral factors, may manifest either as hemorrhagic or thromboembolic phenomena.⁵⁾ We speculate that similar coagulatory changes in hemangiopericytoma manifesting as intracranial hemorrhage may participate in the mode of onset and its rarity. Further investigation of the

pathophysiologic mechanism involved in hemangiopericytoma associated with intracranial hemorrhage is needed.

Meningeal hemangiopericytoma with intracranial hemorrhage has been treated by simultaneous evacuation of the hemorrhage and removal of the tumor.^{1,4,5,9,21} These tumors bleed profusely, and the large amount of bleeding from these tumors has caused deaths on the operating table or in the early postoperative course.¹⁰⁻¹² Preoperative radiotherapy or intratumoral embolization might be useful to reduce this profuse bleeding, but cannot be used in the emergent situation. A huge meningeal hemangiopericytoma in the suprasellar region and left middle fossa was removed successfully by using preoperative autologous transfusion and hemodilutional autologous transfusion.² Hemodilutional autologous transfusion might be useful for the surgical treatment of meningeal hemangiopericytoma with intracranial hemorrhage, because this method can be performed in the emergent situation. In our Case 1, two-staged operation was performed without complication. Namely, evacuation of the hematoma was performed initially, and the tumor was totally removed 12 days after the first operation. We suggest that this staged operation is safe and effective for meningeal hemangiopericytoma manifesting as intracranial hemorrhage.

While postoperative radiotherapy is generally recommended for meningeal hemangiopericytoma to reduce the risk of local recurrence, improve the survival rate, and delay recurrence,^{3,11,14,17,19} some authors consider that the value of postoperative radiotherapy for meningeal hemangiopericytoma is questionable, since postoperative radiotherapy did not protect against neuraxis and peripheral metastasis.^{7,8} However, stereotactic radiosurgery is indicated for recurrent tumors measuring less than 25 mm in diameter⁷ and is an excellent alternative to repeated craniotomy in recurrent disease.^{6,8} In our Case 1, postoperative radiotherapy was not performed, so we are planning to carry out stereotactic radiosurgery if careful long-term follow up identifies intracranial recurrence.

In conclusion, meningeal hemangiopericytoma manifesting as intracranial hemorrhage is quite rare, but carries the risk of life-threatening massive bleeding from the tumor.

Acknowledgments

We are grateful to Dr. K. Saito, Department of Pathology, Akita Red Cross Hospital, for special comments on the histological diagnosis.

References

- 1) Ajani OA, Ejeckam GC, Raza A: Haemangiopericytoma presenting as acute subdural haematoma. *Br J Neurosurg* 17: 559-561, 2003
- 2) Asano K, Ohkuma H, Kudo K, Takemura A, Suzuki S, Kubo O: [Successful treatment of a huge meningeal hemangiopericytoma using Preoperative Autologous Transfusion and Hemodilutional Autologous Transfusion: case report]. *No Shinkei Geka* 30: 631-637, 2002
- 3) Bastin KT, Mehta MP: Meningeal hemangiopericytoma: defining the role for radiation therapy. *J Neurooncol* 14: 277-287, 1992
- 4) Brunori A, Delitala A, Oddi G, Chiappetta F: Recent experience in the management of meningeal hemangiopericytomas. *Tumori* 83: 856-861, 1997
- 5) Cervoni L, Artico M, Salvati M, Bristot R, Wierzbicki V, Gagliardi FM: Haemangiopericytoma and meningioma presenting clinically with intracranial haemorrhage: report of three cases and review of the literature. *Zentralbl Neurochir* 54: 20-23, 1993
- 6) Chang SD, Sakamoto GT: The role of radiosurgery for hemangiopericytomas. *Neurosurg Focus* 14: e14, 2003
- 7) Dufour H, Metellus P, Fuentes S, Murracchiole X, Regis J, Figarella-Branger D, Grisoli F: Meningeal hemangiopericytoma: a retrospective study of 21 patients with special review of postoperative external radiotherapy. *Neurosurgery* 48: 756-763, 2001
- 8) Ecker RD, Marsh WR, Pollock BE, Kurtkaya-Yapicier O, McClelland R, Scheithauer BW, Buckner JC: Hemangiopericytoma in the central nervous system: treatment, pathological features, and long-term follow up in 38 patients. *J Neurosurg* 98: 1182-1187, 2003
- 9) Feldman ZT, Reichenthal E, Zucker G, Greiff M: Haemangiopericytoma presenting with intracerebral haemorrhage. Case report and review of literature. *Acta Neurochir (Wien)* 112: 151-153, 1991
- 10) Goellner JR, Laws ER Jr, Soule EH, Okazaki H: Hemangiopericytoma of the meninges. Mayo Clinic experience. *Am J Clin Pathol* 70: 375-380, 1978
- 11) Guthrie BL, Ebersold MJ, Scheithauer BW, Shaw EG: Meningeal hemangiopericytoma: histopathological features, treatment, and long-term follow-up of 44 cases. *Neurosurgery* 25: 514-522, 1989
- 12) Jaaskelainen J, Servo A, Haltia M, Wahlstrom T, Valtonen S: Intracranial hemangiopericytoma: radiology, surgery, radiotherapy, and outcome in 21 patients. *Surg Neurol* 23: 227-236, 1985
- 13) Joseph JT, Lisle DK, Jacoby LB, Paulus W, Barone R, Cohen ML, Roggendorf WH, Bruner JM, Gusella JF, Louis DN: NF2 gene analysis distinguishes hemangiopericytoma from meningioma. *Am J Pathol* 147: 1450-1455, 1995
- 14) Kim JH, Jung HW, Kim YS, Kim CJ, Hwang SK, Paek SH, Kim DG, Kwun BD: Meningeal hemangiopericytomas: long-term outcome and biological behavior. *Surg Neurol* 59: 47-53, 2003

- 15) Kleihues P, Burger PC, Scheithauer BW: The new WHO classification of brain tumours. *Brain Pathol* 3: 255-268, 1993
- 16) McDonald JV, Terry R: Hemangiopericytoma of the brain. *Neurology* 19: 497-502, 1969
- 17) Soyuer S, Chang EL, Selek U, McCutcheon IE, Maor MH: Intracranial meningeal hemangiopericytoma: the role of radiotherapy: report of 29 cases and review of the literature. *Cancer* 100: 1491-1497, 2004
- 18) Stout AP, Murray MR: Hemangiopericytoma: a vascular tumor featuring Zimmerman's pericytes. *Ann Surg* 116: 26-33, 1942
- 19) Uemura S, Kuratsu J, Hamada J, Yoshioka S, Kochi M, Ushio Y, Nakahara T, Kishida K: Effect of radiation therapy against intracranial hemangiopericytoma. *Neurol Med Chir (Tokyo)* 32: 328-332, 1992
- 20) Wakai S, Yamakawa K, Manaka S, Takakura K: Spontaneous intracranial hemorrhage caused by brain tumor: its incidence and clinical significance. *Neurosurgery* 10: 437-444, 1982
- 21) Wyler AR, Hered J, Smith JR, Loeser JD: Subarachnoid hemorrhage in infancy due to brain tumor. *Arch Neurol* 29: 447-448, 1973
- 22) Yoshioka H, Inagawa T, Katoh Y, Tokuda Y, Ohbayashi N, Shibukawa M: [A case of meningioma associated with intracerebral hemorrhage and acute deterioration]. *No Shinkei Geka* 23: 79-84, 1995 (Jpn, with Eng abstract)

Address reprint requests to: J. Maruya, M.D., Department of Neurosurgery, Akita Red Cross Hospital, 222-1 Nawashirosawa, Saruta, Kamikitate, Akita 010-1495, Japan.
e-mail: jmaruya@archosp-1998.com