

RESEARCH REPORT

RIGHT UNILATERAL JARGONAGRAFIA AS A SYMPTOM OF CALLOSAL DISCONNECTION

Nami Ihori¹, Junko Murayama², Masaru Mimura², Yumi Miyazawa³ and Mitsuru Kawamura⁴

¹Department of Rehabilitation, Kawasaki Cooperative Hospital, Kawasaki, Japan; ²Department of Psychiatry, Showa University School of Medicine, Tokyo, Japan; ³Department of Neurology, Ushioda General Hospital, Yokohama, Japan; ⁴Department of Neurology, Showa University School of Medicine, Tokyo, Japan)

ABSTRACT

We report the case of a right-handed patient who exhibited right unilateral jargonagraphia after a traumatic callosal hemorrhage. The lesions involved the entire corpus callosum, except for the lower part of the genu and the splenium. The patient's right unilateral jargonagraphia was characterized by neologisms and perseveration in kanji and kana, and was more prominent in kana than kanji. The jargonagraphia was similar to that observed in crossed aphasia, except that agraphia occurred only with the right hand. The patient also showed right unilateral tactile anomia and right tactile alexia, along with right-ear extinction on a dichotic listening test for verbal stimuli, which suggested that language function was lateralized to the right hemisphere. Since this patient had learned to write with his right hand, kinesthetic images of characters were thought to be formed and stored dominantly in the left hemisphere. We suggest that the callosal lesions disturbed the interhemispheric transfer of information for the dual-route procedures for writing in the right hemisphere, allowing the kinesthetic images of characters stored in the left hemisphere to be processed freely, resulting in the right unilateral jargonagraphia. At least two factors seem to explain that kana was more defective than kanji. First, writing in kana, which is assumed to be processed mainly via a sub-word phoneme to grapheme conversion route, might depend more strongly on lateralized linguistic processing than writing in kanji. Second, kanji, which represent meaning as well as phonology, with much more complicated graphic patterns than kana, are assumed to be processed in both hemispheres.

Key words: callosal disconnection, right-hand agraphia, jargonagraphia, kanji and kana, kinesthetic images of characters

INTRODUCTION

Callosal lesions may disturb the integration of functions in the right and left hemispheres, resulting in callosal disconnection syndrome. Unilateral agraphia, which was first described by Liepmann and Maas (1907), is one of the symptoms of callosal disconnection. Since the language center is located in the left cerebral hemisphere for most right-handed individuals, after callosal lesions the left hand may show agraphia despite normal writing ability with the right hand. Geschwind and Kaplan (1962) and Sugishita et al. (1980) suggested that due to callosal lesions, the linguistic information stored in the left hemisphere might not transfer to the motor area in the right hemisphere, resulting in left unilateral agraphia.

Higher brain functions, such as language, praxis, and visuospatial functions, are considered independent; language and praxis are lateralized to the left hemisphere and visuospatial functions to the right. Furthermore, since agraphia and apraxia do not always co-occur, writing is also assumed to be independent of praxis (Baxter and Warrington, 1986; Coslett et al., 1986). Although quite rare, callosal agraphia in patients with an anomalous pattern of cerebral lateralization has also been reported, including right-hand agraphia in left-handed individuals (Rosa et al., 1991; Tei et al., 1994), left-hand agraphia in left-handed individuals

(Gur et al., 1984; Ceccaldi et al., 1994; Zesiger et al., 1994; Lausberg et al., 1999), and right-hand agraphia in right-handed individuals (Starkstein et al., 1988; Tanaka et al., 1990). However, the characteristics and neuropsychological mechanisms for callosal agraphia in such anomalous patients have not been investigated in detail.

The Japanese language has two types of orthographic system: kanji and kana (for more details see Paradis et al., 1985). Kanji (morphograms) are used for nouns and for the root morphemes of inflected verbs, adjectives, and adverbs. They represent phonetic and semantic values, most of which have complicated graphic patterns consisting of two or more radicals. By contrast, there are two types of kana (phonograms), hiragana and katakana, and their graphic patterns are usually much simpler than those for kanji. Hiragana are used for nouns with unfamiliar kanji representations, and for function words and the inflections of verbs, adjectives and adverbs, while katakana are used for foreign loan words. Although kana are rather similar to alphabets, there is a one-to-one correspondence between the character and a syllable in kana, and the phonology of each kana does not vary according to the orthographic environment, unlike English. In cognitive psychology, written language is assumed to be processed via a dual route procedure, namely the lexical route and a sub-word grapheme to phoneme

(for reading aloud) or phoneme to grapheme (for writing) conversion procedure (Coltheart et al., 1987; Ellis, 1982; Patterson et al., 1985). In Japanese, since kanji have semantic values, they are thought to be processed mainly through a lexical route, whereas kana are assumed to depend on the sub-word route, although some familiar kana words might be processed through the lexical route (Sasanuma, 1985, 1987). Differences in deficits for kanji and kana in left unilateral agraphia have been reported in Japanese patients; notably, some patients showed more deficits for kana than kanji (e.g., Sugishita et al., 1980; Yamadori et al., 1980; Ohigashi et al., 1983), and *vice versa* (Kawamura et al., 1989).

In this study, we investigated the right unilateral agraphia observed in a right-handed patient with callosal lesions. The agraphia was more prominent in kana than in kanji, was characterized by neologisms and perseveration, and appeared to fit the definition of jargonagraphia. The patient showed reversed patterns of the normal lateralization of higher brain functions, including for language. We discuss the characteristics of the agraphia in this patient and the implications for the neuropsychological mechanisms, referring to the similarities with jargonagraphia observed in crossed aphasics.

CASE REPORT

A 27-year-old male hairdresser with 12 years of formal education was riding his motorcycle when he was struck from behind by a car, while stopped at a traffic light, in March 2001. He received emergency care in a hospital, and was then transferred and admitted to another hospital, where he was diagnosed with a callosal hemorrhage based on CT scans and Magnetic Resonance Imaging (MRI). He was in a coma for about one month, which made us suspect that he might have diffuse axonal damage. One month after his admission, he regained consciousness and his speech then gradually improved. From June 28 to August 30, 2001, we performed detailed neurological and neuropsychological evaluations.

Neurologically, the patient was fully conscious and cooperative during the examinations. He was strongly right-hand dominant, according to our handedness checklist consisting of 14 questions about manual dexterity. There was no family history of left-handedness. His major complaint was of walking disturbances due to fractures. Light reflex was sluggish for both eyes with slight anisocoria (left larger than right). Mild dysarthria was present, with weak articulation in consonants and mildly defective speech rhythm. Muscle tone was normal. On pronation-supination diadochokinesis, the right upper limb showed mild difficulty in starting the movements, and demonstrated clumsiness after starting, while no abnormalities were observed for

TABLE I
Results of the neuropsychological tests

Test	Result	
WAB	Aphasia quotient	95
WAIS-R	Verbal IQ	77
	Performance IQ	scale out
	Full scale IQ	59
WMS-R	Verbal memory	57
	Visual memory	55
	General memory	scale out
	Attention/Concentration	60
	Delayed recall	scale out
WCST	Category achieved	0

Note. WAB = Western Aphasia Battery (Kertesz, 1982), standardized for Japanese language (Sugishita, 1986); WAIS-R = Wechsler Adult Intelligence Scale-Revised; WMS-R = Wechsler Memory Scale-Revised; WCST = Wisconsin Card Sorting Test.

the left upper limb. A finger-nose test showed a mild deficit of the right arm. Deep tendon reflexes were normal on both sides. In a thumb-localizing test (Hirayama et al., 1999), the patient showed some difficulty in pinching the left thumb with the right thumb and index finger with his eyes closed, suggesting mild deficits in deep sensation related to the left upper limb. Other somatosensory functions were normal, except for transfer deficits between the right and left upper limbs, which we will describe later.

The results of the neuropsychological tests are listed in Table I. Aphasia was not apparent, since his speech was fluent with good auditory and visual comprehension, repetition, and reading aloud. Although mild anomia was present on a confrontation-naming task, his daily communication was preserved. Mental functions, including attention and memory, were generally impaired (Table I). Perseveration was prominent on the Wisconsin Card Sorting Test. His recent memory was disturbed, and he had about 1 year retrograde amnesia. His awareness of his deficits in mental functioning was impaired, so much so that he thought he would soon be able to return to his job.

Table II shows the patient's callosal disconnection symptoms. He demonstrated crossed visuomotor ataxia (Kamaki et al., 1993) with either hand. Somatosensory transfer deficits on position sense, touch localization, and hand posture were also found between the two hands (Table II), while in the ipsilateral condition (responding with the same hand), he performed well, with 80 to 100% correct. He also showed tactile anomia and tactile alexia with the right hand (Table II). Mild deficits in deep sensation related to the left upper limb may have affected some of the errors in tactile reading with the left hand. On dichotic listening tasks, using pairs of natural speech consonant-vowel syllables selected from among [pa, ta, ka, ba, da, ga], the index of laterality was $-.9$ for divided attention and -1 for focused selective attention, which shows a strong left-ear advantage (right-ear extinction) (Table II). Regarding his writing ability, the patient showed right unilateral agraphia

TABLE II
Callosal disconnection symptoms

	Right hand		Left hand	
Crossed visuomotor ataxia	+		+	
Somatosensory transfer deficits*:				
Position sense	+	(right to left, 8/14)	+	(left to right, 6/14)
Finger touch localization	+	(right to left, 8/20)	+	(left to right, 7/20)
Hand posture	+	(right to left, 3/7)	+	(left to right, 2/7)
Tactile anomia*	+	(10/26)	-	(21/26)
Tactile alexia*	+	(0/10)	-	(5/10)
Extinction of verbal stimuli	+	(right ear, 3/120 with DA)	-	(left ear, 110/120 with DA)
On dichotic listening test**	+	(right ear, 0/60 with FSA)	-	(left ear, 57/60 with FSA)
Agraphia	+		-	
Ideomotor apraxia	+		-	
Constructional disturbance	-		+	
Unilateral spatial neglect	-		+	
				(right USN)

Note. + = present; - = absent; the numbers in parentheses are the number of correct responses/total number of items; * = the tasks by Ihori et al. (2000) were used to investigate somatosensory transfer, tactile naming, and tactile reading; ** = dichotic listening test was administered in two conditions, with divided attention (DA) and with focused selective attention (FSA) (Sugishita et al., 1995).

(Figures 1, 2). Figure 1 shows the patient's written version of serial digits from 1 to 20. Although the left hand wrote them correctly (B), the right hand wrote jargon made up of irrelevant kana and kanji (A, C). Figure 2 shows samples of dictated words and a sentence written by the patient. The right hand showed neologistic jargonagraphia in kanji and kana with perseveration, while the left hand wrote correct, but distorted, characters. Spontaneous writing demonstrated the same features as dictation.

In terms of praxis, the patient showed right unilateral ideomotor apraxia. When asked to perform actions such as a salute, or to pantomime the use of common objects (toothbrush, comb, hammer, saw, key), the right hand showed amorphous responses, perseveration, and errors of direction or position. Performance was better for imitation than for verbal command, although some clumsiness was observed. The left hand performed the actions correctly, both in response to verbal command and for imitation. In copying figures, the patient performed well with the right hand, but showed prominent clumsiness and right Unilateral Spatial Neglect (USN) with the left (Figure 3). In

the line bisection task, he also showed mild right USN with the left hand. In copying a list of words with the left hand, the patient omitted words that were in the right upper corner of the paper, as well as occasionally omitting strokes on the right-hand side of kanji. A staff member who cared for the patient in the hospital reported that he did not wash the right side of his body with his left hand while taking a bath. When he was asked to read sentences written horizontally aloud, he neglected some words on the right-hand side of the paper.

NEURORADIOLOGICAL FINDINGS

For anatomical localization of the lesion, MRI was performed with a Hitachi .3 Tesla superconducting MR imager in September 2001 (six months after the accident). The width of each slice was 10 mm and the patient's head was positioned supine. Midsagittal images (Figure 4) showed a lack of normal intensity in the entire corpus callosum, except for the lower part of the genu and the splenium. No focal lesions were found in the left or right cerebral hemispheres on MRI.

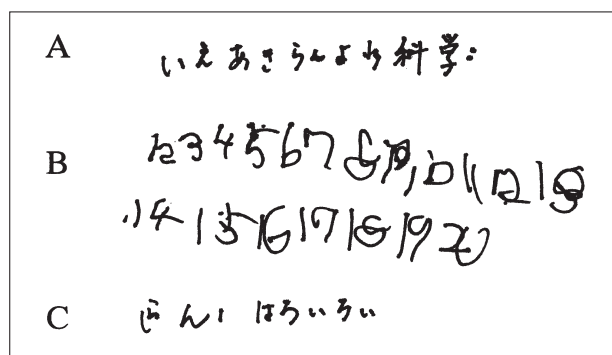


Fig. 1 - Writing a series of numerals with the left (B) and right (A, C) hands. First, the patient wrote them with the right hand (A); hiragana and kanji (10 characters) appeared instead of numerals, creating jargon. Then he was asked to write them with the left hand and he wrote them correctly (B). Although he tried again with the right hand, hiragana appeared and he stopped writing (C).

INVESTIGATION OF AGRAPHIA METHODS AND RESULTS

To investigate the characteristics of writing with the left and right hands, dictation, copying, and anagram tasks were administered, as described below. Sixteen stimuli words were used in the dictation and copying tasks (see Appendix). Each word can be represented by one or two kanji (26 in total), and by one to four hiragana (46 in total). The words were divided into two groups, A and B, for presentation purposes. Errors were analyzed at the word and character levels (Table III). To determine how much his writing might depend upon visual feedback, dictation tasks were

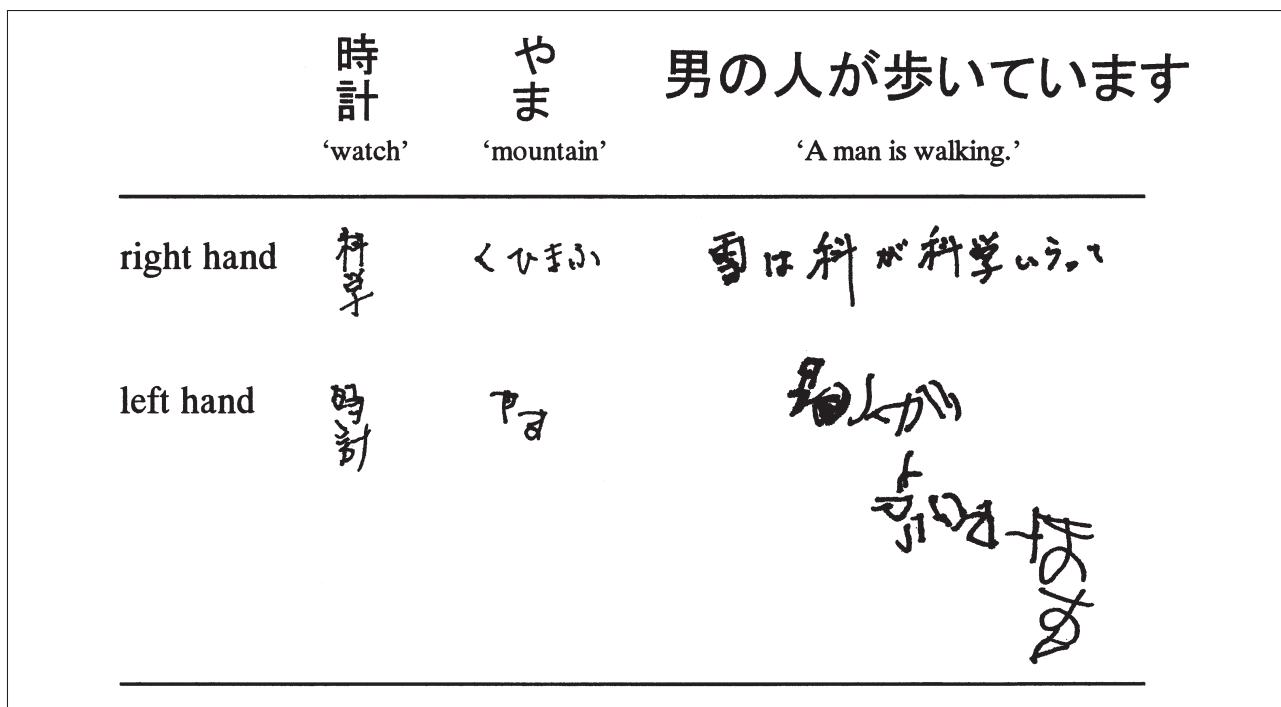


Fig. 2 – Dictation of words and a sentence.

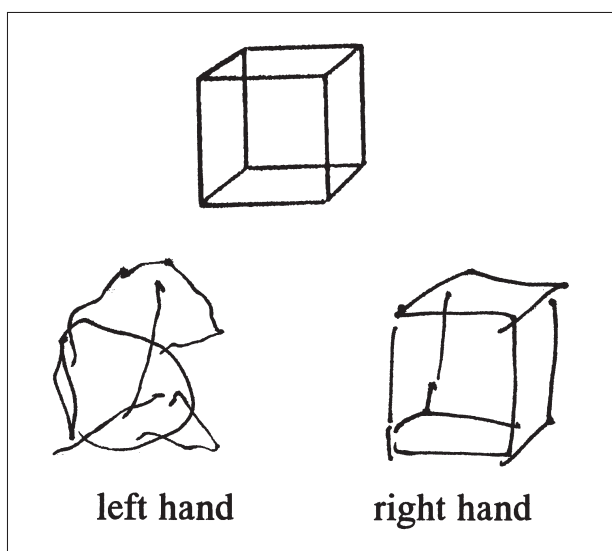


Fig. 3 – Samples of copying a cube with the left and right hands.

administered both in eyes-open and eyes-closed conditions. Anagram tasks were given to determine whether the selection of characters corresponding to target words was impaired. Dictation tasks were administered to five normal controls (17 to 54 years old, 30 for mean), who were matched for educational level (12.6 years \pm 1.95).

Dictation of Kanji Words (Eyes Open)

The patient was asked to write down 16 orally presented words in kanji (see Appendix), with a time limit of 30 seconds for each word. The words were presented in the following order: right-hand

group A, left-hand group B, left-hand group A, and right-hand group B.

The number of correct words was 11 (68.8%) for the left hand and 9 (56.3%) for the right (Table III). There were no instances of non-response. For the left hand, all the errors involved some change in the graphic pattern of the target kanji, suggesting that retrieval of the target kanji itself was largely preserved. There was one substitution with a kanji of similar form, and four distortions, two of which were the omission of a right-side stroke (Figure 5a). By contrast, the right hand produced six neologisms consisting of kanji (Figure 5b). In addition, there were eight substitutions, two of which involved substitution with phonologically related kanji. The remainder of the substitutions involved substitution with unrelated kanji that were not similar to the targets in shape, meaning, or pronunciation. The right hand also showed a neographeme made by substitution of the radical, and three instances of perseveration of characters or radicals. The order of the strokes and the speed of writing with the right hand were preserved. The mean performance of normal controls was 100% correct for the right hand and 98.8% for the left.

Dictation of Hiragana Words (Eyes Open)

The patient was asked to write down 16 orally presented words in hiragana (see Appendix), within an allotted time of 30 seconds for each word. The order of administration of the words was left-hand group A, right-hand group B, right-hand group A, and left-hand group B.

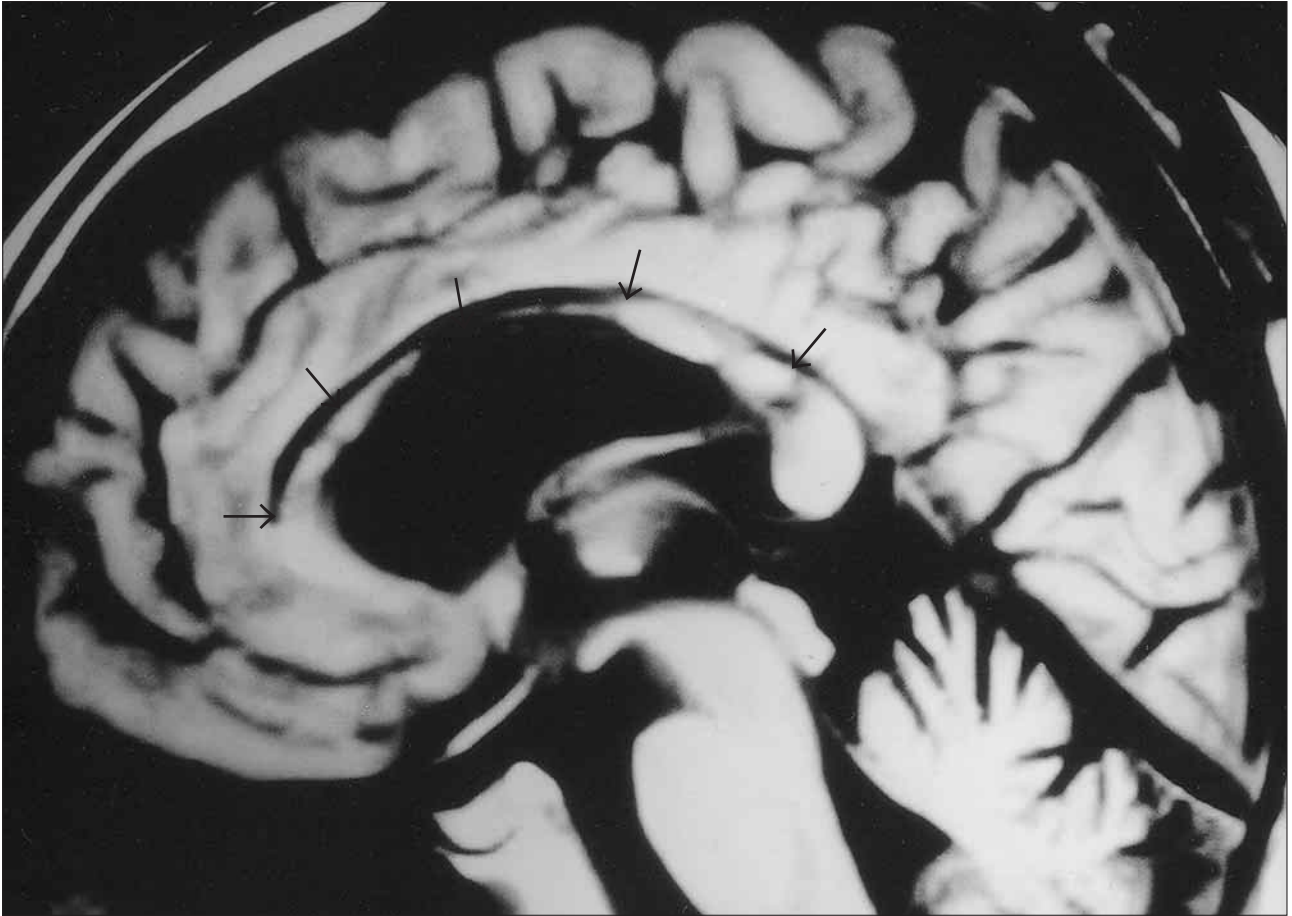


Fig. 4 – Magnetic resonance imaging six months after the accident, midsagittal view [Time of Repetition (TR) = 500 msec, Time of Echo (TE) = 20 msec]. A distinct, low-intensity area is evident (arrows) in the entire corpus callosum, except for the lower part of the genu and the splenium.

The number of correct words was 16 (100%) for the left hand, compared to 1 (6.3%) for the right (Table III). The right hand substituted other hiragana or groups of hiragana for 23 out of 46 target characters, producing seven neologisms and five literal paraphasia. There were eight erroneous words that contained more characters than the targets (Figure 5c). Nine hiragana (four kinds) were

perseverated. There were two neographemes made by the omission or addition of a stroke (Figure 5d). Although the order of strokes and penmanship with the right hand were well preserved, the patient complained that the characters that he put down differed from those that he intended to write. The mean performance of normal controls was 100% correct for either hand.

TABLE III
Writing performance and error analysis

	Dictation (eyes open)				Dictation (eyes closed)				Copy			
	Kanji		Kana		Kanji		Kana		Kanji		Kana	
	L	R	L	R	L	R	L	R	L	R	L	R
Correct words*	11	9	16	1	11	7	14	3	15	16	16	12
Errors												
Neologism	0	6	0	7	0	4	0	8	0	0	0	0
Verbal paraphasia	0	0	0	1	0	0	0	2	0	0	0	1
Literal paraphasia	0	0	0	5	0	0	0	3	0	0	0	3
Correct characters**	21	14	46	12	21	15	44	15	25	26	46	41
Errors												
Neographeme	0	1	0	2	0	5	0	5	0	0	0	0
Substitution	1	8	0	23	0	3	0	21	0	0	0	4
Distortion	4	0	0	0	5	0	2	0	1	0	0	0
Perseveration	0	3	0	9	0	3	0	5	0	0	0	1

Note. L = left hand; R = right hand; * = total number of target words is 16; ** = total number of target characters are 26 for kanji and 46 for kana.

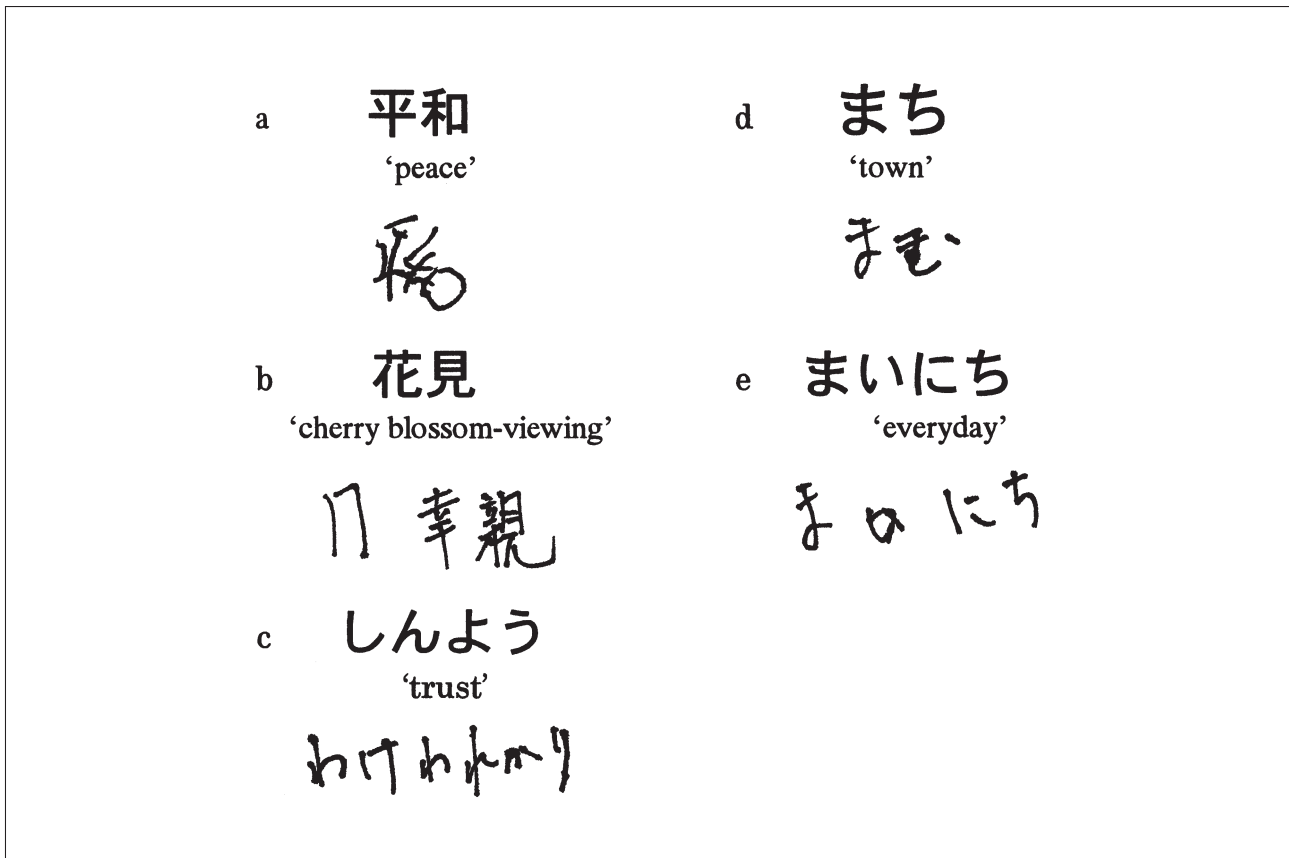


Fig. 5 – Writing and copying samples with eyes open.

a: Left hand dictation of a kanji word. The radical on the right-hand side of 平 was omitted.

b: Right hand dictation of a kanji word. A neologism was produced by substituting a character (花 → 幸) and adding a radical 親 to the target 見.

c: Right hand dictation of a hiragana word. A neologism was produced that had more characters than the target.

d: Right hand dictation of a hiragana word. A non-existent character was produced by adding a radical to an existent hiragana, む.

e: Right hand copying. After writing, まつ, the patient noticed the error, つ and made a self-correction by writing い over つ.

Dictation of Kanji Words (Eyes Closed)

The procedure was similar to the procedure described above for the dictation of kanji in the eyes-open condition (1), except that the patient wore a blindfold. The number of correct words was 11 (68.8%) for the left hand and 7 (43.8%) for the right hand (Table III), which was almost the same as in the eyes-open condition. Five erroneous responses were made with the left hand, all of which involved distortion of the target character, including the omission or addition of a stroke, suggesting that retrieval of the target characters was preserved. By contrast, the right hand produced three substitutions of other kanji that were not similar to the targets in shape, meaning, or pronunciation, resulting in three neologisms. There was also a neologism consisting of only hiragana. In addition, five neographemes were made by omitting a stroke or combining irrelevant radicals or parts of a radical. The character or radical was perseverated in three responses. The mean performance of normal controls was 98.8% correct for the right hand and 100% correct for the left.

Dictation of Hiragana Words (Eyes Closed)

The procedure was similar to the procedure described above for the dictation of hiragana words in the eyes-open condition (2), except the patient wore a blindfold. The number of correct words was 14 (87.5%) for the left hand and 3 (18.8%) for the right hand (Table III), which was almost the same as in the eyes-open condition. For the left hand, there were two distortions: in one instance a stroke of the target hiragana was omitted, and in the other, the shape of the target hiragana was distorted markedly. These errors indicate that the retrieval of the target character itself was probably reasonably well preserved. However, the right hand substituted other hiragana or groups of hiragana for 21 out of 46 target hiragana, resulting in seven neologisms, three literal paraphasia, and two verbal paraphasia. One neologism consisted of irrelevant kanji and katakana. There were two responses with more characters than target words. Five neographemes were produced, and five hiragana (three kinds) were perseverated. The mean performance of normal controls was 100% correct for the right hand and 98.8% for the left.

Copying Kanji and Hiragana Words

The patient was asked to copy the same words that were used in the dictation. The order of administration was the same as for tasks 1 and 2. The number of words written correctly was 15 (93.8%) with the left hand and 16 (100%) with the right for kanji, and 16 (100%) with the left hand and 12 (75%) with the right for hiragana (Table III). In kanji, the left hand error was a distortion made by omitting a stroke. In hiragana, the right hand errors were substitutions with characters that had similar shapes. In 4 out of 16 words, the patient self-corrected the errors soon after noticing that he was writing a different hiragana (Figure 5e).

Anagram Letters

The stimuli were ten words consisting of three hiragana, and ten different words consisting of three kanji. For each trial, ten cards were placed on a table, with one character printed on each card. After being given an auditory stimulus, the patient was asked to choose and arrange the characters to construct the stimulus word. The order of administration was ten hiragana words with the right hand, ten kanji words with the left hand, ten hiragana words with the left hand, and ten kanji with the right hand. Responses were 100% correct in both tasks, for both hands, and there were no differences in response times for the two hands, which suggests that selection of characters corresponding to target words was preserved for either hand.

DISCUSSION

The patient manifested right unilateral agraphia with various callosal disconnection symptoms following a traumatic callosal hemorrhage. The characteristics of his right-hand agraphia were neologistic paraphasia with perseveration, produced by substituting irrelevant characters for targets in both kanji and kana; the sentences became neologistic jargon with prominent perseveration. These features fit the definition of jargonagraphia (Lecours and Rouillon, 1976). Since his penmanship, including the order of strokes with the right hand, was preserved, with no distortion of the graphic patterns of the characters, and copying characters was performed well, the patient's right-hand agraphia cannot be explained by motor disturbances, such as ideomotor apraxia. Furthermore, since aphasia was absent and writing performance was much better with the left hand than with the right, especially in writing kana, our observations cannot be explained by aphasia, a decline of intelligence, or attentional disorders. Therefore, the right-hand agraphia in this patient was likely a result of his callosal disconnection.

The patient manifested several characteristics that are typically observed in the opposite side of the body in patients with callosal disconnection symptoms. He showed tactile anomia with the right hand, which is generally observed with the left in patients with callosal lesions. He also demonstrated unilateral somesthetic alexia with the right hand. Unilateral somesthetic alexia is also thought to be a callosal disconnection symptom, and is typically observed with the left hand (Trescher and Ford, 1937; Geschwind and Kaplan, 1962; Ihori et al., 2000). In addition, we observed complete right-ear extinction in the dichotic listening test for verbal stimuli. Combined, these atypical symptoms strongly suggest that for this patient, language function was lateralized in the right cerebral hemisphere. Furthermore, this patient showed unilateral ideomotor apraxia with the right hand, although this is typically observed with the left hand after callosal damage. Although skilled movements are usually assumed to be lateralized in the hemisphere contralateral to the dominant hand, some right-handed patients whose praxis appeared to be lateralized in the right hemisphere (crossed apraxia) have been reported (Marchetti and Della Sala, 1997; Raymer et al., 1999). Our patient also showed a tendency to constructional disturbances and unilateral spatial neglect with the left hand, although both have been generally observed with the right hand (Bogen, 1969; Kashiwagi et al., 1990; Kamaki et al., 1993). These findings imply that praxis and visuospatial function also had lateralized anomalously (Figure 6).

In right-handed patients with the typical pattern of cerebral lateralization, two types of callosal agraphia of the left hand have been reported: apraxic agraphia, in which scrawls are prominent (Sweet, 1941; Watson and Heilman, 1983; Degos et al., 1987; Case 1 in Leiguarda et al., 1989), and agraphia in which paraphasia and neographemes with perseveration predominate (Geschwind and Kaplan, 1962; Sugishita et al., 1980; Yamadori et al., 1980). Since left unilateral apraxic agraphia is often accompanied by left ideomotor apraxia (Sweet, 1941; Watson and Heilman, 1983; Case 1 in Leiguarda et al., 1989), the severity of apraxia may affect the appearance of apraxic agraphia of the left hand. In addition, Watson and Heilman (1983) suggested a relationship between the type of agraphia and the site of callosal lesions. Furthermore, the degree to which kinesthetic images of characters (graphic motor patterns) are formed and stored in the non-dominant hemisphere may affect the features of callosal agraphia. This occurs because when callosal agraphia appears in the hand that is dominant for writing, i.e., left-hand agraphia in a left-handed patient (Gur et al., 1984; Zesiger et al., 1994; Ceccaldi et al., 1994), and right-hand agraphia in a right-handed patient (Starkstein et al., 1988; Tanaka et al., 1990), including our patient, the agraphia is characterized

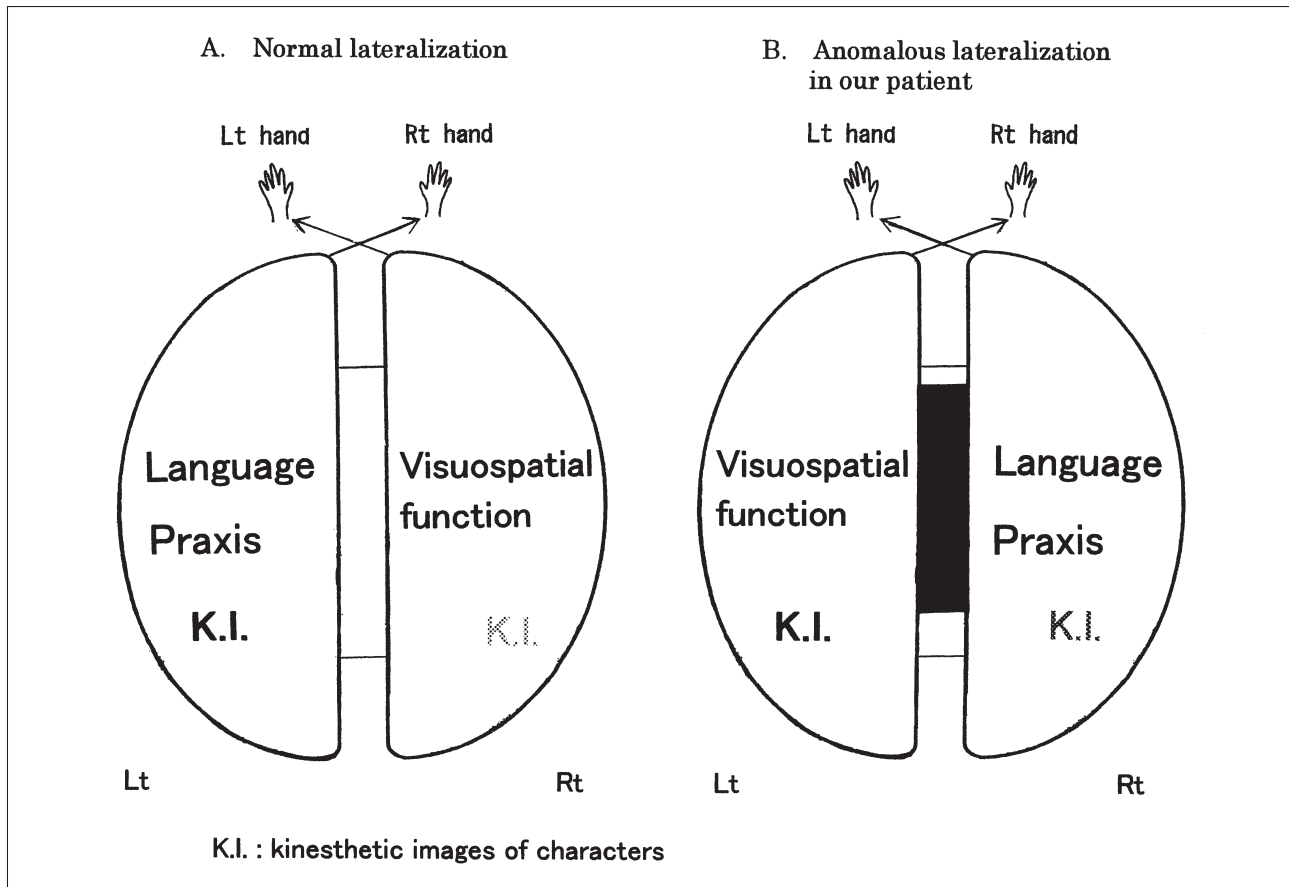


Fig. 6 – Schematic representation of the mechanism for our patient's right unilateral jargonagraphia. In contrast to normal lateralization, in our patient language and praxis were thought to be lateralized in the right hemisphere, while visuospatial functions were lateralized in the left. Kinesthetic images of characters assumed to be stored in the left hemisphere might have been processed without linguistic information from the right hemisphere, due to callosal lesions, resulting in jargonagraphia with the right hand.

mainly by neologistic paraphagia, not by apraxic agraphia, regardless of the lesion site or the presence of apraxia in the hand with agraphia. In these patients, kinesthetic images of characters formed in the hemisphere that governs the dominant hand seem to be almost complete; this may be why they do not show apraxic agraphia, but neologistic paraphagia instead.

The characteristics of the callosal right unilateral agraphia in right-handed patients (Starkstein et al., 1988; Leiguarda et al., 1989; Tanaka et al., 1990), including our case, resemble the jargonagraphia that is observed in an anomalous type of crossed aphasia, except that the agraphia occurred only with the right hand. Starkstein et al. (1988) and Leiguarda et al. (1989) reported on the same case, who showed jargonagraphia with perseveration, omission, transposition, and letter inversion in dictation and copying characters with the right hand after hemorrhage involving the entire corpus callosum. Tanaka et al. (1990) reported a right-handed patient who demonstrated neologistic paraphagia with perseveration in both kanji and kana that was evident only with the right hand after damage to the anterior two thirds of the corpus callosum and medial parts in both hemispheres. Starkstein et al. (1988), Leiguarda et al. (1989) and Tanaka et al. (1990) suggested that

their patients might have language dominance in the right hemisphere. Ihori et al. (1994) reviewed crossed aphasics with jargonagraphia, pointing out that jargonagraphia in crossed aphasia is also characterized by neologism and perseveration. Since writing is thought to be generally learned with the right hand in right-handed people, kinesthetic images of characters are thought to be dominantly formed and stored in the left hemisphere. In crossed aphasics, since the language center is thought to be located in the right hemisphere, the graphemic information retrieved after the lexical or sub-word procedure for writing is assumed to be transferred from the right hemisphere to the left via the corpus callosum, and to be matched to the kinesthetic images of characters stored in the left hemisphere where writing movements with the right hand might be programmed and achieved based on the kinesthetic images of characters (Ellis, 1982; Patterson, 1986; Roeltgen, 1993). Ihori et al. (1994) suggested that in crossed aphasia, kinesthetic images of characters in the left hemisphere might "freely-run" (be processed freely) under the condition that the linguistic processes and dual-route procedures for writing are disturbed by the right hemisphere damage, resulting in jargonagraphia. In the patients described in Starkstein et al. (1988), Leiguarda et al.

(1989) and Tanaka et al. (1990), as well as in our patient, the kinesthetic images of characters might have been processed freely under the condition that the information of the dual-route procedures for writing in the right hemisphere could not be transferred to the left due to callosal disconnection, resulting in right unilateral jargonagraphia. Our patient's introspective comments about characters emerging that differed from his intention might reflect unrestricted processing of the kinesthetic images of characters. Figure 6 shows a schematic representation of the lateralization of higher-brain functions and the mechanisms for the right unilateral agraphia in our patient. Since little difference in writing was evident between the eyes-open and eyes-closed conditions with either hand, and the order of strokes with the left hand was essentially preserved, the right hemisphere in our patient might also contain kinesthetic images of characters to a high degree. Regarding the jargonagraphia in kanji observed in crossed aphasia, Ihori et al. (1994) suggested that neologisms consisting of irrelevant kanji were produced by "free-running on" (unrestricted processing) of the visual and kinesthetic images of kanji without linguistic information, and that neographemes in kanji might result from "free-running on" of the radical or a part of the radical of the kanji. A similar hypothesis can be applied to neologisms and neographemes in kanji observed in right-handed writing by the patients in Tanaka et al. (1990) and this study.

Our patient showed paragraphia with the right hand more prominently in kana than in kanji, regardless of whether his eyes were open. Writing words in kana is assumed to be processed mainly at a sub-word level by phoneme-to-grapheme conversion, which depends heavily on lateralized linguistic processing (usually in the left hemisphere, but in the right in our patient) (Sasanuma, 1985, 1987). Furthermore, since kana are simple in shape, they may be more likely to be associated with kinesthetic images than visual images (Iwata, 1986). Therefore, kinesthetic images of kana are thought to easily "freely-run" under callosal disconnection without the availability of information on the sub-word route for writing from the dominant hemisphere. Conversely, writing in kanji is assumed to be processed mainly via the lexical route (Sasanuma, 1985, 1987). Studies of deep dyslexia suggest that the lexical route for written language functions in the non-dominant hemisphere as well as in the dominant hemisphere (Coltheart et al., 1987; Coltheart, 2000). Yamadori et al. (1983) also suggested that the non-dominant hemisphere has some ability to process the meaning of words. In addition, since kanji have much more complicated graphic patterns than kana, writing in kanji is thought to depend strongly on visual images (Iwata, 1986), which may prevent unrestricted writing in kanji. These factors may contribute to an explanation of why paragraphia occurs less often

with kanji than with kana in callosal agraphia (e.g., Sugishita et al., 1980; Yamadori et al., 1980; Ohigashi et al., 1983), including our patient. Kawamura et al. (1989) reported a rare case of an individual who showed left hand agraphia only with kanji after posterior damage in the trunk of the corpus callosum. The existence of such a case suggests that kanji and kana cross in different regions of the corpus callosum, or that individual differences exist in the way orthographic information is represented in the two hemispheres.

Our patient produced distortions (peripheral errors) in writing with the left hand, especially for kanji. When we observed his penmanship, it seemed clear that he could retrieve the target grapheme. Since writing kanji is thought to require visuo-constructional ability because of their graphic complexity (Iwata, 1984, 1986; Ihori et al., 1994), our patient's constructional disturbance or his tendency for right unilateral neglect with the left hand may have affected the distortion of kanji, including the omission of strokes on the right-hand side. In addition, since writing with the non-dominant hand might increase cognitive loads, for example, by requiring closer attention or greater effort than writing with the dominant hand, the patient's attentional deficits might have affected the distortion produced when writing with the left hand. Furthermore, since writing was learned with the right hand, kinesthetic images of characters are suspected to have been formed less completely in the right hemisphere than in the left.

Acknowledgments. We thank Dr. Tsuneo Nakamura of the Saiseikai Kanagawaken Hospital for introducing us to the patient and giving us the opportunity to investigate the patient's callosal syndrome. Parts of this study were presented at the 25th Annual Meeting of the Aphasia Association of Japan, held in Osaka, in December 2001.

REFERENCES

- BAXTER DM and WARRINGTON EK. Ideational agraphia: A single case study. *Journal of Neurology, Neurosurgery, and Psychiatry*, 49: 369-374, 1986.
- BOGEN JE. The other side of the brain I: Dysgraphia and dyscopia following cerebral commissurotomy. *Bulletin of the Los Angeles Neurological Societies*, 34: 73-105, 1969.
- CECCALDI M, ROYÈRE ML, DANOY MC and PONCET M. Syndrome de Déconnexion Interhémisphérique Post-Traumatique. *Revue Neurologique*, 150: 229-232, 1994.
- COLTHEART M. Deep dyslexia is right-hemisphere reading. *Brain and Language*, 71: 299-309, 2000.
- COLTHEART M, PATTERSON K and MARSHALL JC. *Deep Dyslexia* (2nd ed.). London and New York: Routledge & Kegan Paul, 1987.
- COSLETT HB, ROTH LJG, VALENSTEIN E and HEILMAN KM. Dissociations of writing and praxis: Two cases in point. *Brain and Language*, 28: 357-369, 1986.
- DEGOS JD, GRAY F, LOUARN F, ANSQUER JC, POIRIER J and BARBIZET J. Posterior callosal infarction: Clinicopathological correlations. *Brain*, 110: 1155-1171, 1987.
- ELLIS AW. Spelling and writing (and reading and speaking). In Ellis AW (Ed), *Normality and Pathology in Cognitive Functions*. New York: Academic Press, 1982.
- GESCHWIND N and KAPLAN E. A human cerebral disconnection syndrome: A preliminary report. *Neurology*, 12: 675-685, 1962.
- GUR RE, GUR RC, SUSSMAN NM, O'CONNOR MJ and VEY MM. Hemispheric control of the writing hand: The effect of callosotomy in a left-hander. *Neurology*, 34: 904-908, 1984.

- HIRAYAMA K, FUKUTAKE T and KAWAMURA M. 'Thumb localizing test' for detecting a lesion in the posterior column-medial lemniscal system. *Journal of Neurological Sciences*, 167: 45-49, 1999.
- IHORI N, KASHIWAGI T, KASHIWAGI A and TANABE H. Jargonagraphia in kanji and kana in a Japanese crossed Wernicke's aphasic. *Brain and Language*, 47: 197-213, 1994.
- IHORI N, KAWAMURA M, FUKUZAWA K and KAMAKI M. Somesthetic disconnection syndromes in patients with callosal lesions. *European Neurology*, 44: 65-71, 2000.
- IWATA M. Kanji versus kana: Neuropsychological correlates of the Japanese writing system. *Trends in Neurosciences*, 7: 290-293, 1984.
- IWATA M. Neural mechanism of reading and writing in the Japanese language. *Functional Neurology*, 1: 43-52, 1986.
- KAMAKI M, KAWAMURA M, MORIYA H and HIRAYAMA K. "Crossed homonymous hemianopia" and "crossed left hemispacial neglect" in a case of Marchiafava-Bignami disease. *Journal of Neurology, Neurosurgery, and Psychiatry*, 56: 1027-1032, 1993.
- KASHIWAGI A, KASHIWAGI T, NISHIKAWA T, TANABE H and OKUDA J. Hemispacial neglect in a patient with callosal infarction. *Brain*, 113: 1005-1023, 1990.
- KAWAMURA M, HIRAYAMA K and YAMAMOTO H. Different interhemispheric transfer of kanji and kana writing evidenced by a case with left unilateral agraphia without apraxia. *Brain*, 112: 1011-1018, 1989.
- KERTESZ A. *The Western Aphasia Battery*. New York: Grune & Stratton, 1982.
- LAUSBERG H, GÖTTERT R, MÜNGBINGER U, BOEGNER F and MARX P. Callosal disconnection syndrome in a left-handed patient due to infarction of the total length of the corpus callosum. *Neuropsychologia*, 37: 253-265, 1999.
- LECOURS AR and ROUILLON F. Neurolinguistic analysis of jargonaphasia and jargonagraphia. In Whitaker HA (Ed), *Studies in Neurolinguistics*. New York: Academic Press, 1976.
- LEIGUARDA R, STARKSTEIN S and BERTHIER M. Anterior callosal haemorrhage: A partial interhemispheric disconnection syndrome. *Brain*, 112: 1019-1037, 1989.
- LIEPMANN H and MAAS O. Fall von linksseitiger Agraphie und Apraxie bei rechtsseitiger Lahmung. *Journal für Psychologie und Neurologie*, 10: 214-227, 1907.
- MARCHETTI C and DELLA SALA S. On crossed apraxia: Description of a right-handed apraxic patient with right supplementary motor area damage. *Cortex*, 33: 341-354, 1997.
- OHIGASHI Y, HAMANAKA Y, ASANO K and MORIMUNE S. Left unilateral agraphia: Its characteristics and dynamics. *No to Shinkei*, 35: 1065-1072, 1983 (in Japanese).
- PARADIS M, HAGIWARA H and HILDEBRANDT N. *Neurolinguistic Aspects of the Japanese Writing System*. Tokyo: Academic Press, 1985.
- PATTERSON KE, MARSHALL JC and COLTHEART M. *Surface Dyslexia: Neuropsychological and Cognitive Studies of Phonological Reading*. London: Lawrence Erlbaum Associates, Publishers, 1985.
- PATTERSON KE. Lexical but nonsemantic spelling? *Cognitive Neuropsychology*, 3: 341-367, 1986.
- RAYMER AM, MERIANS AS, ADAIR JC, SCHWARTZ RL, WILLIAMSON DJG, ROTH L, POIZNER H and HEILMAN KM. Crossed apraxia: Implications for handedness. *Cortex*, 35: 183-199, 1999.
- ROELTGEN DP. Agraphia. In Heilman KM and Valenstein E (Eds), *Clinical Neuropsychology* (3rd ed.). Oxford: Oxford University Press, 1993.
- ROSA A, DEMIATI M, CARTZ L and MIZON JP. Marchiafava-Bignami disease, syndrome of interhemispheric disconnection, and right-handed agraphia in a left-hander. *Archives of Neurology*, 48: 986-988, 1991.
- SASANUMA S. Surface dyslexia and dysgraphia: How are they manifested in Japanese? In Patterson KE, Marshall JC, and Coltheart M (Eds), *Surface Dyslexia, Neuropsychological and Cognitive Studies of Phonological Reading*. London: Lawrence Erlbaum Associates Publishers, 1985.
- SASANUMA S. Acquired dyslexia in Japanese: Clinical features and underlying mechanisms. In Coltheart M, Patterson K and Marshall JC (Eds), *Deep Dyslexia*. London and New York: Routledge & Kegan Paul, 1987.
- STARKSTEIN SE, BERTHIER ML and LEIGUARDA R. Disconnection syndrome in a right-handed patient with right hemispheric speech dominance. *European Neurology*, 28: 187-190, 1988.
- SUGISHITA M. *The Japanese Edition of the Western Aphasia Battery*. Tokyo: Igaku-Shoin, 1986.
- SUGISHITA M, OTOMO K, YAMAZAKI K, SHIMIZU H, YOSHIOKA M and SHINOHARA A. Dichotic listening in patients with partial section of the corpus callosum. *Brain*, 118: 417-427, 1995.
- SUGISHITA M, TOYOKURA Y, YOSHIOKA M and YAMADA R. Unilateral agraphia after section of the posterior half of the truncus of the corpus callosum. *Brain and Language*, 9: 215-225, 1980.
- SWEET WH. Seeping intracranial aneurysm simulating neoplasm: Syndrome of the corpus callosum. *Archives of Neurology and Psychiatry*, 45: 86-104, 1941.
- TANAKA Y, IWASA H and OBAYASHI T. Right hand agraphia and left hand apraxia following callosal damage in a right-hander. *Cortex*, 26: 665-671, 1990.
- TEI H, SOMA Y and MARUYAMA S. Right unilateral agraphia following callosal infarction in a left-hander. *European Neurology*, 34: 168-172, 1994.
- TRESCHER JH and FORD FR. Colloid cyst of the third ventricle: Report of a case; operative removal with section of posterior half of corpus callosum. *Archives of Neurology and Psychiatry*, 37: 959-973, 1937.
- WATSON RT and HEILMAN KM. Callosal apraxia. *Brain*, 106: 391-403, 1983.
- YAMADORI A, NAGASHIMA T and TAMAKI N. Ideogram writing in a disconnection syndrome. *Brain and Language*, 19: 346-356, 1983.
- YAMADORI A, OSUMI Y, IKEDA H and KANAZAWA Y. Left unilateral agraphia and tactile anomia: Disturbances seen after occlusion of the anterior cerebral artery. *Archives of Neurology*, 37: 88-91, 1980.
- ZESIGER P, PEGNA A, and RILLIET B. Unilateral dysgraphia of the dominant hand in a left-hander: A disruption of graphic motor pattern selection. *Cortex*, 30: 673-683, 1994.

Nami Ihori, Department of Rehabilitation, Kawasaki Cooperative Hospital, 2-1-5, Sakuramoto, Kawasaki-ku, Kawasaki 210-0833, Japan.
e-mail: ihorinami@aol.com

(Received 25 June 2003; reviewed 11 September 2003; revised 29 January 2004; accepted 6 April 2004; Action Editor Ria De Bleser)

APPENDIX

	Group A		Group B	
	Kanji	Kana	Kanji	Kana
Winter	冬	ふゆ	Beans	豆 まめ /mame/
Society	社会	しゃかい	Name	名前 なまえ /namae/
Trust	信用	しんよう	Everyday	毎日 まいにち /mainichi/
Eye	目(眼)	め	Town	町 まち /machi/
Bamboo	竹	たけ	Peace	平和 へいわ /heiwa/
Schedule	予定	よてい	Mountain stream	谷川 たにがわ /tanigawa/
Evening	夕方	ゆうがた	Meat	肉 にく /niku/
Cherry blossom-viewing	花見	はなみ	Goods	品物 しなもの /shinamono/