

Neoplasm

An unusual case of tumor-to-cavernoma metastasis. A case report and literature review

Chow H. Patrick Chan, MBBS^a, Gavin C.A. Fabinyi, MBBS, FRACS^{a,*},
Renate M. Kalnins, MBBS, FRCPA^b

Departments of ^aNeurosurgery and ^bAnatomical Pathology, University of Melbourne, Austin Health, Heidelberg 3084, Victoria, Australia

Received 10 December 2004; accepted 6 June 2005

Abstract

Background: Metastases of systemic neoplasia to preexisting intracranial mass lesions are uncommon phenomena. Tumor-to-intracranial cavernoma metastases are even more unusual and rarely reported. We describe here a case of melanoma to intracranial cavernoma metastasis.

Case Description: A 39-year-old woman presented after an episode of generalized tonic-clonic seizure on a background of infrequent epilepsy. She was found to have a left parieto-occipital hemorrhagic lesion on imaging studies. The lesion was surgically removed and histopathology showed a metastatic melanoma within a cavernoma.

Conclusion: This case report represents the third recorded case of tumor-to-intracranial cavernoma metastasis and the first melanoma to intracranial cavernoma metastasis. An extensive literature review of tumor-to-intracranial tumor metastases was conducted and disclosed an increase in reporting of the uncommon phenomenon of metastasis into preexisting intracranial lesions. It should therefore be considered as a differential diagnosis in patients with history of systemic cancer who present with progression of preexistent intracranial lesions.

© 2006 Elsevier Inc. All rights reserved.

Keywords:

Brain metastasis; Melanoma; Cavernoma; Tumor-to-tumor metastasis

1. Background

Metastases of systemic cancers to preexisting mass lesions, although infrequent, have been reported. It is even rarer for systemic cancers to metastasize to intracranial lesions. The reported intracranial cases usually involve meningioma as the host tumor bed [2-4,6-10,12,16,17, 19-22, 24,27-32,36-38,40,41,43,45,46,50-53,56,58-60,69, 72,73,79,81,83,86,87,90,93,97,98,100,101,103-105,107, 110-112]. Rarely, metastases to vestibular schwannoma [21, 57,84,99,102,106], pituitary adenoma [1,13,18,47,48,54, 62,68,75-77,82,95,96,109], glioma [33,35,50,61,63,65,74, 88-91,108], cerebellar hemangioblastoma [14,26,39,49,64],

central neurocytoma [15], and infundibular choristoma [90] have also been reported.

Only two cases of tumor-to-intracranial cavernoma have been previously reported [42,94]. As far as we are aware, we report on the first case of malignant melanoma metastasizing to a preexisting cavernous angioma.

2. Case report

A 39-year-old woman presented after a generalized tonic-clonic seizure during a basketball game. This was followed with a brief period of postictal confusion, but no neurologic sequelae.

Over a period of 20 years, she had had 5 episodes of generalized tonic-clonic seizure. Her first seizure occurred at the age of 19 years, in the immediate postnatal period after the delivery of her first child. Her subsequent seizure episodes over the next 20 years were presumed to be related to the effects of sleep deprivation, alcohol intake, or eclampsia; therefore, no brain imaging had ever been performed. She

Abbreviations: ACTH, Adrenocorticotrophic hormone; CT, Computed tomography; FLAIR, Fluid attenuated inversion recovery; GH, Growth hormone.

* Corresponding author. Epworth Medical Centre, Richmond, Victoria 3121, Australia. Tel.: +61 3 94289066; fax: +61 3 94277085.

E-mail address: fabinyi@ozemail.com.au (G.C.A. Fabinyi).

was treated with prophylactic phenytoin during the final trimester of her last 3 pregnancies. Apart from this, she was on no medication.

She also described occasional episodes of visual disturbance and sometimes speech difficulty. On further questioning, she denied any history of headache, nausea, vomiting, weakness, or numbness. She had no history to suggest previous malignancy. There was no family history of malignancy or epilepsy.

The patient was otherwise neurologically intact. There were no suspicious skin lesions apart from a brown nevus-like lesion over the right abdomen. Systemic examination was unremarkable.

A CT brain scan demonstrated a left parieto-occipital intra-axial hyperdense lesion measuring 3.5×2.5 cm with mild contrast enhancement associated with moderate degree of vasogenic edema. Magnetic resonance imaging of brain revealed this lesion to be heterogenous in signal with predominant high signal on T1-weighted images (Fig. 1A) and low signal on T2-weighted images associated with a moderate degree of vasogenic edema (Fig. 1B). The heterogeneity was accentuated in FLAIR sequence with a low-signal rim capping the lesion anteriorly (Fig. 1C). There was enhancement posteriorly within the lesion on gadolinium-enhanced T1-weighted images (Fig. 1D). A

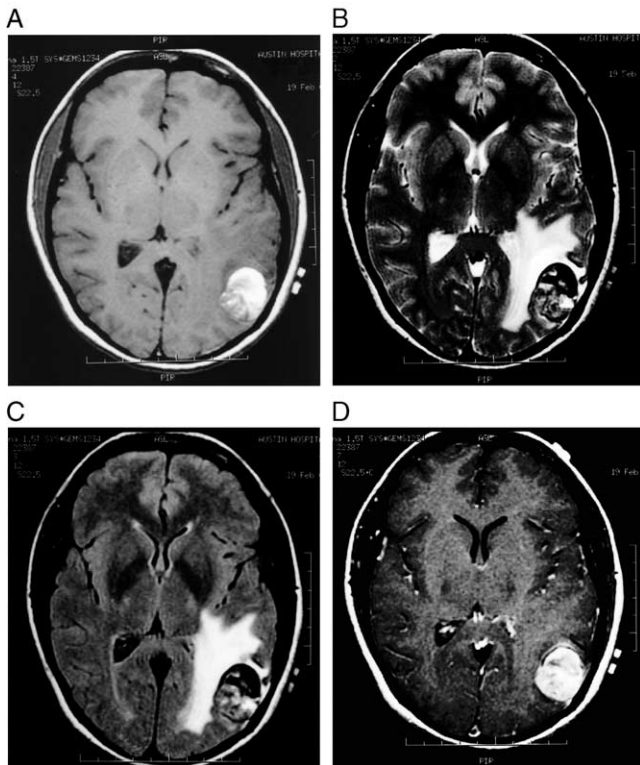


Fig. 1. Magnetic resonance brain images revealed the left parieto-occipital lesion to be heterogenous in signal with predominant high signal on T1-weighted images (A) and low signal on T2-weighted images associated with moderate degree of vasogenic edema (B). The heterogeneity was accentuated in FLAIR sequence with a low-signal rim capping the lesion anteriorly (C). There was enhancement posteriorly within the lesion on gadolinium-enhanced T1-weighted images (D).

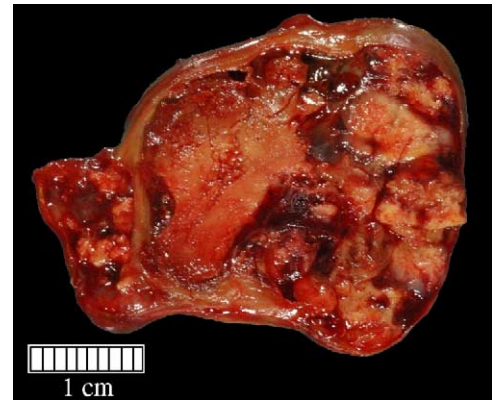

Fig. 2. Cut surface of resected lesion showing relatively smooth fibrous capsule, fibrous septation, and variegated contents of blood clot and pale tumor.

presumptive diagnosis of hemorrhagic left parieto-occipital metastasis or high-grade glioma was made.

The patient underwent an image-guided frameless stereotactic craniotomy. After durotomy, a greenish lesion was noted close to the surface with a thin layer of cortex over it. The lesion was well circumscribed and discrete and could be shelled quite readily from the brain. There was some local hemorrhage around the lesion, but no residual lesion was seen in the surrounding cerebral tissue. The lesion was removed en bloc with an intact margin.

On gross examination, the lesion was a relatively smooth-surfaced nodule with a smaller protuberant nodule evident at one end. It measured $45 \times 35 \times 25$ mm. On incising, there was a 1- to 2-mm smooth thick fibrous capsule. The cut surface was variegated, with large blood-filled areas, fibrous septation, and intervening ragged pale foci of granular solid tissue (Fig. 2).

Histologically, the lesion was surrounded by a thick collagenous fibrous wall containing chronic inflammatory cells, notably hemosiderin-containing macrophages. Collagenous fibrous tissue subdivided the lesion into blood-filled

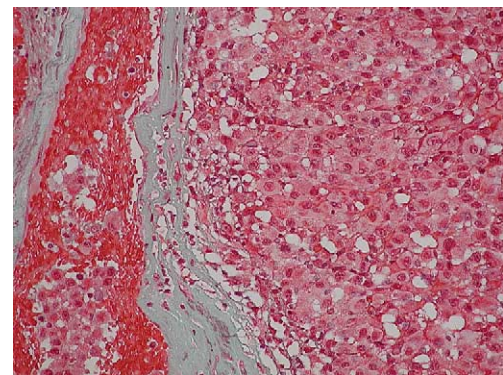


Fig. 3. Histologic section showing green collagenous fibrous tissue walls of cavernous angioma, with metastatic melanoma occupying vascular channels on the right and blood admixed with tumor on the left side. A portion of a further blood-filled channel is seen at upper left (Masson trichrome stain, original magnification $\times 200$).

Table 1

Published cases of tumor-to-CNS lesion metastases

Host tumor = meningioma		
Primary	Reported cases	Site
Breast [2,4,7,16,17, 20-22,28,29,31,32, 41,50,52,56,58-60, 69,81,83,90,93,98, 100,110]	27	Convexity (14); parasagittal/parafalcine (4); frontobasal (2); posterior fossa (2); planum sphenoidale (1); olfactory groove (1); petrous ridge (1); parasellar (1); brain unspecified (1)
Lung [3,4,8-10,21,24, 27,36-38,46,51,71, 72,83,86,101,103, 104,111]	22	Parasagittal/parafalcine (8); convexity (5); sphenoid wing (3); Sylvian fissure (2); posterior fossa (2); planum sphenoidale (1); optic nerve sheath (1)
Renal [4,12,40,53, 71,87,90,102]	8	Convexity (2); Sylvian fissure (2); unspecified (2); sphenoid ridge (1); tentorial (1)
Unspecified [79,112]	5	Unspecified (5)
Prostate [6,21,30]	3	Parasagittal (2); cerebellopontine angle (1)
Unknown primary [19,59,60]	3	Parasagittal (3)
Parotid [97]	1	Sphenoid ridge (1)
Esophagus [52]	1	Unspecified (1)
Stomach [45]	1	Cerebellopontine angle (1)
Gallbladder [73]	1	Suprasellar (1)
Testicular lymphoma [52]	1	Unspecified (1)
Cervix [107]	1	Convexity (1)
Endometrium [43]	1	Convexity (1)
Lymphoma [90]	1	Unspecified (1)
Melanoma [105]	1	Convexity (1)
Host tumor = acoustic neuroma		
Primary	Reported cases	
Breast [99,102,106]	3	
Lung [21,57]	3	
Stomach [84]	1	
Host tumor = pituitary adenoma		
Primary	Reported cases	Histologic types
Breast [13,77,95,109]	4	Nonsecreting (3); gonadotrophin-secreting (1)
Lung [54,62,75,82]	4	Nonsecreting (2); oncocytic (1); unspecified (1)
Unknown primary [13,47,75]	3	ACTH-secreting (1); GH-secreting (1); gonadotrophin-secreting (1)
Stomach [62,96]	2	GH-secreting (1); prolactin-secreting (1)
Colorectal [68]	1	Nonsecreting (1)
Renal [48]	1	Nonsecreting (1)
Renal pelvis and ureteric [18]	1	Nonsecreting (1)
Malignant carcinoid tumor of anterior mediastinum [1]	1	Prolactin-secreting (1)
Prostate [76]	1	Nonsecreting (1)
Pancreas [76]	1	ACTH-secreting (1)

Table 1 (continued)

Host tumor = glioma		
Primary	Reported cases	Histologic types
Breast [65,88,91,108]	4	Oligodendroglioma (3); pilocytic astrocytoma (1)
Lung [63,89]	4	Anaplastic astrocytoma (2); astrocytoma (1); ependymoma (1)
Melanoma [33,90,112]	3	Glioblastoma multiforme (1); oligodendroglioma (1); glioma unspecified (1)
Unknown primary [50,102]	2	Astrocytoma (1); glioblastoma multiforme (1)
Colorectal [61]	1	Oligodendroglioma (1)
Renal [35]	1	Glioblastoma multiforme (1)
Thyroid [74]	1	Glioblastoma multiforme (1)
Host tumor = cerebellar hemangioblastoma		
Primary	Reported cases	
Renal (clear cell carcinoma) [14,39,49,64]	4	
Prostate [26]	1	
Host tumor = central neurocytoma		
Primary	Reported cases	
Melanoma [15]	1	
Host tumor = infundibular choristoma		
Primary	Reported cases	
Lymphoma [90]	1	
Host tumor = intracranial cavernoma		
Primary	Reported cases	Site
Lung [42,94]	2	Pons (1); temporal lobe (1)
Host tumor = spinal meningioma		
Primary	Reported cases	Site
Breast [44]	1	Cervical
Host tumor = spinal hemangioblastoma		
Primary	Reported cases	Site
Renal (clear cell carcinoma) [39]	1	Thoracic

endothelial-lined spaces, some containing extensively necrotic tumor. The tumor consisted of sheets of large cells with abundant eosinophilic cytoplasm, showing frequent mitoses (Fig. 3). These tumor cells showed positive staining for S-100, gp100 (HMB-45), and Mel-A, confirming the morphologic diagnosis of malignant melanoma.

Hence, the diagnosis was a metastatic malignant melanoma within a preexisting cavernoma.

There was no neurosurgical complication and the postoperative course was unremarkable. She underwent a resection of an abdominal cutaneous lesion that was confirmed to be a benign compound nevus. No other malignant skin lesion nor ocular lesions were found. Staging

thoracic and abdominal CT scans did not reveal any lesions. She subsequently completed a course of whole brain radiotherapy 30 Gy in 10 fractions.

3. Discussion

Metastases of systemic cancers to preexisting mass lesions, phenomena termed as tumor-to-tumor metastases in the literature, although uncommon, have been well documented, with the most common host tumor being renal cell carcinoma [85]. The phenomenon was first reported in 1902 by Berent [5], who described a case of mandibular squamous cell carcinoma metastasizing remotely to a renal cell carcinoma of the right kidney. Recorded host lesions have included benign lesions, such as thyroid adenoma, adrenocortical adenoma, ovarian cystoma, and hepatic cavernous angioma [70], and malignant tumors, such as sarcoma and adenocarcinoma of prostate, pancreas, gastrointestinal tract, breast, and endometrium [85]. The lung primary tumors have been the most common metastases, followed by the prostate, thyroid, and others [85].

Metastases of extracranial malignant tumors into intracranial lesions have also been reported as a rare occurrence in review literature and case reports. Our extensive literature review of previously reported cases (Table 1) has found that the phenomenon might be uncommon, but recognition of cases had increased over the decades. The increased frequency may be due to increased awareness of the phenomenon, better histopathologic identification, or longer survival of patients with systemic cancer. Tumor-to-tumor metastases may be found at either surgery or autopsy, usually as a part of systemic metastasis and rarely as the initial manifestation of primary cancer.

The overwhelming majority of intracranial host tumors have been meningiomas [2-4,6-10,12,16,17,19-22,24,27-32,36-38,40,41,43,45,46,50-53,56,58-60,69,72,73,79,81,83,86,87,90,93,97,98,100,101,103-105,107,110-112]. More than 70 cases have been reported since Fried [36] reported a case of bronchogenic carcinoma metastasized to meningioma. A study of 660 operated meningiomas found 2 cases of tumor-to-meningioma metastases (0.3% of operated meningiomas) [60]. However, Barz [4] documented an incidence of 4 cases of metastases-to-meningiomas in 88 (4.5%) meningiomas in a series of 8371 autopsies, suggesting a higher frequency than the number operated or reported. A rare metastasis to spinal meningioma was also reported by Hockley [44]. From our literature review, most donor tumors to meningiomas were carcinomas from breast (35%), lung (29%), and kidney (10%). The preponderance of breast and lung metastases may be explained by their more frequent occurrence. In addition, the association of meningioma and breast carcinoma has been well documented [60]. Hormonal, genetic, and immunologic factors have been suggested to be the reason for this association.

Less commonly, there have been cases of metastases to vestibular schwannomas [21,57,84,99,102,106], pituitary

adenomas [1,13,18,47,48,54,62,68,75-77,82,95,96,109], and intracranial gliomas of various histologic types and grades, including astrocytoma, oligodendroglioma, ependymoma, anaplastic astrocytoma, and glioblastoma multiforme [33,35,50,61,63,65,74,88-91,108].

There were also reports of metastatic renal cell carcinoma to cerebellar hemangioblastoma, mainly in patients with von Hippel-Lindau disease [14,39,49,64], but also including one sporadic case reported by Crockard et al [26]. A case of metastasis to T5/6 thoracic spinal hemangioblastoma was also recorded by Hamazaki et al [39].

Rare examples include a case of metastatic melanoma to a central neurocytoma reported by Brown et al [15] and a case of lymphoma metastasized to infundibular choristoma (granular cell tumor of the infundibulum) recorded by Takakura et al [90].

Intracranial cavernomas are not common with a quoted incidence of 0.4% [78]. Metastasis to intracranial cavernous angioma has rarely been reported in the literature. In 1975, Hirtzler et al [42] reported a 35-year-old man who died of metastatic small cell carcinoma of the lung in 1946. At autopsy, a metastatic focus was identified within a pontine cavernoma. Trapella et al [94] reported a 66-year-old man who had a total removal of left temporal cystic lesion. Histologically, the lesion was described as “an arterio-venous haemangioma with the appearance in some parts of a cavernous angioma.” Metastatic tissue was not noted in this specimen. The patient subsequently represented 3 months later with recurrent symptoms and a recurrent left temporal cystic lesion was partially removed. The microscopic examination showed a pulmonary small cell metastasis. However, this latter case did not conclusively show a metastasis within the vascular malformation, but a metastasis in a previous site of vascular malformation. Extracranially, metastases to hepatic cavernoma had been reported in 4 instances [11,34,66,70]. Our case adds another case to the rare identification of metastasis into a vascular malformation, and represents the first case of metastasis to intracranial cavernoma involving malignant melanoma as the primary tumor.

In total, we found 115 reported cases of metastases of extracranial malignancies to central nervous system (CNS) lesions. Most primary tumors were breast (34%), lung (30%), and renal (13%). Melanoma contributed only 4% of reported cases. These figures are different from the reported frequencies of common brain metastases, with most primary tumors being lung (50%), breast (15%), and melanoma (10.5%) [67]. The higher incidence of breast and renal metastases to a CNS lesion relative to lung tumor, compared with their reported proportion in normal CNS bed, may be related to the association of breast carcinoma with meningioma in female patients and renal clear cell carcinoma with hemangioblastoma in patients with von Hippel-Lindau disease, as discussed above.

To be comprehensive, no published reports are excluded from the listing in Table 1. The table also includes cases

mentioned without specific details and illustration, such as those of Zulch [112], Kepes [52], and Scheithauer [82]. Nevertheless, they should not all be accepted without reservation. Some histologic subtypes of meningioma and glioma can resemble metastatic lesions and vice versa. Mörk and Rubinstein [63] argued that the case report by Farnsworth [33], which described a case of metastatic melanoma into an oligodendroglioma, could not be accepted without reservation due to its unconvincing illustration because the ability of a metastatic intracranial melanoma to mimic a glioma is well known. Similarly, Russell and Rubinstein [80] contended that the case report by Posnikoff and Stratford [74], which described a thyroid papillary carcinoma metastasis to a glioblastoma multiforme, may in fact represent a glioblastoma multiforme with epithelial-like formations. In the case reported by Osterberg [71], argued Smith et al [86], with presumed renal clear cell carcinoma metastasizing to meningioma, the clear cell could simply represent intrinsic clear cells of the meningioma. Recent cases can now be more accurately categorized with the help of immunohistochemical stains.

In our case, the long clinical history of epilepsy and the skeleton of the lesion with its smooth well-demarcated fibrous wall and vascular channels with variable size lumens separated by purely collagenous tissue without brain parenchyma were typical of cavernoma. The distinctively separate lesion within the cavernoma showed histologic and immunohistochemical characteristics of melanoma with positive staining for S-100, gp100 (HMB-45), and MEL-A.

The precise mechanism of this unique melanoma-to-cavernoma metastatic phenomenon remains undefined. Theories proposed to explain the metastases to meningiomas and other host tumors can similarly explain some possible reasons for metastasis to a cavernoma.

Generally, metastases were found in slow-growing host lesions, thus providing themselves as a potential host for a longer period. This might explain the overall rarer cases of malignant gliomas as the host lesions. Cavernomas may remain asymptomatic for years.

Several authors have mentioned the rich vascularity of the host tumor as a possible predisposing factor increasing their chance of capturing circulating cancer cells [6,83]. A cavernoma, as a vascular malformation, has a highly vascular architecture, which may increase the chances of encountering hematogenous metastases. The slow blood flow within the lesion may increase the likelihood of adherence to vessel wall by the metastatic emboli.

Gyori [38] suggested the high collagen contents of meningioma as offering a favorable biochemical soil for metastatic growth. Similarly, the frequently found organized thrombi in cavernomas may serve to anchor the platelet-tumor aggregate and may also provide the metastasis a “fertile soil” for seeding and growth. The ease of expansile growth within the cavernoma may also be a factor in successful metastatic growth.

Hormonal influences and genetic factors may be important. For example, both meningiomas and breast carcinomas commonly express estrogen and progesterone receptors. The occurrence of metastatic renal clear cell carcinoma into cerebellar hemangioblastomas in patients with von Hippel-Lindau disease suggests the influence of genetic factors.

Recently, adhesive interactions between tumor cell surface receptors and endothelial cell adhesion molecules are thought to contribute to tumor cell arrest and extravasation during hematogenous metastasis [25,92]. Melanoma cells are known to express integrin on their surface, which can interact with cell adhesion molecules expressed on the endothelial surface, leading to tumor cell adherence in *in vitro* studies [23,55]. It is possible that such cell adhesion molecules are expressed on the endothelial cells of cavernoma. Cell adhesion molecules, such as E-cadherin, have been demonstrated by Watanabe et al [100] to be expressed in the donor tumor, the invasive breast ductal carcinoma, and the recipient tumor, the meningioma.

Hope and Symon [46] and Mörk and Rubinstein [63] believed that no causal relationships can be invoked for these coexistence of two different tumors and suggested that the phenomena of metastases in preexisting mass lesions should be regarded as coincidental [107].

4. Conclusion

A patient with tumor-to-intracranial cavernoma metastasis is reported. A literature review disclosed an increase in reporting of the uncommon phenomenon of metastasis into preexisting intracranial lesions. It should therefore be considered as a differential diagnosis in patients with history of systemic cancer who present with progression of preexistent intracranial lesions.

References

- [1] Abe T, Matsumoto K, Iida M, Hayashi M, Sanno N, Osamura RY. Malignant carcinoid tumor of the anterior mediastinum metastasis to a prolactin-secreting pituitary adenoma: a case report. *Surg Neurol* 1997;48(4):389–94.
- [2] Anylan FH, Heinzen BR, Carras R. Metastasis of tumour to second different tumor: collision tumors. *JAMA* 1970;212:2124.
- [3] Arnold AC, Hepler RS, Badr MA, et al. Metastasis of adenocarcinoma of the lung to optic nerve sheath meningioma. *Arch Ophthalmol* 1995;113:346–51.
- [4] Barz H. The incidence of metastatic carcinoma in meningiomas. *Zentralbl Allg Pathol u pathol Anat* 1983;127:367–74 [in German].
- [5] Berent W. Seltene Metastasenbildung. *Centralbl f Allg Path u path Anat* 1902;13:406–10 [in German].
- [6] Bernstein RA, Grumet KA, Wetzel N. Metastasis of prostatic carcinoma to intracranial meningioma. *J Neurosurg* 1983;58:774.
- [7] Bernstein SA. Über Karzinommetastase in einem Duraendothelium. *Zentralbl Allg Pathol* 1933;58:163–6 [in German].
- [8] Best PV. Metastatic carcinoma in a meningioma. *J Neurosurg* 1964;20:892–9.
- [9] Bhargava P, McGrail KM, Manz HJ, et al. Lung carcinoma presenting as metastasis to intracranial meningioma: case report and review of the literature. *Am J Clin Oncol (CCT)* 1999;22:199–202.

- [10] Bori R, Kiss CA, Huszka E, Szucs M, Tusa M, Cserni G. A rare case of tumor-to-tumor metastasis: secondary deposits of pulmonary adenocarcinoma in a secretory meningioma. *Magy Onkol* 2002;46(3):261–4 [in Hungarian].
- [11] Brandt M. Metastasierung eines Bronchialkarzinoms in ein Leberkavernom. *Zentralbl Allg Pathol* 1972;115:402–3 [in German].
- [12] Breadmore R, House R, Gonzales M. Metastasis of renal cell carcinoma to a meningioma. *Australas Radiol* 1994;38:141–3.
- [13] Bret P, Juvet A, Madarassy G, Guyotat J, Trouillas J. Visceral cancer metastasis to pituitary adenoma: report of two cases. *Surg Neurol* 2001;55(5):284–90.
- [14] Bret P, Streichenberger N, Guyotat J. Metastasis of renal cell carcinoma to a cerebellar haemangioblastoma in a patient with von Hippel-Lindau disease: a case report. *Br J Neurosurg* 1999;13:413–6.
- [15] Brown HM, McCutcheon IE, Leeds NE, Schomer DS, Luna MA, Fuller GN. Melanoma metastatic to central neurocytoma: a novel case of tumor-to-tumor metastasis. *J Neuro-Oncol* 2003;61(3):209–14.
- [16] Bucciero A, DelBassoDeCaro M, Vizioli L, Carraturo S, Cerillo A, Tedeschi G. Metastasis of breast carcinoma to intracranial meningioma. Case report and review of the literature. *J Neurosurg Sci* 1992;36:169–72.
- [17] Buge A, Escourroule R, Martin M, Poirier J, Devoise C. Métastases cérébro-méningées d'un épithélioma du sein. Méningiome multiple Intrication des deux processus. *Rev Neurol (Paris)* 1966;114:308–12 [in French].
- [18] Burns WA, Kadar AT. Unusual metastases from a transitional cell carcinoma of the renal pelvis and ureter. *Med Ann D C* 1973;42:65–6.
- [19] Cappabianca P, De Chiara A, Spaziante R, et al. Metastasis of carcinoma to an intracranial meningioma. Case report and revision of the literature. *Acta Neurol* 1985;7:482–93.
- [20] Cervoni L, Salvati M, Gagliardi D, Delfini R. Metastasis of breast carcinoma to intracranial meningioma. Case report. *Neurosurg Rev* 1994;17:233–6.
- [21] Chambers PW, Davis RL, Blanding JD, Buck FS. Metastases to primary intracranial meningiomas and neurilemmomas. *Arch Pathol Lab Med* 1980;104:350–4.
- [22] Chow LW, Ho KH, Fong CM. Intracranial meningioma with metastatic breast carcinoma. *Ann Oncol* 1992;3:409–10.
- [23] Constantinides P, Harkey M, McLaury D, et al. The role of microvascular environment in the metastasizing ability of an experimental tumour. *Virchows Arch A* 1987;411:223–32.
- [24] Conzen M, Sollmann H, Schnabel R. Metastasis of lung carcinoma to intracranial meningioma. *Neurochirurgica* 1986;29:206–9.
- [25] Cotran RS, Kumar V, Robbins SL. *Pathologic basis of disease*. 5th ed. Philadelphia: W.B. Saunders; 1994. p. 276–80.
- [26] Crockard HA, Barnard RO, Isaacson PG. Metastasis of carcinoma to haemangioblastoma cerebelli: case report. *Neurosurg* 1988;23(3):382–384.
- [27] Cserni G, Bori R, Huszka E, Kiss AC. Metastasis of pulmonary adenocarcinoma in right Sylvian secretory meningioma. *Br J Neurosurg* 2002;16:66–8.
- [28] DiBonito L, Bianchi C. Metastase d'un cancer mammaire dans un méningiome. *Sem Hosp Paris* 1978;55:171–2 [in French].
- [29] Di Bonito L, Giarelli G, Falconieri D, Bonifacio-Gori G, Tomasic G, Vielh P. Association of breast cancer and meningioma: report of 12 new cases and review of the literature. *Pathol Res Pract* 1993;189:399–404.
- [30] Doring L. Metastasis of carcinoma of prostate to meningioma. *Virchows Arch (Pathol Anat)* 1975;366:87–91.
- [31] Doron Y, Gruzkiwicz J. Metastasis of invasive carcinoma of the breast to an extradural meningioma of the cranial vault. *Cancer* 1987;60:1081–4.
- [32] Elmaci I, Ekinci G, Kurtkaya O, Sav A, Pamir MN. Tumor in tumor: metastasis of breast carcinoma to intracranial meningioma. *Tumori* 2001;87:423–7.
- [33] Farnsworth J. Regressing melanoma metastasising to an oligodendroglioma. *Pathol* 1972;4:253–7.
- [34] Figari G, Tanzi R. Carcinoma (microcitoma) polmonare con metastasi in angiomi (cavernomi) del fegato. *Pathologica* 1976;68:159–62 [in Italian].
- [35] Franke FE, Altmannsberger M, Schachenmayr W. Metastasis of renal carcinoma colliding with glioblastoma. *Acta Neuropathol* 1990;80:448–552.
- [36] Fried BM. Metastatic inoculation of a meningioma by cancer cells from a bronchogenic carcinoma. *Am J Pathol* 1930;6:47–52.
- [37] Gardiman M, Altavilla G, Marchioro L, et al. Metastasis to intracranial meningioma as first clinical manifestation of occult primary lung carcinoma. *Tumori* 1996;82:256–8.
- [38] Gyori E. Metastatic carcinoma in meningioma. *South Med J* 1976;69:514–7.
- [39] Hamazaki S, Nakashima H, Matsumoto K, Taguchi K, Okada S. Metastasis of renal cell carcinoma to central nervous system haemangioblastoma in two patients with von Hippel-Lindau disease. *Pathol Int* 2001;51:948–53.
- [40] Han HS, Kim EY, Han JY, Kim YB, Hwang TS, Chu YC. Metastatic renal cell carcinoma in a meningioma: a case report. *J Korean Med Sci* 2000;15:593–7.
- [41] Helpap B. Mammacarcinoma-Metastase in einem Meningeom. *Zentralbl Allg Pathol u pathol Anat* 1965;107:242–5 [in German].
- [42] Hirtzler R, Pavelie Z, Kubovic M, Salie M. Metastasen des Lungenkarzinoms in benignen Tumoren. *Zentralbl Allg Pathol Bd* 1975;119:272–5 [in German].
- [43] Ho KL. Metastasis of carcinoma to meningioma. *Arch Pathol Lab Med* 1980;104:394–5.
- [44] Hockley A. Metastatic carcinoma in a spinal meningioma. *J Neurol Neurosurg Psychiatry* 1975;38:695–7.
- [45] Honma K, Hara K, Sawai T. Tumor-to-tumor metastasis: a report of two unusual autopsy cases. *Virchows Arch Pathol Anat* 1989;416:153–7.
- [46] Hope DT, Symon L. Metastasis of carcinoma to meningioma. *Acta Neurochir* 1978;40:307–13.
- [47] Hurley TR, D'Angelo CM, Clasen RA, Di Gianfilippo A, Ryan WG. Adenocarcinoma metastatic to a growth-hormone-secreting pituitary adenoma: case report. *Surg Neurol* 1992;37:361–5.
- [48] James RL, Arsenis G, Stoler M, Nelson C, Baran D. Hypophyseal metastatic renal cell carcinoma and pituitary adenoma. Case report and review of the literature. *Am J Med* 1984;76:337–40.
- [49] Jamjoon A, Kane N, Kicoll J. Metastasis of a renal carcinoma to a cerebellar haemangioblastoma in a case of von Hippel-Lindau disease. *Neurosurg Rev* 1992;5:231–4.
- [50] Joglekar VM, Davis CH, Blakeney CG. Metastasis of carcinoma to meningioma and glioma. *Acta Neurochir* 1981;58:67–74.
- [51] Jomin M, Dupont A, Wemeau J, et al. Metastasis of visceral tumors in intracranial tumors. Apropos of a metastasis of a lung cancer in an intracranial meningioma. *Neurochirurgie* 1982;28:343–7.
- [52] Kepes JJ. *Meningiomas: biology, pathology and differential diagnosis*. New York: Masson; 1982. p. 129–34.
- [53] Kessel FK. Über multiple Hirngeschwulste. *Nervenarzt* 1938;11:13–9 [in German].
- [54] Kovacs K. Metastatic cancer of the pituitary gland. *Oncology* 1973;27:533–42.
- [55] Langley R, Carlisle R, Ma L, et al. Endothelial expression of vascular cell adhesion molecule-1 correlates with metastatic pattern in spontaneous melanoma. *Microcirculation* 2001;8:335–45.
- [56] Lapresle J, Netsky MG, Zimmermann HM. The pathology of meningiomas. A study of 121 cases. *Am J Pathol* 1952;28:757–71.
- [57] LeBlanc R. Metastasis of bronchogenic carcinoma to acoustic neurinoma. Case report. *J Neurosurg* 1974;41:614–6.
- [58] Lee A, Wallace C, Rewcastle B, Sutherland G. Metastases to meningioma. *AJNR Am J Neuroradiol* 1998;19:1120–2.
- [59] Lodrini S, Savioardo M. Metastases of carcinoma to intracranial meningioma. *Cancer* 1981;48:2668–73.

- [60] Maiuri F, Cappabianca P, Iaconetta G, D'Acunzi G. Meningiomas associated with brain metastases. *Zentralbl Neurochir* 2002;63:111–5.
- [61] Mizutani H, Suzuki H, Wakabayashi S, et al. A case of metastasis from a colon carcinoma to an intracranial oligodendroglioma. *Gan No Rinsho* 1987;33(13):1733–9 [in Japanese].
- [62] Molinatti PA, Scheithauer BW, Randall RV, et al. Metastasis to pituitary adenoma. *Arch Pathol Lab Med* 1985;109:287–9.
- [63] Mörk SJ, Rubinstein LJ. Metastatic carcinoma in glioma: a report of three cases with a critical review of the literature. *J Neurol Neurosurg Psychiatry* 1988;51:256–9.
- [64] Mottotese C, Stan H, Giordano F, Frappaz D, Alexei D, Streichenberger N. Metastasis of clear-cell renal carcinoma to cerebellar haemangioblastoma in von Hippel Lindau disease: rare or not investigated? *Acta Neurochir (Wien)* 2001;143:1059–63.
- [65] Muller W, Schroder R. Spreading of metastases into cranial tumors: metastasis of a breast carcinoma to a pilocytic astrocytoma. *Clin Neuropathol* 1999;18(3):109–12.
- [66] Nadin C. Metastasi di carcinoma bronchiale in angioma cavernosa del fegato. *G Veneto Sci Med* 1956;11:199 [in Italian, abstract].
- [67] Nelson JS, von Deimling A, Petersen I, Janzer R-C. Metastatic tumours of the CNS. In: Kleihues P, Cavenee WK, editors. *World Health Organization classification of tumours. Pathology and genetics. Tumours of the nervous system*. Lyon: IARC Press; 2000. p. 250–3.
- [68] Noga C, Prayson RA, Kowalski R, Sweeney PJ, Mayberg M. Metastatic adenocarcinoma to a pituitary adenoma. *Ann Diagn Pathol* 2001;5(6):354–60.
- [69] Nunnery E, Kahn LB, Rudnik SA. Breast carcinoma metastatic to meningioma. *Arch Pathol Lab Med* 1980;104:392–3.
- [70] Ortega P, Li I, Shimkin N. Metastasis of neoplasms to other neoplasms. *Ann West Med Surg* 1951;5:601–9.
- [71] Osterberg DH. Metastases of carcinoma to meningioma. *J Neurosurg* 1957;14:337–43.
- [72] Pamphlett R. Carcinoma metastasis to meningioma. *J Neurol Neurosurg Psychiatr* 1984;47:561–3.
- [73] Peison WB, Feigin I. Suprasellar meningioma containing metastatic meningioma. Report of a case. *J Neurosurg* 1961;18:688–9.
- [74] Posnikoff J, Stratford J. Carcinoma metastasis to malignant glioma. Case report. *Arch Neurol* 1960;3:559–63.
- [75] Post KD, Mc Cormick PC, Hays AP, Kandji AG. Metastatic carcinoma to pituitary adenoma. Report of two cases. *Surg Neurol* 1988;30:286–92.
- [76] Ramsay JA, Kovacs K, Scheithauer BW, Ezrin C, Weiss MH. Metastatic carcinoma to pituitary adenomas: a report of two cases. *Exp Clin Endocrinol* 1988;92(1):69–76.
- [77] Richardson J, Katayama I. Neoplasm to neoplasm metastasis. An acidophil adenoma harboring metastatic carcinoma: a case report. *Arch Pathol* 1971;91:135–9.
- [78] Rigamonti D, Hsu FPK, Monsein LH. Cavernous malformations and related lesions. In: Wilkins RH, Rengachary SS, editors. *Neurosurgery*, vol. 2. 2nd ed. New York: McGraw-Hill; 1992. p. 2503–8.
- [79] Rubinstein LJ. Tumors of the central nervous system. In: Rubinstein LJ, editor. *Atlas of tumour pathology. Series 2, fascicle 6*. Washington (DC): Armed Forces Institute of Pathology; 1972. p. 321–7.
- [80] Russell DS, Rubinstein LJ. *Pathology of tumours of the nervous system*. 5th ed. London: Edward Arnold; 1989. p. 840–1.
- [81] Savoiardo M, Lodrini S. Hypodense area within a meningioma: metastasis from a breast cancer. *Neuroradiol* 1980;20:108–10.
- [82] Scheithauer BW. Surgical pathology of the pituitary: the adenomas. *Pathol Annu* 1984;19(2):269–329.
- [83] Schmitt HP. Metastases of malignant neoplasms to intracranial tumours: the tumour in a tumour phenomenon. *Virchows Arch* 1984;405:155–60.
- [84] Schwesinger G, Pusinelli WD. Acoustic neurinoma with metastases of a carcinoma of the stomach. *Zentralbl Allg Pathol* 1974;118(5):473–5 [in German].
- [85] Sella A, Ro JY. Renal cell cancer: best recipient of tumor-to-tumor metastasis. *Urology* 1987;30(1):35–8.
- [86] Smith TW, Wang S-Y, Schoene WC. Malignant carcinoid tumor metastatic to a meningioma. *Cancer* 1981;47:1872–7.
- [87] Stortebeker TP. Metastatic hypernephroma of the brain from a neurosurgical point of view. A report of 19 cases. *J Neurosurg* 1951;8:185–7.
- [88] Strang RR. Metastasis of breast carcinoma to an intracerebral oligodendroglioma. *Zentralbl Neurochir* 1965;25:206–10.
- [89] Tajika Y, Reifenberger G, Kiwit JC, Wechsler W. Metastatic adenocarcinoma in cerebral astrocytoma: clinicopathological and immunohistochemical study with review of the literature. *Acta Neurochir* 1990;105:50–5.
- [90] Takakura K, Sano K, Hojo S, et al. Metastatic tumors of the central nervous system. Tokyo: Igaku-Shoin; 1982.
- [91] Tally PW, Laws ER, Scheithauer BW. Metastases of central nervous system neoplasms: case report. *J Neurosurg* 1988;68:811–6.
- [92] Tang DG, Honn KV. Adhesion molecules and tumor metastasis: an update. *Invasion Metastasis* 1994;14:109–22.
- [93] Theologides A, Lee JC. Tumor to tumor metastasis. *JAMA* 1972;219:384.
- [94] Trapella G, Migliore MM, Rocella P, Cavazzini L. Metastatic carcinoma to arterio-venous haemangioma. Case report. *J Neurosurg Sci* 1993;37(1):35–8.
- [95] Van Der Zwan A, Luyendijk W, Bots GTAM. Metastasis of mammary carcinoma in a chromophobe adenoma of the hypophysis. *Psychiatr Neurol Neurochir* 1971;74:369–77.
- [96] Van Seters AP, Bots GTAM, Van Dulken H, Luyendijk W, Jan Viel Voyer G. Metastasis of an occult gastric carcinoma suggesting growth of a prolactinoma during bromocriptine therapy: a case report with a review of the literature. *Neurosurg* 1985;16:813–7.
- [97] Van Zandijcke M, Casselman J. MR imaging of a metastasis in a meningioma. *Acta Neurol Belg* 1996;96:329–31.
- [98] Völker U, Thierauf P. Tumor in tumor: Mammakarzinommetastase in einem Meningiome. *Pathologe* 1993;14:231–3 [in German].
- [99] Wallach J, Edberg E. Metastases of cancer to primary intracranial tumor. *Arch Neurol* 1959;1:191–4.
- [100] Watanabe T, Fujisawa H, Hasegawa M, et al. Metastasis of breast cancer to intracranial meningioma: case report. *Am J Clin Oncol (CCT)* 2002;25:414–7.
- [101] Weems TD, Garcia JH. Intracranial meningioma containing metastatic foci. *South Med J* 1977;70:503–5.
- [102] Wessel H, Gerlach H. Mammakarzinommetastasen in einem Akustikusneurinom. *Zbl Allg Pathol* 1973;117:146 [in German].
- [103] Wilson CB, Jenevein Jr EP, Bryant LR. Carcinoma of the lung metastatic to falx meningioma. Case report. *J Neurosurg* 1967;27:161–5.
- [104] Wolintz AH, Mastro A. Metastasis of carcinoma of lung to sphenoid ridge meningioma. *N Y State J Med* 1970;70:2592–8.
- [105] Wong A, Koszyz B, Blumbergs PC, et al. Malignant melanoma metastatic to a meningioma. *Pathology* 1999;31:162–5.
- [106] Wong T-W, Bennington JL. Metastasis of a mammary carcinoma to an acoustic neuroma. *J Neurosurg* 1962;19:1088–93.
- [107] Wu WQR, Hiszezynski R. Metastasis of a carcinoma of cervix uteri to convexity meningioma. *Surg Neurol* 1977;8:327–9.
- [108] Wurm G, Huber A, Hier tz H, Fischer J, Cervos-Navarro J. Composite cerebral metastasis and oligodendroglioma: an exceptional form of mixed neoplasia. *Neurosurg Rev* 1994;17(4):291–4.
- [109] Zager EL, Hedley-Whyte T. Metastasis within a pituitary adenoma presenting with bilateral abducens palsies: case report and review of the literature. *Neurosurgery* 1987;21:383–6.
- [110] Zon LI, Johns WD, Stomper PC, et al. Breast carcinoma metastatic to meningioma. *Arch Int Med* 1989;149:959–62.
- [111] Zoos BA. Neoplastic metastasis in a tumour. *Arkh Pathol* 1970;32:68–70 [in German].
- [112] Zulch KJ. *Brain tumours: their biology and pathology*. 2nd ed. London: Heinemann; 1965. p. 255 [Translated by Rothballer AB and Olszewski JJ].