

### Moyamoya Syndrome in a Splenectomized Patient With $\beta$ -Thalassemia Intermedia

#### ABSTRACT

We describe a 14-year-old Japanese girl with  $\beta$ -thalassemia intermedia who developed moyamoya syndrome after splenectomy. This patient had compound heterozygous mutations of the  $\beta$ -globin gene and received occasional transfusions. After splenectomy at 12 years of age, she transiently required partial exchange transfusions for leukoerythroblastosis but attained transfusion independence. Two years after the splenectomy, transient ischemic attacks occurred repeatedly with right hemiparesis or left paresthesia. Magnetic resonance imaging revealed bilateral stenosis of the internal carotid arteries and dilatation of the perforating branches with the formation of moyamoya vessels but not infarctions. The strict adherence to aspirin and dipyridamole has led to no stroke or progression of the vasculopathy for 8 years. Moyamoya disease has been reported in a patient with  $\beta$ -thalassemia major. Cerebral vasculopathy can be a rare but grave consequence of the thromboembolic complications in  $\beta$ -thalassemia major/intermedia. (*J Child Neurol* 2006;21:75–77).

Moyamoya disease is an idiopathic cerebral vasculopathy characterized by the bilateral occlusion of intracranial carotid arteries and proximal portions of anterior and/or middle cerebral arteries with a collateral network of telangiectatic vessels resembling a “puff of smoke” (“moyamoya”) in adjacent areas.<sup>1</sup> Ischemic attacks of hemiplegia or seizures constitute the major presentation in childhood, whereas subarachnoid hemorrhage occurs more frequently in adults. The progressive nature of the disease leads to unfavorable neurologic outcomes without surgical intervention to reconstitute the cerebral circulation.<sup>2</sup> The diagnosis of moyamoya disease but not moyamoya syndrome is made in patients with no underlying disease or identifiable cause of vasculitis, atherosclerosis, and malformations for understanding the etiology and pathophysiology of vasculopathy.

The  $\beta$ -thalassemias are a heterogeneous group of inherited hemoglobin disorders characterized by reduced synthesis of  $\beta$ -globin chains and primarily affecting individuals in malaria-endemic areas.<sup>3</sup> Homozygous or compound heterozygous mutations of the  $\beta$ -globin gene lead to severe anemia with ineffective erythropoiesis and hemolysis as the major or intermediate phenotype. Splenectomy is not recommended for thalassaemic patients without hypersplenism because of its limited effects on the increase in the hemoglobin concentration and the thromboembolic complications. It is difficult to determine the degree of hypersplenism affecting the severity of the anemia caused by the unbalanced production of globin chains. There has been renewed interest in the thromboembolic complication of thalassemias because a subclinical hypercoagulable state has already started in children.<sup>4,5</sup> Cerebrovascular accidents are the major complication of sickle cell disease and are accompanied by narrowing and occlusion of the internal carotid arteries with the formation of moyamoya vessels.<sup>6,7</sup> On the other hand, only one case of an association between thalassemia and moyamoya disease has been reported.<sup>8</sup>

We describe a 14-year-old Japanese girl with  $\beta$ -thalassemia who developed moyamoya syndrome after splenectomy. There were no ischemic attack recurrences during the antiplatelet therapy. The moyamoya vessels

and stenotic lesions were not progressive. The pathogenesis of the moyamoya vasculopathy in  $\beta$ -thalassemia is discussed.

#### Case Report

A 14-year-old Japanese girl with  $\beta$ -thalassemia intermedia visited us owing to consecutive episodes of transient right hemiparesis. An aplastic crisis in a parvovirus B19 infection at 6 years of age had led to the diagnosis of  $\beta$ -thalassemia with compound heterozygous mutations IVS-2 654 C>T and IVS-2 1 G>A.<sup>9</sup> Her parents and brother had either one of the mutations, exhibiting a minor phenotype. There was no family history of cerebral vascular accidents. The patient underwent splenectomy at 12 years of age because of the monthly transfusions and splenomegaly. One month and 5 months after the splenectomy, headache and general malaise associated with leukoerythroblastosis occurred but were controlled by temporary partial exchange transfusions. Her hemoglobin levels then remained at more than 8.0 g/dL without any following transfusion. Aspirin therapy was continued for postsplenectomy thrombocytosis.

On the visit, physical examination revealed a small, slightly pale, and icteric girl of 135.5 cm in height ( $-3.0$  SD) and 28.7 kg in weight ( $-2.7$  SD). Her pulse rate was 114/minute, and her blood pressure was 110/48 mm Hg. Chest auscultation was normal. The liver was palpated 5 cm below the right costal margin. The spleen had been resected. Neurologic examinations defined no abnormality. The peripheral blood counts showed leukocytes  $11.72 \times 10^9/L$ , erythrocytes  $3080 \times 10^9/L$ , hemoglobin 8.5 g/dL, hematocrit 26.9%, reticulocytes 68%, nucleated erythrocytes  $22.86 \times 10^9/L$ , and platelet count  $958 \times 10^9/L$ . Marked poikilocytosis and Howell-Jolly bodies were found. Blood chemistry indicated hemolysis, lactate dehydrogenase 802 IU/L, and indirect bilirubin 3.8 mg/dL. Coagulation studies revealed subnormal activities of protein C (40%; reference range 75–131), protein S (58%; reference range 70–118), and plasminogen (68%; reference range 80–128) and an increase in thrombin-antithrombin complexes (3.4 ng/mL; reference range 0–3.0). There were no abnormalities in other parameters, including antithrombin III, lupus anticoagulant, and anticardiolipin antibodies. Her family members showed normal coagulation studies. Electroencephalographic and cardiologic studies were normal. Computed tomography revealed no brain lesions with widening of the diploic spaces of the skull bone. Magnetic resonance imaging revealed no infarctions but high signal intensities of bilateral basal ganglia surrounded by multiple small signal voids in  $T_1$ -weighted images, which indicated iron overload and collateral small vessels (Figure 1). Magnetic resonance angiography showed bilateral and left dominant narrowing of the supraclinoid portions of the internal carotid arteries and dilatation of the thalamoperforating branches, along with the formation of collateral vessels (Figure 2). These findings were compatible with stage III moyamoya disease.<sup>10</sup> A close interview disclosed 1 week of discontinuation of aspirin therapy before the attack. Transient left paresthesia and hypoxic attacks recurred a month after the resumption of aspirin therapy. Combined administration of dipyridamole has resulted in no attack for 8 years. Follow-up magnetic resonance angiograms showed no progression of the stenotic lesions and moyamoya vessels. She has been free of any neurologic deficits.

#### Discussion

Moyamoya syndrome occurs in patients with brain tumors, vascular malformations, or vasculitis after irradiation, infections, and head trauma. It can be associated with various inherited disorders, that is, neurofibromatosis, tuberous sclerosis complex, Down syndrome, and Alagille syndrome, along with some anemias.<sup>1</sup> Patients with homozygous hemoglobin S occasionally develop cerebral infarctions and narrowing or occlusion of the internal carotid arteries, with the moyamoya pattern as the most common arteriographic finding.<sup>6,7,11–13</sup> The progressive vasculopathy can be a consequence of the flow in the vasa vasorum being obstructed by sickle cells, which leads to ischemia in the walls of the internal carotid arteries, intimal

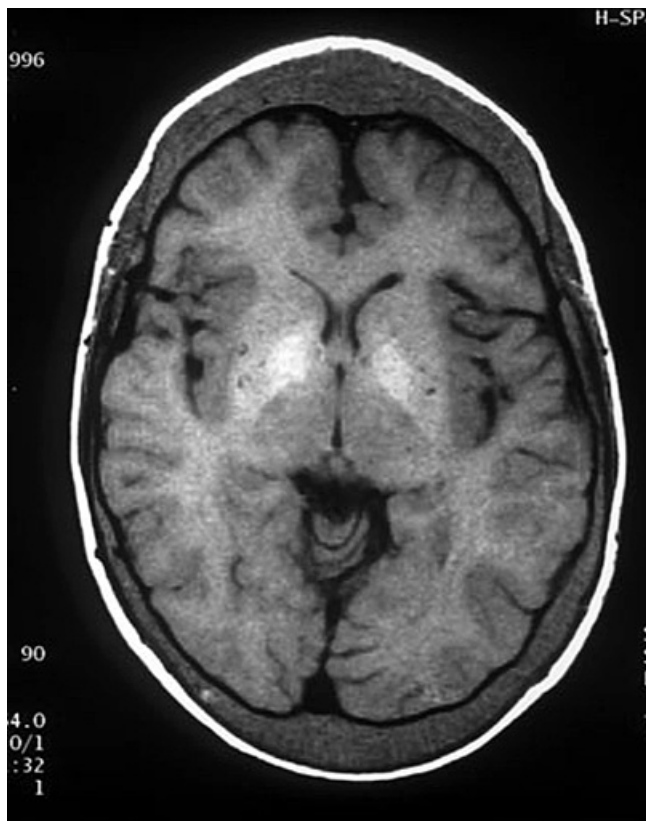

Figure 1. Brain magnetic resonance image showing no infarctions but high signal intensities in bilateral basal ganglia surrounded by multiple small round voids and widening of the diploic spaces of the skull bone ( $T_1$ -weighted image [repetition time: 560.0 milliseconds; echo time: 14.0 milliseconds]).

proliferation, and occlusion but not exclusively of the direct obstruction of small cerebral vessels by the cells. Moyamoya syndrome has been reported in patients with hereditary spherocytosis<sup>14</sup> and Fanconi anemia.<sup>15</sup> Ischemic strokes might be associated with other types of anemia, including iron deficiency anemia<sup>7</sup> and Diamond-Blackfan anemia.<sup>16</sup> There is a high incidence of cerebral thrombosis in  $\alpha$ - and  $\beta$ -spectrin-deficient mice with hereditary spherocytosis.<sup>17</sup> The increased blood flow caused by anemia, together with less deformable red cells, can lead to progressive endothelial proliferation and subsequent vascular occlusion. There has been one case report of the association of moyamoya vasculopathy and  $\beta$ -thalassemia.<sup>8</sup> A 5-year-old girl with  $\beta$ -thalassemia major presented with hemiconvulsions and hemiplegia with cerebral infarctions and bilateral occlusion of the internal carotid arteries with moyamoya vessels and suffered from aphasia and spastic paraplegia as sequelae.<sup>8</sup> Unlike in our patient, the ischemic attacks in the patient with the major phenotype occurred prior to splenectomy. A chronic hypercoagulable state has been a focus of constant attention in  $\beta$ -thalassemia major/intermedia.<sup>4,5</sup> An excess of  $\alpha$ -chain molecules and their derivatives, including hemo, results in damage to the erythrocyte membranes in  $\beta$ -thalassemia via oxidative stress. The membrane damage induces increased surface expression of anionic phospholipids, such as phosphatidylserine, which incites the platelet activation and the procoagulant effect of thalassemic erythrocytes.<sup>5</sup> Patients with  $\beta$ -thalassemia or sickle cell anemia share the membrane phospholipid abnormalities of erythrocytes and exhibit similar coagulation profiles, including elevated plasma levels of thrombin-antithrombin complexes and decreased levels of proteins C and S.<sup>5</sup> The present patient showed the typical coagulation profile of  $\beta$ -thalassemia. On the other hand, overt thrombotic events are less common in  $\beta$ -thalassemia major/intermedia cases than in those with homozygous hemoglobin S (sickle cell crisis).<sup>5</sup> Sickle cells are less deformable than tha-

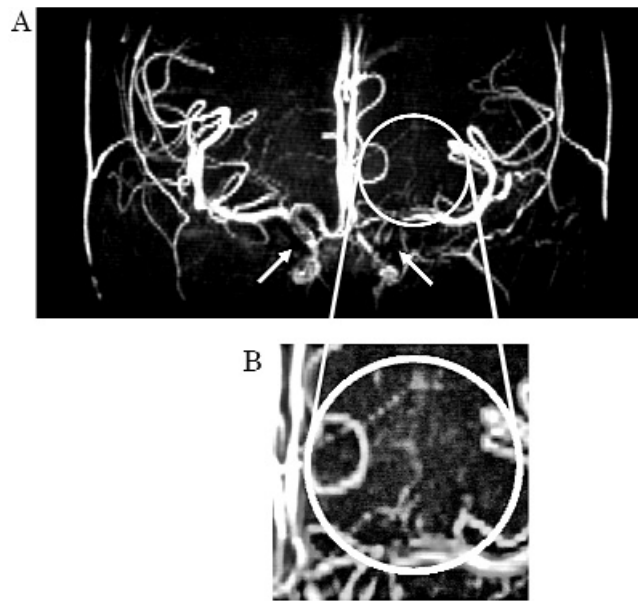


Figure 2. A Brain magnetic resonance angiogram showing bilateral narrowing of the supraclinoid portions of the internal carotid arteries with left predominance (arrows) and dilatation of the thalamoperforating branches, along with the formation of bilateral collateral vessels. B Enlarged view of the left moyamoya vessels (circle). These findings are consistent with stage III moyamoya disease.

lassemic erythrocytes to obstruct the microcirculation. Patients with  $\beta$ -thalassemia intermedia who do not receive transfusions regularly have a much higher incidence of thrombotic events than patients receiving regular transfusions.<sup>5</sup> Splenectomy usually increases the risk of strokes and embolism owing to thrombocytosis and hyperlipidemia. In this setting, postsplenectomy thrombocytosis and weaning from transfusions augmented the hypercoagulability associated with the abnormal erythrocyte rheology and might have elicited the formation of moyamoya vessels in our patient with intermediate thalassemia. No ischemic attacks soon after splenectomy, when transient leukoerythroblastosis occurred, might indicate the later development of the cerebral vasculopathy. However, it remains undetermined whether the vascular changes started before or after splenectomy because magnetic resonance angiography was not performed prior to the splenectomy. Cerebral vasculopathy in the first reported case with  $\beta$ -thalassemia was described as moyamoya disease but not moyamoya syndrome.<sup>8</sup> On the other hand, Peerless raised the possible risk of moyamoya syndrome in thalassemia based on an epidemiologic study in North America.<sup>18</sup> The bilateral vascular lesion in our patient was not progressive after antiplatelet therapy. The present observation might indicate a potential role of hemoglobinopathy in the etiopathogenesis of moyamoya vasculopathy, as well as a caveat for the management of splenectomized patients with  $\beta$ -thalassemia.

#### Acknowledgments

We thank Dr Y. Matsushima (Division of Neurosurgery, Hamanomachi Hospital, Fukuoka, Japan) for the helpful discussion, Mr T. Kanemaru (Morphology Core Unit, Kyushu University, Fukuoka, Japan) for the assistance, and Mr N. J. Halwood (a native English speaker) for the review.

Masafumi Sanefuji, MD  
Shouichi Ohga, MD  
Ryutaro Kira, MD  
Department of Pediatrics  
Graduate School of Medical Sciences  
Kyushu University

Takashi Yoshiura, MD  
 Department of Radiology  
 Graduate School of Medical Sciences  
 Kyushu University  
 Hiroyuki Torisu, MD  
 Toshiro Hara, MD  
 Department of Pediatrics  
 Graduate School of Medical Sciences  
 Kyushu University  
 Fukuoka, Japan

Received December 27, 2004. Received revised February 22, 2005. Accepted for publication February 23, 2005.

This work was supported in part by a Grant-in-Aid for Scientific Research to Dr Ohga from the Ministry of Education, Culture, Sports, Science and Technology of Japan.

Address correspondence to Dr Masafumi Sanefuji, Department of Pediatrics, Faculty of Medicine, Kyushu University, 3-1-1 Maidashi, Higashi-ku, Fukuoka 812-8582, Japan. Tel: +81-92-642-5421; fax: +81-92-642-5435; e-mail: sane26@pediatr.med.kyushu-u.ac.jp.

DOI 10.2310/7010.2006.00006

### References

1. Suzuki J, Kodama N: Moyamoya disease—Review. *Stroke* 1983;14:104–109.
2. Matsushima Y, Aoyagi M, Nariai T, et al: Long-term intelligence outcome of post-encephalo-duro-arteri-synangiosis in childhood moyamoya patients. *Clin Neurol Neurosurg* 1997;99(Suppl 2):S147–S150.
3. Olivieri NF: The beta-thalassemias. *N Engl J Med* 1999;341:99–109.
4. Eldor A, Durst R, Hy-Am E, et al: A chronic hypercoagulable state in patients with beta-thalassaemia major is already present in childhood. *Br J Haematol* 1999;107:739–746.
5. Eldor A, Rachmilewitz EA: The hypercoagulable state in thalassemia. *Blood* 2002;99:36–43.
6. Ohene-Frempong K, Weiner SJ, Sleeper LA, et al: Cerebrovascular accidents in sickle cell disease: Rates and risk factors. *Blood* 1998;91:288–294.
7. Ganesan V, Prengler M, McShane MA, et al: Investigation of risk factors in children with arterial ischemic stroke. *Ann Neurol* 2003;53:167–173.
8. Mukherjee A: Moyamoya disease and  $\beta$ -thalassemia. *J Assoc Physicians India* 1995;43:710–711.
9. Chifu Y, Nakashima H, Hara T, et al: Beta-thalassemia major resulting from a compound heterozygosity for the beta-globin gene mutation: Further evidence for multiple origin and migration of the thalassemia gene. *Hum Genet* 1992;89:343–346.
10. Suzuki J, Takaku A: Cerebrovascular “moyamoya” disease: Disease showing abnormal net-like vessels in base of brain. *Arch Neurol* 1969;20:288–299.
11. Pegelow CH: Stroke in children with sickle cell anaemia: Aetiology and treatment. *Paediatr Drugs* 2001;3:421–432.
12. Grotta JC, Manner C, Pettigrew LC, Yatsu FM: Red blood cell disorders and stroke. *Stroke* 1986;17:811–817.
13. Stockman JA, Nigro MA, Mishkin MM, Oski FA: Occlusion of large cerebral vessels in sickle-cell anemia. *N Engl J Med* 1972;287:846–849.
14. Tokunaga Y, Ohga S, Suita S, et al: Moyamoya syndrome with spherocytosis: Effect of splenectomy on strokes. *Pediatr Neurol* 2001;25:75–77.
15. Cohen N, Berant M, Simon J: Moyamoya and Fanconi's anemia. *Pediatrics* 1980;65:804–805.
16. Butrum MW, Williams LS, Golomb MR: A child with Diamond-Blackfan anemia, methylenetetrahydrofolate reductase mutation, and perinatal stroke. *J Child Neurol* 2003;18:800–802.
17. Kaysser TM, Wandersee NJ, Bronson RT, Barker JE: Thrombosis and secondary hemochromatosis play major roles in the pathogenesis of jaundiced and spherocytic mice, murine models for hereditary spherocytosis. *Blood* 1997;90:4610–4619.
18. Peerless SJ: Risk factors of moyamoya disease in Canada and the USA. *Clin Neurol Neurosurg* 1997;99(Suppl 2):S45–S48.

## A Boy With Muscle Weakness, Hypercarbia, and the Mitochondrial DNA A3243G Mutation

### ABSTRACT

The point mutation in the mitochondrial genome tRNA<sup>Leu</sup> (A3243G) is associated with the syndrome of mitochondrial encephalomyopathy, lactic acidosis, and stroke-like episodes (MELAS). We report a boy presenting with respiratory compromise and hypercarbia owing to severe muscle weakness. Historically, he demonstrated idiopathic growth hormone deficiency, retarded bone age, and exercise avoidance. Owing to severe respiratory compromise out of proportion to expected recovery, a metabolic work-up was performed. Muscle biopsy demonstrated abnormal mitochondria structure and heteroplasmic A3243G mutation. Idiopathic growth hormone deficiency and retarded bone age have not been previously reported in MELAS, and these findings delayed testing for mitochondrial disease. This case demonstrates that isolated muscle weakness in the context of other organ system abnormalities should make the investigator consider MELAS. (*J Child Neurol* 2006;21:77–79).

The syndrome of mitochondrial encephalomyopathy, lactic acidosis, and stroke-like episodes (MELAS) is a well-defined mitochondrial encephalomyopathic syndrome.<sup>1</sup> This syndrome is genetically heterogeneous, with various point mutations in mitochondrial transfer ribonucleic acid and electron transport chain complexes.<sup>2–5</sup> The A3243G mutation accounts for 80% of the mutations identified in MELAS, with other abnormalities accounting for the remainder. Owing to threshold and heteroplasmy, the A3243G tRNA<sup>Leu</sup> for leucine mutation can present with distinctive features not usually associated with classic MELAS.<sup>1,6</sup> We report the unique presentation of a child presenting with severe muscle weakness–induced hypercarbia, without the other cardinal features of MELAS, with the A3243G mutation. Retrospectively, this case suggests that retarded bone maturation and idiopathic growth hormone deficiency might be associated with the A3243G mutation.

### Case Report

Our patient, an 11-year-old boy, presented with a 2-week history of upper respiratory symptoms. Prior to illness, he was an honor student and competitive chess player. He disliked physical sports and did not participate in physical education classes. His short stature and delayed bone maturation were thought to be due to isolated idiopathic growth hormone deficiency. Otherwise, his medical history was unrevealing for abnormalities. Respiratory difficulties began with an upper respiratory illness. On hospitalization, the initial examination showed a severely hypotonic boy with shallow respirations, hypnic breathing, and metabolic acidosis. His condition deteriorated, with arterial blood gases showing carbon dioxide partial pressure levels in the 70s, in the context of an upper respiratory illness. Owing to carbon dioxide partial pressure levels and breathing pattern, he was subsequently tracheally intubated with mechanical ventilation for 7 days. Echocardiography demonstrated diffuse mild cardiomyopathy. Blood work revealed severe lactic acidosis. The etiology of the respiratory illness was not found. Magnetic resonance imaging of the brain was interpreted as without abnormality. He underwent muscle biopsy, with subsequent analysis of mitochondrial electron transport chain complex enzymatic activity, electron microscopy, histologic analysis, and mitochondrial DNA testing. Before hospital discharge, a sleep study revealed obstructive sleep apnea with nighttime elevated carbon dioxide partial pressure levels, 85 to 124 mm Hg. After several months, repeat cardiac echocardiography revealed a normal functioning heart without cardiomyopathy. He was weaned off nighttime continuous positive airway pressure, with normalized carbon dioxide par-