

Short communication

Embolic internal auditory artery infarction from vertebral artery dissection

Kwang-Dong Choi, Jong-Un Chun, Moon Gu Han, Seong-Ho Park, Ji Soo Kim *

Department of Neurology, College of Medicine, Seoul National University Bundang Hospital, 300 Gumi-dong, Bundang-gu, Seongnam-si, Gyeonggi-do, 463-707, Korea

Received 14 October 2005; received in revised form 14 February 2006; accepted 15 February 2006

Available online 31 March 2006

Abstract

A 51-year-old man developed sudden vertigo, right hearing loss and dysphagia. Examination revealed right Horner syndrome, spontaneous torsional-horizontal nystagmus, right central type facial palsy, dysarthria, reduced soft palate elevation without gag reflex, left hypesthesia, right dysmetria and imbalance. Audiometry and bithermal caloric tests documented right sensorineural hearing loss and canal paresis. Brain MRI and cerebral angiography documented right lateral medullary infarction from vertebral artery dissection, without involvement of other parts of the brainstem supplied by the anterior inferior cerebellar artery (AICA). This case suggests artery-to-artery embolism as a possible mechanism of isolated vertigo or hearing loss from labyrinthine infarction.

© 2006 Elsevier B.V. All rights reserved.

Keywords: Labyrinthine infarction; Vertebral artery dissection; Embolism

1. Introduction

In infarctions in the territory of the anterior inferior cerebellar artery (AICA), vertigo or deafness is usually associated with other brainstem and cerebellar signs [1]. Occasionally, acute auditory symptoms or vertigo may precede AICA infarction [1]. As the internal auditory artery (IAA), ordinarily a branch of the AICA, irrigates the inner ear, partial ischemia of the AICA may give rise to an isolated vertigo or deafness [2,3]. However, the mechanism of isolated IAA infarction without involvement of other parts of the brainstem supplied by the AICA remains to be elucidated. We report on a patient who developed unilateral hearing loss and canal paresis possibly due to an embolism from the vertebral artery dissection.

2. Report of a case

A 51-year-old man with hypertension developed sudden vertigo, right hearing loss and dysphagia. He denied

previous history of head and neck trauma, or accompanying headache or neck pain. On admission, he had a blood pressure of 154/87 mm Hg, a pulse rate of 80 beats/min and body temperature of 37°C. In primary position, he showed counter-clockwise torsional nystagmus from a patient's point of view with a small left beating component, which was augmented in the leftward gaze. The nystagmus was changed into right beating on rightward gaze. There was no ocular lateropulsion, head tilt or skew deviation. Saccades and smooth pursuit were normal. Head thrust to the right elicited corrective catch-up saccades, suggesting right vestibular hypofunction. He also had right central type facial palsy, dysarthria and right Horner syndrome. Soft palate elevation was reduced and no gag reflex was elicited in the right side. He showed right dysmetria and gait ataxia. Pain and temperature sensations were reduced in the left face, arm and leg. The Weber test was lateralized to the left. Tympanic membranes were intact. Audiometry documented a mild sensorineural hearing loss in the right ear with intact speech discrimination (Fig. 1A). Stapedial reflexes and brainstem auditory evoked responses were normal bilaterally. Bithermal caloric stimulation disclosed a canal paresis in the right ear (72%) (Fig. 1B). The test of subjective visual vertical while binocular viewing showed rightward tilt (7.2°,

* Corresponding author. Tel.: +82 31 787 7463; fax: +82 31 719 6828.

E-mail address: jisookim@snu.ac.kr (J.S. Kim).

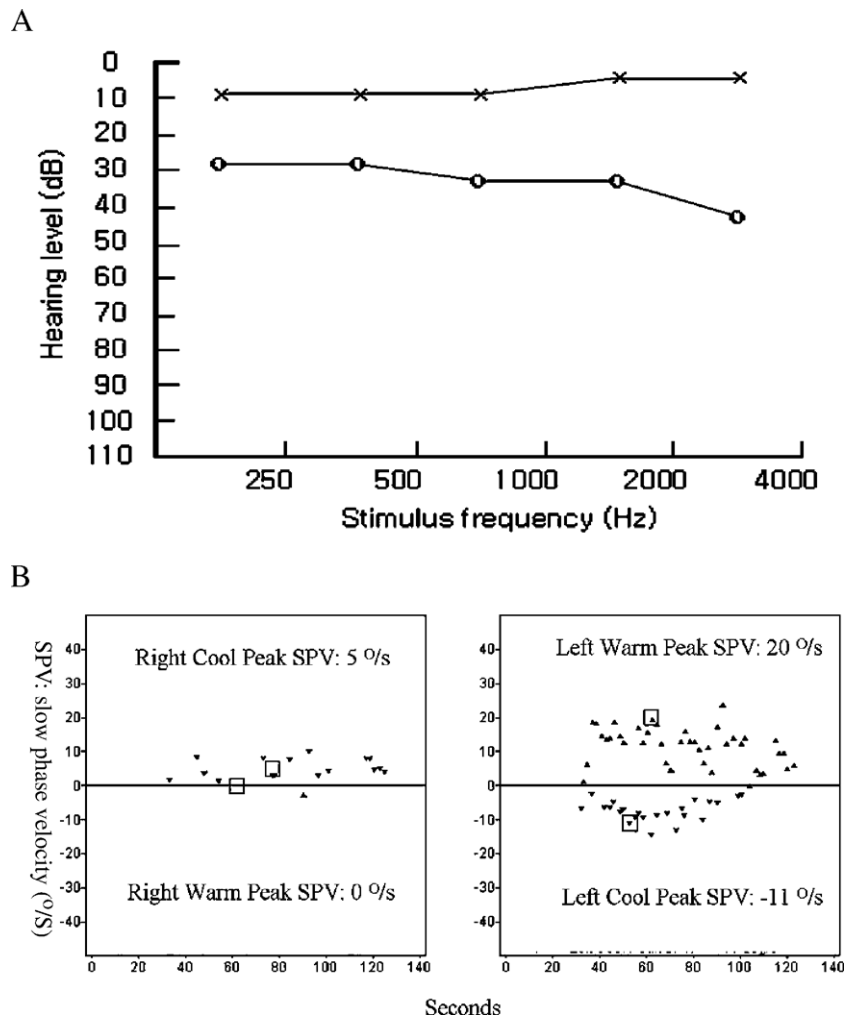


Fig. 1. (A) Pure tone audiometry demonstrates a mild sensorineural hearing loss in the right ear. The patient’s hearing levels are plotted against stimulus frequency on a logarithmic scale. Measurements were made according to the American National Standards Institute, 1989. Circles, air conduction on the right side; crosses, air conduction on the left side. (B) Video-oculographic recordings (ICS medical, IL, USA) of bithermal caloric tests show right canal paresis (72%).

normal range: -3.0° to 2.2° [4]). Fundus photography did not show abnormal ocular torsion. MRI of the brain revealed an infarction in the right lateral medulla (Fig. 2A, B). Cerebral angiography disclosed a fusiform dissecting

aneurysm in the right distal vertebral artery (Fig. 2C). No atherosclerotic narrowings were noted in other parts of the vertebrobasilar system (Fig. 2D). Intravenous heparinization was followed by oral anticoagulation with warfarin for

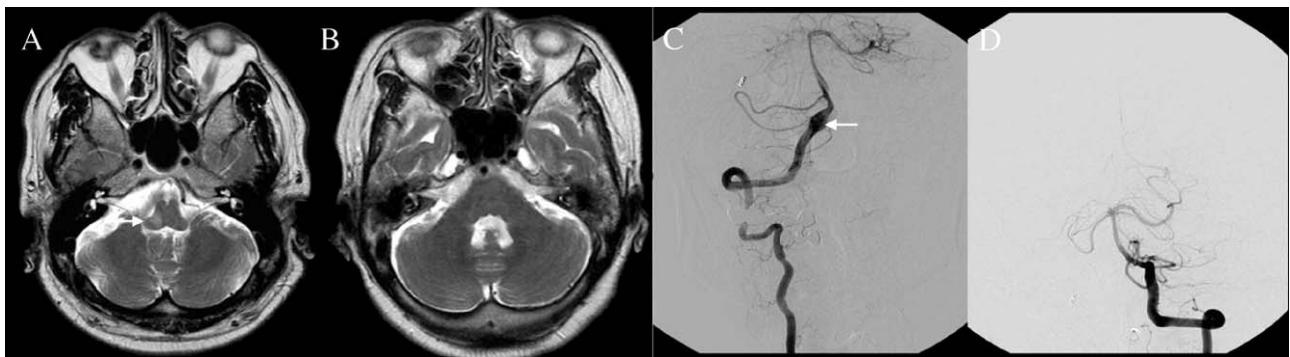


Fig. 2. MRI and cerebral angiography of the patient. (A, B) T2-weighted axial image shows right lateral medullary infarction (arrow) without involvement of other parts of the brainstem or cerebellum. (C, D) Cerebral angiography reveals a dissecting aneurysm in the right distal vertebral artery (arrow) and patent vertebrobasilar system.

6 months. The canal paresis and hearing loss were completely recovered on follow up bithermal caloric stimulation and audiometry 6 months later.

3. Comment

Sudden vertigo or deafness may occur in AICA infarction. When vertigo or hearing loss is associated with other brainstem or cerebellar signs, the diagnosis is straightforward. However, differentiation of isolated vertigo or deafness of vascular origin from other more benign disorders involving the inner ear remains a diagnostic challenge [5]. Most common mechanism of AICA infarction has been thought to be thrombotic narrowing of the AICA itself or of the basilar artery that blocks the orifice of the AICA [6]. Since the IAA, which supplies the inner ear, is a branch of the AICA and is an end artery with minimal collaterals from other major arterial branches, partial ischemia of the AICA may lead to isolated deafness or vertigo [2,3]. Previously, six of seven patients with isolated vertigo from presumed vertebrobasilar insufficiency showed atherosclerotic narrowing of the vertebral arteries that extended up to the proximal basilar artery where the AICA takes off [7]. The authors speculated that hypoperfusion of the AICA may result in labyrinthine ischemia giving rise to vertigo.

Our patient developed sudden vertigo and deafness from vertebral artery dissection. Audiological evaluation revealed mild sensorineural hearing loss in the right ear with normal stapedial reflex, speech discrimination and auditory brainstem response (ABR), and caloric test also documented a severe canal paresis in the right ear. Brain MRI showed an isolated lateral medullary infarction without any other infarctions in the AICA territory. Mild degree of hearing loss, normal speech discrimination, normal stapedial reflexes and normal BAEP indicate a cochlear damage [8]. The cochlear damage is also consistent with its high metabolic energy requirement and lack of collateral circulation [1,8]. By contrast, the retrocochlear acoustic nerve has abundant collateral blood supplies arising from the lateral medullary artery, arteries supplying adjacent dura matter and petrous bone, and the inferior lateral pontine artery [9,10]. The canal paresis of our patient is hardly explained by lateral medullary infarction, which usually involves the vestibular nucleus. In patients with central vestibular lesions, compared with those having labyrinthine damage, the degree of canal paresis is generally mild [11]. This agrees with the previous experimental studies in primates which showed that the greatest degree of canal paresis is produced by lesions in the vestibular nerve up to the level of the nerve root entry zone, where the maximum number of afferent nerve fibres from the labyrinth could be damaged [12].

There has been a few reports on isolated deafness which occurred during embolization of a meningioma [13], bilateral knee replacement [14] and cardiopulmonary bypass

surgery [15]. However, mechanisms of the deafness were not elucidated. In our patient, obvious source of emboli, infarctions involving different vascular territories and patency of the distal vertebrobasilar system without evidence of atherosclerotic change lead us to a diagnosis of embolic inner ear infarction. Our presumption is also supported by a recent report on a patient who developed unilateral sudden deafness from vertebral artery dissection [16]. In that patient, as the brain MRI revealed only a small infarction in the right posterior inferior cerebellar artery (PICA) territory, the authors postulated that small emboli originating from the dissected vertebral artery caused a small selective cerebellar and cochlear infarction, sparing the vestibular apparatus.

The IAA divides into two main branches within the internal auditory canal, the common cochlear and anterior vestibular arteries. The common cochlear artery further divides into the main cochlear and the vestibulocochlear arteries, the latter forming the posterior vestibular artery and the cochlear ramus. The anterior vestibular artery supplies the ampullae of the anterior and horizontal semicircular canals, the utricle and superior part of the saccule, while the posterior vestibular artery is the source of blood supply to the inferior part of the saccule and the ampulla of the posterior semicircular canal [3,17]. IAA mostly originates from the AICA, but it may branch off the PICA or basilar artery in a few. Our patient showed a circumscribed infarction in the lateral medulla and no other infarction was noted in the brainstem or cerebellum supplied by the basilar perforators or PICA. These findings are more consistent with an embolism from the dissecting vertebral artery.

Our patient with labyrinthine ischemia from vertebral artery dissection suggests an artery-to-artery embolism as a possible mechanism of IAA infarction. The embolism may give rise to various combinations of symptoms (isolated vertigo, isolated deafness or vertigo and deafness), depending on the branches involved.

Acknowledgement

This work was supported by Korea Research Foundation Grant (KRF-2004-003-E00202).

References

- [1] Lee H, Sohn SI, Jung DK, Cho YW, Lim JG, Yi SD, et al. Sudden deafness and anterior inferior cerebellar artery infarction. *Stroke* 2002;33:2807–12.
- [2] Perlman HB, Kimura RS, Fernandez C. Experiments on temporary obstruction of the internal auditory artery. *Laryngoscope* 1959;69: 591–613.
- [3] Kim JS, Lopez I, DiPatre PL, Liu F, Ishiyama A, Baloh RW. Internal auditory artery infarction: clinicopathologic correlation. *Neurology* 1999;52:40–4.

- [4] Kim JS, Moon SY, Kim KY, Kim HC, Park SH, Yoon BW, et al. Ocular contrapulsion in rostral medial medullary infarction. *Neurology* 2004;63:1325–7.
- [5] Grad A, Baloh RW. Vertigo of vascular origin. Clinical and electro-nystagmographic features in 84 cases. *Arch Neurol* 1989;46:281–4.
- [6] Amarenco P, Rosengart A, DeWitt LD, Pessin MS, Caplan LR. Anterior inferior cerebellar artery territory infarcts: mechanisms and clinical features. *Arch Neurol* 1993;50:154–61.
- [7] Fife TD, Baloh RW, Duckwiler GR. Isolated dizziness in vertebral-basilar insufficiency: clinical features, angiography, and follow-up. *J Stroke Cerebrovasc Dis* 1994;4:4–12.
- [8] Baloh RW, Honrubia V. *Clinical neurophysiology of the vestibular system*. 3rd ed. New York: Oxford University Press; 2001. p. 200–14.
- [9] Mazzoni A. Internal auditory canal arterial relations at the porus acusticus. *Ann Otol Rhinol Laryngol* 1969;78:797–814.
- [10] Mazzoni A. Internal auditory artery supply to the petrous bone. *Ann Otol Rhinol Laryngol* 1972;81:13–21.
- [11] Francis DA, Bronstein AM, Rudge P, du Boulay EPGH. The site of brainstem lesions causing semicircular canal paresis: an MRI study. *J Neurol Neurosurg Psychiatry* 1992;55:446–9.
- [12] Uemura T, Cohen B. Effects of vestibular nuclear lesions on vestibulo-ocular reflexes and posture in monkeys. *Acta Oto-Laryngol(Suppl 315):1–71*.
- [13] Watanabe Y, Ohi H, Shojaku H, Mizukoshi K. Sudden deafness from vertebral-basilar artery disorder. *Am J Otol* 1994;15:423–6.
- [14] Phillips JS, Prinsley PR. Sudden unilateral deafness after bilateral knee replacement. *J Laryngol Otol* 2003;117:310–1.
- [15] Wright JL, Saunders SH. Sudden deafness following cardio-pulmonary bypass surgery. *J Laryngol Otol* 1975;89:757–9.
- [16] Raupp SFA, Jellema K, Sluzewski M, de Kort PLM, Visser LH. Sudden unilateral deafness due to a right vertebral artery dissection. *Neurology* 2004;62:1442.
- [17] Mazzoni A. The vascular anatomy of the vestibular labyrinth in man. *Acta Oto-Laryngol* 1990;472:1–83 (Suppl).