

Kenneth F. Layton
J. Bradley White
Harry J. Cloft
David F. Kallmes
Edward M. Manno

Expanding the treatment window with mechanical thrombectomy in acute ischemic stroke

Received: 11 October 2005
Accepted: 20 January 2006
Published online: 4 April 2006
© Springer-Verlag 2006

K. F. Layton (✉) · H. J. Cloft ·
D. F. Kallmes
Department of Radiology, Mayo Clinic,
200 First Street SW,
Rochester, MN 55905, USA
e-mail: layton.kennith@mayo.edu
Tel.: +1-507-2840440
Fax: +1-507-2664735

J. B. White
Department of Neurosurgery
Mayo Clinic,
Rochester, MN, USA

E. M. Manno
Department of Neurology
Mayo Clinic,
Rochester, MN, USA

Abstract *Introduction:* Acute ischemic stroke is a common disease associated with high mortality and significant long-term disability. Treatment options for acute ischemic stroke continue to evolve and include pharmaceutical and mechanical therapies. With the recent US Food and Drug Administration approval of a new device for mechanical thrombectomy, the options available for treatment of acute ischemic stroke have been expanded. Thrombolytic therapy is generally given intravenously in the first 3 h and up to 6 h via the intraarterial route for pharmacological clot disruption. The maximum time-frame for mechanical thrombectomy devices has yet to be determined. *Methods:* A 78-year-old female presented to the emergency room with a dense right hemiparesis, leftward gaze preference and dense global aphasia. Eight hours after symptom onset, left carotid angiography confirmed a left internal carotid artery terminus occlusion. A single

pass was made through the clot with an X6 Merci Retriever device.

Results: After a single pass, the vessel was reopened and normal flow in the left internal carotid artery was demonstrated. At the time of discharge, her neurological deficits had improved significantly. Furthermore, the final infarct area, as demonstrated on magnetic resonance imaging, was probably much smaller than it would have been if the vessel had not been recanalized. *Conclusion:* We report the use of a new mechanical thrombectomy device 8 h after onset of ischemic symptoms, with substantial subsequent improvement in neurological outcome. In selected cases, use of the Merci Retriever can result in improved outcomes beyond the traditional 6-h window used for intraarterial pharmacological thrombolysis.

Keywords Ischemia · Stroke · Thrombolysis · Neuroradiology

Introduction

Acute ischemic stroke therapy has evolved over the recent years to include various treatment options. Until recently, treatment options included intravenous, intraarterial or combined intravenous–intraarterial thrombolysis. Prior to the advent of the Merci Retriever device (Concentric Medical,

Mountain View, Calif.), clot disruption with microwires or clot removal with loop snare devices were the only mechanical means available for clot removal. The recent introduction of the Merci Retriever device has expanded the options for treatment of acute ischemic stroke. We report a case of successful mechanical thrombectomy late in the course of acute ischemic stroke, using the Merci Retriever device.

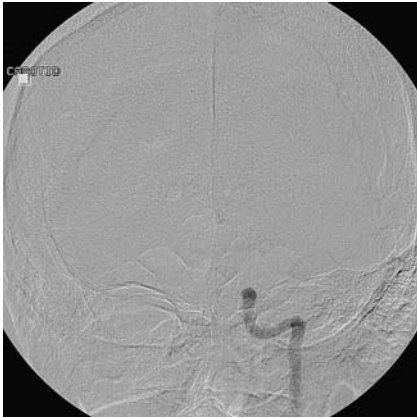

Fig. 1 A 78-year-old woman with acute-onset right hemiparesis and dense aphasia. The initial left CCA cerebral angiogram demonstrates occlusion of the ICA terminus

Methods

Clinical information

A 78-year-old, right-handed woman presented to the emergency room with a dense right hemiparesis, leftward gaze preference and dense global aphasia. She had been in her usual state of health 6 h prior to presentation, but was noted to have left-sided weakness and speech difficulties by her husband after awakening from a nap 3 h prior to presentation. A preliminary head computed tomography (CT) scan showed no evidence of intracranial hemorrhage, but there was evidence of early ischemic change involving the left insular region.

Technical note

The patient was taken to the angiography suite, where a left common carotid artery (CCA) angiogram revealed an internal carotid artery (ICA) terminus occlusion of the left ICA (Fig. 1). Right CCA angiography demonstrated cross-filling of the left

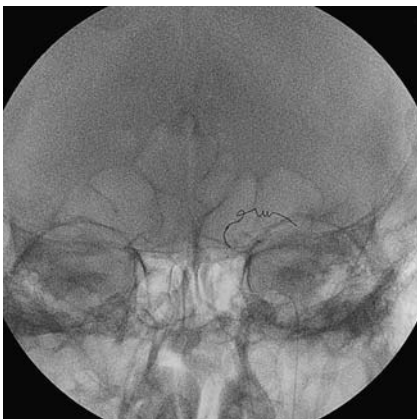


Fig. 2 An anterior-posterior image demonstrates the device deployed in the left M1 MCA segment

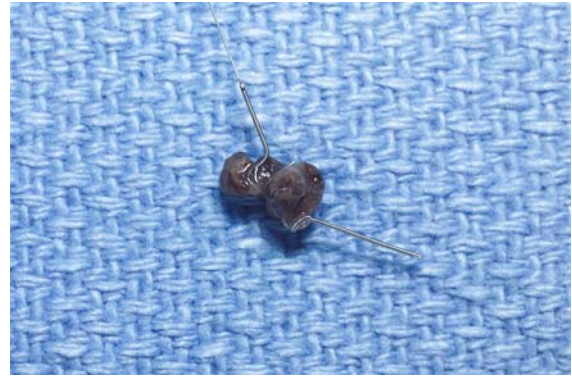


Fig. 3 A high-resolution image demonstrates the extracted clot entrapped within the loops of the Merci Retriever

anterior cerebral artery territory, but there was limited collateral flow to the left middle cerebral artery (MCA) territory. At this time, the patient was approximately 8 h out from her last known normal clinical state, which was beyond the window for thrombolytic therapy based upon clinical guidelines.

A 9F Merci Balloon catheter (Concentric Medical) was placed in the left CCA. Using the X6 Merci Retriever device (Concentric Medical), a single pass was made through the left M1 MCA portion of the clot (Fig. 2). A large piece of clot was noted within the retriever device after removal (Fig. 3). A subsequent left CCA angiogram revealed complete restoration of flow in the left anterior circulation, without evidence of residual clot or distal emboli (Fig. 4). The device was removed and a Perclose Proglide device (Abbott Laboratories, Abbott Park, Ill.) was used to achieve hemostasis of the arterial access site.

Results

A follow-up head magnetic resonance imaging (MRI) scan 2 days after the procedure revealed an acute infarct in the

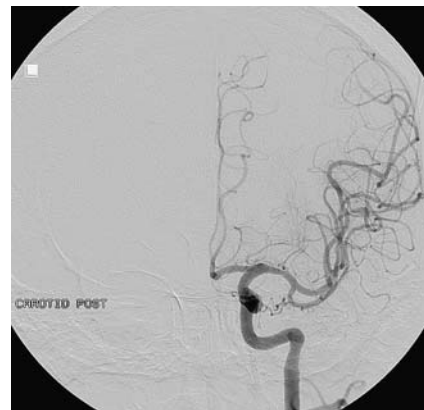

Fig. 4 After clot extraction, a follow-up anterior-posterior left CCA angiogram demonstrates restoration of normal flow in the anterior circulation

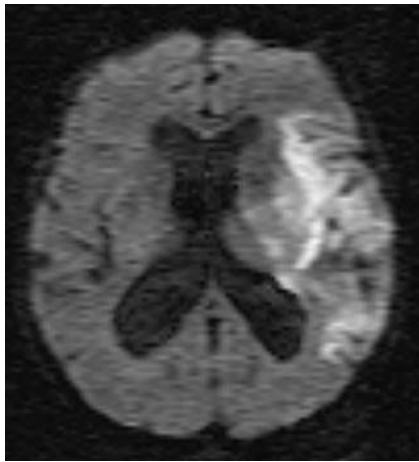


Fig. 5 Diffusion-weighted MRI image 2 days after thrombectomy reveals a limited left MCA territory infarct

left temporoparietal region and insula that was much smaller than would have been expected if thrombectomy had not been performed (Fig. 5). Pathological evaluation of the extracted clot revealed a recent fibrin thrombus. Nine days after the thrombectomy, the patient was discharged to a rehabilitation center. At the time of discharge, she had regained mobility of her right side and improved her language deficit to a moderate expressive aphasia.

Discussion

Mechanical thrombectomy with the Merci Retriever device can extend the window for treatment in acute ischemic stroke beyond the traditional 3-h intravenous and 6-h intraarterial thrombolytic guidelines. Large-vessel ischemic strokes have a particularly poor prognosis, with high mortality [1, 2]. Improved outcomes have been documented for patients treated with intravenous or intraarterial thrombolytics [3, 4]. Unfortunately, many patients are not candidates for thrombolytic therapy. Recent results from the Mechanical Embolus Removal in Cerebral Ischemia

(MERCİ) trial have demonstrated the safety and efficacy of an endovascular device (Merci Retriever) in restoring the patency of occluded intracranial vessels [5]. In this study, 48% of occluded intracranial vessels were successfully revascularized, and revascularization was found to be an independent predictor of neurological outcome and mortality. Based on the MERCİ trial results, US Food and Drug Administration clearance for the Merci Retriever was granted in 2004 for acute stroke patients who are ineligible for intravenous tissue plasminogen activator (tPA), or in whom intravenous tPA treatment has failed. The combined use of mechanical thrombectomy with intravenous and/or intraarterial thrombolysis is less well defined, and additional investigations are necessary to study the effectiveness of combined therapy in the treatment of acute ischemic stroke. In addition, the acceptable time-frame for treating acute ischemic strokes with this new device still needs to be determined. As with thrombolytic therapy, the use of CT or MRI perfusion studies prior to mechanical thrombectomy may be useful in the evaluation and treatment planning of acute ischemic strokes. Further studies are necessary to establish guidelines for the treatment of acute ischemic stroke, especially when relying upon a CT or MRI perfusion mismatch to initiate endovascular therapy with the Merci Retriever device.

The restoration of cerebral blood flow remains a technical challenge in the acute stroke setting, despite the numerous modalities that are available. In this patient, successful recanalization was achieved relatively late in the course of her stroke. Although the patient still had a significant deficit, her outcome would probably have been much worse without intervention. As demonstrated in this report, mechanical thrombectomy can be performed successfully later in the course of an acute ischemic stroke and provide for improved clinical outcome. As practitioners gain further experience with this device, the time limitations for instituting treatment, with or without the use of adjunctive thrombolytic therapy, will hopefully become clearer.

The authors have control of the data. None of the authors has any financial disclosures to make concerning the devices used in this study.

References

1. Hacke W, Schwab S, Horn M, Spranger M, De Georgia M, von Kummer R (1996) "Malignant" middle cerebral artery territory infarction: clinical course and prognostic signs. *Arch Neurol* 53:309–315
2. Jansen O, von Kummer R, Forsting M, Hacke W, Sartor K (1995) Thrombolytic therapy in acute occlusion of the intracranial internal carotid artery bifurcation. *AJNR Am J Neuroradiol* 16:1977–1986
3. Furlan A, Higashida R, Wechsler L, et al (1999) Intra-arterial prourokinase for acute ischemic stroke. The PROACT II study: a randomized controlled trial. *Prolyse in acute cerebral thromboembolism*. *JAMA* 282:2003–2011
4. The National Institute of Neurological Disorders and Stroke rt-PA Stroke Study Group (1995) Tissue plasminogen activator for acute ischemic stroke. *N Engl J Med* 333:1581–1587
5. Smith WS, Sung G, Starkman S, et al (2005) Safety and efficacy of mechanical embolectomy in acute ischemic stroke: results of the MERCİ trial. *Stroke* 7:1432–1438