

C. Rabe^{1*}
 Z. Balta^{1*}
 U. Wüllner²
 J. Heller¹
 C. Hammerstingl³
 K. Tiemann³
 T. Sommer⁴
 M. Schepke¹
 H.-P. Fischer⁵
 T. Sauerbruch¹

Biliary Metal Stents and Air Embolism: A Note of Caution

Metal stents are a valuable treatment modality for patients with biliary obstruction. However, we present here two patients whose cases may serve as a warning about an unusual complication associated with these stents. We encountered this complication after endoscopic retrograde cholangiography for obstructed metal biliary stents. The first patient, an 87-year-old man with a benign biliary stricture, failed to regain consciousness after clearing of his stent using a Dormia basket and balloon catheter. Cerebral air embolism was diagnosed on cerebral computed tomography, and transesophageal echocardiography revealed a patent foramen ovale as a precipitating factor for paradoxical air embolism. He survived and was discharged with a residual hemiparesis. In the second patient, a 54-year-old man

who had a history of a Billroth II operation and chronic pancreatitis and who had a portal cavernoma with biliary obstruction due to collateral veins, electromechanical dissociation complicated the balloon-catheter stent revision. Echocardiography performed during cardiopulmonary resuscitation showed major air embolism to the right heart. The patient died. These cases demonstrate that air may gain access to the venous system during therapeutic endoscopic procedures of this type. It is likely that the large diameter of metal stents and the potential for these stents to lacerate venous structures facilitate the entry of air into the venous circulation, an event which may have life-threatening consequences.

Introduction

Metal stents have been an important advance in the bridging of biliary stenoses. The large diameter of these prostheses guarantees prolonged patency compared with plastic stents [1]. However, the large diameter can also allow for easy passage of insufflated air through the stent. We present here two cases of air embolism occurring during endoscopic retrograde cholangiography (ERC) that may have been facilitated by metal stents.

Case Reports

Patient 1

An 87-year-old man, who had been in excellent health apart from a transient cerebral ischemic episode 1 year earlier, presented with recurrent obstruction of a metal biliary stent. This stent had been placed 15 months earlier to bridge a distal choledochal stenosis caused by an adenoma of the distal bile duct. On ERC, the stent was found to be partially obstructed and the obstructing debris were removed using a Dormia basket and balloon catheter. The procedure was performed under light sedation

Institution

¹ Department of Medicine I, University of Bonn, Bonn, Germany

² Department of Neurology, University of Bonn, Bonn, Germany

³ Department of Medicine II, University of Bonn, Bonn, Germany

⁴ Department of Radiology, University of Bonn, Bonn, Germany

⁵ Department of Pathology, University of Bonn, Bonn, Germany

Remark

* These authors contributed equally to this work

Corresponding Author

C. Rabe, M.D. · Department of Medicine I · University of Bonn · Sigmund-Freud-Strasse 25 · D-53105 Bonn · Germany · Fax: +49-228-287-4698 · E-mail: rabe@uni-bonn.de

Bibliography

Endoscopy 2006; 38 (6): 648–650 © Georg Thieme Verlag KG Stuttgart · New York · DOI 10.1055/s-2006-925053 · Published online 8 February 2006 · ISSN 0013-726X

(5 mg midazolam, 50 mg pethidine). The patient failed to regain consciousness after ERC despite the administration of flumazenil and naloxone. Two hours after the ERC, computed tomography was performed, which showed air within the parenchyma of the right hemisphere of the brain (Figure 1a). Diffusion-weighted magnetic resonance imaging (not shown) suggested cerebral infarction about 10 hours after the endoscopic procedure.

The patient was placed on high-dose oxygen via a facemask, but his condition deteriorated, his airway-protective reflexes were lost, and a left-sided hemiparesis became evident. He was intubated in order to protect his airway. Follow-up cerebral computed tomography after 2 days showed that the intracerebral air had dissolved. Transesophageal echocardiography demonstrated a patent foramen ovale with a right-to-left shunt (Figure 1b). The patient was weaned from mechanical ventilation over the course of 1 month, and his cognitive functions recovered largely. Magnetic resonance imaging 15 days after the air embolism revealed edema of the right hemisphere without destruction of the cortex (Figure 1c). The patient refused to undergo closure of the patent foramen ovale and was started on low-molecular-weight heparin to prevent the formation of further emboli. He was transferred to a rehabilitation unit, with a residual hemiparesis.

Patient 2

A 54-year-old man, an alcoholic, presented to us with a history of a Billroth II operation, chronic pancreatitis, and diabetes mellitus. He had had a metal stent placed 2 years earlier to treat biliary obstruction caused by chronic pancreatitis, and at that time choledochal varices due to portal vein cavernoma after portal vein thrombosis were diagnosed (Figure 2a). He now presented with obstruction of the stent and underwent therapeutic ERC. A stenosis seen at and above the stent during ERC (Figure 2b) was dilated using a balloon catheter. After the dilation, however, he began to bleed briskly and he suffered a cardiorespiratory arrest. Cardiopulmonary resuscitation was started immediately. His electrocardiogram showed electromechanical dissociation. When adequate volume resuscitation failed to reverse the electromechanical dissociation, echocardiography was performed while cardiopulmonary resuscitation was continued. This showed air in the right ventricle (Figure 2c). A long central venous catheter was advanced into the right ventricle in an attempt to remove the air, but this was unsuccessful, and the patient died. At autopsy, about 20 ml of air was found in the right heart, and the pathologist also found a small tear at the upper edge of the bile duct which had access to the adjacent venous collaterals.

Discussion

Air embolism is an exceedingly rare complication of gastrointestinal endoscopy. It requires entry of air into the venous circulation and, in the case of cerebral embolism, a mechanism for the air to pass into the arterial circulation. Because air is introduced into the gastrointestinal tract through the endoscope at relatively high pressures of up to 43kPa and at a high flow of up to 2000 ml/minute [2,3], it is perhaps not surprising that it may inadvertently enter the venous circulation [4].

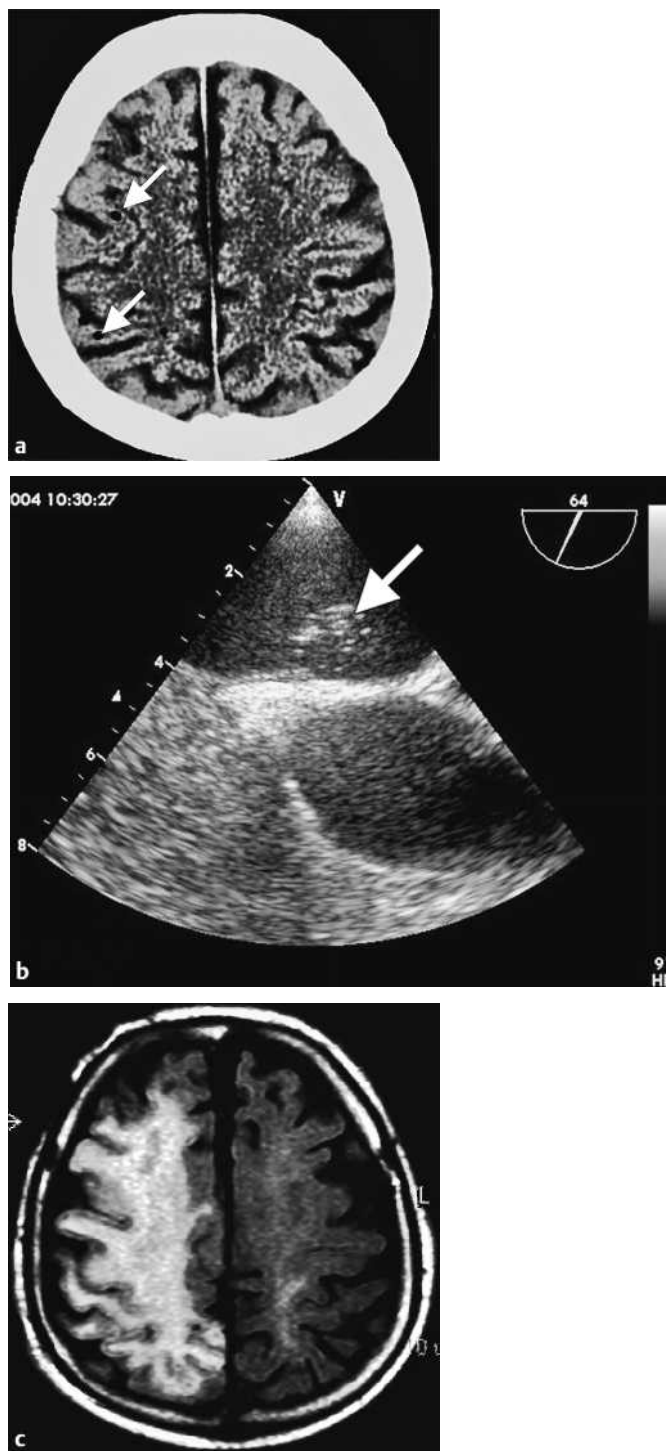


Figure 1 Patient 1. **a** Computed tomography showed air bubbles in the brain parenchyma (arrows). **b** Transesophageal contrast echocardiography demonstrated a patent foramen ovale with a spontaneous right-to-left shunt, shown by the bubbles of Echovist contrast (Schering, Berlin, Germany) entering the left atrium (arrow). **c** Magnetic resonance imaging with an axial FLAIR sequence 15 days after the air embolism showed edema of the right hemisphere.

In both of our patients, air may have entered the biliary system through the metal stent and then gained entry into the hepatic venous system or into venous collaterals, possibly through small injuries caused by manipulation of the instruments (Dormia basket, balloon catheter) used to restore the stent's patency. We believe that the large caliber of metal stents facilitates this air en-

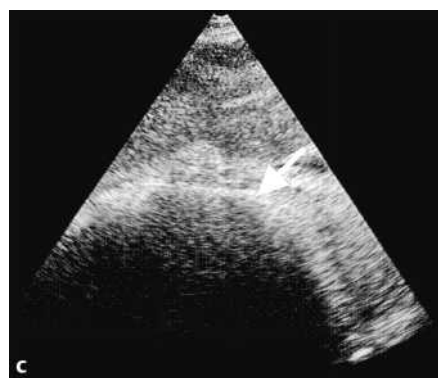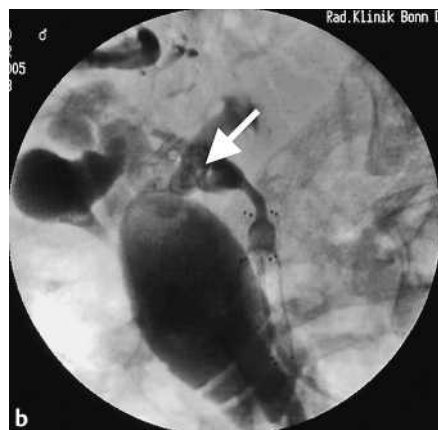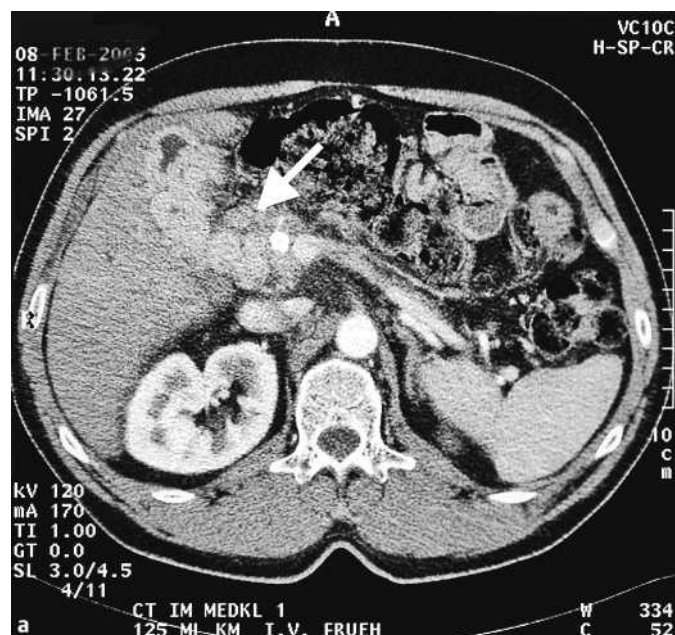


Figure 2 Patient 2. **a** Computed tomography showed multiple large venous collaterals (arrow) in proximity to the biliary system. **b** At endoscopic retrograde cholangiography, a fistula (arrow) was seen extending from the bile duct at the proximal edge of the stent into the cavernous vessels; the stent is blocked by a balloon catheter. At the same time, the common hepatic duct is not visualized. **c** Echocardiography: subcostal view with characteristic pattern of massive air embolism. Note the substantial acoustic shadowing adjacent to the right ventricular free wall (arrow).

try. Under normal circumstances, most air will either be trapped in the liver or in the lung. If the pulmonary capillary filter is overwhelmed by large amounts of insufflated air [5], however, or circumvented via a right-to-left shunt (as occurs with a patent foramen ovale), it is possible for air to pass into the arterial system.

In our second patient, air clearly had access from the common bile duct into the venous collaterals that bypassed the liver. As we could not detect the exact location of the fistula which allowed passage of air into the venous system in the first patient, we speculate that manipulation during endoscopy may have caused a small injury to a hepatic vein.

If the amount of air is large enough, cardiac function is compromised. Emergency treatment aims to remove air from the right heart by introducing a catheter and suctioning. Unfortunately, this did not lead to clinical improvement in our second patient.

In the treatment of cerebral air embolism, anecdotal reports have described the use of measures such as high-dose oxygen [6], pressure chambers, and anticoagulation [7]. However, there are no controlled data suggesting that these therapies (especially pressure-chamber therapy, nevertheless several case reports advocate this measure) are superior to supportive care [8]. In our first patient, we applied mechanical ventilation with a high fraction of inspired oxygen in the hope of speeding up the dissolution of air bubbles in the brain. This may have accelerated the disappearance of air bubbles that was shown by serial cerebral computed tomographic scans.

In conclusion, air embolism is a rare cause of cardiopulmonary and/or neurological dysfunction following endoscopic procedures. In many cases massive systemic air embolism to the right heart will be fatal, and, although cerebral air embolism is theoretically reversible, persistent neurological deficits are common in those patients who survive.

References

- 1 Neuhaus H, Schumacher B. Use of metal stents in gastroenterology [in German, abstract in English]. *Z Gastroenterol* 1998; 36: 121–134
- 2 Katzgraber F, Glenewinkel F, Rittner C, Beule J. Fatal air embolism resulting from gastroscopy. *Lancet* 1995; 346: 1714–1715
- 3 Katzgraber F, Glenewinkel F, Fischler S, Rittner C. Mechanism of fatal air embolism after gastrointestinal endoscopy. *Int J Legal Med* 1998; 111: 154–156
- 4 Herron DM, Vernon JK, Gyska PV, Reines HD. Venous gas embolism during endoscopy. *Surg Endosc* 1999; 13: 276–279
- 5 Butler BD, Hills BA. Transpulmonary passage of venous air emboli. *J Appl Physiol* 1985; 59: 543–547
- 6 Akhtar N, Jafri W, Mozaffar T. Cerebral artery air embolism following an esophagogastrosocopy: a case report. *Neurology* 2001; 56: 136–137
- 7 Raju GS, Bendixen BH, Khan J, Summers RW. Cerebrovascular accident during endoscopy: consider cerebral air embolism, a rapidly reversible event with hyperbaric oxygen therapy. *Gastrointest Endosc* 1998; 47: 70–73
- 8 Heckmann JG, Lang CJ, Kindler K et al. Neurologic manifestations of cerebral air embolism as a complication of central venous catheterization. *Crit Care Med* 2000; 28: 1621–1625