

# Cervical herpes zoster and delayed brainstem infarction

J. Willeit, and E. Schmutzhard\*

## Introduction

Delayed contralateral hemiparesis following herpes zoster ophthalmicus (HZO) is a well-defined syndrome<sup>1-4</sup>; over 50 cases have been reported. The pathogenesis remained controversial until histological evidence of arteritis<sup>4-7</sup> suggested either direct viral invasion of the vessels or a postinfectious immunological reaction<sup>8-11</sup>. Angiography in some patients has shown segmental narrowing of ipsilateral cerebral arteries<sup>4,12</sup>, and computerized tomography has shown lesions in the internal capsule or in the hemispheric cortex, consistent with infarction<sup>3,4,13,14</sup>. We describe the first case, to our knowledge, with brainstem infarction following cervical herpes zoster.

## Case history

A 54-year-old female was in excellent health until April 1987 when she developed burning and shooting pains in the left occipital region. On examination she showed a papulovesical erythema within the dermatomata C2 and C3 on the left side, consistent with segmental herpes zoster. No abnormal neurological signs and symptoms were present at that time. All routine laboratory tests were normal. The skin lesions and the local pains began to resolve without specific therapy after two weeks.

Six weeks later, the patient was admitted to

## Summary

Varicella-zoster (VZ) virus is a rare cause of CNS angiitis, which commonly presents as herpes zoster ophthalmicus with contralateral hemiplegia due to hemispheric infarction. We report the first case of VZ-angiitis with infarction in the ventral pons, following cervical herpes zoster.

Key words: Varicella-zoster virus, angiitis, cerebral infarction.

our service because of sudden onset of dizziness, unsteadiness of gait, double vision and tinnitus. Neurological examination showed a left abducens and facial nerve palsy and a right sided hemiparesis (Foville-Millard-Gubler Syndrome). The neurological deficit progressed to a full locked-in-syndrome in the next two days, with complete impairment of horizontal gaze, pseudobulbar paralysis and tetraplegia<sup>15</sup>. The plantar response was extensor bilaterally. Additional investigations of serum complement, immunoglobulins, cryoglobulins, antinuclear antibodies, and rheumatoid factor were normal.

Chest X-ray and ECG did not show any abnormalities. The CSF was clear, glucose and protein were normal, the cell count was 23 lymphocytes/mm<sup>3</sup>. CSF-IgG was 18 mg/100 ml (normal, 3 to 6 mg/100 ml). Isoelectric focusing of CSF protein demonstrated a polyclonal pattern

\*Department of Neurology, University of Innsbruck, Austria

Address for correspondence and reprint requests: Dr. J. Willeit, Univ.-Klinik für Neurologie, Anichstraße 35, A-6020 Innsbruck, Austria.

Accepted 2-10-90

Clin Neurol Neurosurg 1991. Vol. 93-3

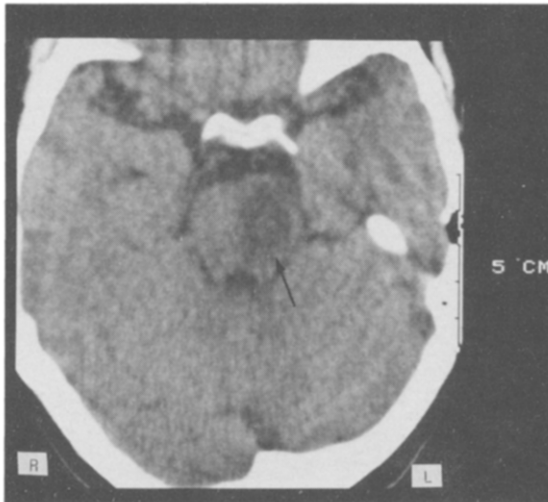


Figure 1: CT scan showing a hypodense lesion (←) in the pons consistent with recent infarction.

with few oligoclonal bands. The HVZ complement fixation titers were 1:256 in blood (normal, less than 1:16) and 1:64 in CSF (normal, less than 1:2). CT scanning showed a hypodense area within left side of the central part of the pons, consistent with recent infarction (Fig. 1). Cerebral panangiography did not reveal any arterial occlusion or narrowing. Treatment with high doses corticosteroids and acyclovir (2000 mg daily for a total period of ten days) induced regression of the clinical deficits, but a mild spastic tetraparesis remained, most marked on the right side. A repeat CT-scan showed a cystic hypodense area in the ventral part of the pons. The HVZ complement fixation titers decreased to 1:32 in blood and 1:4 in CSF after 3 months.

## Discussion

Up to now, cerebral angiitis after herpes zoster has been described mainly in cases of HZO-associated hemiparesis<sup>1-4, 10-14</sup>. After an interval of 1 to 8 weeks subacute or acute contralateral hemiparesis develops, as a result of infarction in the territory of the homolateral arteria cerebri media. Angiography, usually, shows narrowing of intracranial arteries<sup>3,4,12</sup>. In several instances, histological examination has shown granulomatous angiitis<sup>5-6</sup>; on two occasions necrotizing vasculitis of smaller perforating arteries was found<sup>4,7</sup>.

The VZ virus probably induces cerebral arteritis. Zinnemann et al<sup>8</sup> and Dyole et al<sup>10</sup> on electronmicroscopy found virus-like intranuclear particles within the vascular muscle cells. Virus isolation has not yet been achieved; however, virus antigen was demonstrated to be present in the vessel wall<sup>11</sup>. Several authors have proposed that HZO-associated angiitis is the result of spread of virus along the trigeminal nerve, from the affected semilunar ganglion to the neighbouring blood vessels<sup>8-11</sup>. In some patients however, involvement of vascular structures not known to be innervated by trigeminal nerve branches was found. Hilt et al<sup>4</sup>, at post mortem examination four months after the onset of HZO-associated hemiparesis, detected a necrotizing angiitis with focal infarction not only in the cerebral hemisphere, but also in the brainstem. In such patients, dissemination via CSF pathways or a post-infectious autoimmune reaction must be considered. In our case, cutaneous cervical herpes zoster infection was followed by a brainstem infarction after six weeks. As in the case reported by Economou<sup>16</sup> involvement of the vertebrobasilar branches might have occurred by propagation of virus via perivascular pathways or via the CSF. In the Economou case, the clinical signs consisted in an asynchronously developing contralateral hemiparesis and ipsilateral Bell's palsy following herpes zoster of the left brachial plexus. In our case, arteritis of the perforating smaller branches of the basilar artery has to be assumed.

The mortality of HVZ-associated cerebral angiitis in published cases is approximately 20%<sup>3</sup>. Treatment is still controversial. Hilt et al<sup>4</sup> used corticosteroids and acyclovir without success, whereas other authors saw improvement with corticosteroids and anticoagulation therapy<sup>2</sup>, acyclovir<sup>17</sup>, or platelet aggregation inhibiting drugs<sup>18</sup>. As in our case, the clinical remission may have been spontaneous. The efficacy of acyclovir in cutaneous herpes zoster is beyond doubt<sup>19</sup>. Even the incidence of ocular and/or CNS complications of acute herpes zoster infection can be reduced by early therapy<sup>20</sup>. Whether postherpetic angiitis can be prevented by specific antiviral treatment has yet to be proved.

## References

- 1 ANASTOSOPOULOS F, ROUTSOMAS K, IERODIAKONOU CS. Ophthalmic herpes zoster with contralateral hemiplegia. *J Neurol Neurosurg Psychiatry* 1958; 21:210-2.
- 2 GILBERT GJ. Herpes zoster ophthalmicus and delayed contralateral hemiparesis. *JAMA* 1974; 299:302-4.
- 3 RESHEF E, GREENBERG SB, JANKOVIC J. Herpes zoster ophthalmicus followed by contralateral hemiparesis: report of two cases and review of the literature. *J Neurol Neurosurg Psychiatry* 1985; 48:122-7.
- 4 HILT DC, BUCHHOLZ D, KRUMHOLZ A, WEISS H, WOLINSKY JS. Herpes zoster ophthalmicus and delayed contralateral hemiparesis caused by cerebral angiitis: Diagnosis and management approaches. *Ann Neurol* 1983; 14:543-553.
- 5 KOLODNY EH, REBEIZ JJ, CAVINESS VS, RICHARDSON EP. Granulomatous angiitis of the central nervous system. *Arch Neurol* 1968; 19:510-4.
- 6 ROSENBLUM WI, HADFIELD MG. Granulomatous angiitis of the nervous system in cases of herpes zoster and lymphosarcoma. *Neurology (Minneap)* 1972; 22:348-54.
- 7 GASPERETTI C, SONG SK. Contralateral hemiparesis following herpes zoster ophthalmicus. *J Neurol Neurosurg Psychiatry* 1985; 48:338-41.
- 8 LINNEMANN CC, ALVIRA MM. Pathogenesis of varicella-zoster angiitis in the central nervous system. *Arch Neurol* 1980; 37:239-40.
- 9 REYES MG, FRESCO R, CHOKRVERTY S, SALUD EQ. Virus-like particles in granulomatous angiitis of the central nervous system. *Neurology (Minneap)* 1976; 26:797-9.
- 10 DOYLE PW, GIBSON G, DOLMAN CL. Herpes zoster ophthalmicus with contralateral hemiplegia: Identification of cause. *Ann Neurol* 1983; 14:84-5.
- 11 EIDELBERG D, SORTEL A, HOROUPIAN DS, NEUMANN PE, PUMAROLA-SUNE T, PRICE RW. Thrombotic cerebral vasculopathy associated with herpes zoster. *Ann Neurol* 1986; 19:7-14.
- 12 MACKENZIE RA, FORBES GS, KARNES WE. Angiography findings in herpes zoster arteritis. *Ann Neurol* 1981; 458-64.
- 13 VECHT CHJ, VAN DE SANDE JJ. Hemispheric infarction after herpes zoster ophthalmicus. *Neurology (NY)* 1982; 32:914.
- 14 KUROIWA Y, FURUKAWA T. Hemispheric infarction after herpes zoster ophthalmicus: Computed tomography and angiography. *Neurology (NY)* 1981; 31:1030-2.
- 15 BAUER G, GERSTENBRAND F, RUMPL E. Varieties of the locked-in syndrome. *J Neurol* 1979; 221:77-91.
- 16 ECONOMOU PG. Hemiparesis and Bell's palsy following brachial plexus herpes zoster. *JAMA* 1984; 252:1012.
- 17 BOOSS J, HAAK BB, LEROY RF. Delayed contralateral hemiplegia following herpes zoster ophthalmicus: Should antiviral therapy be used? *Eur Neurol* 1985; 24:225-38.
- 18 LANDI G, CALLONI MV, SCALATO G. Transient contralateral hemiplegia after ophthalmic zoster: Therapeutic problems in elderly patients. *J Neurol* 1981; 224:297-300.
- 19 BEAN B, BRAUN C, BALFOUR HH. Acyclovir therapy for acute herpes zoster. *Lancet* 1982; 17:118-21.
- 20 STRAUSS SE. Varicella-zoster virus infection. Biology, natural history, treatment, and prevention. *Ann Intern Med* 1988; 221:37.