

Alejandro Horga Hernández  
Francesc Pujadas  
Francisco Purroy  
Pilar Delgado  
Rafael Huertas  
José Álvarez-Sabín

## Upside down reversal of vision due to an isolated acute cerebellar ischemic infarction

Received: 1 October 2005  
Received in revised form:  
14 December 2005  
Accepted: 22 December 2005  
Published online: 20 April 2006

Sirs: Room tilt illusion (RTI) is a spatial perception disorder characterized by a transient 90- or 180-degree rotation of the visual field in the coronal plane, not associated with other perceptive distortions [1]. Cases with 180° distortion have also been described as “reversal of vision metamorphopsia” or “upside-down reversal of vision” [2, 3]. RTI has been described in association with peripheral, brainstem or cortical injuries [3–5]. There have been reports of cases previously that have suggested a causal relationship between RTI and an isolated cerebellar ischemic lesion, but they made use of neuroimaging techniques performed several days after the RTI event [3, 6]. We describe a patient who presented with an RTI episode that was attributable to an acute cerebellar infarction, as revealed by early neuroimaging studies.

A 60-year-old man was admitted to hospital because of transient tilt perception of the visual image and truncal ataxia. Just a few hours before the admission, he suddenly noted upside-down reversal of vision during a flight. The visual distortion lasted for three minutes,

and involved the seating lines and people on the flight, but not the perception of his own body position. Afterwards, the patient noticed that he was dizzy and unable to maintain an upright position while standing or walking. Once the plane had landed, he went to hospital.

Neurological examination showed severe truncal ataxia and skew deviation with hypotropia of the right eye. Results of the examination were otherwise normal. He had never had a similar episode previously. He had been a smoker and his medical history included arterial hypertension, atrial flutter and a head injury during childhood, the latter not having any neurological sequelae. The patient was being treated with atenolol, enalapril, hydrochlorothiazide and acetylsalicylic acid.

Results of chest radiography, electrocardiography, laboratory tests and ultrasonographic examination of carotid arteries were unremarkable. Computed tomography of the head performed during the first 24 hours after the RTI event disclosed signs of an acute ischemic cerebellar lesion. Magnetic resonance imaging (MRI) performed within 48 hours of the

RTI episode revealed signs of an isolated and acute ischemic cerebellar infarct without bulbar involvement in the territory of the right posterior inferior cerebellar artery on diffusion-weighted MRI (DWI-MRI) (Fig. A), and chronic encephalomalacic areas in both frontal lobes. MR angiography showed an occlusion of the right vertebral artery (Fig. B). During admission, the patient did not report any perceptive disorder.

The present case establishes: 1) a close temporal relationship between RTI and acute ischemic cerebellar infarction, and 2) a localized cerebellar lesion as the most probable anatomical substrate for the malfunction that led to the perceptive disorder. To our knowledge, this is the first clinical observation to suggest a probable causal connection between an acute isolated lesion in the posterior fossa and an RTI episode with the support of early DWI-MRI findings. On the other hand, although commonly attributed to brainstem lesions [7], skew deviation can also be caused by isolated cerebellar lesions, as has been demonstrated recently [8]. Thus, both the RTI and the skew deviation phenomena were probably the

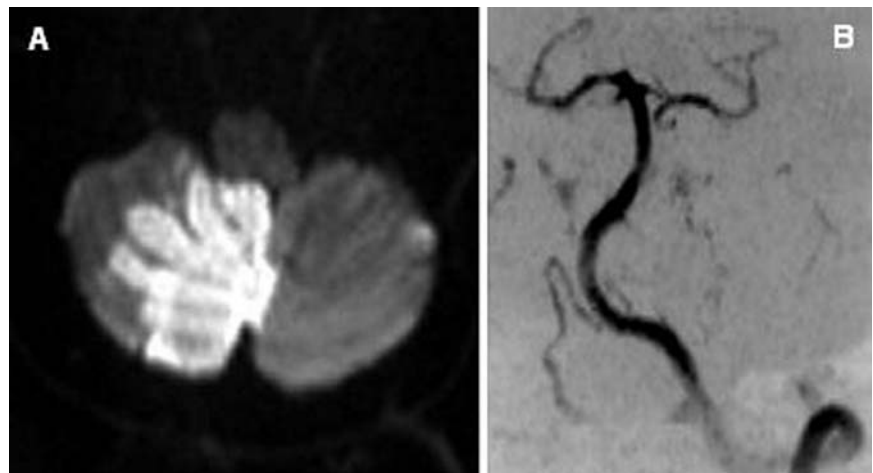


Fig.

consequence of the cerebellar infarction in our patient.

The perception of spatial orientation relies on visual, vestibular and proprioceptive inputs integrated at higher-level cortical networks. Visual and vestibular senses provide signals to create two distinct three-dimensional coordinate maps. It is probable that the perceptive integration process aligns both spatial maps in order to generate a valid representation of the visual scene, and a unique perception of verticality [1]. We propose that in this case the most plausible pathophysiological mechanism of RTI was an acute dysfunction of vestibulo-cerebellar pathways, which modified the otolithic basal input and caused a transient mismatch between the visual and vestibular coordinate maps. Since skew deviation is due to asymmetric disruption of central otolithic pathways [7], its coexistence with RTI in this patient supports an

otolithic inflow distortion [8, 9]. The continuous integration process of visual, vestibular and proprioceptive information was probably responsible for the recovery.

## References

1. Brandt T (1997) Cortical matching of visual and vestibular 3D coordinate maps. *Ann Neurol* 42:983–984
2. Steiner I, Shahin R, Relamed E (1987) Acute “upside down” reversal of vision in transient vertebrobasilar ischaemia. *Neurology* 37:1685–1686
3. River Y, Ben Hur T, Steiner I (1998) Reversal of vision metamorphopsia: clinical and anatomical characteristics. *Arch Neurol* 55:1362–1368
4. Arias M, Lema C, Requena A, Soto A, Pereiro I, Nunez J (2001) Inverted metamorphopsia: an alteration in the perception of a spatial situation of objects. *Neurologia* 16:149–153
5. Malis DD, Guyot JP (2003) Room tilt illusion as a manifestation of peripheral vestibular disorders. *Ann Otol Rhinol Laryngol* 112:600–605
6. Charles N, Froment C, Rode G, et al. (1992) Vertigo and upside down vision due to an infarct in the territory of the median branch of the posterior inferior cerebellar artery caused by dissection of a vertebral artery. *J Neurol Neurosurg Psychiatry* 55:188–189
7. Brandt T, Dieterich M (1994) Vestibular syndromes in the roll plane: topographic diagnosis from brainstem to cortex. *Ann Neurol* 36:337–347
8. Wong AM, Sharpe JA (2005) Cerebellar skew deviation and the torsional vestibuloocular reflex. *Neurology* 65:412–419
9. Tiliket C, Ventre-Dominey J, Vighetto A, Grochowicki M (1996) Room tilt illusion. A central otolith dysfunction. *Arch Neurol* 53:1259–1264

Dr. A. Horga Hernández (✉) · F. Pujadas, MD · F. Purroy, MD, PhD · P. Delgado, MD · R. Huertas, MD · J. Álvarez-Sabín, MD, PhD  
Department of Neurology  
Hospital de la Vall d’Hebron  
Passeig Vall d’Hebron 119–129  
08035, Barcelona, Spain  
Tel.: + 34-93/4894257  
Fax: + 34-93/4894257  
E-Mail: ahorga@comb.es