

## Absence epilepsy associated with moyamoya disease

### Case report

**KEN-ICHIRO KIKUTA, M.D., PH.D., YASUSHI TAKAGI, M.D., PH.D.,  
YOSHIKI ARAKAWA, M.D., PH.D., SUSUMU MIYAMOTO, M.D., PH.D.,  
AND NOBUO HASHIMOTO, M.D., PH.D.**

*Department of Neurosurgery, Kyoto University Graduate School of Medicine, Kyoto, Japan*

✓The authors present the case of a 6-year-old girl with typical absence epilepsy induced by hyperventilation associated with moyamoya disease (MMD). A diffuse 3-Hz spike-and-wave complex induced by hyperventilation was apparent on an electroencephalogram, and her seizures were intractable to medication. Significant ischemia in the bilateral frontal lobes was present. The epilepsy disappeared after superficial temporal artery–middle cerebral artery anastomosis with encephalomyosynangiosis on both sides. In the treatment of children with intractable absence epilepsy, the possibility of underlying MMD and indications that revascularization surgery may be needed should be taken into consideration.

**KEY WORDS • absence epilepsy • hyperventilation • moyamoya disease •  
electroencephalogram • revascularization • pediatric neurosurgery**

**M**OYAMOYA disease is considered a progressive stenocclusive disease at the terminal portion of bilateral ICAs accompanied by the development of moyamoya vessels.<sup>1,20</sup> Although abnormal electroencephalographic findings such as the “re-build up” phenomenon are often observed in pediatric patients, epileptic-type MMD affects only a small percentage of children with MMD.<sup>6,8,13,19</sup> Absence epilepsy is characterized behaviorally by a paroxysmal, abrupt-onset loss of consciousness and a termination associated with a bilateral, synchronous, 3-Hz spike-and-wave complex on an EEG, which can usually be induced by hyperventilation.<sup>10</sup> Although juvenile absence epilepsy is generally considered benign because remission of seizures can be achieved in most cases by monotherapy with anti-epileptic drugs, some refractory cases do exist.<sup>10</sup> We present a case of MMD that was initially thought to be a refractory case of typical juvenile absence epilepsy.

### Case Report

*History and Examination.* This 6-year-old girl presented in January 2002 having suffered recurrent syncopal episodes lasting several seconds, approximately five times a day since 2001. The attacks were accompanied by ocular

*Abbreviations used in this paper:* EEG = electroencephalogram; ICA = internal carotid artery; MMD = moyamoya disease; rCBF = regional cerebral blood flow; rCVR = regional cerebrovascular reserve; SPECT = single-photon emission computerized tomography; <sup>99m</sup>Tc-ECD = technetium 99m-ethylcysteinate dimer.

abduction and urinary incontinence, and often occurred when she ate or went to bed. The attacks were not accompanied by automatism (such as orofacial twitches) or cognitive impairment. At 4 years of age she had experienced episodes of bilateral motor weakness in her legs, induced by hyperventilation. She was taken to a pediatrician who rendered a diagnosis of juvenile absence epilepsy on the basis of an EEG obtained in August 2001 that revealed a typically diffuse 3-Hz spike-and-wave discharge induced by hyperventilation (Fig. 1A). In spite of daily oral administration of high-dose sodium valproate (up to 1800 mg), the incidence of seizures increased inversely, reaching 10 times per day; the child was taken to another hospital for further examination. A magnetic resonance imaging study performed in November 2001 demonstrated a small brain infarction at the left frontal lobe (Fig. 2A), and findings from a cerebral angiography study in November 2001 revealed stenocclusive changes at the terminal portions of the bilateral ICA and the presence of moyamoya vessels at the base of the brain (Fig. 2B–E). A diagnosis of MMD was made, and antiplatelet therapy with 81 mg of aspirin a day was started. The girl presented to our hospital for surgical treatment in January 2002. Results of a <sup>99m</sup>Tc-ECD SPECT study the same month showed decreased rCBF in the bilateral frontal lobes (Fig. 2F), and decreased rCVR in the same region was revealed on an acetazolamide challenging study (Fig. 2G).

*Operation and Postoperative Course.* The patient underwent superficial temporal artery–middle cerebral artery anastomosis with encephalomyosynangiosis on the right

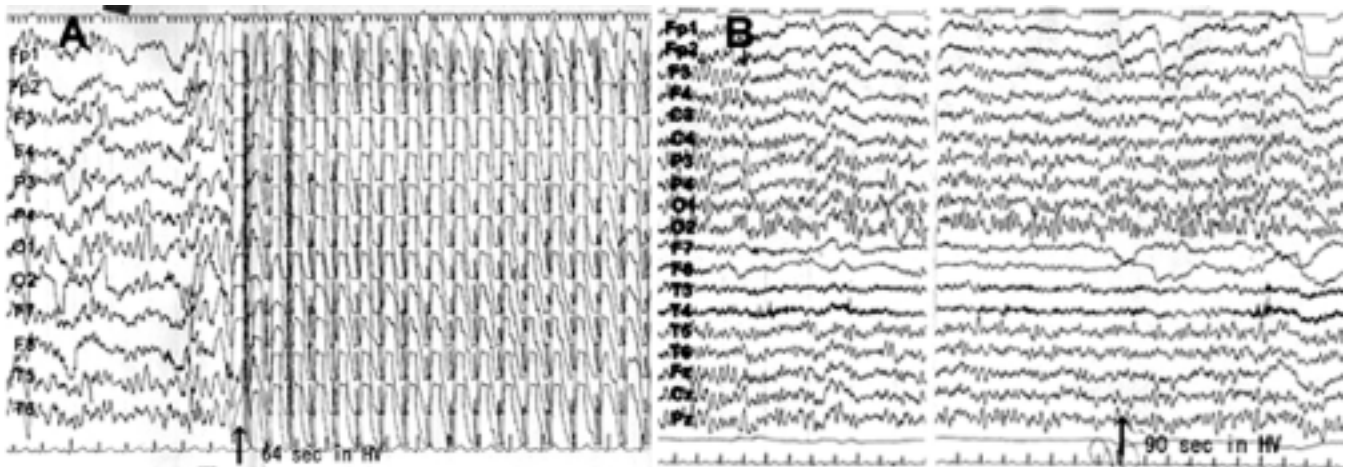


FIG. 1. A: A preoperative EEG obtained in August 2001 showing a diffuse 3-Hz spike-and-wave complex induced by hyperventilation. An absence seizure was induced 64 seconds after hyperventilation began (*arrow*). B: A postoperative EEG in the nonmedicated patient from March 2005 showing mild buildup without induction of a spike-and-wave complex under hyperventilation. The absence seizure was not induced by hyperventilation, and the *arrow* indicates 90 seconds after hyperventilation began.

side in January, and on the left side in March 2002. Medication with 81 mg of aspirin and 600 mg of sodium valproate a day continued postoperatively. The success of the bypass surgeries and improvement in rCBF and rCVR were confirmed on cerebral angiograms (Fig. 3A and B) and on  $^{99m}\text{Tc}$ -ECD SPECT images (Fig. 3C and D) in July 2002. The child discontinued the use of aspirin in September 2002 and sodium valproate in January 2005.

The patient has been free from either seizures or transient ischemic attacks for more than 2 years since her surgery, and experiences no restriction in activities of daily life. On an EEG obtained in March 2005, a 3-Hz spike-and-wave complex was not induced by hyperventilation, although the patient was taking no medication (Fig. 1B).

### Discussion

Although several abnormal findings on EEGs have been reported in patients with epileptic-type MMD (such as resting regional slow waves, diffuse inactive patterns, paroxysmal slow bursts, or epileptic discharges), patients with MMD and absence epilepsy exhibiting typical 3-Hz spike-and-wave complexes on EEGs have not been reported previously.<sup>6,8,12,13,17</sup> The prevalence of MMD in Japan has been reported as 3.16 per 100,000 persons,<sup>22</sup> and the incidence of MMD in combination with epilepsy has been reported to be 6 to 12.5% of the group suffering from the disease as a whole.<sup>13,18</sup> The prevalence of epilepsy in children and adolescents ranges from 5 to 15 per 100,000 persons, and 10 to 15% of these present with absence epilepsy.<sup>2</sup> Thus, the prevalence of epileptic MMD is 0.19 to 0.4 per 100,000 persons and that of absence epilepsy 0.5 to 2.3 per 100,000 persons. The prevalence of MMD in combination with absence epilepsy as garnered from epidemiological data is roughly 0.0000009 to 0.0000089 per 100,000 persons, which is quite low.

In MMD, the degree of brain ischemia is generally more severe in pediatric patients than in adults because the demand for cerebral blood flow is rather high in children.<sup>11</sup>

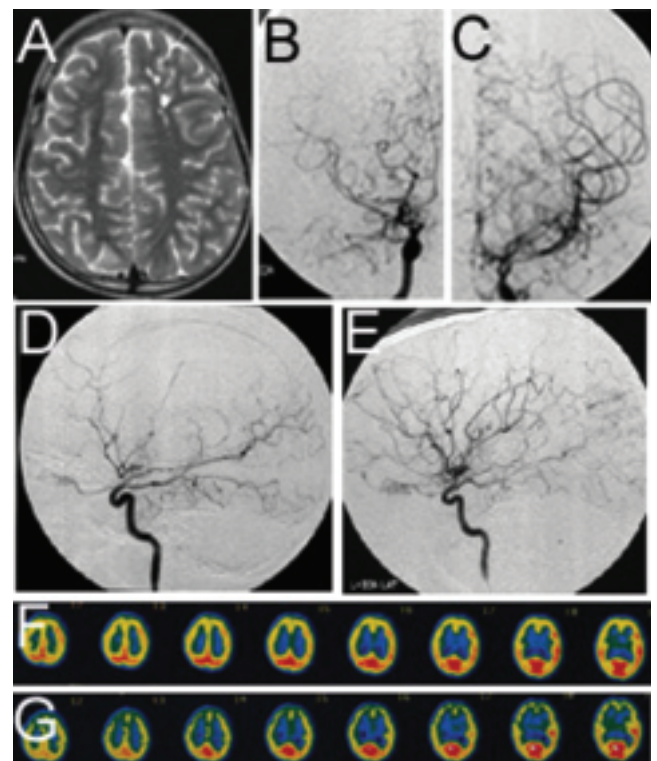


FIG. 2. A: A magnetic resonance image obtained in November 2001 demonstrating an ischemic lesion at the left frontal lobe. B–E: Angiograms (right anteroposterior view) obtained in November 2001 showing stenocclusive changes at the terminal portions of the bilateral ICAs and the presence of moyamoya vessels at the base of the brain (anteroposterior views of the right [B] and left [C] ICA and lateral views of the right [D] and left [E] ICA). F: A  $^{99m}\text{Tc}$ -ECD SPECT study from January 2002 demonstrating decreased rCBF in the bilateral frontal lobes and reduced rCVR revealed by acetazolamide challenging in the same region (G).

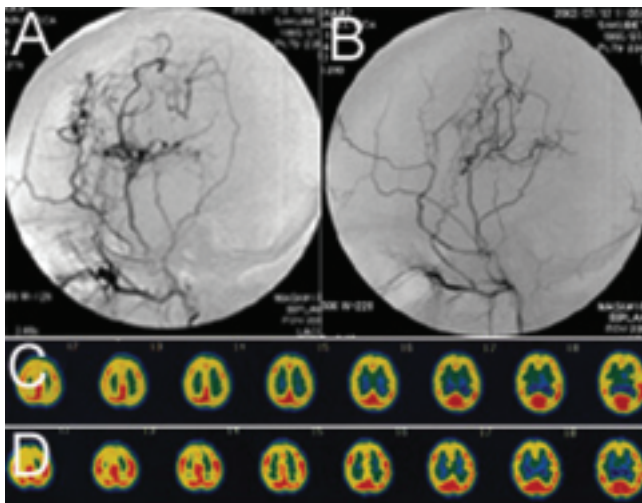


FIG. 3. Right (A) and left (B) external carotid artery angiograms obtained in the patient in July 2002 demonstrating extensive blood supply to the brain via a bypass. A postoperative  $^{99m}\text{Tc}$ -ECD SPECT study obtained on the same day shows the recovery of rCBF (C) and rCVR (D) in the bilateral frontal lobes.

Abnormal findings on EEGs such as the re-build up phenomenon after hyperventilation are also usually observed in pediatric patients only.<sup>6,8,19</sup> The occurrence of the re-build up phenomenon after hyperventilation is frequently seen in the region where rCBF or rCVR was reduced, indicating a close relationship between this phenomenon and brain ischemia.<sup>3,5,9,14,16,21</sup> Based on these findings, brain ischemia is thought to be significantly involved in abnormalities detected on EEGs obtained in patients with MMD.

The pathogenesis of absence epilepsy remains unclear.<sup>10,15</sup> Some authors posit that decreased rCBF in the frontal lobes enhanced by hyperventilation is implicated.<sup>4,7</sup> In our case, a preoperative SPECT study revealed decreased rCBF and rCVR in the bilateral frontal lobes. After our patient's revascularization surgeries, the ischemia in her bilateral frontal lobes improved. Neither the absence epilepsy nor the 3-Hz spike-and-wave complex on our patient's EEGs appeared to be induced by hyperventilation during the time she was not receiving medication. It is highly probable that ischemia in the frontal lobes enhanced by hyperventilation was related to the occurrence of absence epilepsy in this case.

Revascularization surgery was beneficial for the control of epilepsy in this case. Nakase, et al.,<sup>13</sup> have reported that the clinical features of epileptic-type MMD are similar to those of ischemic-type MMD. In their research, a patient age of less than 1 year and the presence of major ischemic lesions indicated a poor prognosis; early revascularization surgery was particularly recommended for patients with these risk factors. Robertson and colleagues<sup>17</sup> reported the case of a 13-year-old girl with MMD who exhibited partial seizures induced by the Valsalva maneuver. They speculated that cerebral hypoperfusion induced by the maneuver had caused the seizures, which were resolved not by medication but by bilateral extracranial-intracranial synangiosis. In a surgical procedure for epilepsy such as an amygdalohippocampectomy, postoperative therapy with antiepileptic drugs is recommended for approximately 2 years to achieve complete remission of seizures.<sup>23</sup> Hence, we did not think that a

cure for the seizures in our patient could be accomplished by revascularization without valproate; however, the possibility exists that improvement of the seizures could have been achieved with revascularization alone. Early revascularization surgery is recommended in patients with epileptic-type MMD when seizures are intractable to medication.

Absence epilepsy can usually be cured by monotherapy with antiepileptic drugs; however, in some refractory cases patients exhibit atypical absence seizures or other generalized seizure forms.<sup>10</sup> In our patient, neither automatism nor focal seizures were present, both of which are often observed in patients with atypical absence seizures. Therefore, an initial diagnosis of typical absence epilepsy was made by a pediatrician, despite past episodes of transient ischemic attacks. In the treatment of pediatric patients with intractable absence epilepsy, the possibility of underlying MMD should be considered.

### Conclusions

This is the first reported case of absence epilepsy associated with MMD. Ischemia in the frontal lobes enhanced by hyperventilation was probably related to the occurrence of epilepsy, and the seizures resolved with revascularization surgery.

### References

1. Fukui M, Research Committee on Spontaneous Occlusion of the Circle of Willis (Moyamoya Disease) of the Ministry of Health and Welfare, Japan: Guidelines for the diagnosis and treatment of spontaneous occlusion of the circle of Willis ('moyamoya disease'). *Clin Neurol Neurosurg* 99 Suppl 2:S238-S240, 1997
2. Hauser WA: The prevalence and incidence of convulsive disorders in children. *Epilepsia* 35 Suppl 2:S1-S6, 1994
3. Kameyama M, Shirane R, Tsurumi Y, Takahashi A, Fujiwara S, Suzuki J, et al: Evaluation of cerebral blood flow and metabolism in childhood moyamoya disease: an investigation into "re-build-up" on EEG by positron CT. *Childs Nerv Syst* 2:130-133, 1986
4. Kapucu LO, Serdaroglu A, Okuyaz C, Kose G, Gucuyener K: Brain single photon emission computed tomographic evaluation of patients with childhood absence epilepsy. *J Child Neurol* 18:542-548, 2003
5. Kazumata K, Kuroda S, Houkin K, Abe H, Mitumori K: Regional cerebral hemodynamics during re-build-up phenomenon in childhood moyamoya disease. An analysis using  $^{99m}\text{Tc}$ -HMPAO SPECT. *Childs Nerv Syst* 12:161-165, 1996
6. Kodama N, Aoki Y, Hiraga H, Wada T, Suzuki J: Electroencephalographic findings in children with moyamoya disease. *Arch Neurol* 36:16-19, 1979
7. Kudo T, Sato K, Yagi K, Seino M: Can absence status epilepticus be of frontal lobe origin? *Acta Neurol Scand* 92:472-477, 1995
8. Kurlmann G, Schuierer G: [EEG in diagnosis of other disease pictures than epilepsy.] *Klin Padiatr* 206:100-107, 1994 (Ger)
9. Kuroda S, Kamiyama H, Isobe M, Houkin K, Abe H, Mitumori K: Cerebral hemodynamics and "re-build-up" phenomenon on electroencephalogram in children with moyamoya disease. *Childs Nerv Syst* 11:214-219, 1995
10. Manceau E, Giroud M, Dumas R: Moyamoya disease in children. A review of the clinical and radiological features and current treatment. *Childs Nerv Syst* 13:595-600, 1997
11. Manning JP, Richards DA, Bowery NG: Pharmacology of absence epilepsy. *Trends Pharmacol Sci* 24:542-549, 2003
12. Miyamoto S, Akiyama Y, Nagata I, Karasawa J, Nozaki K, Hashimoto N, et al: Long-term outcome after STA-MCA anastomosis for moyamoya disease. *Neurosurg Focus* 5(5):E5, 1998

13. Nakase H, Ohnishi H, Touho H, Miyamoto S, Watabe Y, Itoh T, et al: Long-term follow-up study of "epileptic type" moyamoya disease in children. **Neurol Med Chir (Tokyo)** **33**:621–624, 1993
14. Ohyama H, Niizuma H, Fujiwara S, Suzuki J: [EEG findings in moyamoya disease in children—with special reference to the genesis of re-build up.] **No Shinkei Geka** **13**:727–733, 1985 (Jpn)
15. Prevett MC, Duncan JS, Jones T, Fish DR, Brooks DJ: Demonstration of thalamic activation during typical absence seizures using H<sub>2</sub>(15)O and PET. **Neurology** **45**:1396–1402, 1995
16. Qiao F, Kuroda S, Kamada K, Houkin K, Iwasaki Y: Source localization of the re-build up phenomenon in pediatric moyamoya disease—a dipole distribution analysis using MEG and SPECT. **Childs Nerv Syst** **19**:760–764, 2003
17. Robertson P, Compton DA, Kirkpatrick P: Moyamoya disease presenting as valsalva related partial seizures. **J Neurol Neurosurg Psychiatry** **66**:111, 1999
18. Scott RM, Smith JL, Robertson RL, Madsen JR, Soriano SG, Rockoff MA: Long-term outcome in children with moyamoya syndrome after cranial revascularization by pial synangiosis. **J Neurosurg** **100** (2 Suppl Pediatrics):142–149, 2004
19. Sunder TR, Erwin CW, Dubois PJ: Hyperventilation induced abnormalities in the electroencephalogram of children with Moyamoya disease. **Electroencephalogr Clin Neurophysiol** **49**:414–420, 1980
20. Suzuki J, Takaku A: Cerebrovascular "moyamoya" disease. Disease showing abnormal net-like vessels in base of brain. **Arch Neurol** **20**:288–289, 1969
21. Touho H, Karasawa J, Shishido H, Morisako T, Yamada K, Nagai S, et al: Mechanism of the re-buildup phenomenon in moyamoya disease—analysis of local cerebral hemodynamics with intra-arterial digital subtraction angiography. **Neurol Med Chir (Tokyo)** **30**:721–726, 1990
22. Wakai K, Tamakoshi A, Ikezaki K, Fukui M, Kawamura T, Aoki R, et al: Epidemiological features of moyamoya disease in Japan: findings from a nationwide study. **Clin Neurol Neurosurg** **99 Suppl 2**:S1–S5, 1997
23. Wieser HG, Hane A: Antiepileptic drug treatment before and after selective amygdalohippocampectomy. **Epilepsy Res** **55**: 211–223, 2003

---

Manuscript received May 13, 2005.

Accepted in final form January 6, 2006.

*Address reprint requests to:* Ken-ichiro Kikuta, M.D., Ph.D., Department of Neurosurgery, Kyoto University Graduate School of Medicine, 54 Kawaharacho, Shogoin, Sakyo-ku, Kyoto 606-8507, Japan. email: kikuta@kuhp.kyoto-u.ac.jp.