

Delayed Hemorrhage From Completely Obliterated Arteriovenous Malformation After Gamma Knife Radiosurgery

—Case Report—

Hiroaki MATSUMOTO, Tetsuji TAKEDA, Kanehisa KOHNO,
Yoshiaki YAMAGUCHI, Keiji KOHNO, Akihiko TAKECHI,
Daizo ISHII, Masaru ABIKO, and Ushio SASAKI

Department of Neurosurgery, Ehime Prefectural Central Hospital, Matsuyama, Ehime

Abstract

A 43-year-old female was treated with gamma knife radiosurgery (GKS) for right frontal arteriovenous malformation (AVM) manifesting as absence seizures. Complete nidus obliteration was confirmed on angiography 4 years after GKS. However, she experienced recurrence of her previous seizures and delayed hemorrhage occurred within the treated nidus, despite absence of abnormalities by repeated angiography 81 months after GKS. She was treated conservatively and discharged home without neurological deficits. The risk of hemorrhage from obliterated AVM is significantly reduced but not eliminated after radiosurgery. Recanalization of thrombus that is too small to detect by neuroimaging may result in delayed hemorrhage.

Key words: arteriovenous malformation, gamma knife, radiosurgery, hemorrhage

Introduction

Gamma knife radiosurgery (GKS) is a widely accepted modality for the treatment of cerebral arteriovenous malformations (AVMs), particularly if deep-seated or located in eloquent areas of the brain.^{1,4,5,7,9,11-13,16} The primary goal of GKS for treatment of cerebral AVMs is the complete angiographic obliteration of the nidus, as defined by complete absence of detectable draining veins and normalized hemodynamics.^{2,7,12,13} The rate of nidus obliteration ranges from 55% to 94% at 2 to 5 years,^{1,3,4,7,9,11-13,15} and the annual risk of hemorrhage during the latency period is 1.5% to 3.7%,^{1,5,6,11-13} which is lower than the rebleeding rate of AVMs not treated with GKS. However, even in the presence of complete angiographic obliteration of the AVM, a small risk of hemorrhage persists.^{4,8-11,14,15}

We describe a case of hemorrhage from a cerebral AVM at 81 months after GKS, despite complete angiographic obliteration.

Case Report

A 43-year-old female patient presented to our hospital for evaluation of the abrupt onset of absence seizures on July 20, 1997. The patient was alert and without neurological deficits. Magnetic resonance (MR) imaging revealed a right frontal lobe AVM (Fig. 1), and angiography demonstrated that the AVM was supplied by branches of the right middle cerebral artery and drained into the basal vein of Rosenthal through the deep sylvian vein (Fig. 2).

Anticonvulsant medication was subsequently initiated, and GKS was performed on April 1, 1998. The $2 \times 3 \times 2$ -cm (5.8 cm³) nidus was covered with a 50% isodose volume, with a central dose of 36 Gy to obtain a marginal dose of 18 Gy (Fig. 3). The seizure frequency progressively decreased with complete resolution by 26 months after GKS. Follow-up MR imaging was performed every 6 months, and postradiosurgical MR imaging at 24 months rev-

Received March 31, 2005; Accepted December 6, 2005

Author's present address: H. Matsumoto, M.D., Department of Neurosurgery, Faculty of Medicine, Ehime University School of Medicine, Toon, Ehime, Japan.

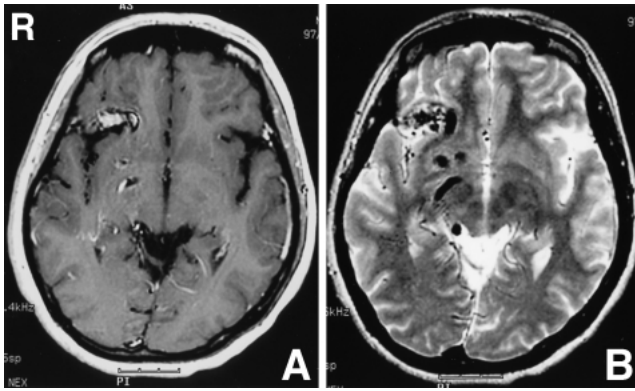


Fig. 1 Preradiosurgical magnetic resonance images showing an arteriovenous malformation in the right frontal lobe. Gadolinium-enhanced T₁-weighted image showing enhancement of the nidus (A). T₂-weighted image showing multiple abnormal flow-void signals (B).

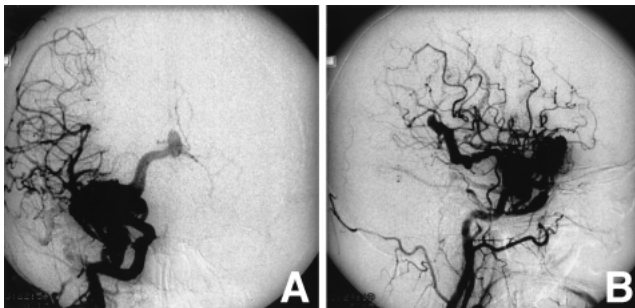


Fig. 2 Preradiosurgical right carotid angiograms demonstrating a right frontal arteriovenous malformation which was supplied by branches of the right middle cerebral artery and drained into the basal vein of Rosenthal through the deep sylvian vein (A: anteroposterior view, B: lateral view).

ected neither enhancement of the nidus nor flow-void signal abnormalities. However, a capillary high intensity area persisted within the treated nidus on the T₂-weighted image. Complete obliteration of the AVM was confirmed by angiography at 48 months after radiosurgery (Fig. 4). Anticonvulsant medication was discontinued in November 2004, because there were no new abnormalities on MR imaging or electroencephalography (Fig. 5A).

The patient experienced recurrence of her previous seizures and presented to our hospital for evaluation on January 14, 2005. The patient complained of headaches but had no neurological deficits. Computed tomography (CT) showed

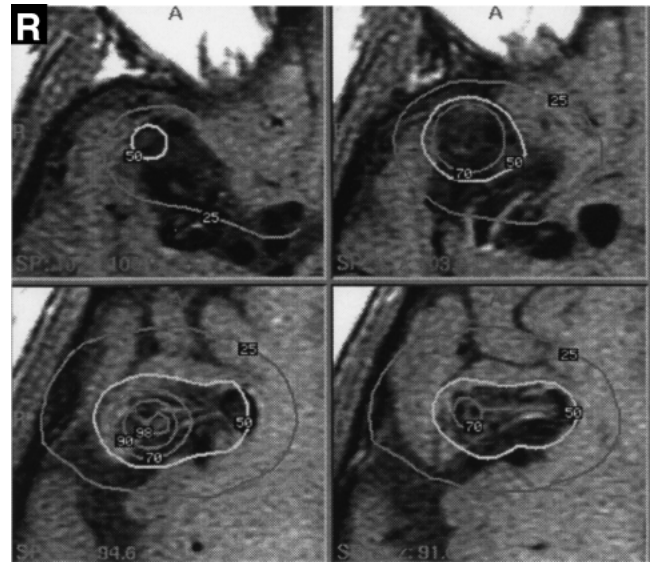


Fig. 3 Axial gadolinium-enhanced T₁-weighted images showing the dose planning for the right frontal lobe arteriovenous malformation. The nidus was covered with a 50% isodose volume, with a central dose of 36 Gy to obtain a marginal dose of 18 Gy.

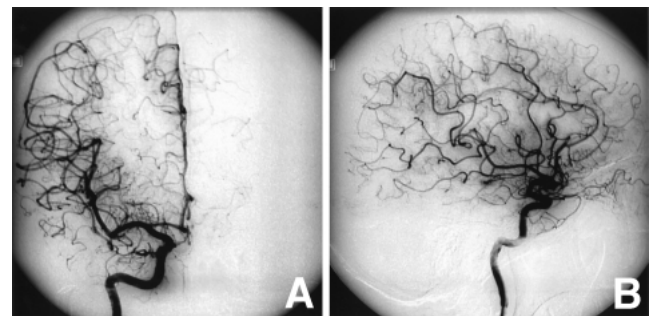


Fig. 4 Right carotid angiograms obtained 48 months after gamma knife radiosurgery demonstrating complete disappearance of the nidus (A: anteroposterior view, B: lateral view).

hemorrhage within the treated nidus (Fig. 6), but angiography revealed no vascular abnormalities (Fig. 7). The patient declined open surgery and elected to be treated conservatively with reinitiation of anticonvulsant medication. MR imaging with contrast medium performed 10 days later showed the known hemorrhage without enhancement (Fig. 5B). Serial CT showed reabsorption of the hemorrhage, and the patient was discharged home without neurological deficits after 2 weeks.

Discussion

This case is another example of the risk of hemorrhage despite the angiographic obliteration of the AVM by GKS.^{1-7,9-11,13,16)} Delayed hemorrhage occurred in six of 250 patients (2.4%) after complete obliteration,⁹⁾ and delayed hemorrhage occurred in one of 130 patients (0.7%).⁴⁾ Including the present case, nine cases of delayed hemorrhage have been reported after angiographic obliteration of AVM after GKS (Table 1).^{8,10,15)} The patients with delayed hemorrhage were predominantly female and young (mean 25.1 years), and tended to have smaller AVMs. Repeated angiography revealed no recanalization of the original malformations in six of these nine patients.

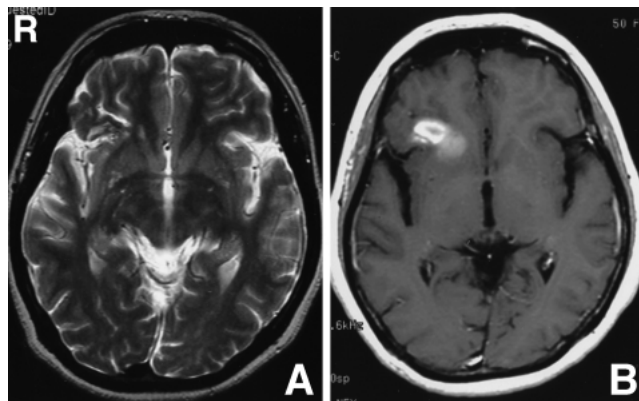


Fig. 5 T₂-weighted magnetic resonance image obtained 2 months before the ictus showing a capillary high intensity area within the treated nidus (A). Gadolinium-enhanced T₁-weighted image obtained 10 days after the ictus showing the known hemorrhage without enhancement (B).

The cause of delayed hemorrhage in the absence of angiographic abnormalities remains unclear. Nidus obliteration after radiosurgery results from endothelial degeneration and hyaline transformation,^{6,9,10,14,16)} and may leave organized thrombi within the original nidus. A time-related decrease in contrast medium enhancement on CT or MR imaging following angiographic nidus obliteration suggested that reconstructive and destructive processes continued within the radiosurgically occluded nidus.¹⁶⁾ Therefore, radiosurgery-induced changes (e.g., obliteration of the remaining or recanalizing vessels) in the nidus possibly continued after the nidus was angiographically obliterated. Histological examinations of resected tissue from the obliterated nidus after LINAC radiosurgery found recanalization of the thrombus.¹⁴⁾ In contrast,

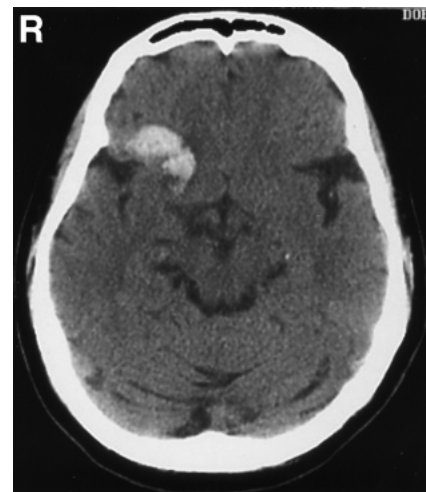

Fig. 6 Computed tomography scan on admission showing hemorrhage within the treated nidus.

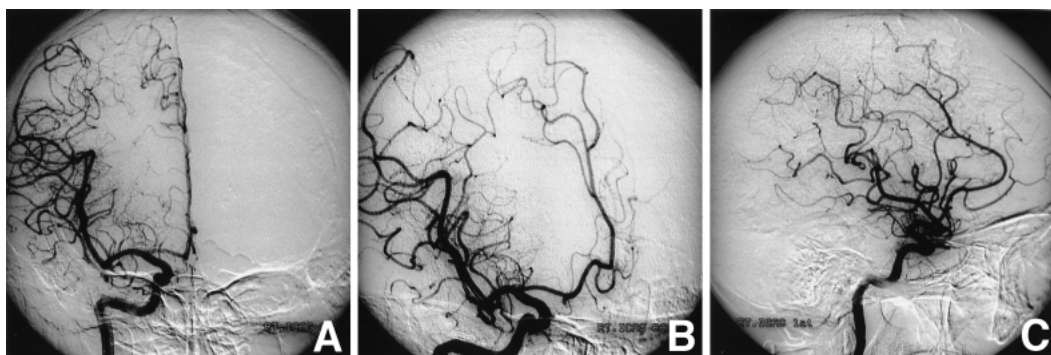


Fig. 7 Right carotid angiograms obtained 81 months after gamma knife radiosurgery (or immediately after the ictus) demonstrating no vascular abnormalities (A: anteroposterior view, B: oblique view, C: lateral view).

Table 1 Summary of reported cases of delayed hemorrhage from completely obliterated arteriovenous malformation after gamma knife radiosurgery (GKS)

Author (Year)	Age at GKS (yrs)/ Sex	History of hemorrhage before GKS	Nidus volume (cm ³)	GKS dosimetry		Clinical course after GKS				Treatment
				Maximum dose (Gy)	Marginal dose (Gy)	Time from GKS to angiographic obliteration (mos)	Time from GKS to delayed hemorrhage (mos)	Continuous abnormalities on CT or MR imaging	Abnormalities on repeated angiography	
Yamamoto et al. (1996) ¹⁵⁾	30/F	+	0.68	24	21.6	24	81	ND	–	conservative
Lindqvist et al. (2000) ⁸⁾	10/M	+	ND	ND	ND	16	95	ND	+ : recurrence	second GKS
	13/F 14/ND	+ ND	ND ND	ND ND	ND ND	12 ND	62 ND	ND ND	+ : de novo + : recurrence	ND ND
Shin et al. (2005) ¹⁰⁾	40/F	–	8.8	40	20	34	50	+	–	surgical resection
	18/F	–	1.8	40	20	47	85	+	–	conservative
	26/F	+	0.6	50	25	25	64	+	–	conservative
	32/M	+	1.3	40	20	14	65	+	–	conservative
Present case	43/F	–	5.8	36	18	48	81	+	–	conservative

CT: computed tomography, MR: magnetic resonance, ND: not described.

histological examinations of resected AVMs presenting with delayed hemorrhage showed the presence of small endothelial cell-lined channels containing erythrocytes within the area of hyalinization.¹⁰⁾ Further, some of the AVM vessels were still partially patent, despite apparent obliteration by angiography. In the present case, follow-up MR imaging showed a capillary high intensity area on a T₂-weighted image within the treated nidus, which probably corresponded to organized thrombus. Recanalization of a thrombus that is too small to detect via neuroimaging may result in delayed hemorrhage, because the hemorrhage occurred within the treated nidus, and no new enhancement was present on serial MR images.

Accurate methods of predicting which patients will experience delayed hemorrhage would be of great benefit. Continuous abnormalities on CT or MR imaging with contrast medium was the only significant factor positively associated with the delayed hemorrhage from completely obliterated nidus after GKS.¹⁰⁾ In contrast, continuous clinical symptoms might indicate persistence of the AVM and a higher risk of rebleeding.²⁾ In the present case, a capillary high intensity area persisted on a T₂-weighted image despite the absence of seizure activity. These findings suggest that the persistence of MR imaging abnormalities may indicate increased risk of delayed hemorrhage despite complete angiographic obliteration of AVM and absence of clinical symptoms.

Complete angiographic occlusion of an AVM does

not guarantee freedom from the risk of delayed hemorrhage,⁴⁾ and so reinvestigation of young patients with proven total obliteration after radiosurgery is recommended, because of the possibility of reappearance of the AVM.⁸⁾ AVM recanalization may occur without obvious neuroimaging correlates and may increase the risk of delayed hemorrhage even after complete angiographic obliteration of the AVM. There is no standard treatment strategy for such delayed hemorrhage. Repeat radiosurgery may be considered if a recurrent nidus is confirmed angiographically, and surgical resection can be used if a recurrent nidus without angiographic confirmation is suspected.

References

- 1) Coffey RJ, Nichols DA, Shaw EG: Stereotactic radiosurgical treatment of cerebral arteriovenous malformations. Gamma Unit Radiosurgery Study Group. *Mayo Clin Proc* 70: 214–222, 1995
- 2) Guo WY, Karlsson B, Ericson K, Lindqvist M: Even the smallest remnant of an AVM constitutes a risk of further bleeding. Case report. *Acta Neurochir (Wien)* 121: 212–215, 1993
- 3) Inoue HK, Ohye C: Hemorrhage risks and obliteration rates of arteriovenous malformations after gamma knife radiosurgery. *J Neurosurg* 97(5 Suppl): 474–476, 2002
- 4) Izawa M, Hayashi M, Chernov M, Nakaya K, Ochiai T, Murata N, Takasu Y, Kubo O, Hori T, Takakura K: Long-term complications after gamma knife surgery for arteriovenous malformations. *J Neurosurg* 102

- Suppl: 34–37, 2005
- 5) Karlsson B, Lax I, Soderman M: Risk for hemorrhage during the 2-year latency period following gamma knife radiosurgery for arteriovenous malformations. *Int J Radiat Oncol Biol Phys* 15: 1045–1051, 2001
 - 6) Karlsson B, Lindquist C, Steiner L: Effect of Gamma Knife surgery on the risk of rupture prior to AVM obliteration. *Minim Invasive Neurosurg* 39: 21–27, 1996
 - 7) Lindquist C, Steiner L: Stereotactic radiosurgical treatment of arteriovenous malformations, in Lunsford LD (ed): *Modern Stereotactic Neurosurgery*. Boston, Martinus Nijhoff, 1988, pp 491–505
 - 8) Lindqvist M, Karlsson B, Guo WY, Kihlstrom L, Lippitz B, Yamamoto M: Angiographic long-term follow-up data for arteriovenous malformations previously proven to be obliterated after gamma knife radiosurgery. *Neurosurgery* 46: 803–810, 2000
 - 9) Maruyama K, Kawahara N, Shin M, Tago M, Kishimoto J, Kurita H, Kawamoto S, Morita A, Kirino T: The risk of hemorrhage after radiosurgery for cerebral arteriovenous malformations. *N Engl J Med* 352: 146–153, 2005
 - 10) Shin M, Kawahara N, Maruyama K, Tago M, Ueki K, Kirino T: Risk of hemorrhage from an arteriovenous malformation confirmed to have been obliterated on angiography after stereotactic radiosurgery. *J Neurosurg* 102: 842–846, 2005
 - 11) Shin M, Kawamoto S, Kurita H, Tago M, Sasaki T, Morita A, Ueki K, Kirino T: Retrospective analysis of a 10-year experience of stereotactic radiosurgery for arteriovenous malformations in children and adolescents. *J Neurosurg* 97: 779–784, 2002
 - 12) Shin M, Maruyama K, Kurita H, Kawamoto S, Tago M, Terahara A, Morita A, Ueki K, Takakura K, Kirino T: Analysis of nidus obliteration rates after gamma knife surgery for arteriovenous malformations based on long-term follow-up data: the University of Tokyo experience. *J Neurosurg* 101: 18–24, 2004
 - 13) Steiner L, Lindquist C, Adler JR, Torner JC, Alves W, Steiner M: Clinical outcome of radiosurgery for cerebral arteriovenous malformations. *J Neurosurg* 77: 1–8, 1992
 - 14) Szeifert GT, Salmon I, Baleriaux D, Brotchi J, Levivier M: Immunohistochemical analysis of a cerebral arteriovenous malformation obliterated by radiosurgery and presenting with re-bleeding. Case report. *Neurol Res* 25: 718–721, 2003
 - 15) Yamamoto M, Jimbo M, Hara M, Saito I, Mori K: Gamma knife radiosurgery for arteriovenous malformation: long-term follow-up results focusing on complications occurring more than 5 years after irradiation. *Neurosurgery* 38: 906–914, 1996
 - 16) Yamamoto M, Jimbo M, Ide M, Lindquist C, Steiner L: Gamma Knife radiosurgery in cerebral arteriovenous malformations: postobliteration nidus changes observed on neurodiagnostic imaging. *Stereotact Funct Neurosurg* 64 Suppl 1: 126–133, 1995
-
- Address reprint requests to: H. Matsumoto, M.D., Department of Neurosurgery, Faculty of Medicine, Ehime University School of Medicine, Shitsukawa, Toon, Ehime 791-0295, Japan.
e-mail: hiroaki-matsu@umin.ac.jp