

Atypical Teratoid/Rhabdoid Tumor of the Velum Interpositum Presenting as a Spontaneous Intraventricular Hemorrhage in an Infant: Case Report with Long-Term Survival

Daniel J. Donovan^a Alice B. Smith^b Gregory W. Petermann^b

^aDepartment of Surgery, Neurosurgery Service, and ^bDepartment of Radiology, Tripler Army Medical Center, Honolulu, Hawaii, USA

Key Words

Atypical teratoid/rhabdoid tumor · Brain neoplasm · Hemorrhage · Velum interpositum

Abstract

Atypical teratoid/rhabdoid tumors (ATRT) of infancy are highly malignant neoplasms that are most common in the first 2 years of life. We present the case of a 3-month-old girl who presented with the acute onset of generalized seizures and was found to have a large spontaneous intraventricular hemorrhage. The blood masked an underlying ATRT of the velum interpositum in the midline of the lateral ventricles and roof of the third ventricle, the first reported case in this location. Serial imaging studies and two ventriculoscopic biopsies were required to establish the diagnosis of the tumor in this unique location and in the midst of an evolving hematoma. After surgical resection, the patient received adjuvant chemotherapy. At 4-year follow-up, the child is neurologically intact, meeting normal developmental milestones, and imaging studies show no evidence of tumor. ATRT were previously associated with an extremely poor prognosis, but more recent evidence with complete surgical resection and adjuvant chemotherapy shows extended survival in some cases, supporting an aggressive and com-

prehensive approach to give these patients the best chance for a good outcome. Spontaneous brain hemorrhage in a full-term infant requires a diligent and persistent search to rule out an underlying neoplasm.

Copyright © 2006 S. Karger AG, Basel

Introduction

Cerebral neoplasms with rhabdoid features were first reported in 1987, and the histopathologic features were similar to those found in the kidney and other sites outside the central nervous system in children [1]. As more of these tumors were encountered, they were most commonly noted to have a mixed appearance with malignant neuroepithelial or mesenchymal cells. Atypical teratoid/rhabdoid tumors (ATRT) are difficult to distinguish histologically from primitive neuroectodermal tumors (PNET), but were characterized as a distinct neoplastic entity by Rorke et al. [2] in 1996 as ATRT of infancy and childhood. They are associated with abnormalities of chromosome 22 in many cases, either monosomy 22 or deletion of 22q [2–5], and are highly malignant and rapidly growing tumors with great vascularity. The vast majority occur within the first 2 years of life, and several cases of congenital ATRT have been reported [6, 7]. They

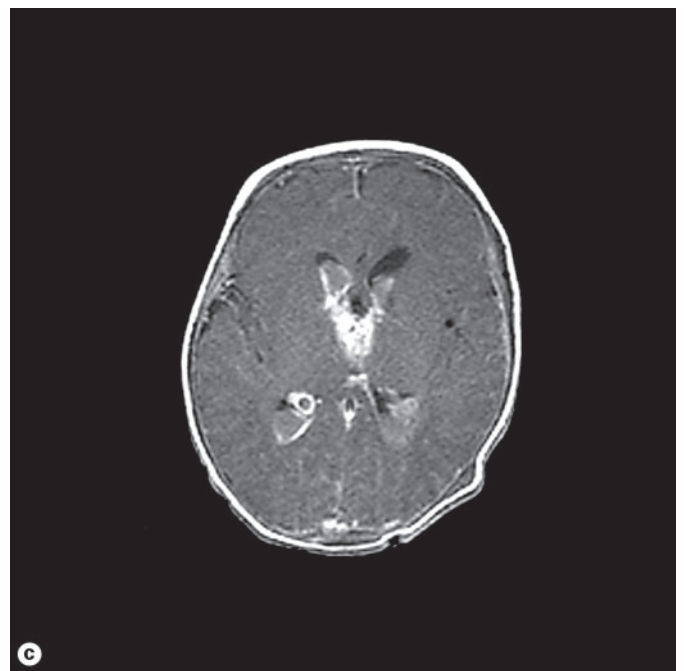
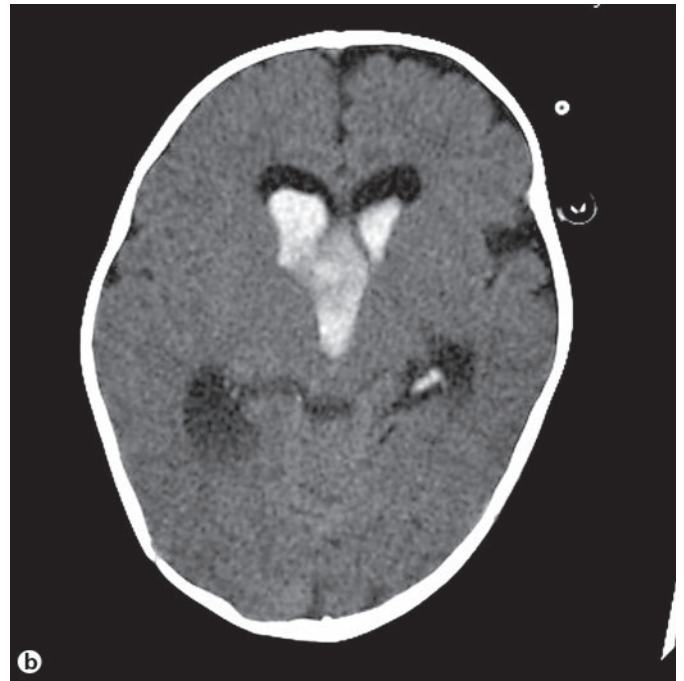
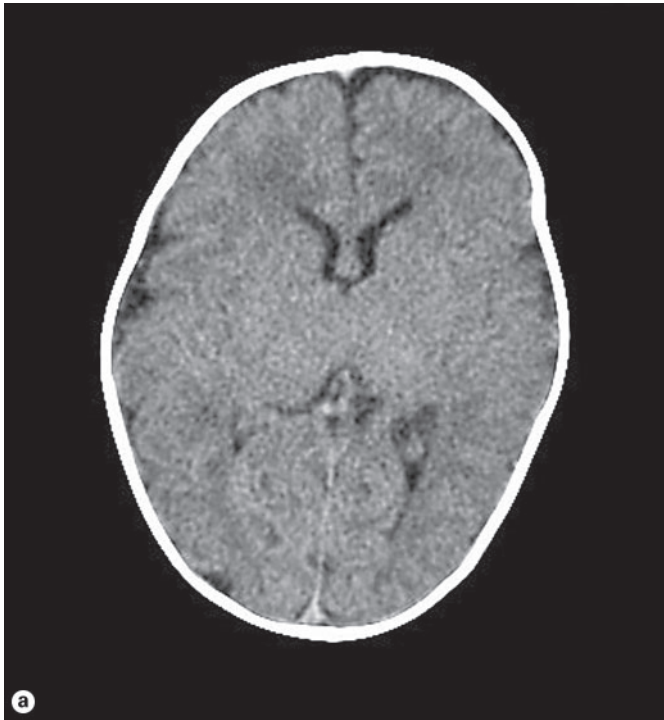


Fig. 1. **a** CT scan at 6 weeks of age without intravenous contrast shows no evidence of tumor, hemorrhage, or hydrocephalus. **b** CT without contrast 6 weeks later when the patient presented with spontaneous onset of a generalized seizure. A large acute hematoma and hydrocephalus are present within the lateral and third ventricles. **c** T₁-weighted MRI shows acute hemorrhage, but no evidence of underlying mass.

have a high rate of dissemination throughout the cerebrospinal fluid (CSF) pathways, and are associated with a very poor prognosis. The median survival for infants is 6–10 months [2, 4, 8–11], but there have been rare reports of individual cases with survival for 3 years or more [11].

The majority of these tumors were previously reported in the posterior fossa, typically the cerebellum and/or fourth ventricle, but in rare cases they have also been described in the supratentorial compartment, and they may even occur as a primary spinal tumor [2, 12–14]. In the supra-

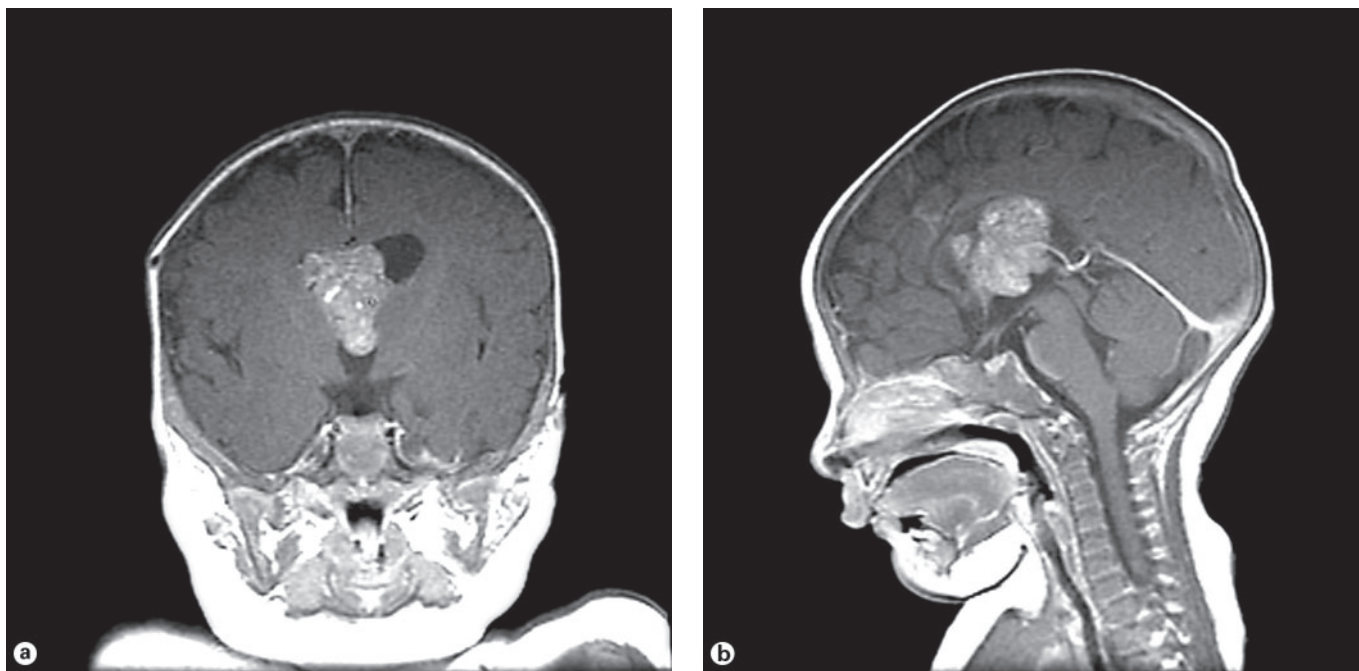


Fig. 2. Second preoperative coronal (a) and sagittal (b) MRI 4 weeks after presentation shows resolution of the hematoma and a more distinct enhancing mass centered within the velum interpositum, extending upward into the lateral ventricles and inferiorly into the third ventricle.

tentorial compartment they have been reported in the cerebral cortex, pineal and suprasellar locations [2, 4, 11, 12], but the velum interpositum location has not been previously described.

Case Description

A female infant was born at full term without complications of the pregnancy or delivery. She was well for the first 6 weeks of life, but then developed fever and emesis. Her pediatrician found no neurologic deficits, but was concerned about the possibility of meningitis. Computerized tomography (CT) was performed without intravenous contrast, and showed no abnormalities (fig. 1a). Lumbar puncture was then performed and clear CSF obtained. The protein, glucose, and cell count were all normal, and cultures were negative for bacterial growth. Her symptoms resolved soon thereafter, and she was presumed to have a mild viral infection.

Just over a month later, at 11 weeks of age, the patient experienced the sudden onset of generalized tonic-clonic seizures while at home. She was transported by ambulance to our institution and intubated in the emergency department. Her seizures stopped after she received phenobarbital and lorazepam, but her anterior fontanelle remained bulging and tense. She underwent a non-contrast CT scan, which revealed a large intraventricular hemorrhage in the lateral and third ventricles, with severe hydrocephalus (fig. 1b). A right frontal ventriculostomy catheter was placed and hemorrhagic

CSF under pressure obtained. Magnetic resonance imaging (MRI) of the brain showed hyperintense signal within the acute blood clot on T₁-weighted images (fig. 1c). The non-contrast appearance was so bright as to make it difficult to discern any enhancement after intravenous contrast agent was given. There were no abnormal blood vessels noted on magnetic resonance angiogram. A CSF cytology sample from the ventriculostomy was negative for malignant cells.

The patient remained neurologically stable, but could not be weaned from the ventriculostomy. Repeat CT scans showed some minimal decrease in attenuation of the hematoma, but no other changes. Ventriculoperitoneal shunt placement was then performed, and ventriculoscopic examination of the lateral ventricles was performed simultaneously because of the concern for underlying neoplasm. A shaggy appearing subacute hematoma was seen, but no abnormal vessels or tumor. Biopsy specimens from this tissue in the right lateral and third ventricles showed only blood clot and macrophages.

Repeat CT scans over the next 3 weeks showed no change in the appearance of the hyperdense mass, but there was some increase in its size and another small area of hemorrhage within the lateral ventricles. MRI was repeated (fig. 2a, b) and with much of the hematoma resolved, a large enhancing mass was more discernible. It was centered within the velum interpositum and extending upward into the lateral ventricles and downward, filling nearly the entire third ventricle. Spinal MRI was negative for drop metastases. Ventriculoscopic biopsy was repeated, this time within the left lateral ventricle, and a purplish mass was seen in the roof of the third ven-

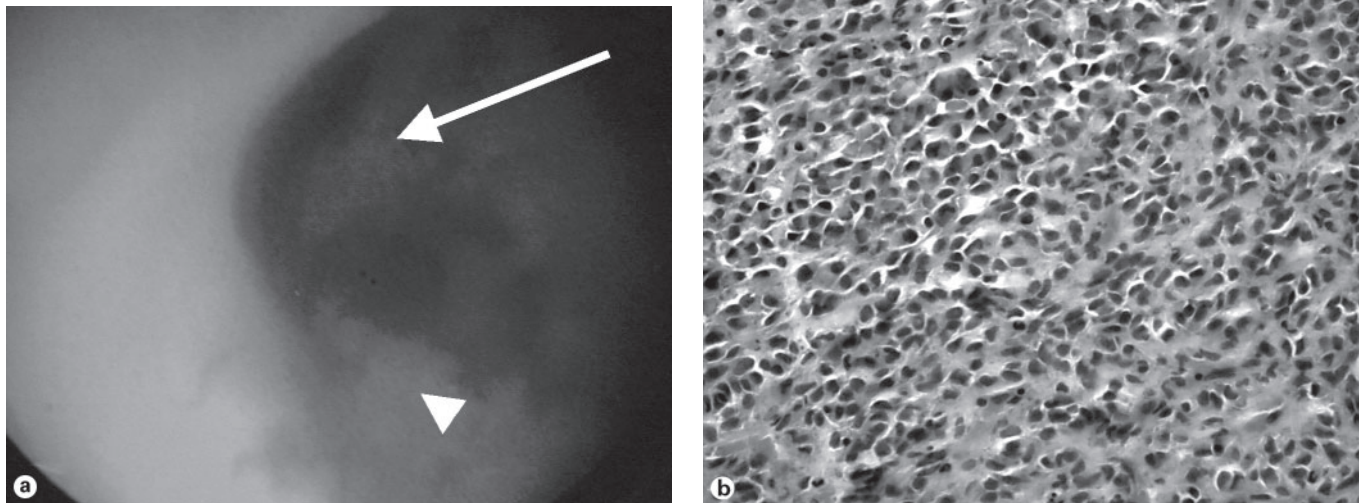


Fig. 3. **a** Intraoperative ventriculoscopic photograph from the left lateral ventricle at 4 weeks post-hemorrhage, showing diffuse subacute hemorrhage in the lateral ventricles (arrowhead) and a purplish mass extending from the velum interpositum through the foramen of Monro (arrow). **b** Histologic specimen of the tumor shows a highly cellular neoplasm, consisting of small to medium-sized cells with a rhabdoid appearance and numerous cytoplasmic inclusions (HE stain). Electron microscopy also showed pleomorphic cells with large oval and irregular nuclei and prominent nucleoli, with conspicuous cytoplasmic filaments and occasional neurosecretory granules. The findings are those of an ATRT.

tricle, extending through the foramen of Monro (fig. 3a). Biopsy of the mass showed a highly cellular neoplasm with malignant features, which initially appeared to be most consistent with PNET.

A midline frontal craniotomy was performed and the tumor was approached through a transcallosal exposure, and it was friable and highly vascular. The tumor vessels from the posterior medial choroidal arteries in the center of the tumor proved difficult to isolate through the tumor above them, and surgery was stopped because of excessive bleeding and hemodynamic instability. The patient recovered well postoperatively and experienced no new focal neurologic deficits, but CT showed that only about 60% of the tumor had been resected.

The larger amount of neoplastic tissue allowed a more detailed histopathologic examination, which revealed a highly cellular neoplasm with small to medium-sized cells. There were numerous cells with a rhabdoid appearance, abundant red cytoplasm filled with intermediate filaments, and cytoplasmic inclusions (fig. 3b). The tissue stained strongly with vimentin, and was negative for glial fibrillary acidic protein and NFP. There was focal reactivity to Kermix, synaptophysin and neuron-specific enolase. Electron microscopy showed pleomorphic cells with large oval and irregular nuclei and prominent nucleoli. There were conspicuous cytoplasmic filaments and occasional neurosecretory granules. The cells were invested by basal lamina and dense basement membrane-like material. The Armed Forces Institute of Pathology was consulted, and

the diagnosis of ATRT made. CT scan of the chest, abdomen and pelvis were negative for tumor, as was whole body bone scan, leaving the brain as the only site of disease.

A second surgery was advised to give the patient the best chance of survival, and a right frontal transcortical approach was chosen to allow better access to the choroidal vessels and the third ventricle. At surgery, most of the tumor was removed with much better control of hemorrhage. The right thalamostriate vein was sacrificed and the choroidal fissure opened to allow wider access to the posterior third ventricle, where all tumor was removed. A few millimeters of tumor remained within the velum interpositum adherent to the internal cerebral veins, and the risk of injury to these vessels was deemed too high to attempt complete resection of this tiny remaining portion.

Results

The patient recovered well postoperatively without new deficits, and postcontrast CT showed no visible remaining tumor (fig. 4a). Adjuvant chemotherapy was then given, and three cycles were completed of cisplatin, cyclophosphamide, vincristine, and etoposide. Comple-

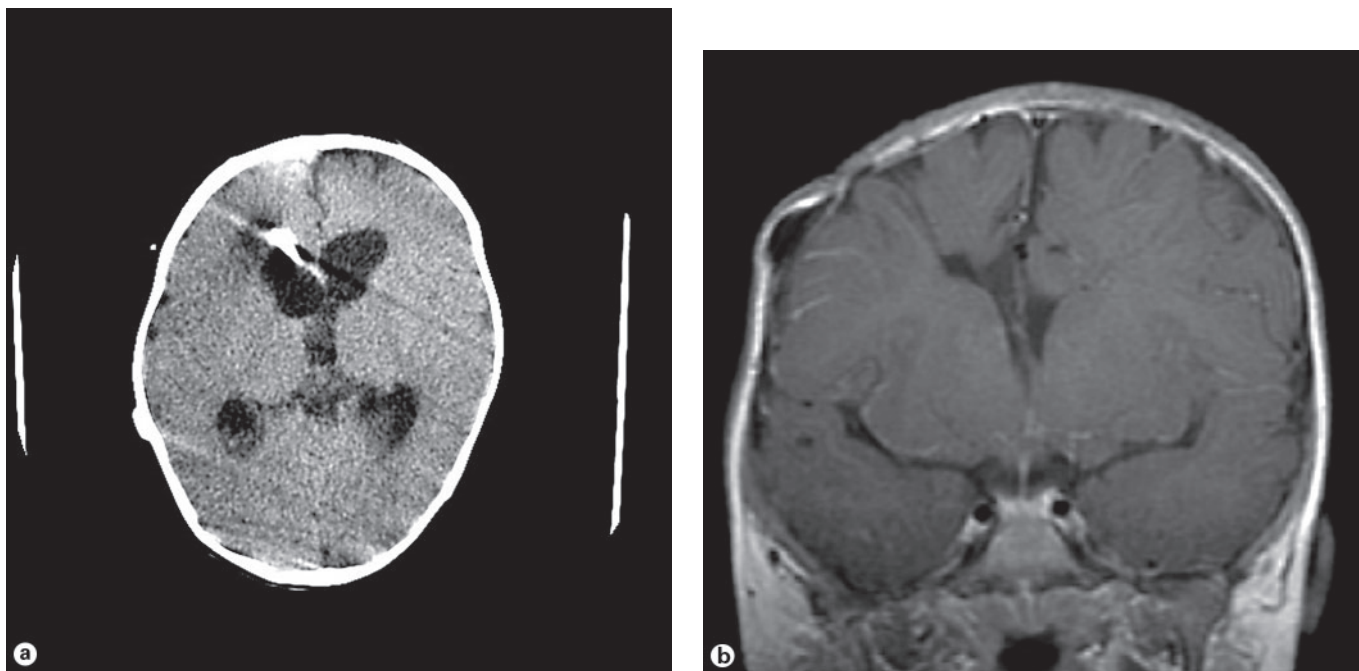


Fig. 4. **a** Postcontrast CT scan immediately following the second surgery, showing no visible residual tumor. At surgery, a tiny amount of residual tumor was left because it was densely adherent to the internal cerebral veins. **b** Follow-up postcontrast MRI 4 years following surgery and an intensive chemotherapy regimen, demonstrating no recurrent tumor.

tion of the first cycle was delayed because of leukopenia, but this resolved and she went on to complete the full course. Follow-up MRI immediately thereafter and at serial intervals showed no recurrent tumor, and no further adjuvant therapy was given. MRI at 4 years postoperatively shows no evidence of tumor (fig. 4b). The child is walking and speaking at a level appropriate for her age, and has met all normal developmental milestones.

Discussion

The most common location of ATRT previously reported was the cerebellum, comprising up to 73% of cases in children under the age of 3 years [2, 4, 15]. However, the largest and most recent series in the literature was comprised of 62% supratentorial and only 38% infratentorial tumors [11]. Supratentorial ATRT have been described in many locations, including the pineal and suprasellar regions and the cerebral cortex, but this is the first reported case of ATRT in the velum interpositum. This location within the lateral and third ventricles presented a unique challenge because of difficulties accessing

and controlling the tumor vasculature within the center of the tumor. It was approached initially through a transcallosal exposure, but the large amount of tumor between the corpus callosum and the tumor vasculature led to excessive bleeding before the vessels could be isolated. At the second surgery, through a transcortical/transventricular approach, the blood supply was reduced earlier without having to go through as much tumor. Repeat surgery to remove residual tumor in children may provide a better chance of survival, but should only be considered if the risks of causing neurologic dysfunction have been carefully assessed and deemed acceptable [16]. The extent of tumor resection may prove to be an important prognostic factor for patients with ATRT [11], as it is for children with other malignant brain tumors such as medulloblastoma and ependymoma. Long-term survival with ATRT is possible in rare cases such as this one and others [11, 17], so aggressive surgical attempts to eradicate the tumor are warranted if the tumor does not invade the brain parenchyma.

The tumor in this case grew rapidly and hemorrhaged within a very short time period, as evidenced by the CT that showed no abnormalities 5 weeks prior to the hem-

orrhage. Brain tumors in early infancy are often highly malignant, and there is an increased risk of spontaneous hemorrhage compared to adults that is attributed to rapid vascular proliferation, invasion of blood vessels by tumor, and/or the fragile developing vasculature of the patients [18, 19]. Wakai et al. [19] reviewed 45 cases of nonpituitary brain tumors that presented with spontaneous hemorrhage, and found a higher rate of tumor related hemorrhage in children under the age of 14 years (5.3%) as opposed to older patients (2.3%), and in 41% of children the hemorrhage was fatal. Congenital tumors may be especially prone to hemorrhage.

Conclusions

ATRT are highly malignant brain neoplasms that are most common within the first two years of life. They can occur almost anywhere in the spine or brain, especially in

the subarachnoid spaces. They are more common in the supratentorial compartment than previously thought, and can even occur in unusual locations such as the velum interpositum, as this case demonstrates. The rapid vascular proliferation and invasive nature of these and other neonatal tumors may lead to spontaneous hemorrhage, which in rare cases may mask the underlying tumor. Diligent and persistent effort should be made with serial imaging studies to ensure that the neoplasm is discovered and treated as early as possible. Long term survival with ATRT is possible in some cases with aggressive adjuvant therapy.

Acknowledgment

The authors wish to thank Ms. Teri Thomson for assistance with reproduction of photographic images.

References

- Biggs PJ, Garen PD, Powers JM, Garvin AJ: Malignant rhabdoid tumor of the central nervous system. *Hum Pathol* 1987;18:332–337.
- Rorke LB, Packer RJ, Biegel JA: Central nervous system atypical teratoid/rhabdoid tumors of infancy and childhood: definition of an entity. *J Neurosurg* 1996;85:56–65.
- Biegel JA, Rorke LB, Packer RJ, Emanuel BS: Monosomy 22 in rhabdoid or atypical tumors of the brain. *J Neurosurg* 1990;73:710–714.
- Burger PC, Yu IT, Tihan T, Friedman HS, Strother DR, Kepner JL, Duffner PK, Kun LE, Perlman EJ: Atypical teratoid/rhabdoid tumor of the central nervous system: a highly malignant tumor of infancy and childhood frequently mistaken for medulloblastoma. A Pediatric Oncology Group study. *Am J Surg Pathol* 1998;22:1083–1092.
- Karnes PS, Tran TN, Cui MY, Bogenmann E, Shimada H, Ying KL: Establishment of a rhabdoid tumor cell line with a specific chromosomal abnormality, 46,XY,t(11;22)(p15.5;q11.23). *Cancer Genet Cytogenet* 1991;56:31–38.
- Fernandez C, Sevenet N, Bouvier-Labit C, Lena G, Figarella-Branger D: Atypical teratoid/rhabdoid tumor: regarding a congenital case (in French). *Ann Pathol* 2001;21:259–262.
- Velasco ME, Brown JA, Kini J, Ruppert ES: Primary congenital rhabdoid tumor of the brain with neoplastic hydranencephaly. *Childs Nerv Syst* 1993;9:185–190.
- Hilden JM, Watters J, Longee DC, Moertel CL, Dunn ME, Kurtzberg J, Scheitauer BW: Central nervous system atypical teratoid/rhabdoid tumor: response to intensive therapy and review of the literature. *J Neurooncol* 1998;40:265–275.
- Lee YK, Choi CG, Lee JH: Atypical teratoid/rhabdoid tumor of the cerebellum: report of two infantile cases. *AJNR Am J Neuroradiol* 2004;25:481–483.
- Lu L, Wilkinson EJ, Yachnis AT: CSF cytology of atypical teratoid/rhabdoid tumor of the brain in a two-year-old girl: a case report. *Diagn Cytopathol* 2000;23:329–332.
- Hilden JM, Meerbaum S, Burger P, Finlay J, Janss A, Scheitauer BW, Walter AW, Rorke LB, Biegel JA: Central nervous system atypical teratoid/rhabdoid tumor: results of therapy in children enrolled in a registry. *J Clin Oncol* 2004;22:2877–2884.
- Howlett DC, King AP, Jarosz JM, Stewart RA, al-Sarraj ST, Bingham JB, Cox TC: Imaging and pathological features of primary malignant rhabdoid tumours of the brain and spine. *Neuroradiology* 1997;39:719–723.
- Rosemberg S, Menezes Y, Sousa MR, Plese P, Ciquini O: Primary malignant rhabdoid tumor of the spinal dura. *Clin Neuropathol* 1994;13:221–224.
- Tamiya T, Nakashima H, Ono Y, Kawada S, Hamazaki S, Furuta T, Matsumoto K, Ohmoto T: Spinal atypical teratoid/rhabdoid tumor in an infant. *Pediatr Neurosurg* 2000;32:145–149.
- Bhattacharjee M, Hicks J, Langford L, Dauser R, Strother D, Chintagumpala M, Horowitz M, Cooley L, Vogel H: Central nervous system atypical teratoid/rhabdoid tumors of infancy and childhood. *Ultrastruct Pathol* 1997;21:369–378.
- Khan RB, Sanford RA, Kun LE, Thompson SJ: Morbidity of second-look surgery in pediatric central nervous system tumors. *Pediatr Neurosurg* 2001;35:225–229.
- Hirth A, Pedersen PH, Webster K, Mork S, Helgestad J: Cerebral atypical teratoid/rhabdoid tumor of infancy: long-term survival after multimodal treatment, also including triple intrathecal chemotherapy and gamma knife radiosurgery – case report. *Pediatr Hematol Oncol* 2003;20:327–332.
- Buetow PC, Smirniotopoulos JG, Done S: Congenital brain tumors: a review of 45 cases. *AJNR Am J Neuroradiol* 1990;11:793–799.
- Wakai S, Yamakawa K, Manaka S, Takakura K: Spontaneous intracranial hemorrhage caused by brain tumor: its incidence and clinical significance. *Neurosurgery* 1982;10:437–444.

Copyright: S. Karger AG, Basel 2006. Reproduced with the permission of S. Karger AG, Basel.
Further reproduction or distribution (electronic or otherwise) is prohibited without permission
from the copyright holder.