

DELAYED POSTTRAUMATIC ACUTE SUBDURAL HEMATOMA IN ELDERLY PATIENTS ON ANTICOAGULATION

Eyal Itshayek, M.D.

Department of Neurosurgery,
Hadassah-Hebrew University
Medical Center,
Jerusalem, Israel

Guy Rosenthal, M.D.

Department of Neurosurgery,
Hadassah-Hebrew University
Medical Center,
Jerusalem, Israel

Shifra Fraifeld, M.B.A.

Department of Neurosurgery,
Hadassah-Hebrew University
Medical Center,
Jerusalem, Israel

Xicotencatl Perez-Sanchez, M.D.

Department of Neurosurgery,
Hadassah-Hebrew University
Medical Center,
Jerusalem, Israel

Jose E. Cohen, M.D.

Department of Neurosurgery,
Hadassah-Hebrew University
Medical Center,
Jerusalem, Israel

Sergey Spektor, M.D., Ph.D.

Department of Neurosurgery,
Hadassah-Hebrew University
Medical Center,
Jerusalem, Israel

Reprint requests:

Eyal Itshayek, M.D.,
Department of Neurosurgery,
Hadassah-Hebrew University
Medical Center,
Kiryat Hadassah,
PO Box 12000,
Jerusalem, Israel 91120.
Email: eyalit@md.huji.ac.il

Received, July 5, 2005.

Accepted, December 2, 2005.

OBJECTIVE: To discuss delayed acute subdural hematoma (DASH), a relatively neglected entity, and to emphasize the potentially elevated risk for DASH among elderly, anticoagulated mild traumatic brain injury (TBI) patients.

METHODS: The authors reviewed clinical and radiological data for four patients who had normal neurological examinations and normal computed tomographic scans after mild TBI, and who subsequently developed DASH and deteriorated rapidly.

RESULTS: The patients included two men and two women, aged 65 to 86 years, who presented to the emergency department after mild TBI between January 2002 and June 2004. All were treated with chronic anticoagulation or anti-aggregation therapy. They deteriorated owing to DASH from 9 hours to 3 days after TBI. Three of the four patients underwent craniotomy for evacuation of their hematomas. One patient, who suffered only focal neurological deficit, was treated conservatively, and her hematoma gradually resolved. Two patients died and two reached Glasgow Outcome Scores of 3 and 4 after extended inpatient rehabilitation.

CONCLUSION: A suspicion of DASH should be raised in elderly, anticoagulated, mild TBI patients, including those who present to the emergency department with Glasgow Coma Scores of 15 and normal computed tomographic scans after injury. Based on our experience, we recommend that elderly, anticoagulated mild TBI patients should be admitted for 24 to 48 hours of observation after injury.

KEY WORDS: Anticoagulation, Delayed subdural hematoma, Elderly patients, Intracranial injury, Glasgow coma scale, Mild traumatic brain injury, Subdural hematoma

Neurosurgery 58:851-856, 2006

DOI: 10.1227/01.NEU.0000209653.82936.96

www.neurosurgery-online.com

More than one million patients experience blunt traumatic brain injury (TBI) in the United States and Canada each year, with 66 to 75% of the injuries classified as minor (15, 19, 35). Mild TBI frequently occurs in elderly patients, many of whom are treated with anticoagulants, which are known to increase the risk of bleeding events (14, 22, 32, 38, 45, 46, 49).

Most mild TBI patients do not develop significant neurosurgical complications. Retrospective studies report incidence of intracranial lesions on computed tomographic (CT) scans in 16 to 28% of patients (7, 21). More recently, prospective studies have found that 3 to 13% of mild TBI patients with Glasgow Coma Scores (GCS) of 15 had intracranial lesions on CT scans (7, 12, 19, 21, 27, 34, 44).

Posttraumatic intracranial hemorrhages, including epidural hematoma (EDH), subdural

hematoma (SDH), subarachnoid hemorrhage, intracerebral hemorrhage (ICH), and intraventricular hemorrhage, are usually seen in the initial CT scan. But, a small subset of head trauma patients experience delayed intracranial bleeding. Delayed ICH, delayed EDH, and delayed chronic SDH are discussed in the literature (2, 3, 8, 10, 31, 37, 39, 40, 43, 45, 46), and may occur after a normal CT scan at admission. However, delayed acute SDH (DASH) is rarely reported. Cohen and Gude-man (6) define DASH as acute SDH that is not apparent on the initial CT scan, but appears on a follow-up CT scan during the patient's post-injury course. They report DASH incidence of approximately 0.5% among operatively treated acute SDH patients at their institution.

We present here a group of elderly patients on anticoagulation who experienced DASH

after mild TBI. On admission, all patients had GCS of 15, no history of loss of consciousness (LOC) or post-traumatic amnesia, no cranial fracture, no focal neurological deficit, and normal CT scans. All deteriorated owing to DASH within hours or days after their mild trauma.

The entity of DASH has experienced a lack of critical focus in the literature (6). Reports of DASH appear only in relation to patients with severe head trauma and/or multiple traumatic injuries (6, 45, 46). The purpose of this article is to add focus to DASH as a distinct entity, to describe the occurrence of DASH in a much more lightly injured subset of patients in whom it has not been reported previously, and to raise the degree of awareness among emergency department physicians towards elderly, anticoagulated mild TBI patients.

MATERIALS AND METHODS

Hadassah Ein Kerem is the sole Level I Trauma Center in the Jerusalem region, serving a population of 800,000 people. All patients who arrive at the emergency department after experiencing head trauma are evaluated and managed according to accepted neurosurgical standards of care by the neurosurgical resident on call, under the supervision of the attending neurosurgeon. High resolution, contiguous, 3 mm, axial CT head studies, without contrast, with brain and bone windows, are performed on spiral or multidetector systems (Philips, Best, The Netherlands) in all patients on anticoagulation, even following minor head injury. The authors describe their experience treating four mild TBI patients who later deteriorated as a result of DASH.

RESULTS

Four patients, two men and two women aged 65 to 86 years (mean, 73 yr), who presented to the emergency department after minor head trauma between January 2002 and June 2004, are included in this study. All were treated with chronic anticoagulation medication, and one patient was also on antiplatelet therapy. All patients had a GCS of 15, no history of LOC, no focal neurological deficit, no evidence of cranial fracture, and normal head CT scans on arrival at the emergency department. All subsequently developed DASH, with rapid neurological deterioration.

Three of the four patients underwent craniotomy for evacuation of their hematomas. The two male patients died after complicated postoperative courses. One female patient underwent surgical evacuation and rehabilitation, eventually achieving a Glasgow Outcome Score (GOS) of 3. In the second female patient, the hematoma was treated conservatively. She achieved a GOS of 4.

Patient 1

An 86-year-old man was hospitalized for treatment of pneumonia. He was receiving 100 mg of aspirin and 40 mg of subcutaneous low molecular weight heparin (enoxaparin)

daily owing to ischemic heart disease. On admission, the patient's neurological examination was normal and blood tests, including a clotting screen, were unremarkable. Two days after admission, the patient fainted and hit his head. He was awake and oriented immediately after the fall, with a GCS of 15. Physical examination revealed slight scalp bruising. He had no LOC or amnesia. A head CT scan performed 6.5 hours after the fall revealed moderate brain atrophy with no evidence of intracranial hemorrhage (*Fig. 1A*). During the next 2 days, the patient did well.

On Day 3, the patient was found comatose in his bed, with bilateral, dilated, nonreactive pupils and a decerebrate response to pain (GCS 4). An emergency CT scan revealed a large acute SDH on the right with midline shift (*Fig. 1B*). The patient underwent an emergency craniotomy with evacuation of a large subdural clot. He expired on postoperative Day 6.

Patient 2

A 69-year-old man presented to the emergency department after a fall from his bed. There was no LOC or amnesia, and no sign of cranial fracture. The patient was on anticoagulation with Coumadin (DuPont Pharmaceuticals, Wilmington, DE) owing to a prosthetic aortic valve, and on hemodialysis owing to end-stage renal disease. His initial international normalized ratio (INR) was 2.99. A CT scan obtained 3 hours after the fall revealed an old infarction in the right occipital region and generalized atrophy (*Fig. 1C*), without evidence of intracranial hemorrhage. He was discharged from the emergency department alert and without focal neurological deficit.

Approximately 12 hours after the fall, the patient's level of consciousness abruptly deteriorated. Upon return to the emergency department, he opened his eyes to voice stimulation and localized to painful stimuli with no verbal response (GCS 9). His pupils were equal and reactive to light bilaterally. There was obvious left-sided weakness. Emergent head CT scanning demonstrated a large right side acute SDH with mass effect (*Fig. 1D*). Fresh frozen plasma and vitamin K were given concomitantly, before craniotomy and evacuation of the hematoma. After surgery, the patient was conscious with left-side weakness. Postoperative CT scanning revealed fair hematoma evacuation, but the patient experienced a series of infections and died after 3 months.

Patient 3

A 65-year-old woman on Coumadin because of mitral valve replacement presented to the emergency department after she fell and experienced minor TBI. She had no history of LOC or amnesia and no sign of cranial fracture. Her neurological exam was normal. Initial head CT scan was without sign of intracranial hemorrhage (*Fig. 1E*). Her INR was 3.03. After 6 hours of observation, she was discharged home.

The following day, she was found unconscious and was transferred immediately to the emergency department. On neurological examination, she did not open her eyes, and responded to pain stimulus with left side pain localization and

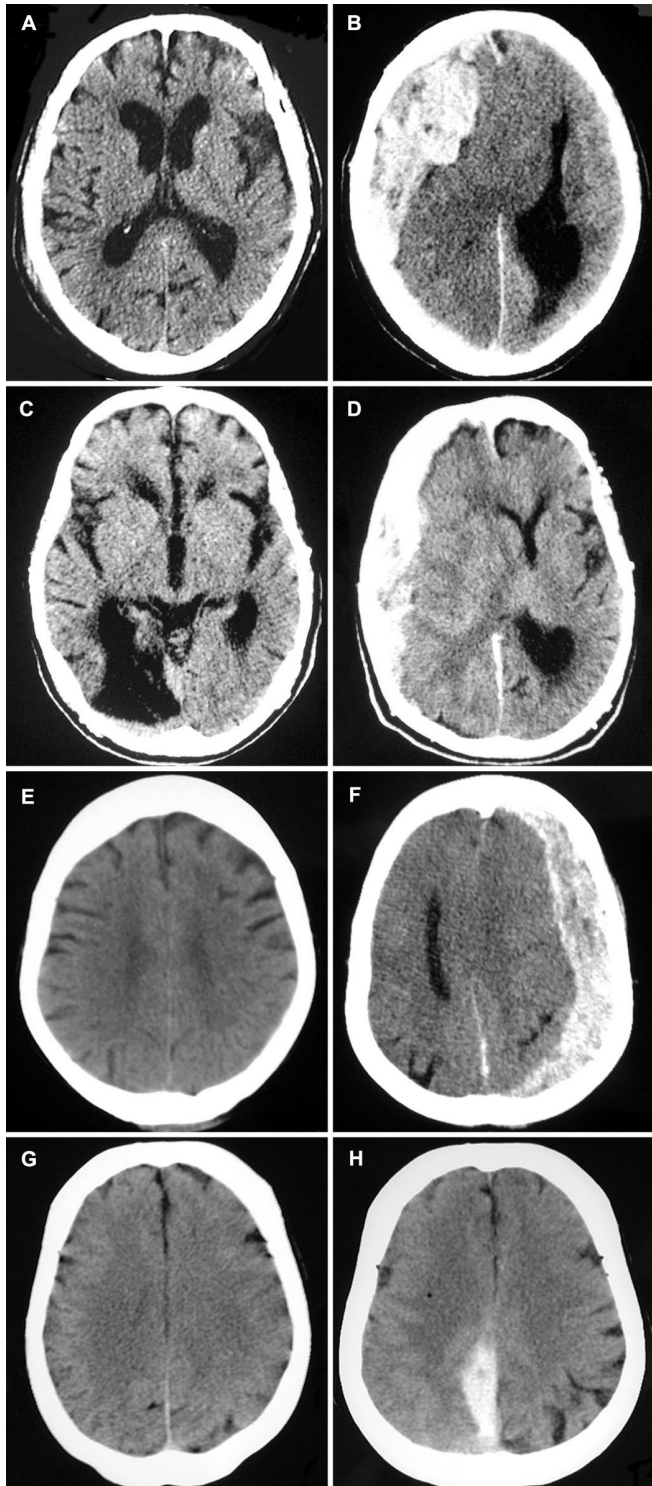


FIGURE 1. A, head CT scan in an 86-year-old man (Patient 1) obtained 6.5 hours after mild TBI revealing moderate brain atrophy. B, head CT scan in the same patient, performed after abrupt neurological deterioration 3 days after trauma, revealing a large right acute subdural hematoma with mass effect. C, head CT scan in a 69-year-old man (Patient 2), obtained in the emergency department approximately 3 hours after a fall in the nursing home where the patient resided, revealing an old infarction in the right occipital region and generalized atrophy. D, repeat head CT scan, performed 12 hours after the initial fall owing to a sudden deterioration in the patient's consciousness, with obvious left-sided weakness, revealed a large right side acute subdural hematoma with mass effect and consequent subfalcine herniation. E, initial posttrauma head CT scan in a 65-year-old woman (Patient 3). F, 1 day after her mild TBI, the patient was found unconscious at her home. At readmission, she had right hemiplegia and her left pupil was fixed and dilated. Head CT scanning revealed a large acute subdural hematoma. G, normal head CT scan upon admission in a 72-year-old woman (Patient 4) who was assaulted when her home was burglarized. H, a second CT scan, obtained 1 day later, after the patient developed left leg plegia, revealing acute interhemispheric subdural hematoma.

uation of the hematoma were performed. Postoperatively, the left pupil became small and reactive, and a CT scan demonstrated absence of SDH. Eventually the patient improved neurologically, and, 26 months later, she has a GOS of 3.

Patient 4

A 72-year-old woman on Coumadin because of a history of paroxysmal atrial fibrillation was assaulted and suffered minor head trauma. She arrived at the emergency department of a community hospital alert and lucid, with no neurological deficit (GCS 15), no history of LOC, and no sign of cranial fracture. Her INR at presentation was 3.2. Her initial head CT scan was normal (Fig. 1G). Her Coumadin was changed to enoxaparin and she was admitted for observation.

The next day, she developed severe progressive headache and weakness in her left leg. Repeat head CT scanning revealed an acute interhemispheric SDH (Fig. 1H). She was transferred to our hospital conscious, lucid, and responsive, but with full plegia of the left leg. During the hospitalization, she was treated conservatively owing to clinical and radiological improvement. One year later, she has a GOS of 4.

DISCUSSION

Many studies address risk factors in patients with mild TBI (1, 3-5, 12, 13, 19, 23, 27, 29, 40, 47, 48). Although the great majority of these patients make uneventful recoveries, misdiagnosis often results in death, a prolonged vegetative state, or significant disability (3, 7, 16, 24, 25, 27, 28, 40, 41). Thus accurate evaluation and treatment of patients who initially seem to be at low risk is one of the most important factors in the reduction of mortality in head-injured patients (19, 28, 47, 48).

Guidelines to determine which mild TBI patients should undergo CT scanning, remain for observation, or be discharged home continue to evolve. It is generally accepted that

right side extension (GCS 7). Her left pupil was fixed and dilated. An emergent head CT scan revealed large acute SDH with midline shift (Fig. 1F). She received fresh frozen plasma and vitamin K, and an emergency left craniotomy and evac-

elderly TBI patients are at greater risk for clinically important brain injury (1, 5, 12, 16, 19, 23, 27, 40, 47, 48). Increasing age is associated with a higher risk of intracranial lesions on CT scans in head-injured patients (5, 18, 19, 22, 27, 47, 48, 51), and elderly patients with ICH tend to have worse outcomes (16, 21, 36). Oral anticoagulation is associated with a significant risk of intracranial bleeding, even after minor head trauma (13, 14, 16, 20, 29, 30, 46). As a result, TBI patients with coagulopathy are often included in a high-risk group regardless of clinical presentation (1, 3, 5, 16, 23, 40, 48).

We reviewed several recently proposed guidelines for the management of mild TBI patients, with a special focus on discussion of patients who are older and anticoagulated (13, 19, 23, 40, 46–48). The European Federation of Neurological Societies (48) recommends that patients with a GCS of 15 after mild TBI, who are over 60 years of age or who are on anticoagulation, be admitted to the hospital for 24-hour observation. In a prospective study of 1101 mild TBI patients, Ibanez et al. (23) found positive CT findings to be very significantly related to both coagulation disorder and patients older than 65 years of age. The authors included older and anticoagulated patients in a high risk group. In a prospective study of 520 mild TBI patients, Haydel et al. (19) found that patients over the age of 60 years were three times more likely to have a positive CT scan than younger patients and found age to be one of seven risk factors predicting positive CT findings.

Both delayed posttraumatic ICH and EDH have been well described in the neurosurgical literature (2, 6, 17, 33, 37, 39, 45, 50). DASH, however, is rarely mentioned. Cohen and Gudeman (6) described their experience with DASH in patients with severe TBI. The occurrence of DASH is mentioned in several large series of head trauma patients, but without discussion or analysis (1, 7, 12, 31, 46).

One commonly discussed mechanism for development of acute SDH is rupture of bridging veins. Cerebral veins empty into the dural sinuses, which are adherent to the inner table of the skull. As the veins cross the subdural space, they have little supporting structure, and are therefore most vulnerable to injury at this point. In the presence of cerebral atrophy, which is common in elderly patients, bridging veins are stretched and transverse a greater distance in the subdural space. Cohen and Gudeman (6) and others (9, 26, 42) suggest that rupture of these veins is the mechanism for DASH in patients with trauma-induced hypotension and/or cerebral edema. In 1961, before the CT era, Drake (11) noted that small, perisylvian cerebral arteries were the origin of bleeding in 11 of 100 operated acute SDH patients. These arteries protrude through the arachnoid and are adherent to the dura mater. He reported that six patients with bleeding of arterial origin experienced delayed deterioration, some owing to subacute SDH, and suggested that this phenomena occurs because of a tiny opening in the ruptured artery.

In patients with hypotension, delayed bleeding may develop as blood pressure returns to normal after resuscitation. Suggested mechanisms for the formation of DASH in the presence of cerebral edema and elevated ICP include intense

treatment to reduce ICP by CSF drainage, administration of mannitol, or evacuation of an accompanying mass lesion. These mechanisms may promote formation of DASH in severely injured trauma patients, and the injuries may well be aggravated by coagulopathy, but they do not explain the occurrence of DASH in the subpopulation of elderly, anticoagulated, mild TBI patients described here. The pathogenesis of DASH in these patients remains obscure.

In this series, we report our experience with four mild TBI patients aged 65 to 89 years, with no history of LOC, post-traumatic amnesia, or epileptic seizure, no evidence of cranial fracture or cranial soft-tissue injury, and no evidence of drug use or intoxication. At the first evaluation after trauma, they had normal neurological examinations and normal CT scans. All were on anticoagulation therapy. Three patients deteriorated within 24 hours after TBI. The fourth patient deteriorated during the night, and was found deeply unconscious 72 hours after TBI. Three patients underwent operation. One was treated conservatively, and her hematoma gradually resolved. The two male patients were sicker and eventually died. One of them arrived after deterioration with a GCS of 4, and the second man experienced several unrelated complex medical problems. The two female patients survived with GOS 3 and 4. One of these women, at an age of 65 years, was the youngest patient in the series. The second had an interhemispheric subdural hematoma, and experienced only a focal neurological deficit.

This series suggests that DASH occurs in some older mild TBI patients who receive anticoagulation. This is only a small series showing our recent experience, the common denominator in these patients is not fully established, and the pathogenesis for DASH is not understood. However, we wish to raise the degree of awareness among emergency department physicians who treat trauma patients on a daily basis that elderly, anticoagulated patients may face higher risk for acute ICH and delayed deterioration after mild TBI. We define this population as high risk minor head injury. Previously we managed these patients with full neurological examination and head CT scans. Patients who had normal examination and normal CT scans were usually discharged home with a responsible observer. We have since changed this policy. Elderly, anticoagulated, mild TBI patients, including those with normal neurological examination and normal CT scans, are hospitalized for 48-hour observation in the Department of Neurosurgery.

In conclusion, we emphasize the need to maintain a high level of vigilance in mild TBI patients with risk factors including anticoagulation therapy, advanced age, and cerebral atrophy. In these patients even a normal neurological exam and normal CT scan does not preclude subsequent rapid deterioration. We recommend that such patients be admitted for neurosurgical observation. Follow-up CT scans should be obtained immediately upon any change in neurological condition.

REFERENCES

1. Arianta C, Caroli M, Balbi S: Management of head-injured patients in the emergency department: A practical protocol. *Surg Neurol* 48:213–219, 1997.

2. Ashkenazi E, Constantini S, Pomeranz S, Rivkind AI, Rappaport ZH: Delayed epidural hematoma without neurologic deficit. *J Trauma* 30:613–615, 1990.
3. Atzema C, Mower WR, Hoffman JR, Holmes JF, Killian AJ, Oman JA, Shen AH, Greenwood SD: Defining “therapeutically inconsequential” head computed tomographic findings in patients with blunt head trauma. *Ann Emerg Med* 44:47–56, 2004.
4. Batchelor J, McGuinness A: A meta-analysis of GCS 15 head injured patients with loss of consciousness or post-traumatic amnesia. *Emerg Med J* 19:515–519, 2002.
5. Borczuk P: Predictors of intracranial injury in patients with mild head trauma. *Ann Emerg Med* 25:731–736, 1995.
6. Cohen T, Gudeman S: Delayed Traumatic Intracranial Hematoma., in Narayan RK (ed): *Trauma*, New York, McGraw-Hill, 1995, pp 689–701.
7. Culotta VP, Sementilli ME, Gerold K, Watts CC: Clinicopathological heterogeneity in the classification of mild head injury. *Neurosurgery* 38:245–250, 1996.
8. Deitch D, Kirshner HS: Subdural hematoma after normal CT. *Neurology* 39:985–987, 1989.
9. Doherty DL: Posttraumatic cerebral atrophy as a risk factor for delayed acute subdural hemorrhage. *Arch Phys Med Rehabil* 69:542–544, 1988.
10. Domenicucci M, Signorini P, Strzelecki J, Delfini R: Delayed post-traumatic epidural hematoma. A review. *Neurosurg Rev* 18:109–122, 1995.
11. Drake CG: Subdural haematoma from arterial rupture. *J Neurosurg* 18:597–601, 1961.
12. Fabbri A, Servadei F, Marchesini G, Morselli-Labate AM, Dente M, Iervese T, Spada M, Vandelli A: Prospective validation of a proposal for diagnosis and management of patients attending the emergency department for mild head injury. *J Neurol Neurosurg Psychiatry* 75:410–416, 2004.
13. Fabbri A, Vandelli A, Servadei F, Marchesini G: Coagulopathy and NICE recommendations for patients with mild head injury. *J Neurol Neurosurg Psychiatry* 75:1787–1788, 2004.
14. Ferrera PC, Bartfield JM: Outcomes of anticoagulated trauma patients. *Am J Emerg Med* 17:154–156, 1999.
15. Francel P, Alves W, Jane JA: Mild Head Injury in Adults, in Joumans JR (ed): *Neurological Surgery*, Philadelphia, WB Saunders, 1996, ed 4, pp 1595–1617.
16. Gomez PA, Lobato RD, Ortega JM, de la Cruz J: Mild head injury: differences in prognosis among patients with a Glasgow Coma Scale score of 13 to 15 and analysis of factors associated with abnormal CT findings. *Br J Neurosurg* 10:453–460, 1996.
17. Gudeman SK, Kishore PR, Miller JD, Girevendulis AK, Lipper MH, Becker DP: The genesis and significance of delayed traumatic intracerebral hematoma. *Neurosurgery* 5:309–313, 1979.
18. Gutman M, Moulton R, Sullivan I, Hotz G, Tucker W, Muller P: Risk factors predicting operable intracranial hematomas in head injury. *J Neurosurg* 77:9–14, 1992.
19. Haydel M, Preston C, Trevor J, Luber S, Blandeau E, DeBlieux P: Indications for computer tomography in patients with minor head injury. *N Engl J Med* 343:100–105, 2000.
20. He J, Whelton PK, Vu B, Klag MJ: Aspirin and risk of hemorrhagic stroke: A meta-analysis of randomized controlled trials. *JAMA* 280:1930–1935, 1998.
21. Hsiang J, Yeung T, Yu A, Poon W: High-risk mild head injury. *J Neurosurg* 87:234–238, 1997.
22. Hylek EM, Singer DE: Risk factors for intracranial hemorrhage in outpatients taking warfarin. *Ann Intern Med* 120:897–902, 1994.
23. Ibanez J, Arikan F, Pedraza S, Sanchez E, Poca MA, Rodriguez D, Rubio E: Reliability of clinical guidelines in the detection of patients at risk following mild head injury: Results of a prospective study. *J Neurosurg* 100:825–834, 2004.
24. Iuvara-Bommeli A, de Tribolet N: Delayed intracranial hematomas following cranio-cerebral trauma [in French]. *Schweiz Med Wochenschr* 121:646–652, 1991.
25. Jennett B: Epidemiology of head injury. *J Neurol Neurosurg Psychiatry* 60:362–369, 1996.
26. Jennett B, Teasdale G (eds): *Management of Head Injuries*. Philadelphia, FA Davies Co., 1981, pp 155–156, ed 3.
27. Jeret JS, Mandell M, Anziska B, Lipitz M, Vilceus AP, Ware JA, Zesiewicz TA: Clinical predictors of abnormality disclosed by computed tomography after mild head trauma. *Neurosurgery* 32:9–16, 1993.
28. Klauber MR, Marshall LF, Luerssen TG, Frankowski R, Tabaddor K, Eisenberg HM: Determinants of head injury mortality: Importance of the low risk patient. *Neurosurgery* 24:31–36, 1989.
29. Li J, Brown J, Levine M: Mild head injury, anticoagulants, and risk of intracranial injury. *Lancet* 357:771–772, 2001.
30. Linkins LA, Choi PT, Douketis JD: Clinical impact of bleeding in patients taking oral anticoagulant therapy for venous thromboembolism: A meta-analysis. *Ann Intern Med* 139:893–900, 2003.
31. Lobato RD, Rivas JJ, Gomez PA, Castaneda M, Canizal JM, Sarabia R, Cabrera A, Munoz MJ: Head-injured patients who talk and deteriorate into coma. Analysis of 211 cases studied with computerized tomography. *J Neurosurg* 75:256–261, 1991.
32. Mathiesen T, Benediktsdottir K, Johnsson H, Lindqvist M, von Holst H: Intracranial traumatic and non-traumatic haemorrhagic complications of warfarin treatment. *Acta Neurol Scand* 91:208–214, 1995.
33. Mertol T, Guner M, Acar U, Atabay H, Kirisoglu U: Delayed traumatic intracerebral hematoma. *Br J Neurosurg* 5:491–498, 1991.
34. Miller EC, Holmes JF, Derlet RW: Utilizing clinical factors to reduce head CT scan ordering for minor head trauma patients. *J Emerg Med* 15:453–457, 1997.
35. National Center for Injury Prevention and Control: Report to Congress on mild traumatic brain injury in the United States: Steps to prevent a serious health problem. Atlanta, Centers for Disease Control and Prevention, 2003.
36. Pentland B, Jones PA, Roy CW, Miller JD: Head injury in the elderly. *Age Ageing* 15:193–202, 1986.
37. Poon WS, Rehman SU, Poon CY, Li AK: Traumatic extradural hematoma of delayed onset is not a rarity. *Neurosurgery* 30:681–686, 1992.
38. Reynolds FD, Dietz PA, Higgins D, Whitaker TS: Time to deterioration of the elderly, anticoagulated, minor head injury patient who presents without evidence of neurologic abnormality. *J Trauma* 54:492–496, 2003.
39. Riesgo P, Piquer J, Botella C, Orozco M, Navarro J, Cabanes J: Delayed extradural hematoma after mild head injury: Report of three cases. *Surg Neurol* 48:226–231, 1997.
40. Servadei F, Teasdale G, Merry G: Defining acute mild head injury in adults: a proposal based on prognostic factors, diagnosis, and management. *J Neurotrauma* 18:657–664, 2001.
41. Shackford SR, Wald SL, Ross SE, Cogbill TH, Hoyt DB, Morris JA, Mucha PA, Pachter HL, Sugerman HJ, O'Malley K: The clinical utility of computed tomographic scanning and neurologic examination in the management of patients with minor head injuries. *J Trauma* 33:385–394, 1992.
42. Shenkin HA: Acute subdural hematoma. Review of 39 consecutive cases with high incidence of cortical artery rupture. *J Neurosurg* 57:254–257, 1982.
43. Snoey ER, Levitt MA: Delayed diagnosis of subdural hematoma following normal computed tomography scan. *Ann Emerg Med* 23:1127–1131, 1994.
44. Spektor S, Agus S, Merkin V, Constantini S: Low-dose aspirin prophylaxis and risk of intracranial hemorrhage in patients older than 60 years of age with mild or moderate head injury: A prospective study. *J Neurosurg* 99:661–665, 2003.
45. Stein SC, Spettell C, Young G, Ross SE: Delayed and progressive brain injury in closed-head trauma: Radiological demonstration. *Neurosurgery* 32:25–30, 1993.
46. Stein SC, Young GS, Talucci RC, Greenbaum BH, Ross SE: Delayed brain injury after head trauma: Significance of coagulopathy. *Neurosurgery* 30:160–165, 1992.
47. Stiell IG, Wells GA, Vandemheen K, Clement C, Lesiuk H, Laupacis A, McKnight RD, Verbeek R, Brison R, Cass D, Eisenhauer ME, Greenberg G, Worthington J: The Canadian CT Head Rule for patients with minor head injury. *Lancet* 357:1391–1396, 2001.
48. Vos PE, Battistin L, Birbamer G, Gerstenbrand F, Potapov A, Prevec T, Stepan ChA, Traubner P, Twijnstra A, Vecsei L, von Wild K: EFNS guideline on mild traumatic brain injury: Report of an EFNS task force. *Eur J Neurol* 9:207–219, 2002.
49. Wong KS, Mok V, Lam WW, Kay R, Tang A, Chan YL, Woo J: Aspirin-associated intracerebral hemorrhage: Clinical and radiologic features. *Neurology* 54:2298–2301, 2000.

50. Young HA, Gleave JR, Schmidek HH, Gregory S: Delayed traumatic intracerebral hematoma: Report of 15 cases operatively treated. *Neurosurgery* 14:22–25, 1984.
51. Zwimpfer TJ, Brown J, Sullivan I, Moulton RJ: Head injuries due to falls caused by seizures: A group at high risk for traumatic intracranial hematomas. *J Neurosurg* 86:433–437, 1997.

COMMENTS

Itshayek et al. describe four elderly patients on anticoagulation therapy who experienced delayed acute subdural hematomas after minor head trauma. The authors correctly point out that delayed intracranial hematomas are more commonly described in the brain parenchyma or in the epidural space. They are also correct that most of the delayed subdural hematomas described in the recent literature follow more severe head trauma. They thus apprise the neurosurgical community that a delayed acute subdural hematoma may occur in elderly patients on anticoagulation. Because we do not have a denomination, the incidence is unknown.

I was surprised that the authors found these hematomas to be venous in origin. In the older literature, delayed arterial hematomas have been reported to occur (1). It is known that traumatic intracranial aneurysms commonly rupture after a delay. Similarly, I would speculate that the subdural hematomas arose from a damaged vessel that bled in a delayed fashion. I can only assume that, in the cases presented, it was a damaged vein that bled.

Patients who “talk and die” have always troubled neurosurgeons. The authors propose that elderly patients on anticoagulants who experience minor head trauma should be observed for 48 hours. It is unsettling that their first patient experienced a fatal subdural hemorrhage 72 hours after his trauma while under observation in the hospital. Monitoring patients for the rare hemorrhage after head trauma poses a challenge to the neurosurgical community.

Allan H. Friedman
Durham, North Carolina

1. Drake CG: Subdural haematoma from arterial rupture. *J Neurosurg* 18:597–601, 1961.

Itshayek et al. have summarized four cases of elderly patients on anticoagulation or antiplatelet therapy who developed acute subdural hematomas well after presenting with a non-focal neurological exam and unremarkable head computed tomographic scans. Although delayed deterioration is typically encountered with small asymptomatic epidural hematomas that rapidly enlarge several hours after the initial injury, this report emphasizes the importance of close observation for at least 24 to 48 hours in all patients with head trauma,

particularly those with additional risk factors such as antiplatelet therapy or anticoagulation.

Ricardo J. Komotar
E. Sander Connolly, Jr.
New York, New York

The authors describe a theoretically well known complication of anticoagulation therapy: hemorrhage after trauma. Their point that actual cases have not been described in the literature is, however, valid. I think this basic clinical observation in four patients merits publication to show that this is not just a theoretical threat, but can be observed in patients. I reviewed the literature and could, to my surprise, not find any comprehensive description of this category of patients. Given economic pressures, these patients may be sent home too early and are then exposed to comparatively high risks of delayed deterioration. We cannot usually heal primary injuries, but we should not fail to prevent fatal deterioration if at all possible.

Tiit Mathiesen
Stockholm, Sweden

This article on delayed post-traumatic subdural hematomas in the elderly who are anticoagulated should be seen as one part of a greater problem, i.e., the increasing frequency of anticoagulation and the development of intraparenchymal hemorrhages after trivial falls. Many years ago, the Traumatic Brain Injury research group from Hong Kong presented a study on the need to observe the elderly for 48 hours if the head was struck. This provided recognition that the softened, often atrophied, brain is more vulnerable to bleeding. Itshayek et al. focus on subdural hematomas, but this is a relatively limited part of the difficulty. We need to educate Trauma and Emergency Room physicians that patients on anticoagulation must be admitted for at least 24 hours of observation, even with trivial head injuries. Ongoing trials with Factor VIIA may provide evidence that this agent may have utility in these patients.

Lawrence F. Marshall
San Diego, California

The message of this paper is important for emergency room physicians, neurosurgeons, hospital administrators, and insurance companies. Neurosurgeons who hospitalize patients who are being treated with anticoagulation, who sustain what initially seems to be a minor head injury, are often faced with denial of the admission by insurance companies. In appealing such denials, it is helpful to have a recent article with the message of the devastating outcomes of missed subdurals in the elderly.

Robert G. Grossman
Houston, Texas