

Shun-ichi Nagata
Kiyoshi Kazekawa
Shuko Matsubara
Sei Sugata

Percutaneous reconstruction of the innominate bifurcation using the retrograde ‘kissing stents’ technique

Received: 22 August 2005
Accepted: 1 February 2006
Published online: 27 April 2006
© Springer-Verlag 2006

S.-i. Nagata · K. Kazekawa (✉) ·
S. Matsubara
Department of Neurosurgery,
Fukuoka University Chikushi Hospital,
377-1 Zokumyoin,
Chikushino, Fukuoka, 818-8502, Japan
e-mail: kazekawa@xb3.so-net.ne.jp
Tel.: +81-92-9211011
Fax: +81-92-928-3890

S. Sugata
Bironoki Neurosurgical Hospital,
8401-1 Noikura, Ariake,
Shibushi, Kagoshima, 899-7402, Japan

Abstract *Introduction:* Obstructions of the supraaortic vessels are an important cause of morbidity associated with a variety of symptoms. Percutaneous transluminal angioplasty has evolved as an effective and safe treatment modality for occlusive lesions of the supraaortic vessels. However, the endovascular management of an innominate bifurcation has not previously been reported.

Methods: A 53-year-old female with a history of systematic hypertension, diabetes mellitus and hypercholesterolemia presented with left hemiparesis and dysarthria. Angiography of the

innominate artery showed a stenosis of the innominate bifurcation.

Results: The lesion was successfully treated using the retrograde kissing stent technique via a brachial approach and an exposed direct carotid approach. *Conclusion:* The retrograde kissing stent technique for the treatment of a stenosis of the innominate bifurcation was found to be a safe and effective alternative to conventional surgery.

Keywords Innominate bifurcation · Retrograde · Kissing stent technique

Introduction

Obstructions of the supraaortic vessels are an important cause of morbidity associated with a variety of symptoms. Ischemic stroke is known to occur as a result of either an artery-to-artery embolism or hemodynamic compromise. Bypass grafting is considered to be the treatment of choice for obstructions of the supraaortic vessels. However, the morbidity and mortality associated with such cases is significant [1]. Percutaneous transluminal angioplasty (PTA), either with or without stent placement, has evolved as an effective and safe treatment modality for occlusive lesions of the supraaortic vessels [2–9]. However, the endovascular management of an innominate bifurcation has not previously been reported.

We report here the use of the novel retrograde ‘kissing stents’ technique for the successful treatment of a stenosis of an innominate bifurcation.

Technical details

A 53-year-old female with a history of systematic hypertension, diabetes mellitus and hypercholesterolemia suffered left hemiparesis and dysarthria, and was referred to our department. Her systolic blood pressure measured in her left arm was 140 mmHg, whereas that in her right arm was 70 mmHg. Her white blood cell count and serum C-reactive protein level were within the normal limits. Magnetic resonance imaging revealed multiple infarctions in the pons (Fig. 1). Carotid ultrasonography detected a retrograde flow in the right vertebral artery. Angiography of the innominate artery showed severe stenosis of the right subclavian artery and moderate stenosis of the right proximal common carotid artery. The origin of the right vertebral artery could just be detected, but the distal antegrade flow could not be detected (Fig. 2). We therefore concluded that the symptoms were caused by

hemodynamic compromise due to the right subclavian artery stenosis. As a result, we decided to perform subclavian stenting to prevent the occurrence of further strokes. To prevent any shifting of plaque in the common carotid artery during subclavian stenting, we planned to perform the carotid stenting simultaneously. The procedures were performed in accordance with the ethical standards of the institutional Ethics Committee, and informed consent was obtained after providing a full explanation to the patient. Aspirin (100 mg/day) and ticlopidine hydrochloride (200 mg/day) were administered for 7 days before performing angioplasty.

The patient was taken to the neuroangiography suite, where general endotracheal anesthesia was initiated. A 6F sheath was then placed percutaneously in the right brachial artery to perform subclavian stenting, and a 5F sheath was placed percutaneously in the right femoral artery for intraoperative angiography. The right common carotid artery and carotid bifurcation were exposed in a manner similar to that for a standard carotid endarterectomy. The activated clotting time was maintained at 200–250 s throughout the procedure by the injection of heparin. A 5F catheter was placed in the innominate artery. A 0.035-inch guidewire, 260 cm in length, was passed carefully through the stenosis of the right subclavian artery and was then led to the brachial sheath under fluoroscopic guidance. This procedure was performed to stabilize the PTA catheter for the subclavian artery. The right internal carotid artery was clamped, and a 7F sheath was inserted into the right common carotid artery in a retrograde fashion under fluoroscopic guidance to perform carotid stenting. A 0.035-inch guidewire, 150 cm in length, was then passed through the stenosis of the right common carotid artery without any difficulty. A 5×40 mm compliant PTA balloon catheter was then navigated across the stenosis of the subclavian artery via the brachial approach, and an

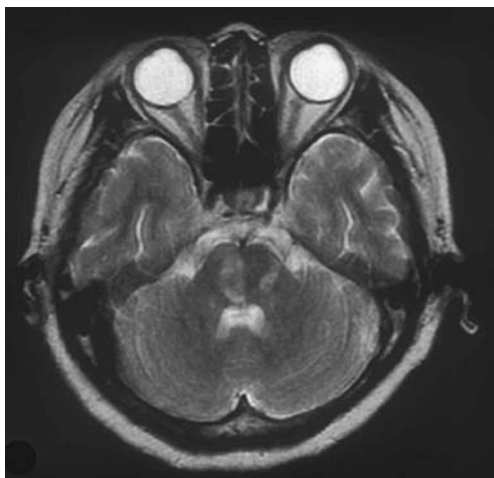


Fig. 1 Magnetic resonance image revealing multiple infarctions in the pons

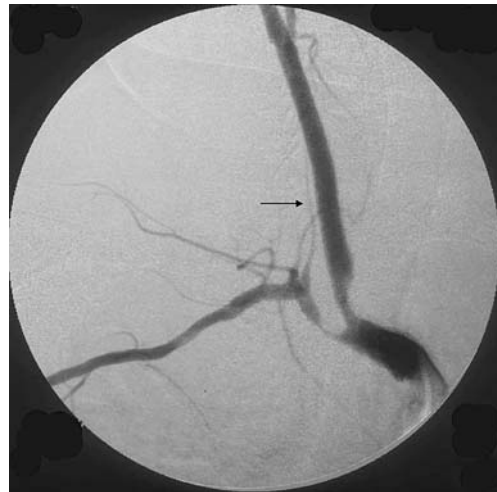

Fig. 2 Preoperative angiography of the innominate artery demonstrating stenosis of the innominate bifurcation. The origin of the right vertebral artery can just be detected (*arrow*), but the distal antegrade flow cannot be detected

8×40 mm compliant PTA balloon catheter was navigated across the stenosis of the common carotid artery via the carotid approach. Balloon angioplasty was performed simultaneously to prevent the shifting of any plaque (Fig. 3a). The balloon catheters were next each exchanged for 8×20 mm and 10×30 mm Easy Wall stents (Boston Scientific Corporation, Natick, Mass.), which were placed simultaneously (Fig. 3b). Postdilations were performed using 8×20 mm and 10×20 mm compliant PTA balloon catheters because residual stenosis was detected (Fig. 3c). Angiography of the innominate artery performed after these procedures revealed excellent dilatation of the innominate bifurcation and a good antegrade flow of the right vertebral artery (Fig. 4). The sheath placed in the carotid artery was removed and the pooled blood and debris were flushed out via the arteriotomy. The arteriotomy site was closed by suturing with 6-0 nylon. Thereafter, the other sheaths were removed. Heparinization was discontinued immediately but was not reversed.

The postoperative course was uneventful. The values of the systolic blood pressure in both arms were the same. The patient continued to receive aspirin and ticlopidine hydrochloride. Follow-up angiography at 3 months demonstrated an excellent dilatation of both arteries, and the antegrade flow of the right vertebral artery was also improved.

Discussion

The ‘kissing stents’ technique has been proposed for the treatment of aortoiliac bifurcation. At the bifurcation, the inflation of a single balloon in one artery can cause compression of the contralateral artery, resulting in a relatively poor dilatation with a risk of contralateral

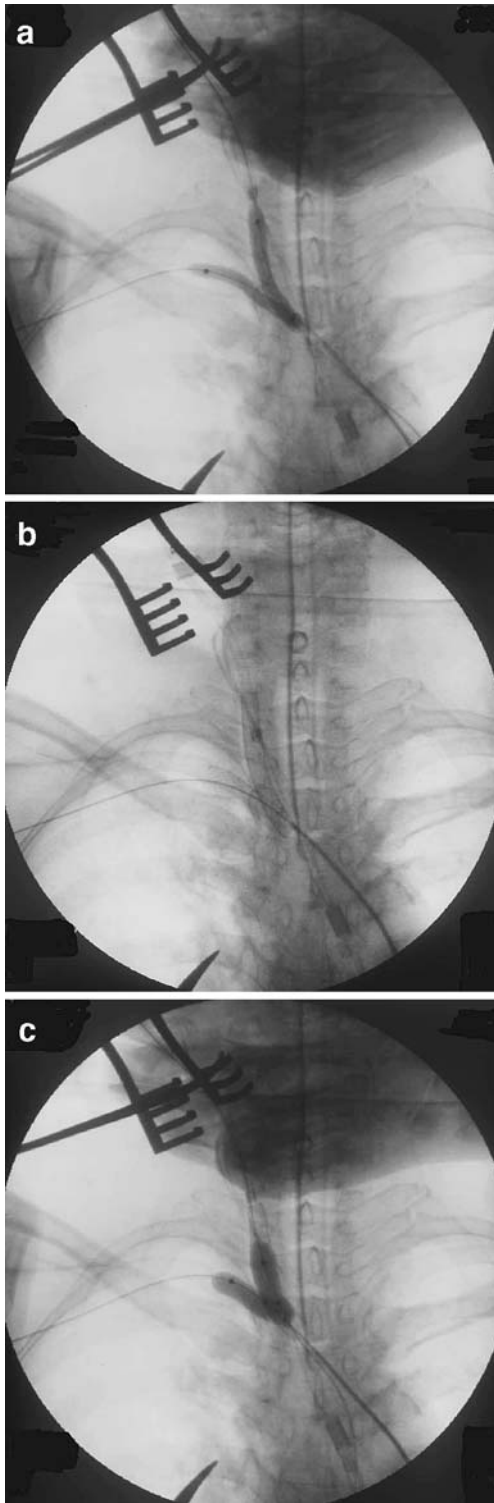


Fig. 3 Balloon angioplasty and the placement of the stents were performed simultaneously: **a** predilatation, **b** stent placement, **c** Postdilatation

embolization and plaque displacement. The simultaneous inflation of bilateral artery balloons can avoid these

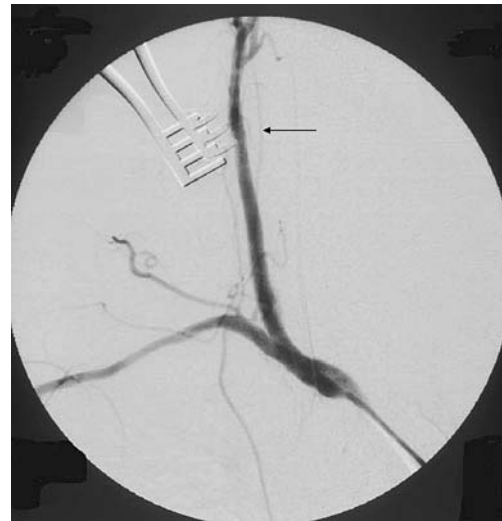

Fig. 4 Postoperative angiography of the innominate artery demonstrating excellent dilatation of the innominate bifurcation and antegrade flow of the right vertebral artery (*arrow*)

problems, and the simultaneous placement of stents using the kissing stents technique can further decrease the incidence of these complications [10, 11]. Therefore, we treated the innominate bifurcation using the kissing stents technique in the present case. We used Easy Wall stents, which are self-expandable stents, because the motion of postoperative everyday life may deform the stents deposited in the subclavian artery and the common carotid artery. The predilatations were performed to reduce the shortening of the stents.

The transfemoral route is used in most cases for the endovascular treatment of the supraaortic vessels. However, transfemoral intervention is difficult in some cases, due to the instability of the guiding catheter, attributed to the tortuosity of the supraaortic vessels [2–4]. Under these conditions, alternative vascular access routes can be used. In the present case, we speculated that transfemoral intervention was difficult because of the instability of the guiding catheter, attributable to the tortuosity of the innominate artery. Therefore, we used the brachial route and directly exposed the carotid route because we were able to perform hemostasis after sheath removal [2, 3]. In addition, the exposed internal carotid artery can be clamped to prevent an embolism of the anterior circulation during these procedures [2, 3].

In most cases, the plaque in the subclavian artery is stable, and the presence of ulcerated plaque is rare [8, 9]. The protective effect of the flow inversion in the vertebral artery due to the subclavian steal phenomenon has been shown [5–7]. The restoration of normal arterial flow in the vertebral artery is delayed for several seconds, or even for as long as 30 min, after angioplasty of the subclavian artery [5]. We therefore treated the stenosis of the subclavian artery without the use of any other protective techniques in the present case. By contrast, the common carotid artery

was treated with the use of protective techniques by clamping the internal carotid artery to protect against embolization during the procedure. In the present case, the clamping time of the internal carotid artery was 10 min.

We covered the orifice of the vertebral artery because it was located close to the subclavian lesion. The stent covering the orifice is not necessarily a factor for immediate or late stroke [6]. In the present case, the stents protruded into the innominate artery because the stenotic lesions were located close to the innominate artery. Very little is known about the natural history of protruding metallic stents [11, 12], and therefore strict observation is needed in such cases.

The present case, presenting with a stenosis of the innominate bifurcation, was treated using the retrograde kissing stents technique. In comparison to the single stent technique via the femoral approach, the retrograde kissing stents technique has the advantages of preventing the shifting of plaque, stabilizing the PTA catheter and preventing the occurrence of embolization. We therefore consider this technique to be a safe and effective alternative to conventional surgery.

Conflict of interest statement We declare that we have no conflict of interest.

References

1. Hadjipetrou P, Cox S, Piemonte T, et al (1999) Percutaneous revascularization of atherosclerotic obstruction of aortic arch vessels. *J Am Coll Cardiol* 33:1238–1245
2. Tsutsumi M, Kazekawa K, Kodama T, et al (2003) Retrograde carotid stenting for isolated stenosis of the proximal common carotid artery. *Neurol Med Chir (Tokyo)* 43:546–549
3. Sidhu PS, Morgan MB, Walters HL, et al (1998) Technical report: Combined carotid bifurcation endarterectomy and intra-operative transluminal angioplasty of a proximal common carotid artery stenosis: an alternative to extrathoracic bypass. *Clin Radiol* 53:444–447
4. Harada K, Nakahara I, Tanaka M, et al (2004) Therapeutic strategy and outcome of stenting for subclavian and innominate artery occlusive disease. *No Shinkei Geka* 32:151–158
5. Ringelstein EB, Zeumer H (1984) Delayed reversal of vertebral artery blood flow following percutaneous transluminal angioplasty for subclavian steal syndrome. *Neuroradiology* 26:189–198
6. Brountzos EN, Petersen B, Binkert C, et al (2004) Primary stenting of subclavian and innominate artery occlusive disease: a single center's experience. *Cardiovasc Intervent Radiol* 27:616–623
7. Gonzalez A, Gil-Peralta A, Gonzalez-Marcos JR (2003) Angioplasty and stenting for total symptomatic atherosclerotic occlusion of the subclavian or innominate arteries. *Cerebrovasc Dis* 13:107–113
8. Bruckmann H, Ringelstein EB, Buchner H, et al (1986) Percutaneous transluminal angioplasty of vertebral artery: a therapeutic alternative to operative reconstruction of proximal vertebral artery stenoses. *J Neurol* 233:336–339
9. Tanaka M, Taki W, Miyamoto S, Nakahara I, Sadato A, Matsumoto K, Kikuchi H (1994) Percutaneous transluminal angioplasty (PTA) for stenosis at subclavian artery and the origin of vertebral artery: therapeutic indication and some adjunctive safe methods during PTA. *No Shinkei Geka* 22:939–946
10. Haulon S, Mounier-Vehier C, Gaxotte V, et al (2002) Percutaneous reconstruction of the aortoiliac bifurcation with the “kissing stents” technique: long-term follow-up in 106 patients. *J Endovasc Ther* 9:363–368
11. Mohamed F, Sarkar B, Timmons G, et al (2002) Outcome of “kissing stents” for aortoiliac atherosclerotic disease, including the effect on the non-diseased contralateral iliac limb. *Cardiovasc Intervent Radiol* 25:472–475
12. Saker MB, Oppat WF, Kent SA, et al (2000) Early failure of aortoiliac kissing stents: histopathologic correlation. *J Vasc Interv Radiol* 11:333–336