

# Nocturnal Hypermotor Seizures, Suggesting Frontal Lobe Epilepsy, Can Originate in the Insula

\*Philippe Ryvlin, ‡Lorella Minotti, \*Geneviève Demarquay, §Edouard Hirsch,  
||Alexis Arzimanoglou, ‡Dominique Hoffman, †Marc Guénot, ¶Fabienne Picard, \*Sylvain Rheims,  
and ‡Philippe Kahane

Departments of \*Functional Neurology and Epileptology and †Functional Neurosurgery, Hospices Civils de Lyon and Université Claude Bernard Lyon 1, Lyon; ‡Epilepsy Surgery Unit, CHU Michallon, Grenoble; §Department of Neurology, CHU de Strasbourg, Strasbourg; and ||Department of Pediatric Epileptology, Hôpital Robert Debré, Paris, France; and ¶Epilepsy Unit, Geneva University Hospital, Geneva, Switzerland

**Summary:** *Purpose:* To report three patients with drug-resistant nocturnal hypermotor seizures (NHSs), no detectable brain lesion, and clinically defined nocturnal frontal lobe epilepsy (NFLE) or autosomal dominant NLFE (ADNFLE), whose intracerebral EEG ictal onset primarily involved the insula, rather than the mesial or orbital frontal cortex.

*Methods:* Fourteen to 15 intracerebral electrodes were implanted in each patient, primarily sampling the frontal lobes with 80 to 91 recording leads covering the most likely side of seizure onset, and two to six leads placed within the ipsilateral insula. Electrical stimulation was used to test the epileptic threshold of frontal and insular brain regions at the various recording sites.

*Results:* In all three patients, a low-voltage fast activity was recorded within the anterosuperior aspect of the insula at ic-

tal onset, either in isolation, or extending to the nearby frontal operculum in the ADNFLE patient. The role of the insula was further supported in all three patients either by the presence of high-amplitude spikes that clearly predominated over that region ( $n = 2$ ) or by triggering the patient's typical aura or seizure when applying an electrical stimulation at that site, selectively ( $n = 2$ ).

*Conclusions:* The anterosuperior portion of the insula might play a pivotal role in generating nocturnal hypermotor seizures in some patients with nonlesional drug-resistant epilepsy suggesting NFLE or ADNFLE. Whether these patients are amenable to successful surgery remain an open issue. **Key Words:** Epilepsy—Insula—Nocturnal hypermotor seizure—NFLE—ADNFLE.

Nocturnal frontal lobe epilepsy (NFLE) is characterized primarily by seizures occurring exclusively or predominantly during sleep; this semiology suggests a frontal lobe origin, as, for example, nocturnal paroxysmal dystonia (NPD) or hypermotor seizures (1). An autosomal dominant inheritance is found in 8% to 43% of patients (1–3) and led to the discovery of the first epilepsy gene a decade ago (4,5). The two mutant genes identified so far in autosomal dominant NFLE (ADNFLE) code for the  $\alpha 4$  and  $\beta 2$  subunits of the nicotinic acetylcholine receptor (nAChR) (5–7). In contrast with these major genetic advances, many uncertainties persist regarding the neural networks underlying the cryptogenic and idiopathic forms of NFLE, inasmuch as very few patients have been investigated with intracranial EEG recordings (8,9). In addition, recent data suggest that seizures arising from tem-

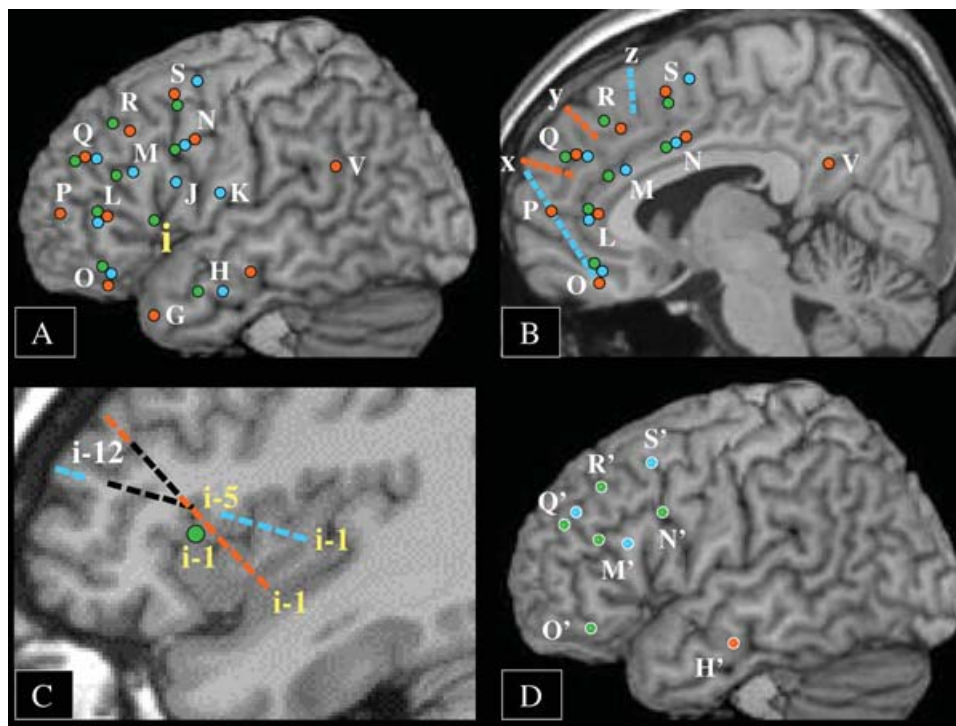
porobasal cortical dysplasia can mimic those observed in NFLE (10). A more precise knowledge of the anatomic origin of NFLE and ADNFLE seizures might allow a better understanding of the complex interaction between the underlying epileptogenic brain region, sleep, and gene dysfunction, when present, as well as a more effective surgical treatment of eligible patients. In this study, we present the hitherto unreported observation of three patients with drug-resistant cryptogenic NFLE or ADNFLE, whose intracerebral investigation demonstrated an ictal-onset zone involving primarily the insula rather the frontal lobe.

## METHODS

The three patients reported in this study were identified prospectively, within a collaborative epilepsy surgery network. They all had drug-resistant seizures, predominantly nocturnal, described as hypermotor by their relatives. Seizure frequency as well as the overall impact of the epilepsy on the patients' quality of life was judged severe

Accepted November 11, 2005.

Address correspondence and reprint requests to Dr. P. Ryvlin at Unité 301, Hôpital Neurologique, 59 bd Pinel, Lyon, 69003, France. E-mail: ryvlin@cermep.fr



**FIG. 1.** Electrode locations of patients 1 (blue), 2 (orange), and 3 (green) coregistered on a normal subject's sagittal T<sub>1</sub> MRI. *Circles*, Electrodes implanted perpendicular to the sagittal plane. *Lines of rectangles*, Oblique electrodes. **A:** Lateral sagittal view of electrodes implanted ipsilateral to the seizure-onset zone. Note that the green electrode (i) corresponds to that targeting the insula of patient 3. **B:** Mesial sagittal view of electrodes implanted ipsilateral to the seizure-onset zone. **C:** Intermediate sagittal view of the electrodes targeting the insula ipsilateral to seizure onset. Lead numbers are indicated for each electrode, with blue leads i1 to i5, and orange leads i1 to i7 being located within the insula of patients 1 and 2, respectively, because of the oblique direction of the electrode, whereas only the green leads i1 and i2 reach the insula of patient 3. *Black rectangles*, Leads that were not recorded during monitoring. **D:** Lateral sagittal view of electrodes implanted contralateral to the seizure-onset zone. The same electrode label is used in every patient, with the following correspondences: i, insula (deepest leads) and either the anterior portion of the second frontal gyrus in patients 1 and 2, or the anterior part of the frontal operculum in patient 3 (superficial leads); G, temporal pole; H, hippocampus (deepest leads) and second temporal gyrus (superficial leads); J, middle part of the frontal operculum; K, posterior part of the frontal operculum; L, anterior cingulate gyrus (deepest leads) and anterior portion of the third frontal gyrus (superficial leads); M, anterior cingulate gyrus (deepest leads) and middle portion of the third frontal gyrus (superficial leads); N, middle cingulate gyrus (deepest leads) and posterior portion of the third frontal gyrus (superficial leads); O, orbitofrontal cortex; P, frontopolar cortex; Q, anterior mesial frontal cortex (deepest leads) and anterior portion of the second frontal gyrus (superficial leads); R, pre-SMA (deepest leads) and middle portion of the first frontal gyrus (superficial leads); S, SMA (deepest leads) and posterior portion of the first frontal gyrus (superficial leads); V, precuneus (deepest leads) and angular gyrus (superficial leads); x, orbitofrontal cortex (deepest leads of patient 1) and anterior mesial frontal cortex; y, anterior mesial frontal cortex; z, pre-SMA. Electrodes H', M', N', O', Q', R', and S' correspond to the same anatomic location as electrodes H, M, N, O, Q, R, and S, but are contralateral to the epileptogenic zone.

enough to justify a presurgical evaluation. All three patients were initially evaluated with video scalp-EEG monitoring that captured their typical seizures. Neuroimaging data included an optimal brain MRI in all cases, an [<sup>18</sup>F]fluorodeoxyglucose–positron emission tomography (FDG-PET) in two patients, and an [<sup>11</sup>C]flumazenil-PET, as well as an ictal single-photon emission computed tomography (SPECT) in one patient each. An intracarotid amobarbital procedure (IAP) was performed in one patient. MRI, PET, and SPECT data were evaluated by visual analysis.

An intracerebral EEG investigation was performed before considering a surgical treatment, partly because MRI proved normal in patients 1 and 2, and showed only an arachnoid cyst in the patient 3. Because noninvasive data primarily suggested the diagnosis of NFLE,

the orbitofrontal and mesial frontal regions were considered the most likely ictal-onset zones. To investigate these deeply located brain regions, we used a stereo-electroencephalography procedure (SEEG), as described in more detail elsewhere (11,12). In total, 14 to 15 electrodes, each containing five to 15 leads, were implanted in each patient, most of which sampled the frontal lobes (71–93%), and particularly the mesial and orbital frontal structures (10–12 electrodes) (Fig. 1). In all three patients, clinical, scalp-EEG, or neuroimaging data provided information of various robustness regarding the most likely side of seizure onset, accounting for the ratio of electrodes placed in that hemisphere (64–93%). A few electrodes were placed in various temporal lobe regions (hippocampus, amygdala, mesial aspect of the temporal pole, and second temporal gyrus), because of the possibility of

nocturnal hypermotor seizures (NHSs) of temporal lobe origin (13), and of the presence of left temporal spikes on interictal scalp-EEG in patient 2. Similarly, a right parietal electrode was placed in the same subject because of the presence of associated right posterior interictal spikes on scalp-EEG recordings.

Finally, the deepest leads of one frontal electrode sampled the anterior portion of the insula in every patient (Fig. 1C). We investigated the insula with the aim of obtaining clinically relevant information regarding seizure propagation and the organization of a potentially complex epileptogenic network, given the close anatomic connections between the insula, the orbitofrontal and cingulate cortices, and the temporolimbic structures (14). In patients 1 and 2, the electrode placed within the insula had an oblique anteroposterior trajectory, parallel to the plane of the insular cortex, with six to seven leads located within that cortex, the majority of which sampled the anterior and superior aspects of the insula. In patient 3, the electrode was inserted by using a classic orthogonal approach, targeting the frontal operculum. Only the two deepest leads of that electrode were located in the anterior and superior aspects of the insula.

Because our digital EEG systems are limited to 96 recording channels, whereas >140 leads were implanted in every patient, we selected the 96 most relevant leads based on their location on the coregistered MRI and the EEG signal initially recorded at each site. Specifically, we preferentially chose leads placed within the grey matter with an appropriate signal-to-noise ratio. Because this selection occurred before the identification of the seizure-onset zone, we did not record from all leads of the oblique electrode placed in the insula of patients 1 and 2. Regarding patient 1, we recorded only from the five deepest leads located in the insula and the two most superficial ones located within the lateral portion of the second frontal gyrus (Fig. 1C). In patient 2, we recorded from the seven deepest leads placed in the insula and the two most superficial ones sampling the second frontal gyrus (Fig. 1C).

Intracerebral electrical stimulation was performed according to our standard clinical protocol in order to test the excitability and functionality of the investigated brain regions, by using a high-frequency, 50-Hz train of 1–5 s duration, 0.3 ms pulse duration, and 1 to 3 mA intensity.

The intracranial EEG data of our three patients were independently reviewed by two of the investigators (P.K. and P.R.), who confirmed the clinical conclusion previously provided after completion of the SEEG procedure.

To evaluate the prevalence of insular seizure onset among patients with nonlesional drug-resistant NHSs who previously underwent an intracranial EEG investigation in our centers, we retrospectively searched for all such cases in our database. We looked at whether the conclusion of the SEEG procedure was confirmed by a successful surgi-

cal treatment, and when not confirmed, whether the insula had been explored by the intracerebral electrodes.

## RESULTS

### Clinical data

The main clinical data of our three patients are summarized in Table 1. The epilepsy of all three began during childhood, without any previous medical history. One of the three patients (patient 1) had a typical family history of ADNFLE, with his father, paternal grandfather, and a paternal uncle having had a similar condition. A previous study has failed to reveal the presence of a mutation in the *CHRNA4* and *CHRN2* genes in that family (15). No family history of epilepsy or parasomnia existed in the two other patients. Nocturnal seizures represented the main seizure type in all three patients and consisted of very stereotyped attacks lasting from 18 to 120 s, during which hypermotor gestures and/or dystonic postures predominated (Fig. 2). All three patients had rare daytime seizures, the semiology of which proved identical to or very comparable with that of nocturnal attacks. Altogether, they had a typical form of so-called nocturnal paroxysmal dystonia, consistent with the diagnosis of ADNFLE in one patient, and with that of sporadic cryptogenic NFLE in the other two.

Lateralizing ictal signs and symptoms were scarce in our population and helped to decide on the most likely side of seizure onset in only patient 1. This lateralization was consistent with the presence of left frontal interictal and ictal scalp-EEG abnormalities, left frontostriatal hyperperfusion on ictal SPECT, and ipsilateral thalamic hypometabolism on FDG-PET. In patient 2, independent interictal spikes were observed over the right posterior and left temporal regions, but ictal scalp-EEG recordings strongly suggested a right frontal seizure onset. In patient 3, in whom both ictal signs and scalp-EEG data failed to demonstrate lateralizing features, the presence of a left sided frontobasal arachnoidal cyst on MRI, together with an ipsilateral mesial frontal FDG and FMZ-PET abnormality, led us to consider the left frontal lobe as the most likely origin of the epileptic discharges.

### SEEG findings

SEEG data are summarized in Table 1. Patients 2 and 3 demonstrated interictal abnormalities that predominated over the anterosuperior insula on the side of the suspected epileptogenic zone (Fig. 3). Less-frequent and milder abnormalities were observed in the ipsilateral frontal lobe and in particular over the mesial and orbitofrontal regions, as well as in the frontal operculum. Interictal abnormalities were remarkable in patient 3, who demonstrated continuous spikes of very high amplitude, suggesting an underlying MRI occult cortical dysplasia (Fig. 3).

A fast-activity discharge was observed in the insula at seizure onset in all three patients (Figs. 4 and 5). It clearly

TABLE 1. Clinical data

	Patient 1 Male	Patient 2 Female	Patient 3 Male
Gender			
Age at SEEG evaluation	14 yr	7 yr	51 yr
Handedness	R	R	R
Personal history	—	—	—
Family history	ADNFLE (no <i>CHRN4</i> or <i>CHRN2</i> mutation)	—	—
Age at onset of epilepsy	5 yr	2 yr	9 yr
Duration of epilepsy	9 yr	5 yr	42 yr
Seizure frequency	Up to 20/night	1 to 3/night	1 to 3/night
AEDs tested	CBZ, BZD, PB, LTG, VGB, GBP, VPA, PHT, TPM	CBZ, VPA, VGB, GBP, OXC, LTG	PHT, CBZ, VGB, BZD, LTG, VPA, TPM, LEV
Seizure semiology	Aura: ± rising tingling over the back and ictal fear Apnea, tachycardia, dystonia upper limbs (R > L), grimacing, sialorrhea, pelvic rolling, fear mimicry, screaming, sitting in bed, postictal aphasia	Aura: ± ictal fear Agitation, dystonia upper limbs, R head version, grimacing, screaming, fear mimicry, grabs her mother	Aura: ± undefinable aura Agitation, turn around the bed (R = L), grimacing, screaming, tachycardia, rubefaction, pelvic thrust
MRI	Normal	Normal	L. frontobasal arachnoidal cyst
Interictal scalp-EEG	L frontal spikes	R posterior and L temporal spikes	Normal
Ictal scalp-EEG	L frontoprecentral discharge, then bilateral frontal	R frontal discharge	Artifacts only
Ictal SPECT	L frontostriatal hyperperfusion	ND	ND
FDG-PET	L thalamic hypometabolism	ND	L mesial frontal hypometabolism
FMZ-PET	ND	ND	L mesial frontal decreased binding
Wada test	ND	ND	L hemisphere dominant for language
SEEG: primary hypothesis	L mesial or orbitofrontal	R mesial or orbitofrontal	L mesial or orbitofrontal
Total number of electrodes	15	14	14
L frontal lobe electrodes	11	0	8
R frontal lobe electrodes	3	10	5
Temporal electrodes	1	3	1
Parietal electrodes	0	1	0
Insular electrode <sup>a</sup>	1 L	1 R	1 L
Interictal abnormalities	Bursts of high-frequency discharges	Bursts of high-frequency discharges	Bursts of high-frequency discharges
Ictal-onset zone	L anterosuperior insula, frontal operculum, SMA L anterosuperior insula and frontal operculum	High-amplitude spikes R anterosuperior insula R anterosuperior insula	Permanent high-amplitude spikes L anterosuperior insula L anterosuperior insula

SEEG, Stereoelectroencephalography; R; Right; L: Left; ADNFLE, autosomal dominant nocturnal frontal lobe epilepsy; AEDs, antiepileptic drugs; CBZ, carbamazepine;

BZD, benzodiazepine; PB, phenobarbital; LTG, lamotrigine; VGB, vigabatrin; GBP, gabapatin; VPA, valproate; PHT, phenytoin; TPM, topiramate; OXC, oxcarbazepine; LEV, levetiracetam;

ND, Not done; MRI, magnetic resonance imaging; SPECT, single-photon emission computed tomography; PET, positron emission tomography; SMA, Supplementary motor area; FDG, [<sup>18</sup>F]fluorodeoxyglucose; FMZ, [<sup>11</sup>C]flumazenil.

<sup>a</sup>The electrode targeting the insula also sampled part of the frontal lobe and is thus also counted in the number of frontal lobe electrodes.



FIG. 2. Video samples of the hypermotor seizure of patients 1 (top row), 2 (middle row), and 3 (bottom row).

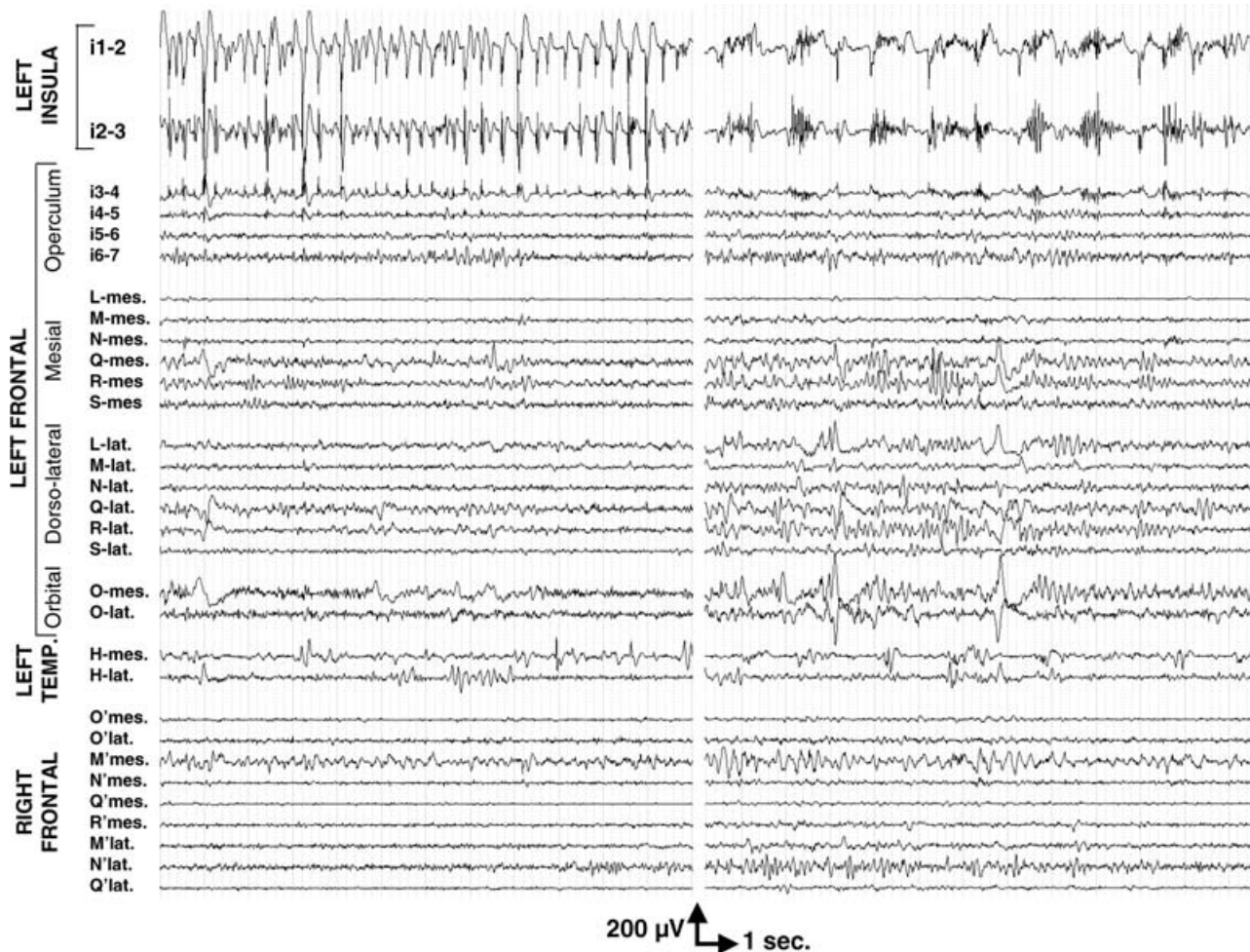
preceded the development of an ictal discharge in other brain regions by several seconds in patients 2 and 3, a period during which they were either asymptomatic or appeared as if perceiving an aura. In patient 1, the build-up of the epileptic discharge was more progressive, hampering a precise delineation of ictal onset. As a consequence, we could not firmly conclude that the discharge observed in the insula offset that seen in the nearby frontal operculum, in some seizures. We thus considered that this patient had an insulo-opercular ictal-onset zone, conservatively, even though the insula appeared more intensely involved at seizure onset. Furthermore, in all three patients, the entire epileptic discharge consistently appeared more sustained and of higher frequency or greater amplitude in the insula than in all other sampled brain regions. In the two patients with five to seven recording leads placed in the insula, a clear gradient was observed between those located in its anterosuperior portion, where the ictal activity predominated, and the more inferior and posterior leads. Similarly, in patient 3 with an orthogonal electrode crossing the frontal operculum down to the an-

terosuperior portion of the insula, a very steep gradient was found between the two structures, separated only by a few millimeters.

Hypermotor activities were observed concurrent with the spread of the epileptic discharge over the mesial frontal structures and, in particular, the supplementary motor area and the cingulate gyrus. This frontal spread was predominantly ipsilateral to seizure onset in the two patients with electrodes placed in the contralateral frontal lobe.

High-frequency electrical stimulation of the anterosuperior insula, but of no other sampled brain regions, elicited a typical aura of rising tingling back sensation in patient 1, and a typical full-blown seizure in patient 3.

Surgery has now been declined by the adult patient and the parents of the two affected children. This decision was partly based on the following information: Epilepsy surgery in the anterior portion of the insula carries potential vascular and functional risks, in particular language deficit, if performed on the side dominant for language, as for patients 1 and 3; To our knowledge, neither these risks nor the chance of postoperative seizure freedom has



**FIG. 3.** Interictal intracerebral EEG abnormalities. Patient 3 showed almost permanent high-amplitude spikes (left EEG traces), intermingled with bursts of high-frequency discharges (right EEG traces) in the anterosuperior portion of left insula (i1, i2), slightly diffusing to the nearby deepest aspect of the frontal operculum (i3–4). Note that all leads are displayed with a similar amplification.

yet been evaluated in patients with cryptogenic epilepsy arising from the anterior insula.

We retrieved from our database seven other patients with MRI-negative drug-resistant NHSs who underwent invasive EEG monitoring in our institutions. Seizure onset was observed in the mesial frontal region in four patients and in the anterior part of the frontal lobe in the remaining three. All patients were subsequently operated on, resulting in complete seizure control in four (three mesial and one anterior frontal resection) and a lack of improvement in the other three, whose insula was not investigated during the intracerebral EEG recordings. Interestingly, pathology revealed cortical dysplasia ( $n = 3$ ) or a large number of heterotopic neurons ( $n = 1$ ) in the seizure-free patient specimens, whereas it proved unremarkable for the other three patients.

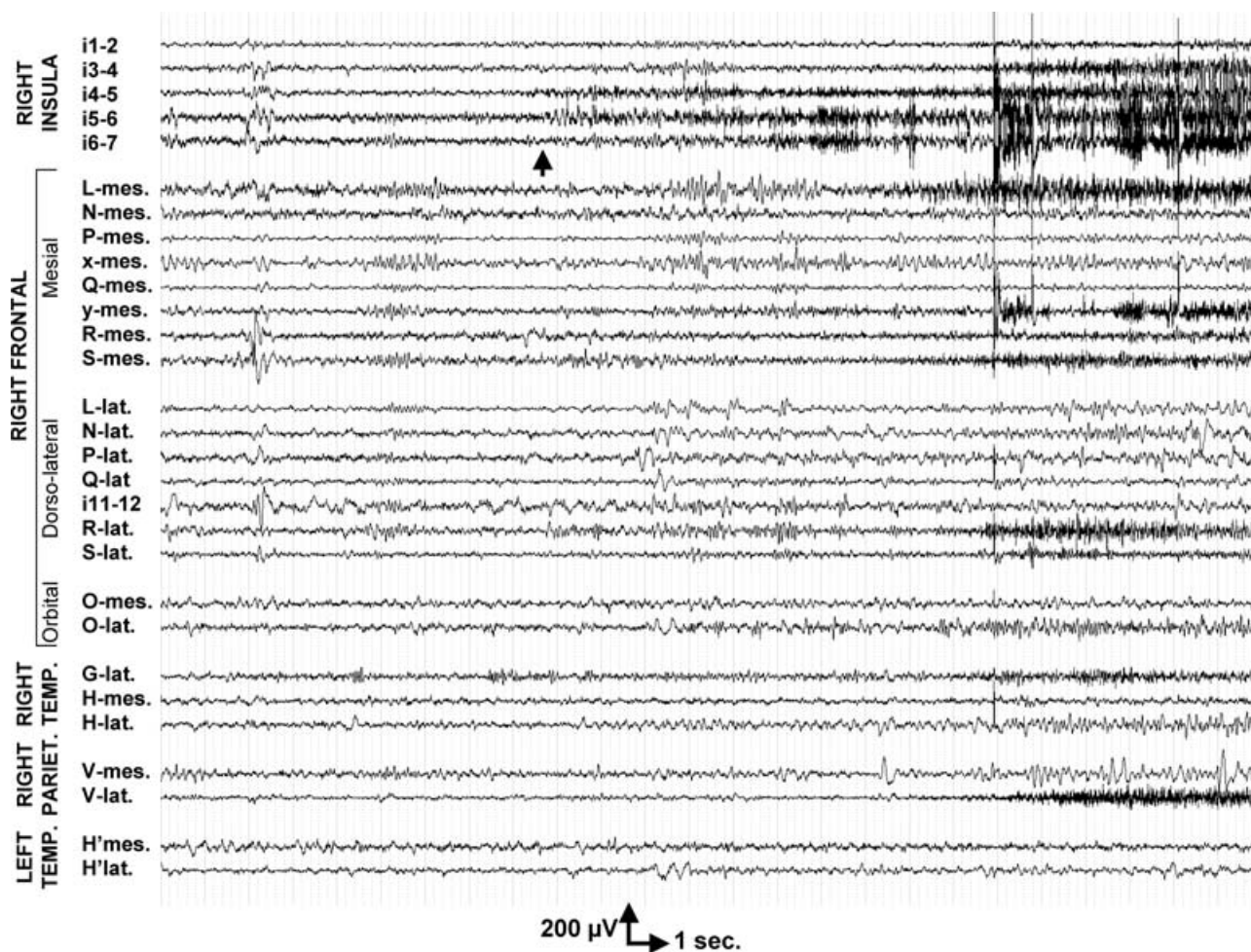
## DISCUSSION

We have reported three patients with drug-resistant NHSs suggesting cryptogenic NFLE in two, and ADNFLE

in another, where intracerebral EEG recordings demonstrated the critical role of the insula in seizure generation. This original finding expands the spectrum of epileptogenic networks that might give rise to NHSs and will be important to consider in patients in whom such seizures are severe enough to justify a presurgical evaluation.

### The issue of intracerebral EEG sampling

The limited sampling of intracerebral EEG investigations must be taken into account in the interpretation of our data. However, the possibility that seizures of which onset appeared located in the insula might have originated in unexplored frontal brain regions seems unlikely in our patients, according to the overall set of available data: (a) the ipsilateral frontal lobe, and in particular the mesial frontal and orbitofrontal structures were investigated with seven to nine electrodes, representing a total of 80 to 91 leads, thus providing a substantial three-dimensional coverage of that lobe; (b) in two patients, frontal lobes were invaded by the ictal discharge after a delay of several seconds after the insular seizure onset; (c) high-frequency



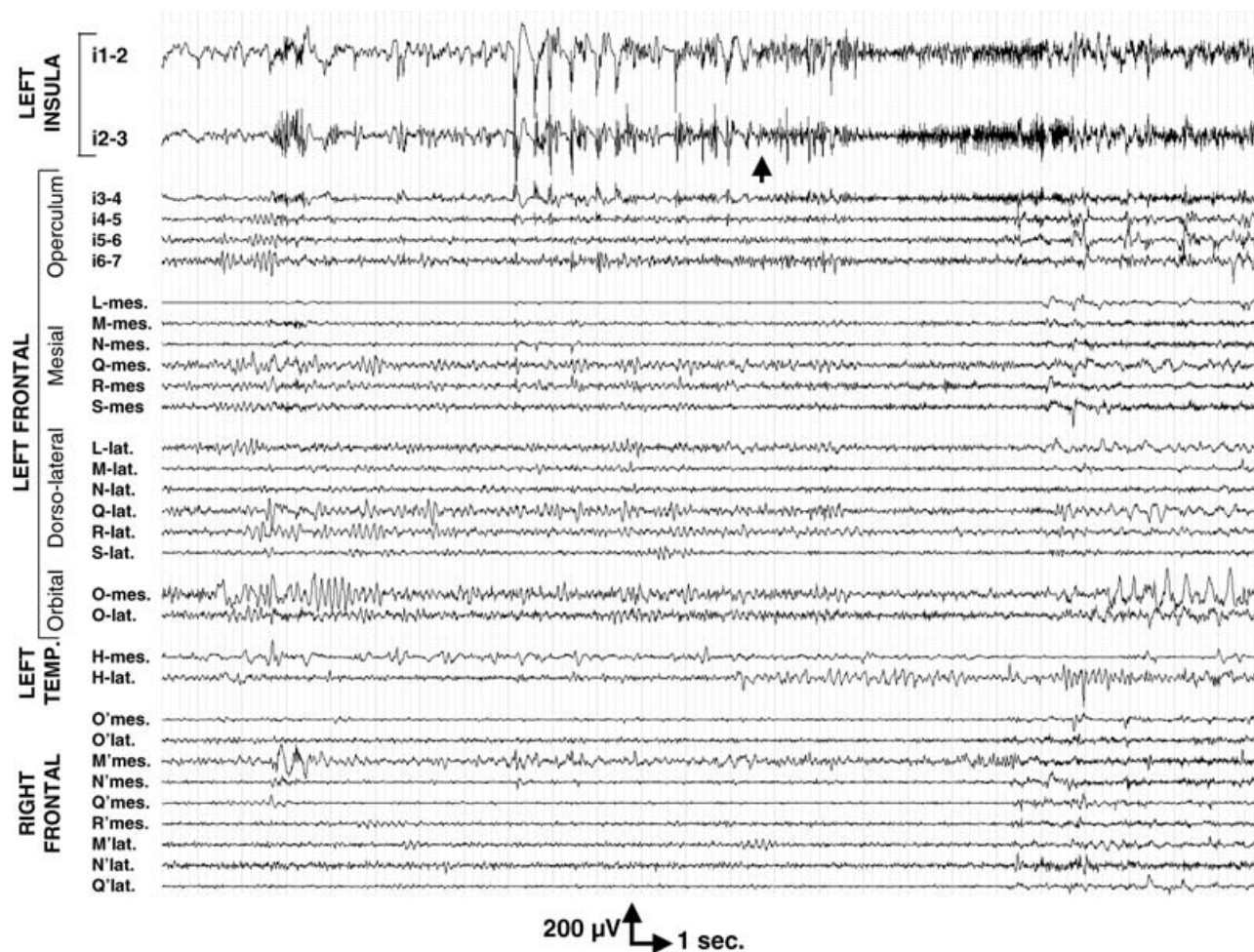
**FIG. 4.** Intracerebral EEG recordings of a seizure onset in patient 2. Note that all leads are displayed with a similar amplification. A focal high-frequency discharge is clearly observed at seizure onset in the anterosuperior portion of the right insula (i4–5, i5–6) (arrow). It spread in a few seconds to the most anterior insular lead (i6–7), and then to several brain regions of the right hemisphere, including the anterior cingulate gyrus (L-mes), the pre-SMA (y-mes, R-mes), the SMA (S-mes), the middle and posterior aspects of the second frontal gyrus (R-lat, S-lat), the temporal pole (G-lat), and the angular gyrus (V-lat).

stimulation of the frontal leads was ineffective in all patients, whereas stimulation of the anterosuperior portion of the insula elicited a typical aura or a full-blown seizure in two patients; and (d) interictal epileptiform abnormalities predominated in the insula in another two patients, including one in which it displayed a pattern of very focal permanent high-amplitude spikes suggesting an underlying MRI occult cortical dysplasia.

An ipsilateral temporal lobe ictal onset also seems unlikely, despite the limited number of electrodes placed in that lobe, according to the lack of or minimal involvement of the mesial and lateral temporal regions during the ictal discharge. In addition, the insular leads that predominantly participated in the interictal and ictal discharges were located in the anterior and superior portions of the insula, in the vicinity of the frontal operculum, whereas the insular propagation of temporal lobe seizures usually affects the inferior and posterior aspects of the insula (16). We cannot firmly exclude the possibility of a parietal or

an occipital seizure onset, because only one patient benefited from the placement of a single parietal electrode motivated by the presence of posterior interictal spikes on scalp-EEG. However, in that patient, the lateral leads of the parietal electrode were invaded by the ictal discharge > 10 s after the insular onset. Furthermore, to our knowledge, no published data support the possibility that NHTs might originate in posterior brain regions.

Although we believe that our data provide compelling evidence of the major role played by the insula in generating the NHTs observed in our patients, we cannot ascertain the precise location and extent of their epileptogenic zone. Because of the anticipated risks of surgery in the anterior insula, in particular on the side dominant for language, we could not test whether the removal of the suspected epileptogenic zone would result in seizure freedom. Furthermore, only a portion of the insular cortex was investigated in each patient, even though a clear gradient of ictal and interictal abnormalities indicated a greater involvement



**FIG. 5.** Intracerebral EEG recordings of a seizure onset in patient 3. Note that all leads are displayed with a similar amplification. Ictal onset occurred after a series of high-amplitude spikes followed by bursts of high-frequency discharge observed over the anterosuperior portion of the left insula (i1–2, i2–3) (*arrow*). A diffusion of the high-amplitude insular discharge is observed over the next adjacent lead (i3), distant only 1.5 mm from the insular lead i2. None of the other opercular leads demonstrates an ictal discharge at this stage, suggesting that i3 activity merely reflects the passive diffusion of the insular discharge laterally rather than an autonomously epileptic activity. Two to four seconds later, an ictal discharge progressively built up in several mesial and lateral frontal regions, bilaterally.

of the anterosuperior portion of the insula. Finally, one of our patients had an insulo-opercular ictal-onset zone rather than a purely insular focus, based on available intracerebral EEG data. A similar issue was recently raised for patients with a temporal lobe–like seizure pattern and an initial or very rapid involvement of the insula (17,18). Some of these patients appear to have a temporoinsular epileptogenic zone, rather than an insular epilepsy proper (18).

Our patients' seizures remained asymptomatic or paucisymptomatic as long as the ictal discharge remained localized within the insula and became hypermotor only when the ipsilateral mesial frontal structures were invaded. We thus can qualify the latter as part of the symptomatogenic zone. One might even question whether surgical removal of these mesial frontal structures could alleviate the hypermotor seizures and leave the patient with nondisabling attacks. However, previous attempts to re-

move only a portion of the seizure-onset zone have consistently proved unsuccessful in various clinical settings (19–22).

#### **Clinical similarities and difference between our patients and the previously reported population of NFLE patients**

Apart from their intracerebral EEG findings, our patients did not demonstrate clinical data that would clearly distinguish their phenotype from typical NFLE or ADNFLE. Their NHSs were characterized primarily by pelvic and bimanual bipedal repetitive movements, including pelvic thrust and kicking, together with screaming in most instances. However, they did not walk out of bed nor did they curse, as frequently observed in episodic nocturnal wanderings (ENWs) (1,23). Their seizure semiology corresponds to that described in nocturnal paroxysmal dystonia (1) and in the so-called “prolonged seizure type”



observed in ADNFLE patients (2). Our patients had rare daytime seizures. The latter also proved to occur in 57% of patients with nocturnal paroxysmal dystonia (1) and are likely to be more frequent in drug-resistant patients. Scalp-EEG either showed frontal ictal discharges or failed to detect any epileptic activity in our population. Likewise, Provini et al. (1) found that only 56% of NFLE seizures were associated with detectable scalp-EEG abnormalities, including diffuse flattening in 14%, and focal frontal or frontotemporal discharges in 27%. In the same series, 14 of 100 NFLE patients demonstrated a brain abnormality on MRI, including three frontobasal arachnoidal cysts, reminiscent of that observed in one of our patients. Although such a lesion is not considered epileptogenic, its location on the side of and at close proximity to the seizure-onset zone in the most anterior aspect of the insula supports the view that a common pathologic mechanism might be responsible for both the arachnoidal cyst and the epilepsy. Overall, the main difference between our patients and the general population of NFLE is the severity of the epilepsy, which obviously reflects the fact that our patients were selected through an epilepsy surgery program. It should be noted, however, that about 30% of NFLE and ADNFLE patients are not responsive to carbamazepine (1,2).

#### **Data supporting the frontal origin of nocturnal hypermotor seizures**

Despite a 30% rate of pharmacoresistance, very few patients with NFLE, and to our knowledge none with ADNFLE, underwent invasive EEG recordings or epilepsy surgery, most likely because the nocturnal attacks were not considered disabling enough. The frontal origin of NHSs is suggested mainly by their resemblance with the daytime attacks observed in well-assessed cases of orbitofrontal or mesial frontal epilepsy (24–30). No clinical difference appears between nocturnal and daytime hypermotor seizures (31). In addition, scalp-EEG demonstrates frontal epileptiform abnormalities in 36% of NFLE, and 50% of ADNFLE patients (3). The scarce intracerebral EEG and post-operative data available in NFLE patients also support the role of the mesial frontal and orbitofrontal cortex (8,9). Neuroimaging findings point in the same direction. In a series of 100 NFLE patients, 12 of 14 brain lesions were located in the frontal lobes (1). Furthermore, hypermotor seizures were found to be associated with orbitofrontal or frontopolar hyperperfusion on ictal SPECT (32), and with mesial frontal as well as perirolandic and frontal operculum hypometabolism on interictal FDG-PET (33). Accordingly, in two patients with ADNFLE, ictal SPECT demonstrated either mesial frontal or orbitofrontal and frontopolar hyperperfusion (34). One of these patients also showed anteroinferior frontal hypometabolism on FDG-PET images. More recently, anterior cingulate hyperperfusion was demonstrated by ictal SPECT in a patient with sporadic NFLE (35). However, as illustrated in two of

our patients, the presence of either scalp-EEG, MRI, ictal SPECT, or FDG-PET frontal abnormalities does not necessarily indicate the frontal origin of NHSs.

#### **Nocturnal hypermotor seizures of extrafrontal origin**

Previous reports demonstrated that nocturnal hypermotor seizures can originate in the temporal lobe, in particular when symptomatic of a temporobasal cortical dysplasia (10,36). The possibility that cryptogenic temporal lobe epilepsy might give rise to NHS is further supported by the observation of bimanual–bipedal automatisms and nocturnal clustering of seizures in such form of epilepsy (13,37), and by the fact that NFLE patients demonstrate interictal scalp-EEG abnormalities localized over the temporal lobe or detectable only on sphenoidal electrodes in 29%, and an ictal EEG onset of similar topography in 14% (1).

To our knowledge, our patients represent the first reported cases of NHS associated with an insular seizure onset. However, functional neuroimaging abnormalities were previously observed in the insula of a few patients with hypermotor seizures or NFLE. FDG-PET showed both frontal and insular interictal hypometabolism in patients with NHS (33), whereas ictal SPECT revealed insular hyperperfusion in one such patient (32). Similarly, the ictal hyperperfusion observed in one ADNFLE patient appears to involve the insular cortex, according to the published figures (34).

The three patients reported in this study account for a significant proportion of the 10 patients with drug-resistant NHSs and no clear-cut epileptogenic MRI lesion who underwent invasive EEG monitoring in our institutions. One might speculate about the role of the insula in the three patients from the same series who failed to respond to frontal lobe surgery, and in whom intracerebral EEG investigation did not explore the insular cortex. In any event, figures obtained in that highly selected group of patients should not be extrapolated to the general population of NFLE. For instance, NHSs of insular origin might be more likely to become drug resistant than those that involve only the frontal lobe.

#### **The diversity of seizures arising from the insula in relation to functional anatomy**

The involvement of the insula in epilepsy has been classically discussed in the context of temporal lobe epilepsy (38). Recently, six patients were reported with various features suggesting TLE, but whose seizures originate or very rapidly spread within the insula (17). Half of these patients also had seizures arising from the temporal lobe, including two who showed MRI signs of mesial temporal sclerosis. Insular seizures were typically associated with a sensation of laryngeal constriction followed by paresthesias that were often unpleasant, affecting large cutaneous territories, with preserved consciousness. These initial symptoms were eventually followed by dysarthric speech and/or

elementary auditory hallucinations or motor signs. Most of the seizures originated in the posterior half of the insula, except for those in one patient, in whom they arose from the anteroinferior quadrant. In contrast, the anterosuperior aspect of the insula, which also was explored in the majority of these patients, was spared at ictal onset. The discharge then preferentially propagated to the mesial temporal structures, even though various frontal lobe regions, including the operculum, could also be invaded. Our three patients dramatically differ from those described in the earlier series. None had electroclinical or neuroimaging data suggesting TLE, but rather NFLE or ADNFLE. None reported laryngeal constriction or paresthesias at seizure onset, even though they seemed to retain some degree of consciousness during the few seconds during which the ictal discharge remained localized within the insula. Finally, the ictal discharge appeared to arise from the anterosuperior aspect of the insula and spread preferentially to the frontal lobe, with only late and mild involvement of the ipsilateral temporal lobe. Thus the striking differences observed among patients with insular seizures might reflect the precise area of the insula involved at ictal onset (i.e., posterior or anteroinferior in TLE-like epilepsy, and anterosuperior in those mimicking NFLE). Although this framework is consistent with the anatomic connections of the various insular subregions described in rhesus monkeys (39,40), it remains hampered by the limited portion of the insular cortex that was investigated in this study.

### Pathophysiologic issues in ADNFLE

A recent review on ADNFLE stressed that seizures associated with this condition arose from the frontal lobes for unknown reasons (3). The observation that the insula can participate to ictogenesis does not clarify this issue, but certainly provides a different perspective regarding the expected brain expression of the mutant genes. The involvement of the insular cortex in NFLE and ADNFLE also questions the role of the insula in sleep physiology. Interestingly, two PET studies of the regional cerebral blood flow demonstrated a marked deactivation of the anterior insula during sleep (41,42).

### CONCLUSION

A significant proportion of surgical candidates with drug-resistant NHTS suggestive of NFLE might have an epileptogenic zone that involves primarily the insula. Whether these patients are amenable to successful surgery remains an open issue, as does the pathogenesis underlying this form of sporadic or familial epilepsy.

**Acknowledgment:** We are grateful to Franck Gilliam for his help and comments on this manuscript.

### REFERENCES

1. Provini F, Plazzi G, Tinuper P, et al. Nocturnal frontal lobe epilepsy: a clinical and polygraphic overview of 100 consecutive cases. *Brain* 1999;122:1017–1031.
2. Oldani A, Zucconi M, Asselta R, et al. Autosomal dominant nocturnal frontal lobe epilepsy: a video-polysomnographic and genetic appraisal of 40 patients and delineation of the epileptic syndrome. *Brain* 1998;121:205–223.
3. Combi R, Dalpra L, Tenchini ML, et al. Autosomal dominant nocturnal frontal lobe epilepsy: a critical overview. *J Neurol* 2004;251:923–934.
4. Phillips HA, Scheffer IE, Berkovic SF, et al. Localization of a gene for autosomal dominant nocturnal frontal lobe epilepsy to chromosome 20q 13.2. *Nat Genet* 1995;10:117–118.
5. Steinlein OK, Mulley JC, Propping P, et al. A missense mutation in the neuronal nicotinic acetylcholine receptor alpha 4 subunit is associated with autosomal dominant nocturnal frontal lobe epilepsy. *Nat Genet* 1995;11:201–203.
6. Phillips HA, Scheffer IE, Crossland KM, et al. Autosomal dominant nocturnal frontal-lobe epilepsy: genetic heterogeneity and evidence for a second locus at 15q24. *Am J Hum Genet* 1998;63:1108–1016.
7. De Fusco M, Becchetti A, Patrignani A, et al. The nicotinic receptor beta 2 subunit is mutant in nocturnal frontal lobe epilepsy. *Nat Genet* 2000;26:275–276.
8. Nobili L, Francione S, Mai R, et al. Nocturnal frontal lobe epilepsy: intracerebral recordings of paroxysmal motor attacks with increasing complexity. *Sleep* 2003;26:883–886.
9. Cascino GD, Buchhalter JR, Mullan BP, et al. SPECT in nonlesional extratemporal epilepsy. *Epilepsia* 2004;45(suppl 4):32–34.
10. Nobili L, Cossu M, Mai R, et al. Sleep-related hyperkinetic seizures of temporal lobe origin. *Neurology* 2004;62:482–485.
11. Cateñoix H, Magnin M, Guenet M, et al. Hippocampal-orbitofrontal connectivity in human: an electrical stimulation study. *Clin Neurophysiol* 2005 (in press).
12. Chabardes S, Kahane P, Minotti L, et al. The temporopolar cortex plays a pivotal role in temporal lobe seizures. *Brain* 2005;128:1818–1831.
13. Swartz BE. Electrophysiology of bimanual-bipedal automatisms. *Epilepsia* 1994;35:264–274.
14. Mesulam MM, Mufson EJ. Insula of the old world monkey, I: architectonics in the insulo-orbito-temporal component of the paralimbic brain. *J Comp Neurol* 1982;212:1–22.
15. Picard F, Baulac S, Kahane P, et al. Dominant partial epilepsies: a clinical, electrophysiological and genetic study of 19 European families. *Brain* 2000;123:1247–1262.
16. Isnard J, Guenet M, Ostrowsky K, et al. The role of the insular cortex in temporal lobe epilepsy. *Ann Neurol* 2000;48:614–623.
17. Isnard J, Guenet M, Sindou M, et al. Clinical manifestations of insular lobe seizures: a stereo-electroencephalographic study. *Epilepsia* 2004;45:1079–1090.
18. Ryvlin P, Kahane P. The hidden causes of surgery-resistant temporal lobe epilepsy: extratemporal or temporal plus? *Curr Opin Neurol* 2005;18:125–127.
19. Wieser HC, Siegel AM, Yasargil MG. The Zurich amygdalohippocampectomy series: a short update. *Acta Neurochir* 1990;50:122–127.
20. Fish D, Andermann F, Olivier A. Complex partial seizures and small posterior temporal or extratemporal structural lesions: surgical management. *Neurology* 1991;41:1781–1784.
21. Li LM, Dubeau F, Andermann F, et al. Periventricular nodular heterotopia and intractable temporal lobe epilepsy: poor outcome after temporal lobe resection. *Ann Neurol* 1997;41:662–668.
22. Li LM, Cendes F, Andermann F, et al. Surgical outcome in patients with epilepsy and dual pathology. *Brain* 1999;122:799–805.
23. Pedley TA, Guilleminault C. Episodic nocturnal wanderings responsive to anticonvulsant drug therapy. *Ann Neurol* 1977;2:30–35.
24. Tharp BR. Orbital frontal seizures: a unique electroencephalographic and clinical syndrome. *Epilepsia* 1972;13:627–642.
25. Ludwig B, Marsan CA, Van Buren J. Cerebral seizures of probable orbitofrontal origin. *Epilepsia* 1975;16:141–158.
26. Geier S, Bancaud J, Talairach J, et al. Automatisms during frontal lobe epileptic seizures. *Brain* 1976;99:447–458.

27. Geier S, Bancaud J, Talairach J, et al. The seizures of frontal lobe epilepsy: a study of clinical manifestations. *Neurology* 1977;27:951-958.
28. Williamson PD, Spencer DD, Spencer SS, et al. Complex partial seizures of frontal lobe origin. *Ann Neurol* 1985;18:497-504.
29. Munari C, Bancaud J. Electroclinical symptomatology of partial seizures of orbital frontal origin. *Adv Neurol* 1992;57:257-265.
30. Rougier A, Loiseau P. Orbital frontal epilepsy: a case report. *J Neurol Neurosurg Psychiatry* 1988;51:146-147.
31. Meierkord H, Fish DR, Smith SJ, et al. Is nocturnal paroxysmal dystonia a form of frontal lobe epilepsy? *Mov Disord* 1992;7:38-42.
32. Harvey AS, Hopkins IJ, Bowe JM, et al. Frontal lobe epilepsy: clinical seizure characteristics and localization with ictal 99mTc-HMPAO SPECT. *Neurology* 1993;43:1966-1980.
33. Schlaug G, Antke C, Holthausen H, et al. Ictal motor signs and interictal regional cerebral hypometabolism. *Neurology* 1997;49:341-350.
34. Hayman M, Scheffer IE, Chinvarun Y, et al. Autosomal dominant nocturnal frontal lobe epilepsy: demonstration of focal frontal onset and intrafamilial variation. *Neurology* 1997;49:969-975.
35. Vetrugno R, Mascalchi M, Vella A, et al. Paroxysmal arousal in epilepsy associated with cingulate hyperperfusion. *Neurology* 2005;64:356-358.
36. Nobili L, Francione S, Cardinale F, et al. Epileptic nocturnal wanderings with a temporal lobe origin: a stereo-electroencephalographic study. *Sleep* 2002;25:669-671.
37. Bernasconi A, Andermann F, Cendes F, et al. Nocturnal temporal lobe epilepsy. *Neurology* 1998;50:1772-1777.
38. Silfvenius H, Gloor P, Rasmussen T. Evaluation of insular ablation in surgical treatment of temporal lobe epilepsy. *Epilepsia* 1964;5:301-320.
39. Mesulam MM, Mufson EJ. Insula of the old world monkey, III: efferent cortical output and comments on function. *J Comp Neurol* 1982;212:38-52.
40. Mufson EJ, Mesulam MM. Insula of the old world monkey, II: afferent cortical input and comments on the claustrum. *J Comp Neurol* 1982;212:23-37.
41. Braun AR, Balkin TJ, Wesenten NJ, et al. Regional cerebral blood flow throughout the sleep wake cycle. An H2(15)O PET study. *Brain* 1997;120:1173-1197.
42. Dang-Vu TT, Desseilles M, Laureys S, et al. Cerebral correlates of delta waves during non-REM sleep revisited. *Neuroimage* 2005;15:14-21.