

Capsular ataxic tetraparesis

U. Utku*, H.Z. Kars**, and Ö. Mengü*

Introduction

Ataxic hemiparesis was first described by Fisher and Cole¹ in 1965. These authors believed that a contralateral lesion in the posterior part of the internal capsule was responsible for this clinical syndrome though multiple cerebral lacunar infarcts were demonstrated at postmortem examination. Pontine lacunar infarcts were also observed at autopsies of three patients with ataxic hemiparesis². In recent years, this syndrome was described in conjunction with contralateral internal capsule infarcts^{3,4,5}, pontine hemorrhage⁶, and a mesencephalic tumor⁷.

A case with cerebellar ataxia and tetraparesis "ataxic tetraparesis" was reported by Van Gijn and Vermeulen⁸ in 1983. In this patient computerized tomography (CT) revealed a lacunar infarct involving the basis pontis.

We report another patient with ataxic tetraparesis. Bilateral infarcts at the junctions of the posterior limb of the internal capsule and the corona radiata were detected at CT.

Report of a case

A 42-year-old man with hypertension and diabetes was admitted for left hemiparesis of sudden onset two days before. A year before admission he had had an attack of right hemiparesis

Summary

A 42-year-old man with ataxic tetraparesis is reported. Computerized tomography showed bilateral and symmetrical lacunar infarcts at the junctions of the posterior limb of the internal capsule and the corona radiata. Previously this clinical syndrome had been reported only with a lesion in the pons.

Key words: ataxia, paresis, quadriplegia.

and dysarthria. Physical examination showed moderate arterial hypertension (160/100 mm Hg). The patient was alert and mentally normal. Speech was dysarthric. Fundoscopy showed retinal exudates and hemorrhages. A left facial palsy of the upper motor neuron type was evident. All four extremities were minimally paretic, though more marked in the legs. The tendon jerks were hyperactive at both sides. He had bilateral Babinski signs and ankle clonus. Left hemihypesthesia, bilateral dysmetria and dysdiadochokinesia were observed. The patient was unable to stand or walk alone. CT scans showed bilateral and symmetrical lacunar infarcts at the junctions of the posterior limb of the internal capsule and the corona radiata (Fig. 1).

* Department of Neurology, Trakya University Medical School, Edirne, and ** Department of Neurosurgery, Cumhuriyet University Medical School, Sivas, Turkey

Address for correspondence and reprint requests: H. Zafer Kars, CÜTF Hastanesi, Nöroşirürji ABD, 58040 Sivas, Turkey

Accepted 27.5.91

Clin Neurol Neurosurg 1991. Vol. 93-4

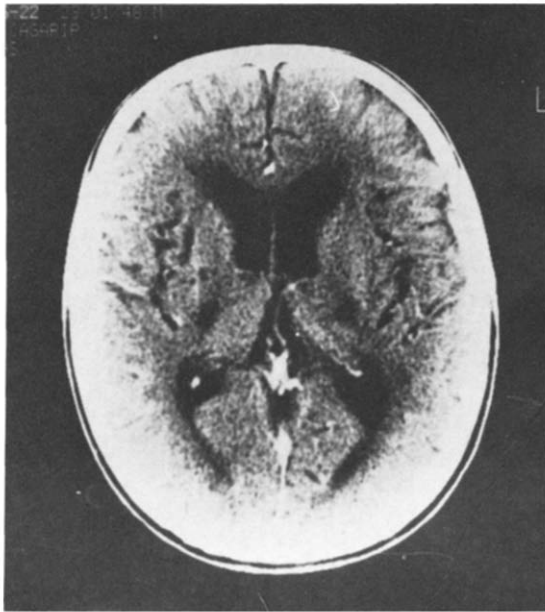


Figure 1. CT scan of the patient shows infarcts located at both internal capsule posterior limbs and corona radiata.

Discussion

Homolateral ataxia with crural paresis was first described by Fisher and Cole¹ in 1965. In this syndrome weakness is minimal, more prominent in the lower limbs, and the degree of weakness does not explain the severity of ataxia. Although Fisher and Cole demonstrated a lesion in the posterior internal capsule-corona radiata region at postmortem examination they added that lesions found in other parts of the brain could also cause this syndrome. In 1978, Fisher demonstrated contralateral upper basis pontis infarcts at autopsies of three patients with this syndrome². He pointed that this pathologic study has furnished a definite solution to an old neurologic problem—the site of the lesion for this syndrome and coined the term ‘ataxic hemiparesis’. In 1980, Perman and Racy observed fresh infarcts in the posterior limb of internal capsule and thalamus with ipsilateral ataxia and crural hemiparesis³. They concluded that the lesion in posterior internal capsule-corona radiata may suffice to cause this syndrome. In recent years, it is stressed that ataxic hemiparesis may exist more frequently with capsular lesions than with pontine lesions^{3,4}. In these reports, posterior limb of internal capsule which involves corticospinal and frontopontine fibers was held responsible for this syndrome. The temporo-

pontine, parietopontine, and occipitopontine fibers which together form the Turck bundle course in the retrolenticular and sublenticular portions of the internal capsule. The frontopontine tract named the “Arnold bundle” arises from the prefrontal cortex and the precentral gyrus. Prefrontal fibers occupy the anterior limb of the internal capsule, but frontopontine fibers from the precentral cortex descend in the posterior limb of the internal capsule adjacent to the corticospinal tract^{4,9}.

Ataxic tetraparesis was first described by Van Gijn and Vermeulen⁸. These authors suggested that occlusion of a perforating branch of the basilar artery with subsequent bilateral pontine ischemia was the cause of this syndrome. It is obvious that this explanation does not hold true in our case. The hypodense lesion at the junction of the posterior limb of the left internal capsule and the corona radiata which was demonstrated by CT may be responsible for the ataxic hemiparesis on the right which had occurred one year before. The left ataxic hemiparesis that had developed two days before admission was obviously caused by a new right capsular lesion. Therefore we suggest that recurrent capsular infarctions may cause ataxic tetraparesis. Symmetrical appearance of posteriorly situated internal capsule infarcts, and absence of any pontine lesion on CT scanning support this suggestion. It seems that ataxic tetraparesis, like ataxic hemiparesis, may be a consequence of different central nervous system lesions.

References

- 1 FISHER CM, COLE M. Homolateral ataxia and crural paresis. A vascular syndrome. *J Neurol Neurosurg Psychiatry* 1965; 28:48-55.
- 2 FISHER CM. Ataxic hemiparesis. *Arch Neurol* 1978; 35:126-128.
- 3 ICHIKAWA K, TSUTSUMISHITA A, FUJIOKA A. Capsular ataxic hemiparesis. *Arch Neurol* 1982; 39:585-86.
- 4 IRAGUI VJ, MCCUTCHEN CB. Capsular ataxic hemiparesis. *Arch Neurol* 1982; 39:528-29.
- 5 PERMAN GP, RACY A. Homolateral ataxic and crural paresis. Case report. *Neurology* 1980; 30:1013-15.
- 6 SCHNAPPER RA. Pontine hemorrhage presenting as ataxic hemiparesis. *Stroke* 1982; 13:518-19.
- 7 BERDHEIM PE, BERG BO. Ataxic hemiparesis from a mid-brain mass. *Ann Neurol* 1981; 9:405-7.
- 8 VAN GIJN J, VERMEULEN M. Ataxic tetraparesis from lacunar infarction in the pons. *J Neurol Neurosurg Psychiatry* 1983; 46:669-70.
- 9 ROSS ED. Localization of the pyramidal tract in the internal capsule by whole brain dissection. *Neurology* 1980; 30:59-64.