

Late in-stent thrombosis following carotid angioplasty and stenting

Abstract— Acute in-stent thrombosis is a well-known complication of carotid angioplasty and stenting (CAS) and often due to resistance to or inadequate treatment with platelet-inhibiting agents. The authors report three cases of a delayed in-stent thrombosis after more than a week but less than 3 months after CAS. In all cases, the postprocedural antiplatelet regimen was discontinued to enable the treatment of a relevant comorbidity.

NEUROLOGY 2006;66:1594–1596

Jan-Hendrik Buhk, MD; Andreas Wellmer, MD; and Michael Knauth, MD

Carotid angioplasty and stenting (CAS) are an alternative to carotid endarterectomy in patients with internal carotid artery (ICA) stenosis. Antiplatelet therapy before and several weeks after stent placement has become an integral part of the procedure in order to reduce the frequency of early stent thrombosis, a main cause of postprocedural embolic stroke.^{1–3} We report three cases out of 96 CAS procedures in which a nonfatal in-stent thrombosis occurred more than 1 week after the intervention. All patients presented with new neurologic symptoms after combined antiplatelet therapy with 100 mg acetylsalicylic acid (ASA) and 75 mg clopidogrel had been discontinued to allow treatment of a second disease.

Case reports. *Patient 1.* A 78-year-old man presented with occasional vertigo. Clinical examination revealed no focal neurologic deficit. An occlusion of the right ICA, an 80% stenosis of the left ICA (figure 1A), and older hemodynamic infarctions in the right hemisphere were diagnosed. CAS was indicated because of the occlusion of the contralateral ICA and radiographic signs of older hemodynamic infarction. A 30% stenosis remained after the procedure due to calcified plaque (figure 1B). Heparin therapy was replaced by a combined antiplatelet therapy with ASA and clopidogrel. One week after the procedure, macrohematuria due to bladder carcinoma occurred. For transurethral tumor resection, the antiplatelet therapy was replaced by subcutaneous heparin. On postoperative day 7, 3 weeks after CAS, the patient suddenly developed aphasia and right-sided hemiparesis. Doppler sonographic examination revealed a high-grade stenosis of the left ICA due to stent thrombosis (figure 1C). Cranial MRI showed acute ipsilateral infarction (figure 1, D and E). Antiplatelet and heparin therapy was restarted. A slow recanalization of the stent with complete resolution of the thrombus was documented (figure 1F). Minor hemiparesis and slight aphasia remained.

Patient 2. An 81-year-old man was admitted 24 hours after a sudden onset of right-sided hemiparesis, aphasia, and dysarthria. Cranial CT did not reveal signs of cerebral infarction. Doppler sonography and CT angiography (CTA) revealed a high-grade stenosis of the left ICA (figure 2A) and no relevant stenosis of the contralateral vessel. The medical history of the patient included a squamous cell carcinoma of the oral cavity that was in complete remission. Reconstructed images of the CTA confirmed the unsuspected clinical findings of the oral cavity. CAS was chosen as

treatment for the clinically symptomatic ICA stenosis and performed successfully (figure 2B).

Two months later, a recurrence of the carcinoma of the oral cavity was diagnosed and resection of the mucosa and parts of the mandible and a left-sided neck dissection were performed. Combined antiplatelet therapy with ASA and clopidogrel was discontinued 1 week before the operation. One week after the operation, the patient suddenly developed right-sided hemiplegia and expressive aphasia. CTA revealed an embolic occlusion of an ipsilateral M2 segment (figure 2D). CTA source images showed acute basal ganglia infarction (figure 2, E and F). CTA also showed filling defects inside the stent, suggesting in-stent thrombosis. Doppler sonography confirmed in-stent thrombosis (figure 2C). Combined antiplatelet therapy was restarted and combined with IV heparin. Two days later, Doppler sonographic examination revealed a complete recanalization of the stent. Slight right-sided hemiparesis and expressive aphasia remained.

Patient 3. A 75-year-old man was admitted with recurrent transient left-sided hemiparesis. Cranial MRI did not show acute infarction, but CTA and Doppler sonography revealed a high-grade stenosis of the right ICA. Treatment with IV heparin as well as ASA and clopidogrel was started. CAS yielded a good result (figure 3, A and B) but was complicated by a groin hematoma. An operation was not necessary, so the patient was discharged. Two weeks after the procedure, the patient developed a deep vein thrombosis in the right leg, possibly due to the groin hematoma. He was admitted to a different hospital, where the combined antiplatelet therapy was replaced by oral phenprocoumon. Three months after the intervention, the patient was admitted to our hospital with slight paresis in the left arm due to an acute infarction as revealed by cranial MRI (figure 3C). No origin of possible emboli could be detected. Phenprocoumon was discontinued and replaced by clopidogrel. A month later, the patient was admitted again following two episodes of speech arrest and left hand palsy. No acute infarction was found, but contrast-enhanced MRA and Doppler sonography revealed an intraluminal lesion suspicious of a stent-associated thrombosis in the right ICA (figure 3D). A second CAS procedure was performed at the level of the thrombus, which resulted in a good reconstruction of the vessel lumen (figure 3F). Slight residual hemiplegia and dysmetria remained.

Discussion. All three case histories have characteristic features in common: antiplatelet pretreatment was performed and CAS was technically successful. Afterward, a second disease had to be treated in all patients. In the first patient, the antiplatelet therapy was replaced by heparin to enable transurethral resection of a bladder carcinoma. Whether the operation could have been delayed to first enable endothelialization of the stent with an unchanged antiplatelet regimen is open to discussion. However, the perioperative conditions resulted in an almost occlusive stent thrombosis with hemodynamic and embolic effects leading to new neurologic symptoms. The second history is quite similar: Again a carcinoma had to be resected and platelet

From the Departments of Neuroradiology (J.-H.B., M.K.), and Neurology (A.W.), University of Goettingen, Goettingen, Germany.

Disclosure: The authors report no conflicts of interest.

Received October 6, 2005. Accepted in final form February 8, 2006.

Address correspondence and reprint requests to Dr. Jan-Hendrik Buhk, Department of Neuroradiology, University of Goettingen, Robert-Koch-Str. 40, D-37075 Goettingen, Germany; e-mail: jh.buhk@med.uni-goettingen.de

1594 Copyright © 2006 by AAN Enterprises, Inc.

Copyright © by AAN Enterprises, Inc. Unauthorized reproduction of this article is prohibited.

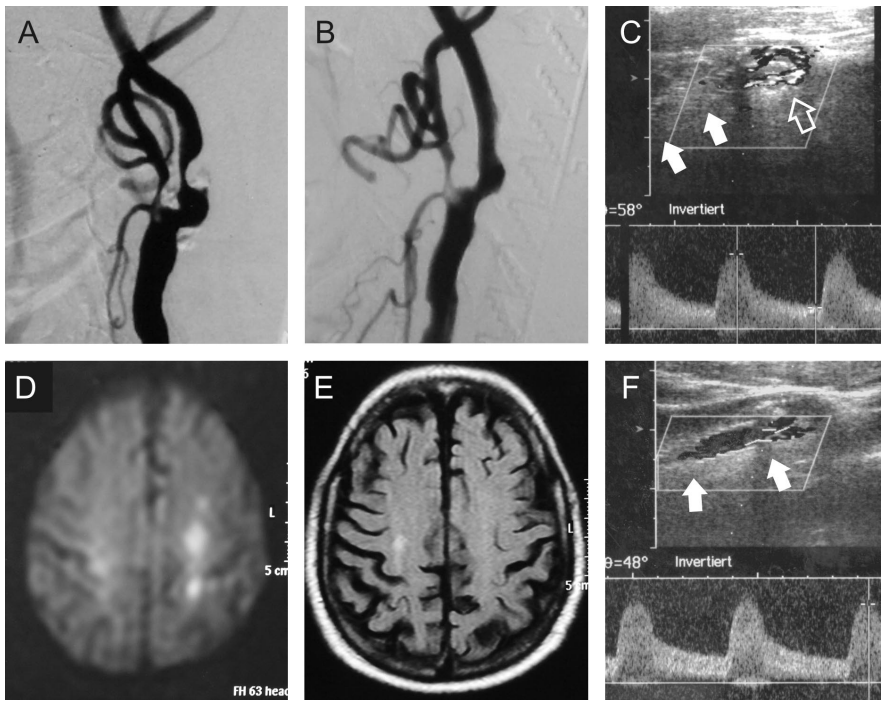


Figure 1. Patient 1: Digital subtraction angiography shows a short high-grade stenosis of the left internal carotid artery (ICA) (A). The contralateral vessel is occluded. After angioplasty and stenting, the morphologic result is good (B). About 2 weeks later, Doppler sonography of the left ICA shows the carotid stent (C, closed arrows) with a thrombus inside surrounded by a ring-shaped flow signal (C, open arrow). Diffusion-weighted cranial MRI shows areas of restricted diffusion in the left hemisphere corresponding to acute hemodynamic infarction (D). The lesions are not yet visible in the fluid-attenuated inversion recovery sequence (E). A few days later, Doppler sonography of the left ICA during combined antiplatelet therapy and IV heparin shows an almost complete recanalization of the ICA (F, arrows).

inhibition was discontinued. Neck dissection was performed on the side ipsilateral to the stent, thus manipulating the ICA bifurcation, which likely had a permissive effect on the development of the stent thrombosis by rerupturing new-grown intima. The diagnosis was difficult to establish in the third patient: Finally, at a second admission, the angiographic appearance and the course of the intervention favor an organized thrombus. All three patients could be treated successfully, at least regarding stent and vessel patency. However, all patients had new

and permanent neurologic symptoms in association with the thrombotic event.

Acute and subacute in-stent thrombosis following CAS is a relevant complication; earlier studies report a frequency of 0.5 to 2%.^{4,5} Most of these incidents likely occurred due to an insufficient platelet-inhibiting regimen, as in some more recently reported cases.^{6,7} Today, well-established protocols exist for anticoagulation and platelet inhibition before and after the intervention, i.e., pretreatment with a combined platelet inhibition (ASA, thienopyri-

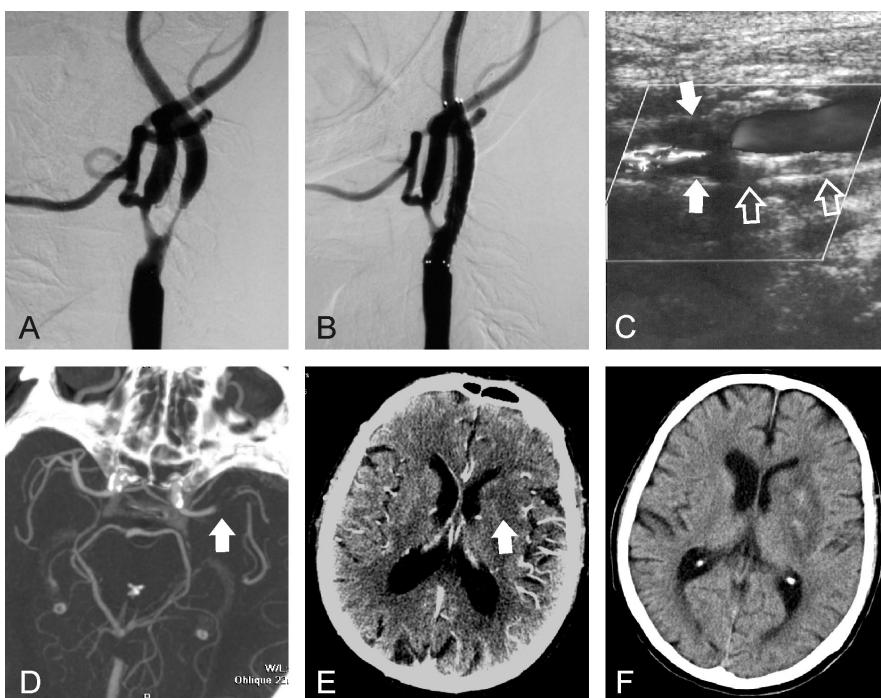


Figure 2. Patient 2: Digital subtraction angiography shows the high-grade stenosis of the left internal carotid artery (ICA) (A). Following CAS, there is a good morphologic result (B). Ten weeks later, color-coded Doppler sonography reveals an in-stent thrombosis (C, closed arrows) causing a subtotal occlusion of the left ICA (C, open arrows). A maximum intensity projection (MIP) image (slice thickness 22 mm) reconstructed from CT angiography (CTA) shows an embolic occlusion of the left middle cerebral artery (D, arrow). A source image of the CTA shows a lack of parenchymal enhancement in the left basal ganglia: acute infarction (E, arrow). Cranial CT a few days later shows a basal ganglia infarction with slight hemorrhagic transformation (F).

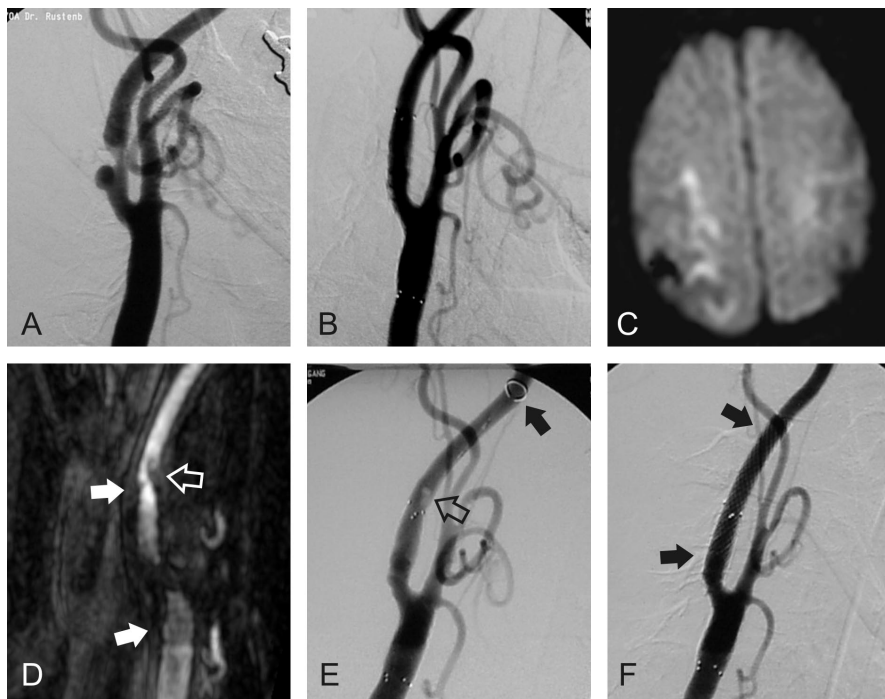


Figure 3. Patient 3: Digital subtraction angiography shows a short high-grade stenosis of the right internal carotid artery (ICA) (A). After angioplasty and stenting, there is a good morphologic result (B). Cranial MRI at a second hospital admission 3 months later shows areas of restricted diffusion in the right centrum semi-ovale corresponding to an acute infarction (C). A thin multiplane reconstructed slice of contrast-enhanced MR angiography during a third admission a month later reveals a lesion, probably an adhering thrombus (D, open arrow) located at the distal end of the stent in the right ICA (D, closed arrows). Digital subtraction angiography confirms this finding (E, open arrow). A distal protection device (FilterWire) is introduced to prevent a possible embolization of parts of the thrombus (E, closed arrow). All attempts to capture or aspirate the thrombus failed.

Finally, a second stent is placed covering the thrombus, yielding an excellent result (F, arrows).

dine), activated clotting time–controlled heparin administration during the procedure and a combined platelet inhibition follow-up for at least several weeks followed by lifelong ASA.¹⁻³ These protocols are similar to those recommended by interventional cardiologists for coronary stenting.

Delayed stent thrombosis after carotid stenting has not been described before, although it is a well-known complication after coronary stenting.⁸ Many studies have been published concerning this complication following coronary stenting, be it with bare metal or drug-eluting stents.⁹ Combined platelet inhibition is crucial in preventing not only acute but also delayed stent thrombosis. In addition, as described before and as demonstrated in our third patient, phenprocoumon alone is not sufficient to prevent a stent thrombosis.¹⁰

The cases that we report emphasize the necessity of strict obedience to an antiplatelet regimen in the months after CAS. In none of our cases was the neurointerventionalist consulted before antiplatelet therapy was discontinued.

References

- Bhatt DL, Kapadia SR, Bajzer CT, et al. Dual antiplatelet therapy with clopidogrel and aspirin after carotid artery stenting. *J Invasive Cardiol* 2001;13:767-771.
- McKevitt FM, Randall MS, Cleveland TJ, Gaines PA, Tan KT, Venables GS. The benefits of combined anti-platelet treatment in carotid artery stenting. *Eur J Vasc Endovasc Surg* 2005;29:522-527.
- Cunningham EJ, Fiorella D, Masaryk TJ. Neurovascular rescue. *Semin Vasc Surg* 2005;18:101-109.
- Roubin GS, Yadav S, Iyer SS, Vitek J. Carotid stent-supported angioplasty: a neurovascular intervention to prevent stroke. *Am J Cardiol* 1996;78:8-12.
- Diethrich EB, Ndiaye M, Reid DB. Stenting in the carotid artery: initial experience in 110 patients. *J Endovasc Surg* 1996;3:42-62.
- Tong FC, Cloft HJ, Joseph GJ, et al. Abciximab rescue in acute carotid stent thrombosis. *Am J Neuroradiol* 2000;21:1750-1752.
- Chaturvedi S, Sohrab S, Tselis A. Carotid stent thrombosis. Report of 2 fatal cases. *Stroke* 2001;32:2700-2702.
- Moussa I, Oetgen M, Roubin G, et al. Effectiveness of clopidogrel and aspirin versus ticlopidine and aspirin in preventing stent thrombosis after coronary stent implantation. *Circulation* 1999;99:2364-2366.
- Ong AT, McFadden EP, Regar E, de Jaegere PP, van Domburg RT, Serruys PW. Late angiographic stent thrombosis (LAST) events with drug-eluting stents. *J Am Coll Cardiol* 2005;45:2088-2092.
- Makkar RR, Eigler NL, Kaul S, et al. Effects of clopidogrel, aspirin and combined therapy in a porcine ex vivo model of high-shear induced stent thrombosis. *Eur Heart J* 1998;19:1538-1546.