

Neoplasm

Meningioangiomas associated with neurofibromatosis: report of 2 cases in a single family and review of the literature

Ibrahim Omeis, MD^{a,*}, Virany Huynh Hillard, MD^a, Alex Braun, MD^b, Deborah L. Benzil, MD^a,
Raj Murali, MD^a, David H. Harter, MD^a

Departments of ^aNeurosurgery and ^bPathology, New York Medical College, Valhalla, NY 10595, USA

Received 4 August 2005; accepted 5 September 2005

Abstract

Background: Meningioangiomas (MA) is a rare benign disorder. It may occur sporadically or in association with neurofibromatosis (NF). The sporadic type typically presents with seizures, whereas that associated with NF is often asymptomatic. Of the 100 cases reported, only 14 are associated with NF. We now report 2 additional cases of MA associated with neurofibromatosis 2 (NF2) in a single family, with one occurring in the cerebellum. The etiology, pathology, and imaging features of MA are presented.

Case Description: A 38-year-old woman (patient 1) presented with a 4-month history of ataxia. She had been diagnosed previously with NF2. Magnetic resonance imaging (MRI) scans of the brain revealed bilateral acoustic neuromas and multiple calcified intracranial lesions. Her 13-year-old daughter (patient 2) presented with complex partial seizures. MRI scans of the brain revealed bilateral acoustic neuromas and a right parietal mass. Patient 1 underwent a suboccipital craniotomy to resect the right-sided acoustic neuroma. A small portion of normal-appearing cerebellar cortex was resected to avoid undue retraction. Histopathologic examination showed the presence of a lesion consistent with MA. Patient 2 underwent a right temporal-parietal craniotomy to remove the enhancing epileptogenic right posterior temporoparietal lesion. Histopathologic analysis showed a lesion consistent with meningioma and MA.

Conclusions: MA has been reported infrequently in association with NF2. We now report 2 cases of MA associated with NF2 in one family, and we add the cerebellum to possible locations of occurrence. MA should be considered in the differential diagnosis of cortical lesions, particularly in patients with NF2.

© 2006 Elsevier Inc. All rights reserved.

Keywords: Meningioangiomas; Neurofibromatosis; Cerebellum; Meningioma

1. Introduction

MA is a rare focal lesion involving the leptomeninges and underlying cortex [75]. It is characterized by meningo-vascular proliferation and leptomeningeal calcification [20]. MA was originally described in association with von Recklinghausen disease [5]. However, it has since been

known to occur sporadically, and it is potentially a surgically curable cause of epilepsy [73]. Of the 100 cases reported, only 14 are associated with NF. We now add 2 additional cases of MA in a mother and daughter with NF. We also report the presence of MA in the cerebellum of one of these patients.

2. Case report

2.1. Patient 1

A 38-year-old, right-handed Hispanic woman of short stature presented with a 6-month history of progressive gait

Abbreviations: EMA, epithelial membrane antigen; MA, meningioangiomas; MRI, magnetic resonance imaging; NF, neurofibromatosis.

* Corresponding author. Tel.: +1 914 594 7195; fax: +1 914 594 3641.

E-mail address: ibrahim_omeis@nycmc.edu (I. Omeis).

instability. Evaluation 4 years earlier for multiple subcutaneous nodules on the forehead and face had led to a diagnosis of neurofibromatosis 2 (NF2). Physical and neurological examination revealed frontal dysplasia, left proptosis, bilateral corneal opacities, left peripheral facial palsy, bilateral sensory neural hearing deficit, and hoarseness. Gait ataxia was present.

MRI scans of the brain revealed the presence of bilateral acoustic neuromas and multiple additional lesions, including bifrontal, falx, petrous ridge, and en plaque meningiomas (Fig. 1), some with large cystic diverticulae extending into the cortex. The patient underwent a suboccipital craniotomy for removal of the right-sided acoustic neuroma. A small portion of lateral cerebellar cortex was resected to avoid undue retraction during surgery. Postoperative MRI confirmed gross total resection of the lesion (Fig. 2). She had a prolonged hospital course and exacerbation of her lower cranial neuropathies that required the placement of a gastrostomy feeding tube.

Histopathologic analysis of the tissue revealed 4 distinct components: schwannoma (Fig. 3A); MA of the cerebellum (Fig. 3B); and 2 meningioma subtypes, 1 mesothelial (Fig. 3C) and 1 psammomatous (Fig. 3D).

2.2. Patient 2

A 13-year-old right-handed girl, the daughter of patient 1, presented with complex partial seizures. Her physical examination was unremarkable.

MRI scans of the brain revealed the presence of bilateral acoustic neuromas and a contrast-enhancing intra-axial lesion in the right parietal midconvexity region (Fig. 4).

Electroencephalography identified an epileptogenic focus in the posterior right temporal region.

The patient underwent a right temporal-parietal craniotomy and resection of the lesion. Postoperative MRI confirmed gross total resection of the tumor (Fig. 5). Her postoperative course was uncomplicated. She has remained seizure-free without anticonvulsant therapy postoperatively.

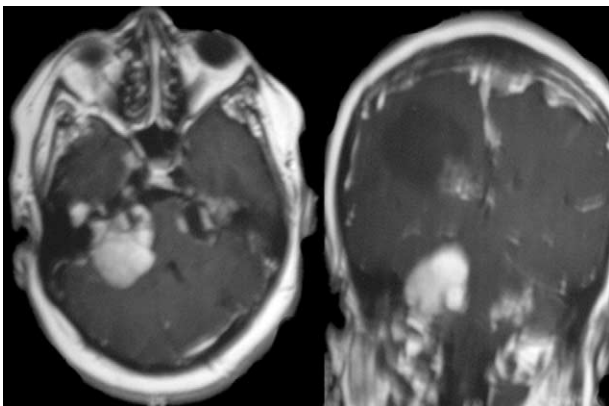


Fig. 1. Preoperative T1-weighted MRI scans with gadolinium of patient 1. Left: Axial image showing bilateral acoustic neuromas, the right larger than the left. Right: Coronal image showing left frontal bone dysplasia, en plaque meningioma, right frontal cystic lesion, and left cerebellar lesions.

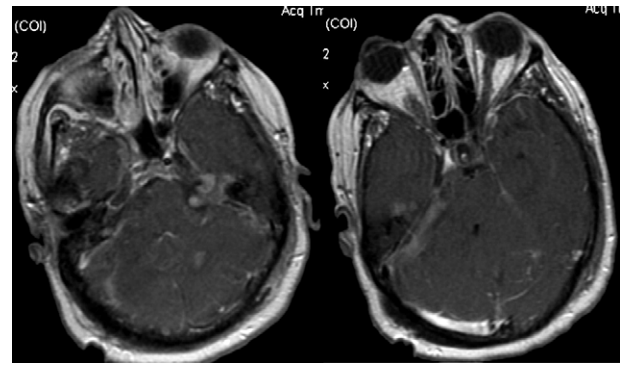


Fig. 2. Postoperative axial T1-weighted MRI scans with gadolinium showing gross total resection of right acoustic neuroma.

Histopathologic analysis of the tumor showed 2 distinct components. One portion was consistent with meningioma (Fig. 6A), and the other with MA (Fig. 6B).

3. Discussion

MA, a rare, benign disease, involves the meninges and cortex. It was first described in 1915 by Basso and Nuzum [5] as an incidental autopsy finding in a 15-year-old boy with NF. It was named by Worster-Drought et al [75] in 1937, who considered it a “forme fruste” of NF, that is, a patient presenting with restricted disease and no family history [68]. Since its initial description, approximately 100 cases of MA have been reported in the literature, 14 in association with NF (Tables 1 and 2). We now add 2 additional cases.

3.1. Demographic features

The median age of patients with MA at the time of diagnosis was 23 years for those associated with NF and 17 years for those occurring sporadically. The youngest patient reported with MA was 11 months [7], and the oldest was 71 years [62]. The male/female ratio was approximately equal in patients with MA associated with NF, but men outnumbered women by a ratio of 2:1 in patients with sporadic MA.

3.2. Location

In patients with sporadic MA, the temporal lobe (33%) is the most common location for MA followed by the frontal lobe (25%). In patients with MA associated with NF, the frontal lobe is the most common location for MA (35%). Multiple lesions of MA, when present, are more common in patients with NF (35%) than in patients without NF (13%). MA mainly involves the cerebral cortex (>80%), although other locations have been described, such as the third ventricle [6], pulvinar-cerebral peduncle [58], corpus callosum [30], trigeminal ganglion [14], and the brain stem [36]. We now add the cerebellum.

3.3. Clinical presentation

In patients with MA associated with NF, MA was found incidentally in 10 of the 12 cases in the literature for whom presentation was reported (Table 1). One patient presented

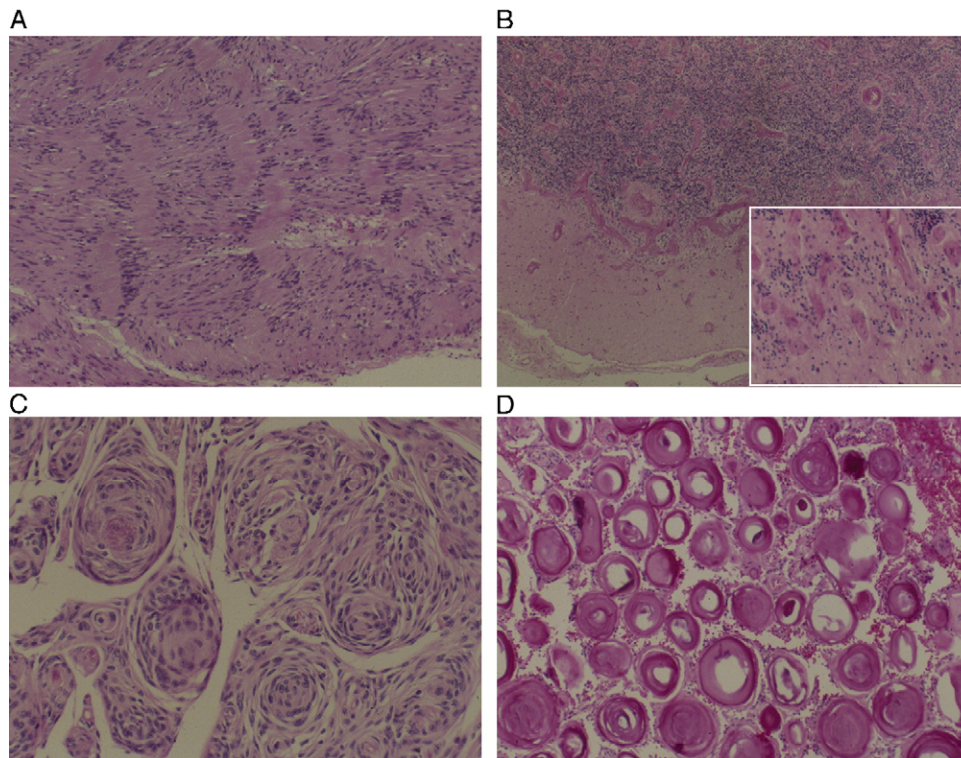


Fig. 3. Photomicrographs of tumors from patient 1, stained with hematoxylin-eosin. Histopathologic findings reveal (A) vestibular schwannoma consisting mostly of Antoni type A tissue with Verocay bodies (original magnification $\times 10$), (B) MA in cerebellar cortex with overlying meningioma (original magnification $\times 10$; inset, magnification $\times 100$), (C) transitional meningioma (original magnification $\times 40$), and (D) psammomatous meningioma (original magnification $\times 40$).

with a headache and one with focal seizure. Patient 2, who was subsequently diagnosed with NF2, presented with a partial complex seizure associated with the location of MA, which is an unusual characteristic of patients with MA and NF. In MA without NF, seizure was the prominent presenting symptom in 60 patients (73%). Other symptoms were headache in 9 patients, hemiparesis in 4, memory impairment in 1, personality change in 1, and vertigo in 1. In only 3 patients was the finding of MA considered incidental (Table 2).

3.4. Imaging

Patients with and without NF had similar findings on the various imaging modalities. The most common finding on computed tomography scan was a calcified enhancing lesion with surrounding low density. MRI findings showed hypointense signal on T1- and T2-weighted images and surrounding hyperintense signal on T2-weighted sequences. Most of these lesions were enhanced with gadolinium. However, MA may mimic other pathological processes on MRI, including meningioma [54], acute hemorrhage [3], calcified arteriovenous malformation, and encephalomalacia. In view of the wide spectrum of findings, radiographic imaging does not permit a precise diagnosis [18].

3.5. Pathogenesis

The pathogenesis of MA is unknown; however, 3 theories have been entertained [17,35,36,56]. First, MA could

originate as a microvascular malformation of the cerebral cortex that induces proliferation of arachnoidal and fibroblastic cells in the Virchow-Robin spaces. Second, MA could result from direct invasion of the brain parenchyma by a leptomeningeal-based meningioma. Third, MA could represent a meningovascular hamartoma that undergoes degenerative changes.

MA occurs in patients with and without NF, and some authors even have hypothesized that sporadic MA could be a forme fruste of NF [31,51,75]. Although historically MA is associated with neurofibromatosis 1 [40,42,56,61], growing evidence indicates a greater association with NF2 [66]. The NF2 gene on chromosome 22q12 encodes a widely expressed protein, merlin, which may link the actin cytoskeleton to cell-surface molecules important for cellular remodeling and growth regulation [4]. Merlin has been shown in a recent study [49] to interact with the cytoplasmic tail of the cell-surface glycoprotein CD44, which appears to be involved in growth-arrest signaling.

Patients with NF2 have an inactivating germline mutation of the NF2 gene that predisposes them to the development of schwannomas and meningiomas [19,45]. In a large proportion of cases of sporadic schwannomas and meningiomas, the NF2 gene is also inactivated by somatic mutations, leading to the loss of merlin. This finding suggests that the NF2 gene product is an important growth regulator for Schwann and leptomeningeal cells [44,60].

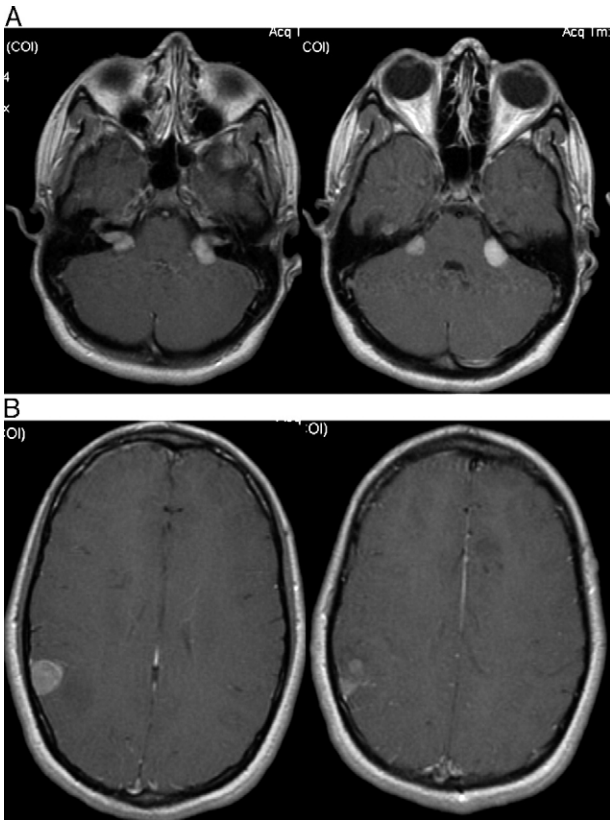


Fig. 4. Preoperative axial T1-weighted MRI scans with gadolinium of patient 2 showing (A) bilateral acoustic neuromas and (B) the right temporal-parietal lesion and the left frontal lesion.

Sporadic MA and NF2-associated MA are histologically similar but clinically different. Whereas sporadic MA is usually a single, clinically symptomatic lesion, NF2-associated MA may occur in multiple locations and is usually diagnosed incidentally. Stemmer-Rachamimov et al [67], in an attempt to determine whether sporadic cases of MA were associated with somatic or germline alterations of the NF2 gene, screened the NF2 gene in 12 patients with

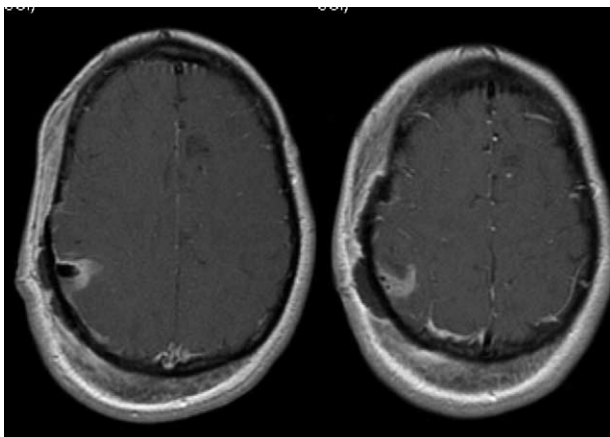


Fig. 5. Postoperative axial T1-weighted MRI scans with gadolinium, showing complete resection of the right temporal-parietal lesion.

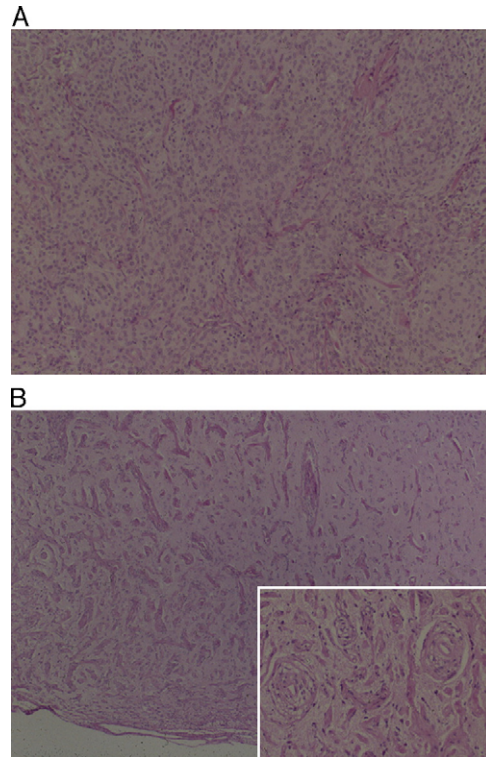


Fig. 6. Photomicrographs of tumors from patient 2 stained with hematoxylin-eosin. Histopathologic findings reveal (A) meningioma (original magnification $\times 10$), (B) MA (original magnification $\times 10$). Inset, Perivascular growth of meningeothelial and fibroblastlike cells (original magnification $\times 100$).

sporadic MA. They found no germline mutations. They also found that somatic mutations of the NF2 gene do not play a major role in sporadic MA.

Table 1
Reported cases of patients with MA and NF

| Series (reference no.) | Age (y)/sex | Location | Presentation |
|----------------------------------|-------------|-------------------------|-------------------------|
| Bassoe and Nuzum, 1915 [5] | 15/M | Right frontal | Incidental |
| Foerster and Gagel, 1932 [11] | 21/M | Frontoparietal | Incidental |
| Worster-Drought et al, 1937 [75] | 25/M | Right frontal | Incidental |
| Beck, 1938 [6] | 23/F | Third ventricle | Incidental |
| Hozay, 1953 [23] | 39/M | Occipitoparietal | Incidental |
| Rubinstein, 1963 [58] | 16/F | Frontoparietal | Incidental |
| | 23/F | Pulvinar | Incidental |
| | 32/M | Cingulate gyrus | Incidental |
| Feigin, 1971 [10] | NS | NS | Incidental |
| Halper et al, 1986 [20] | 38/F | Parietotemporal | Incidental |
| Huson et al, 1988 [24] | 43/M | Right frontal | HA, drowsiness |
| Liu et al, 1989 [42] | 22/F | Left frontal | Seizure |
| Jay et al, 1997 [27] | 6/M | Frontotemporal | NS |
| Mokhtari et al, 1998 [48] | 24/M | NS | NS |
| Present cases | 13/F | Right temporal-parietal | Complex partial seizure |
| | 38/F | Left cerebellar | Ataxic gait |

NS indicates not stated; HA, headache.

Table 2
Reported cases of patients with MA without NF

| Series (reference no.) | Age (y)/sex | Location | Presentation | Surgical outcome | Associated with |
|----------------------------------|-------------|---------------------------|-----------------------------|------------------|--|
| Johnson and Nielson, 1976 [28] | 23/M | NS | Incidental | NS | |
| Rhodes and Davis, 1978 [57] | 27/F | Right frontal | Headache | NS | |
| Kasantikul and Brown, 1981[31] | 15/M | Right frontal | Seizure | NS | Vascular malformation, meningioma |
| | 23/M | Right temporal | Seizure | NS | |
| Auer et al, 1982 [3] | 15/M | Frontal | Headache | NS | |
| Jun and Burdick, 1984 [30] | NS | Corpus Callosum | Headache, nausea, vomiting | NS | |
| Halper et al, 1986 [20] | 10/F | Right frontal | Seizure | NS | |
| | 17/F | Right frontal | Seizure | NS | |
| | 26/M | Left temporal | Seizure | NS | Vascular malformation |
| | 30/M | Right frontal | Seizure | NS | |
| | 70/M | Left occipital | Incidental | NS | |
| Harada et al, 1987 [22] | 62/F | Right frontal | Seizure | NS | Anterior cerebral artery aneurysm, medullary venous malformation |
| Kunishio et al, 1987 [40] | 39/M | Right parietal | Incidental | NS | |
| Sakaki et al, 1987 [61] | 30/F | Right temporal | Seizure | NS | Vascular malformation |
| Kuzniecky et al, 1988 [41] | 24/M | Right temporal | Seizure | NS | |
| Matias-Guiu et al, 1988 [46] | 42/M | Right parietal | Seizure | NS | |
| Garen et al, 1989 [14] | 44/M | Right trigeminal ganglion | Atypical facial pain | NS | |
| Ogilvy et al, 1989 [51] | 9/M | Temporal | Seizure | NS | Hamartoma |
| Paulus et al, 1989 [55] | 5/M | Temporal | Seizure | NS | |
| Louw et al, 1990 [45] | 33/M | Frontotemporal | Headache | NS | Meningioma |
| Whiting et al, 1990 [71] | 18/F | Right temporal | Seizure | NS | Encephalocele |
| Aizpuru et al, 1991 [1] | 2/M | Right parietal | Seizure | NS | |
| | 5/M | Right temporal | Seizure | NS | |
| | 9/F | Left temporal | Seizure | NS | |
| | 21/M | Right temporal | Seizure | NS | |
| Goates et al, 1991 [17] | 13/F | Left parietal | Seizure | NS | Vascular malformation |
| Oka et al, 1991 [52] | 14 mo/F | Left parietotemporal | Seizure | NS | |
| Partington et al, 1991 [54] | 17/F | Right frontal | Generalized seizure | NS | |
| | 19/M | Right frontal | Seizure | NS | |
| Ruscalleda et al, 1991 [59] | NS | NS | NS | NS | |
| Wilson et al, 1991 [74] | 17/M | Frontal | Seizure | Transitional | Meningioma |
| Tien et al, 1992 [70] | 2/F | Right occipital | Seizure | NS | |
| | 7/M | Left frontal | Seizure | NS | |
| Blumenthal et al, 1993 [7] | 11 mo/M | Right frontal | Seizure | NS | Meningioma |
| Drut et al, 1993 [9] | NS | NS | NS | NS | |
| Fujimoto et al, 1993 [12] | 7/F | NS | NS | NS | |
| Kim et al, 1993 [34] | 18/M | Right temporal | Seizure (15 y) | NS | |
| Harada et al, 1994 [21] | NS | NS | Seizure | NS | |
| Gomez-Anson et al, 1995 [18] | 4/M | Bifrontal | Seizure, personality change | NS | |
| Kollias et al, 1994 [36] | 3/F | Brainstem | NS | NS | |
| | 12/M | Right temporal | Seizure | NS | |
| Prayson, 1995 [56] | 11/M | Right frontal | Seizure | NS | |
| | 14/F | Right temporal | Seizure | NS | |
| | 32/F | Left frontal | Seizure | NS | |
| Lopez et al, 1996 [43] | 15/M | Left temporal | Seizure | NS | Oligodendroglioma |
| Al-Hindi et al, 1997 [2] | 7/F | Left temporal | Seizure | NS | |
| Tacconi et al, 1997 [68] | 60/M | Right frontoparietal | Focal seizure | Seizure-free | |
| Chakrabarty and Franks, 1999 [8] | 22/M | Left frontoparietal | Seizure | NS | |
| Giargaspero et al, 1999 [15] | 9/M | Frontal | Seizure | transitional | |

(continued on next page)

Table 2 (continued)

| Series (reference no.) | Age (y)/sex | Location | Presentation | Surgical outcome | Associated with |
|---------------------------------------|-------------|-------------------------------------|--------------------------------|---------------------|--------------------|
| Park et al, 1999 [53] | 47/F | Left frontoparietal, right parietal | Headache, generalized seizure | Seizure-free | |
| | 53/M | Left frontoparietal | Headache, generalized seizure | Seizure-free | |
| Wiebe et al, 1999 [73] | 10/F | Left temporal | Focal seizure | Persistent seizure | Hemorrhagic stroke |
| | 12/M | Left mesial temporal | Seizure | Seizure-free | |
| | 17/M | Right temporal | Seizure | Persistent seizure | |
| | 18/F | Right occipitoparietal | Simple partial seizure | Seizure-free | |
| | 31/M | Left temporal | Seizure | Seizure-free | |
| | 33/F | Left temporal | Seizure | Persistent seizure | |
| | 37/F | Right temporal | Seizure | Persistent seizure | |
| | 28/M | Occipitotemporal | Seizure | Transitional | |
| Izycka-Swieszewska et al, 2000 [25] | 31/F | NS | NS | NS | |
| Jallo et al, 2000 [26] | NS | NS | NS | NS | |
| Jorge et al, 2000 [29] | NS | Temporal | Seizure | NS | |
| Mut et al, 2000 [50] | 20/M | Right temporal | Seizure | NS | Meningioma |
| Scroop et al, 2000 [64] | 16/M | Left temporal | Focal seizure | Seizure-free | |
| Savargaonkar et al, 2001 [62] | 71/M | Left occipital | Focal seizure | NS | |
| Sinkre et al, 2001 [66] | 8/M | NS | NS | NS | Meningioma |
| Garcia Muret et al, 2002 [13] | NS | Right occipital | Generalized seizure | NS | |
| Girija and Somanath, 2002 [16] | 43/M | NS | Migraine, left weakness | NS | |
| Kim NR et al, 2002 [32] | 3/M | Right frontoparietal | Partial seizure, left weakness | Seizure-free | |
| | 4/M | Left frontal | Headache | Symptom-free | |
| | 6/M | Left temporal | Right hemiparesis | Persistent weakness | |
| | 9/M | Bifrontal | Seizure | Seizure-free | |
| | 19/M | Right temporal | Seizure, vertigo | Seizure-free | |
| | NS | Left frontal | Headache | NS | |
| Kim et al, 2002 [33] | NS | Frontal | Intracerebral hemorrhage | NS | |
| | NS | NS | NS | NS | |
| Meyer et al, 2002 [47] | 4/F | NS | Seizure | NS | Meningioma |
| Takeshima et al, 2002 [69] | 16/M | Right temporal | HA | NS | Meningioma |
| Koutsopoulos et al, 2003 [37] | 10/F | Left frontal | Seizure | NS | |
| Krolczyk and Prayson, 2003 [38] | 11/M | Right temporal | Seizure | NS | |
| Kuchelmeister et al, 2003 [39] | 58/M | Right frontal | Forgetfulness | Symptom-free | |
| Savargaonkar et al, 2003 [63] | 3/F | Temporal | Seizure | NS | |
| | NS | NS | NS | NS | |
| Seo et al, 2003 [65] | NS | Frontotemporal | Seizure | NS | |
| Widdess-Walsh and Friedman, 2003 [72] | 15/F | NS | Left hemiparesis | NS | |

3.6. Pathology

MA appears as a firm, whitish, sharply demarcated, plaquelike mass within the cortex. Microscopically, this lesion is characterized by a meningothelial and fibroblastic proliferation ensheathing an angiomatous microvascular network [73]. Histological analysis allows classification into predominantly cellular and predominantly vascular lesions. Some lesions demonstrate a predominance of meningothelial elements accompanying the angiomatous vascular network, infrequently with frank meningioma formation. Scattered psammoma bodies and dense osteoid formation may be present [55,61,67]. Other lesions in which

meningothelial cells are inconspicuous exhibit hyalinized vascular channels associated with perivascular fibrosis and fibroblastic cells. MA encroaches upon the intervening cortical parenchyma, which becomes gliotic and may contain neurons with neurofibrillary tangles. These neurofibrillary tangles, not associated with amyloid plaques, could represent a nonspecific degenerative change [67].

Immunohistochemistry has limited diagnostic value, as there is no constant staining pattern among MA cases that would differentiate them from other pathological processes; staining for vimentin and EMA has been noted [73]. Nonetheless, immunohistochemistry may aid in the differentiation and exclusion of other disorders such as menin-

gioma and schwannoma, because the latter shares common histological features with MA. Schwannomas are diffusely S100 protein-positive and EMA-negative, whereas only 20% of meningiomas stain focally with S100 protein, and 80% stain EMA-positive [18,55]. Moreover, MIB-1 labeling is typically low, less than 1% [56].

3.7. Associated abnormalities

MA was associated with adjacent astrocytoma, ependymoma, and a primitive neuroectodermal tumor [27], meningioma [10,27,38,41,75], hamartoma [50], encephalocoele [71], oligodendroglioma [43], anterior cerebral aneurysm and venous angioma [21], and vascular malformations [17]. In our patients, MA was associated with meningioma (patient 2) and schwannoma (patient 1).

3.8. Electrophysiology

Scalp electroencephalography data revealed 2 patterns of epileptiform discharges. One resembled a focal lesion whose epileptogenicity is produced by adjacent cortex. A second pattern shows an epileptiform discharge that is similar to that of cortical dysplasia in which the lesion itself produces spikes [73].

3.9. Surgical outcome of patients presenting with seizure

In one review [73], seizure-free rates after resection of foci of MA ranged from 43% to 68%. A decrease in seizure frequency and severity occurred in 30%, and no seizure improvement occurred in 5%.

Age, MA location and size, and duration of symptoms did not correlate with seizure outcome. Thus, outcome after surgery for seizure caused by MA is variable. However, lesionectomy may afford considerable improvement, and in some cases, a surgical cure may be effected.

4. Conclusions

MA is a distinct clinicopathologic entity that has an occasional association with NF2. In its sporadic form, the genetic basis is not well clarified. We report 2 cases of MA associated with NF in a single family, and the cerebellum as a new location of occurrence. The wide spectrum of imaging expressions of MA often impedes the clinical diagnosis. MA should be considered in the differential diagnosis of cortical lesions, particularly in patients with NF2.

References

- [1] Aizpuru RN, Quencer RM, Norenberg M, Altman N, Smirniotopoulos J. Meningioangiomas: clinical, radiological, and histopathological correlation. *Radiology* 1991;179:819–21.
- [2] Al-Hindi A, Subach B, Hamilton R. Case of the month. *Brain Pathol* 1997;7:1023–4.
- [3] Auer RN, Budny J, Drake CG, Ball MJ. Frontal lobe perivascular schwannoma. Case report. *J Neurosurg* 1982;56:154–7.
- [4] Baser ME, R Evans DG, Gutmann DH. Neurofibromatosis 2. *Curr Opin Neurol* 2003;16:27–33.
- [5] Bassoe P, Nuzum F. Report of a case of central and peripheral neurofibromatosis. *J Nerv Ment Dis* 1915;42:785–96.
- [6] Beck E. Ein Beitrag zur Kenntnis der Neurofibromatose (Recklinghausensche Krankheit). *Ztschr f d ges Neurol u Psychiat* 1938;162:426–42.
- [7] Blumenthal D, Berho M, Bloomfield SS, Schochet Jr SS, Kaufman HH. Childhood meningioma associated with meningoangiomas. *J Neurosurg* 1993;78:287–9.
- [8] Chakrabarty A, Franks AJ. Meningioangiomas: a case report and review of the literature. *Br J Neurosurg* 1999;13:167–73.
- [9] Drut MM, Miles JM, Gilbert-Barnes E. Pathological case of the month. Meningioangiomas. *Am J Dis Child* 1993;147:1009–10.
- [10] Feigin I. The nerve sheath tumor, solitary and in von Recklinghausen's disease; a unitary mesenchymal concept. *Acta Neuropathol (Berl)* 1971;17:188–200.
- [11] Foerster O, Gagel O. Ein fall von Recklinghausenscher krankheit mit fünf nebeneinander bestehenden Verschiedenartige Tumor-bildungen. *Ztschr f d ges Neurol u Psychiat* 1932;138:339–60.
- [12] Fujimoto K, Nikaidoh Y, Yuasa T, Nagata K, Ida Y, Fujioka M, Ohnishi H, Kurokawa S. Meningioangiomas not associated with von Recklinghausen's disease—case report. *Neurol Med Chir (Tokyo)* 1993;33:651–5.
- [13] Garcia Muret MP, Puig L, Allard C, Alomar A. Hypomelanosis of Ito with Sturge-Weber syndrome-like leptomeningeal angiomas. *Pediatr Dermatol* 2002;19:536–40.
- [14] Garen PD, Powers JM, King JS, Perot Jr PL. Intracranial fibrous lesion. *J Neurosurg* 1989;70:475–7.
- [15] Giangaspero F, Guiducci A, Lenz FA, Mastrorandi L, Burger PC. Meningioma with meningoangiomas: a condition mimicking invasive meningiomas in children and among adults: report of two cases and review of the literature. *Am J Surg Pathol* 1999;23:872–5.
- [16] Girija AS, Somanath V. A case of hemiplegic migraine with leptomeningeal angiomas. *Neurol India* 2002;50:522–3.
- [17] Goates JJ, Dickson DW, Horoupian DS. Meningioangiomas: an immunocytochemical study. *Acta Neuropathol (Berl)* 1991;82:527–32.
- [18] Gomez-Anson B, Munoz A, Blasco A, Madero S, Esparza J, Cordobes F, Orejon G, Mateos F. Meningioangiomas: advanced imaging and pathological study of two cases. *Neuroradiology* 1995;37:120–3.
- [19] Gusella JF, Ramesh V, MacCollin M, Jacoby LB. Neurofibromatosis 2: loss of merlin's protective spell. *Curr Opin Genet Dev* 1996;6: 87–92.
- [20] Halper J, Scheithauer BW, Okazaki H, Laws ER. Meningioangiomas: a report of six cases with special reference to the occurrence of neurofibrillary tangles. *J Neuropathol Exp Neurol* 1986;45:426–46.
- [21] Harada K, Inagawa T, Nagasako R. A case of meningoangiomas without von Recklinghausen's disease. Report of a case and review of 13 cases. *Childs Nerv Syst* 1994;10:126–30.
- [22] Harada K, Kobayashi S, Sigemori M, Watanabe M, Kuramoto S. Medullary venous malformation with azygos anterior cerebral artery aneurysm: a case report. *No Shinkei Geka [in Japanese]* 1987;15: 327–33.
- [23] Hozay J. Une angioneuromatose meningo-encephalique diffuse. *Rev Neurol [in French]* 1963;89:222–36.
- [24] Huson SM, Harper PS, Compston DAS. Von Recklinghausen neurofibromatosis. A clinical and population study in south-east Wales. *Brain* 1988;111:1355–81.
- [25] Izycka-Swieszewska E, Rzepko R, Koczyński S, Franc Z, Szurawska E, Borowska-Lehman J. Meningioangiomas with a predominant fibrocalcifying component. *Neuropathology* 2002;20:44–8.
- [26] Jallo GI, Silvera VM, Abbott IR. Meningioangiomas. *Pediatr Neurosurg* 2000;32:220–1.
- [27] Jay V, Edwards V, Varela-Stavrinou M, Rutka J. Unique intracerebral tumor with divergent differentiation in a patient presenting as NF2: report of a case with features of astrocytoma, ependymoma, and PNET. *Ultrastruct Pathol* 1997;21:57–71.

- [28] Johnson PC, Nielsen SL. Localized neurofibrillary degeneration in vascular malformations. *J Neuropathol Exp Neurol* 1976;35:300.
- [29] Jorge CL, Nagahashi-Marie SK, Pedreira CC, Rosenberg S, Valerio RM, Valente KD, Yacubian EM. Clinical characteristics and surgical outcome of patients with temporal lobe tumors and epilepsy. *Arq Neuropsiquiatr* 2000;58:1002-8.
- [30] Jun C, Burdick B. An unusual fibro-osseous lesion of the brain. *J Neurosurg* 1984;60:1308-11.
- [31] Kasantikul V, Brown WJ. Meningioangiomas in the absence of von Recklinghausen's disease. *Surg Neurol* 1981;15:71-5.
- [32] Kim NR, Choe G, Shin SH, Wang KC, Cho BK, Choi KS, Chi JG. Childhood meningiomas associated with meningioangiomas: report of five cases and literature review. *Neuropathol Appl Neurobiol* 2002;28:48-56.
- [33] Kim WY, Kim IO, Kim S, Cheon JE, Yeon M. Meningioangiomas: MR imaging and pathological correlation in two cases. *Pediatr Radiol* 2002;32:96-8.
- [34] Kim YW, Choi WS, Lee J, Yang MH. Meningioangiomas—a case report [in Korean]. *J Korean Med Sci* 1993;8:308-11.
- [35] Kissil JL, Johnson KC, Eckman MS, Jacks T. Merlin phosphorylation by p21 activated kinase 2 and effects of phosphorylation on merlin localization. *J Biol Chem* 2002;277:10394-9.
- [36] Kollias SS, Crone KR, Ball Jr WS, Prenger EC, Ballard ET. Meningioangiomas of the brain stem. Case report. *J Neurosurg* 1994;80:732-5.
- [37] Koutsopoulos AV, Yannopoulos A, Stathopoulos EN, Evangelidou A, Panayiotides JG, Kafousi M, Krasoudakis A, Markakis E, Delides GS. Meningioangiomas with predominantly cellular pattern. *Neuropathology* 2003;23:141-5.
- [38] Krolczyk S, Prayson RA. Pathologic quiz case: an 11-year-old boy with intractable seizures. *Arch Pathol Lab Med* 2003;127:e349-50.
- [39] Kuchelmeister K, Richter HP, Kepes JJ, Schachenmayr W. Case report: microcystic meningioma in a 58-year-old man with multicystic meningioangiomas. *Neuropathol Appl Neurobiol* 2003;29:170-4.
- [40] Kunishio K, Yamamoto Y, Sunami N, Satoh T, Asari S, Yoshino T, Ohtuki Y. Histopathologic investigation of a case of meningioangiomas not associated with von Recklinghausen's disease. *Surg Neurol* 1987;27:575-9.
- [41] Kuzniecky R, Melanson D, Robitaille Y, Olivier A. Magnetic resonance imaging of meningio-angiomas. *Can J Neurol Sci* 1988;15:161-4.
- [42] Liu SS, Johnson PC, Sonntag VKH. Meningioangiomas: a case report. *Surg Neurol* 1989;31:376-81.
- [43] Lopez JL, Ereno C, Oleaga L, Areitio E. Meningioangiomas and oligodendroglioma in a 15-year-old boy. *Arch Pathol Lab Med* 1996;120:587-90.
- [44] Louis DN, Ramesh V, Gusella JF. Neuropathology and molecular genetics of neurofibromatosis 2 and related tumors. *Brain Pathol* 1995;163-72.
- [45] Louw D, Sutherland G, Halliday W, Kaufmann J. Meningiomas mimicking cerebral schwannoma. *J Neurosurg* 1990;73:715-9.
- [46] Matias-Guiu X, Molet J, Ferrer I, Prat J. Meningio-angiomas: a case report. *Br J Neurosurg* 1988;2:97-100.
- [47] Meyer S, Romeike B, Strowitzki M, Grunewald I, Graf N, Reinhard H, Aliani S. Meningioangiomas with associated meningioma in a 4-year-old girl presenting with a focal seizure. *Nervenarzt* [in German] 2002;73:990-4.
- [48] Mokhtari K, Uchihara T, Clemenceau S, Baulac M, Duyckaerts C, Hauw JJ. Atypical neuronal inclusion bodies in meningioangiomas. *Acta Neuropathol (Berl)* 1998;96:91-6.
- [49] Morrison H, Sherman LS, Legg J, Banine F, Isacke C, Haipek CA, Gutmann DH, Ponta H, Herrlich P. The NF2 tumor suppressor gene product, merlin, mediates contact inhibition of growth through interactions with CD44. *Genes Dev* 2001;15:968-80.
- [50] Mut M, Soylemezoglu F, Firat MM, Palaoglu S. Intraparenchymal meningioma originating from underlying meningioangiomas. Case report and review of the literature. *J Neurosurg* 2000;92:706-10.
- [51] Ogilvy CS, Chapman PH, Gray M, de la Monte SM. Meningioangiomas in a patient without von Recklinghausen's disease. Case report. *J Neurosurg* 1989;70:483-5.
- [52] Oka Y, Sakaki S, Yamashima M, Nakagawa K, Matsuoka K, Matsui H. A case of meningioangiomas in an infant. *No Shinkei Geka* [in Japanese] 1991;19:761-5.
- [53] Park MS, Suh DC, Choi WS, Lee SY, Kang GH. Multifocal meningioangiomas. A report of two cases. *AJNR Am J Neuroradiol* 1999;20:677-80.
- [54] Partington CR, Graves VB, Hegstrand LR. Meningioangiomas. *AJNR Am J Neuroradiol* 1991;12:549-52.
- [55] Paulus W, Peiffer J, Roggendorf W. Meningio-angiomas. *Pathol Res Pract* 1989;184:446-52.
- [56] Prayson RA. Meningioangiomas: a clinicopathologic study including MIB1 immunoreactivity. *Arch Pathol Lab Med* 1995;119:1061-4.
- [57] Rhodes RH, Davis RL. An unusual fibro-osseous component in intracranial lesions. *Hum Pathol* 1978;9:309-19.
- [58] Rubinstein LJ. Tumeurs et hamartomes dans la neurofibromatose centrale. In: Michaux L, Feld M, editors. *Les Phakomatoses Cerebrales*. S.P.E.I; 1963. p. 426-51.
- [59] Ruscalleda J, Coscojuela P, Guardia E, DeJuan M. General case of the day. Cerebromeningeal angiomas (Sneddon syndrome). *Radiographics* 1991;11:929-31.
- [60] Ruttledge MH, Sarrazin J, Rangaratnam S, Phelan CM, Twist E, Merel P, Delatrrre O, Thomas G, Nordenskjold M, Collins VP, Dumanski JP, Rouleau GA. Evidence for the complete inactivation of the NF2 gene in the majority of sporadic meningiomas. *Nat Genet* 1994;6:180-4.
- [61] Sakaki S, Nakagawa K, Takeda S. Meningioangiomas not associated with von Recklinghausen's disease. *Neurosurgery* 1987;20:797-801.
- [62] Savargaonkar P, Bhuiya T, Valderrama E, Farmer P. Scrape cytology of meningioangiomas: a report of two cases with diagnostic cytologic features. *Acta Cytol* 2001;45:1069-72.
- [63] Savargaonkar P, Chen S, Bhuiya T, Valderrama E, Bloom T, Farmer PM. Meningioangiomas: report of three cases and review of the literature. *Ann Clin Lab Sci* 2003;33:115-8.
- [64] Scroop R, Voyvodic F, Sage MR. Meningioangiomas. *Australas Radiol* 2000;44:460-3.
- [65] Seo DW, Park MS, Hong SB, Hong SC, Suh YL. Combined temporal and frontal epileptogenic foci in meningioangiomas. *Eur Neurol* 2003;49:184-6.
- [66] Sinkre P, Perry A, Cai D, Raghavan R, Watson M, Wilson K, Barton Rogers B. Deletion of the NF2 region in both meningioma and juxtaposed meningioangiomas: case report supporting a neoplastic relationship. *Pediatr Dev Pathol* 2001;6:568-72.
- [67] Stemmer-Rachamimov A, Horgan M, Taratuto AL, Munoz DG, Smith TW, Frosch MP, Louis DN. Meningioangiomas is associated with neurofibromatosis 2 but not with somatic alterations of the NF2 gene. *J Neuropathol Exp Neurol* 1997;56:485-9.
- [68] Tacconi L, Thom M, Symon L. Cerebral meningioangiomas: case report. *Surg Neurol* 1997;48:255-60.
- [69] Takeshima Y, Amatya VJ, Nakayori F, Nakano T, Sugiyama K, Inai K. Meningioangiomas occurring in a young male without neurofibromatosis: with special reference to its histogenesis and loss of heterozygosity in the NF2 gene region. *Am J Surg Pathol* 2002;26:125-9.
- [70] Tien RD, Osumi A, Oakes JW, Madden JF, Burger PC. Meningioangiomas. CT and MR findings. *J Comput Assist Tomogr* 1992;16:361-5.
- [71] Whiting DM, Awad IA, Miles J, Chou SS, Luders H. Intractable complex partial seizures associated with occult temporal lobe encephalocele and meningioangiomas: a case report. *Surg Neurol* 1990;34:318-22.

- [72] Widdess-Walsh P, Friedman NR. Left-sided facial nevus with contralateral leptomeningeal angiomas in a child with Sturge-Weber syndrome: case report. *J Child Neurol* 2003;18:304-5.
- [73] Wiebe S, Munoz DG, Smith S, Lee DH. Meningioangiomas: a comprehensive analysis of clinical and laboratory features. *Brain* 1999;4:709-26.
- [74] Wilson D, Dempsey RJ, Clark DB. Meningioma developing from underlying meningoangiomas. *J Neuropathol Exp Neurol* 1991;50:371.
- [75] Worster-Drought C, Carnegie-Dickson WE, McMenemy WH. Multiple meningeal and perineural tumours with analogous changes in the glia and ependyma (neurofibroblastomas): with report of two cases. *Brain* 1937;60:85-117.

The Blunt End

There is little evidence that the use of HIT to improve safety has any sustained positive effect. It can, in fact, be detrimental, as shown in the comparison of manual control of a status board for OR scheduling with a computerized system. One reason is the very poor understanding of what human beings at the “sharp end” of patient care actually do. HIT developed to serve management, the “blunt end,” which uses policies, procedures, resources, and constraints. Blunt HIT can hamper cognitive work and complex human interactions in patient care (Nameth C, et al. *J Biomed Informatics* 2005;38:18-25, available at www.sciencedirect.com).

—AAPS News, Vol 62, No. 1
April 2006
www.aapsonline.org