

Case report

Cheiro-oral-pedal syndrome due to brainstem hemorrhage

Osamu Igarashi, Hiroaki Iguchi, Naoko Ogura, Yasumitsu Ichikawa,
Tetsuhito Kiyozuka, Kiyokazu Kawabe, Michiyuki Maruyama,
Toshiki Fujioka, Ken Ikeda, Yasuo Iwasaki*

Department of Neurology, Toho University Omori Hospital, 6-11-1 Omorinishi Ota-ku, Tokyo 143-8541, Japan

Received 16 August 2004; received in revised form 25 January 2005; accepted 8 February 2005

Abstract

Cheiro-oral-pedal syndrome is characterized by specific sensory disturbance around the corner of the mouth, in the hand and in the foot on the same side. Lesions responsible for causing this syndrome vary. We report two cases of cheiro-oral-pedal syndrome due to midbrain and pontine hemorrhage, respectively. Pontine hemorrhage producing cheiro-oral-pedal syndrome has been reported in three cases, but this is the first case that midbrain hematoma exhibits this syndrome. Damage in the sensory pathway can cause cheiro-oral-pedal syndrome. Difference in the threshold may explain the specific sensory pattern in this syndrome. Cheiro-oral-pedal syndrome is caused by lacunar infarction in majority of the cases. However, it should be kept in mind that hematomas can cause cheiro-oral-pedal syndrome.

© 2005 Elsevier B.V. All rights reserved.

Keywords: Cheiro-oral-pedal syndrome; Midbrain hemorrhage; Pontine hemorrhage; Threshold

1. Introduction

Cheiro-oral-pedal syndrome is a unique sensory disturbance characterized by a unilateral sensory disturbance around the corner of the mouth, in the hand and in the foot on the same side [1]. It is usually due to a lesion in the thalamocortical projections or thalamus and brainstem. We report two cases of cheiro-oral-pedal syndrome, underlying conditions of which were hematomas in the midbrain and pons, respectively. Pontine hemorrhage causing cheiro-oral-pedal syndrome has been reported in three cases [1,2]. However, none has been reported in this syndrome due to midbrain hemorrhage, so far as literature has been surveyed. It is well known that damage of the sensory pathway can cause cheiro-oral-pedal syndrome. Difference in the threshold may play an important role in the development of specific sensory pattern.

2. Case reports*2.1. Case 1*

A 46-year-old hypertensive man noticed diplopia and a numbness in the right corner of mouth, hand and leg in the same region. Limitation in upward, downward and adduction movements of the left eye was also noted. There was no impairment of abduction. Nystagmus was not noticed. Movement of right eye was normal. Pupillary light reflexes were normal on both sides. Pupillary size was normal on both sides. Other cranial nerves were normal on both sides. Hypesthesia and paraesthesia were present in the right perioral, hand and leg region. There was neither muscle weakness nor cerebellar ataxia. Brain CT showed localized high-density area in the left tegmentum of the midbrain. T2-weighted images (TR = 4000, TE = 100 ms) disclosed high intensity, and T1-weighted images (TR = 430, TE = 15 ms) exhibited high-intensity area in the left tegmentum of the midbrain (Fig. 1). Neurological dysfunctions were due to lesions in the medial lemniscus and the partial involvement of third nerve nucleus. Hypesthesia and paraesthesia were diminished in the

* Corresponding author. Tel.: +81 337682566.

E-mail address: yaso@med.toho-u.ac.jp (Y. Iwasaki).

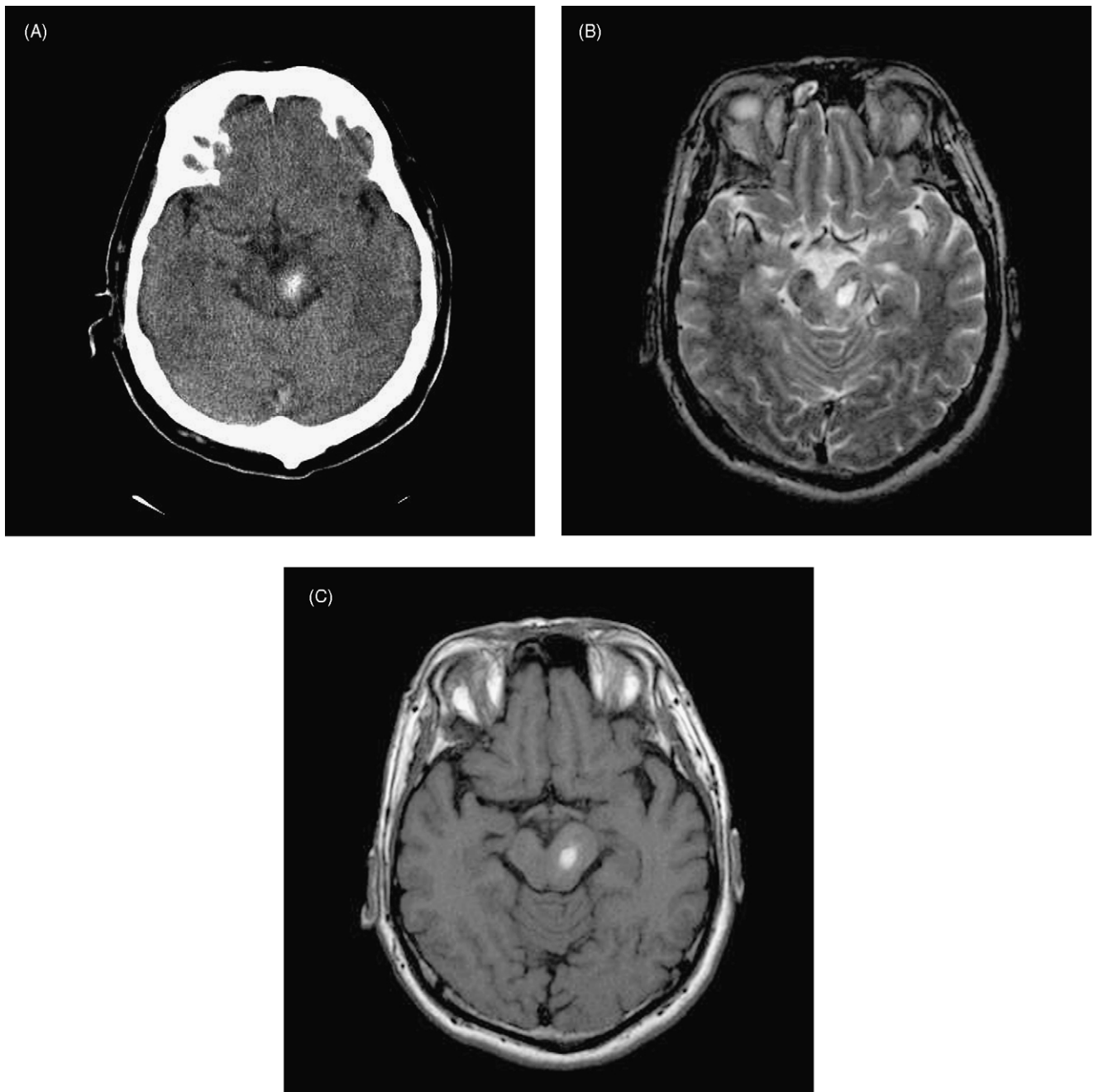


Fig. 1. (A) CT scan in Case 1 exhibiting localized high-density area in the left tegmentum of the midbrain. (B and C) Both T2- and T1-weighted MRI showing high-intensity area in the left tegmentum of the midbrain.

foot and leg region, but were still present in the hand after 6 months.

2.2. Case 2

A 56-year old hypertensive and hyperlipidemic man suddenly developed numbness in the left hand and foot. A few minutes later, he noticed numbness in the left corner of the mouth and he was brought to emergency department. His blood pressure was 202/104 mmHg. Pupillary light reflexes

and size were normal in both eyes. Eye movements were normal, but horizontal nystagmus was observed in both eyes. Other cranial nerves were normal. Muscle strength and deep tendon reflexes were normal. Hypesthesia and paraesthesia were present in the right perioral, hand and leg region. There was neither muscle weakness nor cerebellar ataxia. Brain CT showed localized high-density area in the right tegmentum of the pons. T2-weighted images (TR = 4000, TE = 100 ms) disclosed high intensity, and T1-weighted images (TR = 430, TE = 15 ms) exhibited high-intensity area in

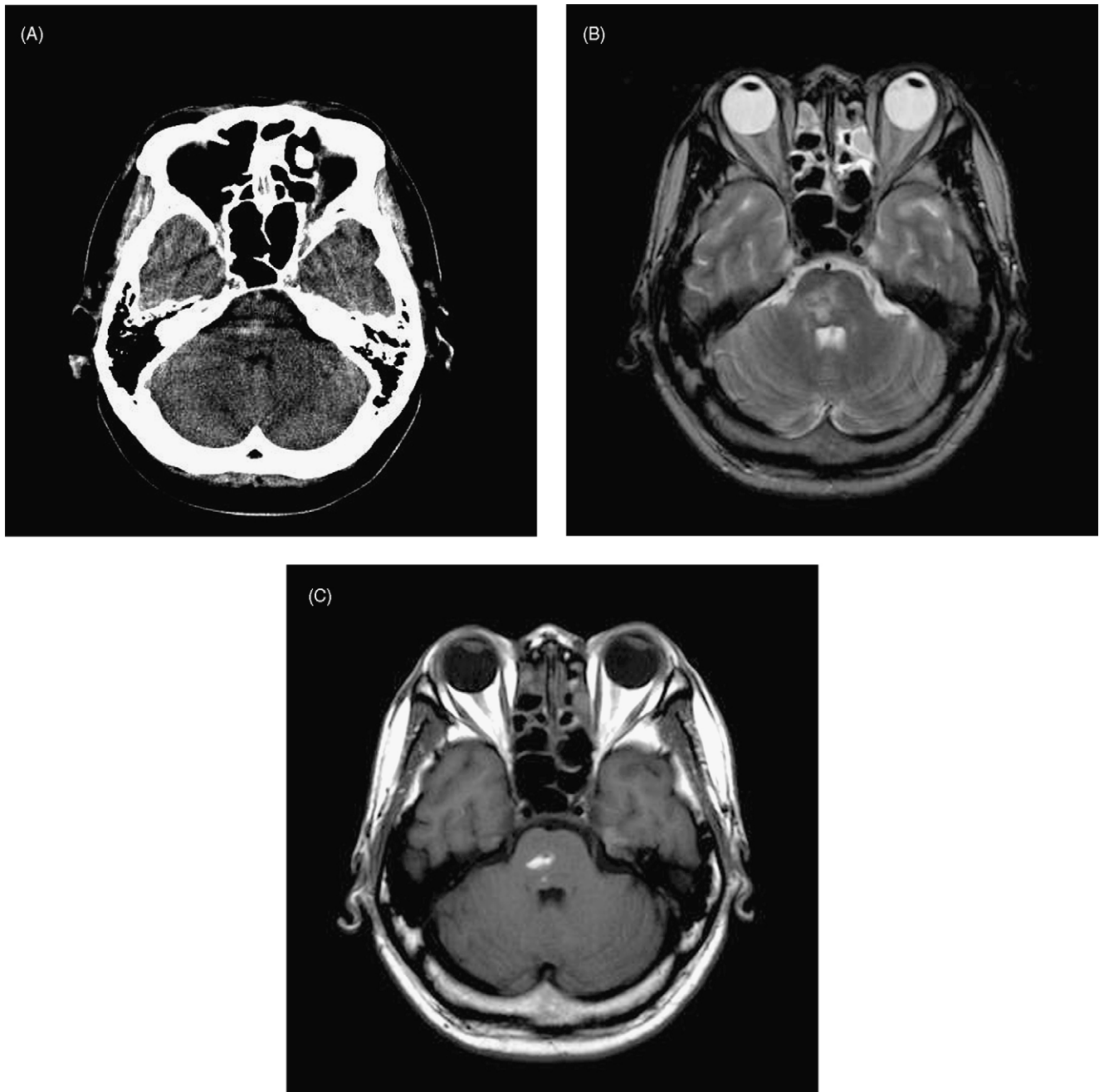


Fig. 2. (A) CT scan in Case 2 showing localized high-density area in the right tegmentum of the pons. (B and C) Both T2- and T1-weighted MRI showing high-intensity area in the right tegmentum of the pons.

the right tegmentum of the pons (Fig. 2). Hypesthesia and paraesthesia disappeared in the leg, perioral and hand, respectively, after 1 year.

3. Discussion

Cheiro-oral syndrome is a sensory disturbance seen around the corner of the mouth and in the palm on the same side, and responsible lesion causing this syndrome are in the parietal lobe [3], a limited lesion in the inferior medial por-

tion of the ventral posterolateral nucleus and lateral portion of the ventral posteromedial nucleus of the thalamus [4–6] and brainstem [7–9]. Thus, cheiro-oral syndrome can be largely explained by the closeness of the sensory fibers from the hand and mouth in any level of the parietal lobe, thalamus and brainstem.

Our cases showed hypesthesia and paraesthesia in the perioral, hand and leg on the same side. This kind of sensory disturbance is thus called cheiro-oral-pedal syndrome and lacunar infarction is the most frequent cause of cheiro-oral-pedal syndrome, and this lacunar syndrome is an infrequent

and partial form of the classic sensory stroke [10,11]. Brainstem hematoma can cause cheiro-oral-pedal syndrome, too [1,2]. In the literature, three cases of cheiro-oral-pedal syndrome following pontine hemorrhage have been reported. In addition to specific sensory impairment, hemiparesis or ataxia were presented. However, our patients did not show hemiparesis and ataxia.

The responsible regions are considered to be the medial lemniscus and trigeminal lemniscus. Absence of pain, temperature disturbance and neuroimaging studies support these regions. In the medial lemniscus, the sensory fibers from the arm, trunk and leg are located from the medial to lateral side in the small area of the lemniscus [12], but these topographies are just the inference from the topography of the ventral posteromedial nucleus and the dorsal column.

Cheiro-oral-pedal-syndrome can be largely explained by the closeness of the sensory fibers among mouth, acral parts and trunk. On the other side, there is a threshold among these. Our case supports that there is a threshold because of the absence of the hypesthesia and paraesthesia in the trunk. Furthermore, our cases have recovered from the leg but the hand still remained. Compared with hand and leg, Yasuda et al. [1] reported that paraesthesia in the lower leg disappeared within 2 weeks, but the distal forearm did not improve. This explanation is compatible with our cases in respect to sensory recovery. Yasuda et al. reported sensory disturbance in the trunk in addition to cheiro-oral or cheiro-oral-pedal syndrome; however, both our cases had no sensory impairment in the trunk.

Case 1 disclosed the first case that midbrain hematoma exhibits this syndrome. In addition, Case 1 shows cheiro-oral-pedal syndrome plus partial involvement of third nerve palsy, not internuclear ophthalmoparesis. Tawara et al. [8] reported cheiro-oral-pedal syndrome with medial longitudinal fasciculus syndrome. Ocular signs may be valuable for the

considering the responsible lesions. Arboix and Thomas [13] reported that cheiro-oral-pedal syndrome was caused by a lacunar infarction in 88% patients. However, it should be kept in mind that brainstem hematomas can cause cheiro-oral-pedal syndrome.

References

- [1] Yasuda Y, Morita T, Okada T, Seko S, Akiguchi I, Kimura J. Cheiro-oral-pedal syndrome. *Eur Neurol* 1992;32:106–8.
- [2] Kim JS. Restricted acral sensory syndrome following minor stroke. *Stroke* 1994;25:2497–502.
- [3] Sittig O. Klinische Beiträge zur Lehre von der Lokalisation der sensiblen Rindenzentren. *Prag Med Wochenschr* 1914;45:548–50.
- [4] Garcin R, Lapresle J. Syndrome sensitive de type thalamique et à topographie chéiro-oral par lésion localisée du thalamus. *Rev Neurol (Paris)* 1954;103:474–81.
- [5] Garcin R, Lapresle J. Deuxième observation personnelle de syndrome sensitive de type thalamique et à topographie chéiro-oral par lésion localisée du thalamus. *Rev Neurol (Paris)* 1960;103:474–81.
- [6] Strauss H. Über Sensibilitätsstörungen an Hand und Gesicht, Geschmacksstörungen und ihre lokalisatorische Bedeutung. *Monatsschr Psychiatr Neurol* 1925;58:265–76.
- [7] Ono S, Inoue K. Cheiro-oral syndrome following midbrain hemorrhage. *J Neurol* 1985;232:304–6.
- [8] Tawara S, Terano A, Araki S, Shirabe T. Unilateral MLF syndrome with palm-oral sensory disturbance: report of a case. *Clin Neurol (Tokyo)* 1974;14:745–51.
- [9] Yasuda Y, Akiguchi I, Ishikawa M, Kameyama M. Bilateral cheiro-oral syndrome following pontine haemorrhage. *J Neurol* 1988;235:489–90.
- [10] Fisher CM. Pure sensory stroke and allied conditions. *Stroke* 1982;13:434–47.
- [11] Iwasaki Y, Kinoshita M, Ikeda K, Takamiya K, Shiojima T. Pure sensory stroke and cheiro-oral syndrome. *J Neurol* 1989;236:186–7.
- [12] Brodal A. The somatic afferent pathways. In: *Neurological anatomy*. New York: Oxford University Press; 1981. p. 46–147.
- [13] Arboix A, Thomas J. Clinical study of 17 patients with cheiro-oral-pedal syndrome. *Med Clin (Barc)* 2002;118:180–2.