

# **Hyperperfusion Syndrome After Clipping of an Unruptured Aneurysm**

## **—Case Report—**

Kazuhiko KUROKI, Haruyoshi TAGUCHI, and Osamu YUKAWA

*Department of Neurosurgery, Hiroshima General Hospital, Hatsukaichi, Hiroshima*

### **Abstract**

**A 41-year-old man developed hyperperfusion 24 hours after undergoing successful clipping surgery for an unruptured middle cerebral artery aneurysm with temporary occlusion for 7 minutes. The patient exhibited motor aphasia 24 hours after surgery. Single photon emission computed tomography revealed hyperperfusion. The patient was sedated for 72 hours using propofol, and his symptoms gradually resolved. He returned to his previous job 2 months after surgery. Hyperperfusion syndrome is possible following any aneurysm surgery, including surgery for unruptured aneurysms using the temporary occlusion technique.**

Key words: hyperperfusion, clipping, aneurysm, single photon emission computed tomography

### **Introduction**

Hyperperfusion is thought to be caused by an acute excessive increase in cerebral blood flow (CBF) into an area of previous hypoperfusion. Hypoperfusion in the cerebral tissue causes the microvessels to become maximally dilated to restore flow, and chronic dilation causes organic disorders and dysautoregulation. If CBF with normal perfusion pressure is suddenly restored to this area by vascular reconstruction, the dilated microvessels cannot constrict sufficiently quickly, resulting in an uncontrollable increase in cerebral blood perfusion. Hyperperfusion then progresses to cerebral edema and intracerebral hemorrhage through the disordered blood-brain barrier.<sup>4-6)</sup> Therefore, hyperperfusion syndrome occurs against a background of metabolic acidosis as a result of brain hypoxia accompanied by diminished or absent autoregulation. Hyperperfusion is known to occur after carotid endarterectomy, extracranial-intracranial bypass surgery, and percutaneous transluminal angioplasty.<sup>2,7-9)</sup>

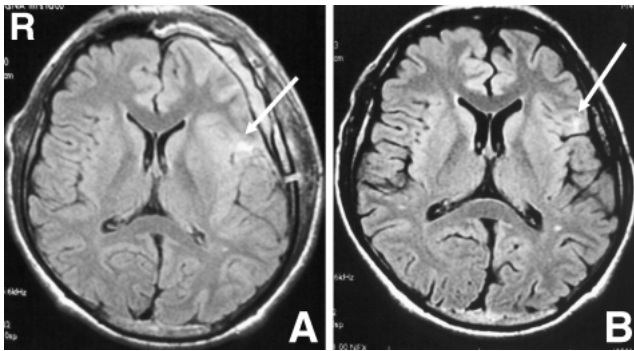
Here we describe a case of hyperperfusion syndrome after clipping of an unruptured small aneurysm.

### **Case Report**

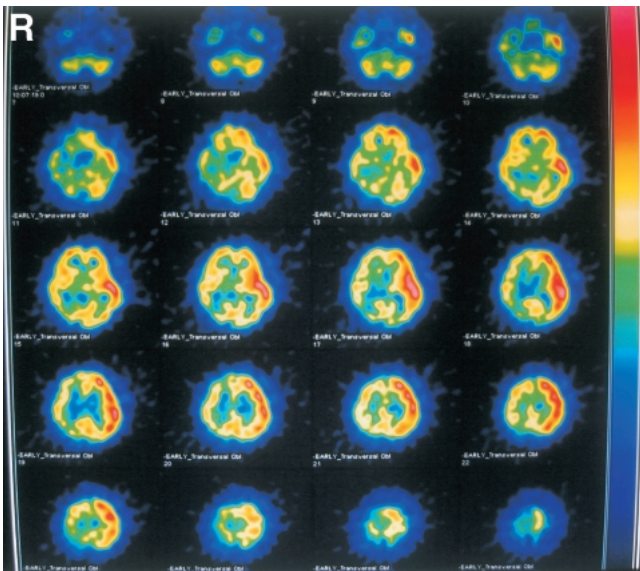
A 41-year-old man was admitted to our hospital for clipping of an unruptured left middle cerebral artery (MCA) aneurysm. He had no remarkable medical history except for acute pancreatitis a few months earlier. Multiple clips were placed to obliterate the aneurysm during temporary MCA occlusion for 7 minutes with the administration of brain protection agents. No neurological deficit occurred during the first 24 hours after surgery, but the patient subsequently exhibited motor aphasia. This symptom was not caused by seizure. There was no abrupt elevation of blood pressure postoperatively.

Computed tomography obtained immediately after the symptom onset revealed neither infarct nor hemorrhage. However, brain infarction was suspected, and hyperbaric oxygen treatment was immediately started. Fluid-attenuated inversion recovery (FLAIR) magnetic resonance (MR) imaging performed 2 days after surgery revealed a high intensity spot lesion in the frontal cortex (Fig. 1A). Iodine-123 N-isopropyl-p-iodoamphetamine single photon emission computed tomography (SPECT) obtained 4 days after surgery demonstrated increased perfusion in the region of the left MCA, and hypoperfusion in the right cerebellar hemisphere, which indicated crossed cerebellar diaschisis (Fig. 2).

The diagnosis was hyperperfusion syndrome and



**Fig. 1** Fluid-attenuated inversion recovery magnetic resonance images showing (A) a faint high intensity lesion in the left frontal region on the day after onset (arrow), and (B) the same finding at 1 year after onset (arrow).



**Fig. 2** Single photon emission computed tomography scans obtained on postoperative day 4 demonstrating increased perfusion in the left hemisphere and decreased blood flow in the right cerebellar hemisphere, suggesting crossed cerebellar diaschisis.

brain infarction therapy was discontinued. The patient was sedated and his blood pressure was maintained under 100 mmHg using propofol for 72 hours. The symptoms gradually improved over a 2-week period and at the time of discharge, 15 days after surgery, the patient had no demonstrable aphasia. He was able to return to his previous job 2 months after surgery. FLAIR MR imaging still

showed the high intensity spot lesion after 1 year (Fig. 1B).

## Discussion

Hyperperfusion has been reported following surgery for giant aneurysm<sup>3)</sup> and for subarachnoid hemorrhage. Hyperperfusion may have been caused by an increase in blood flow distal to the aneurysm after clipping of the giant internal carotid artery aneurysm,<sup>3)</sup> or by post-ischemic reperfusion after temporary clipping for subarachnoid hemorrhage under ischemic circulatory conditions. All of these cases may have had an ischemic background before surgery, whereas the aneurysm in our case was only 5 mm in diameter, and no factors related to brain ischemia were present preoperatively. Therefore, our case of hyperperfusion syndrome was directly associated with the clipping of an unruptured aneurysm.

SPECT revealed increased accumulation in the region of the left MCA and decreased accumulation in the right cerebellar hemisphere. These changes are assumed to reflect crossed cerebellar diaschisis and decreased function of the left cerebellar hemisphere, i.e., hyperperfusion. FLAIR MR imaging revealed a high intensity spot lesion in the frontal cortex, which persisted at 1 year postoperatively. Therefore, hyperperfusion probably occurred in the region of the left MCA and irreversible brain ischemia may have developed in the lesion indicated by FLAIR MR imaging.

The occurrence of brain ischemia following unruptured aneurysm surgery may involve many factors, such as compression by a spatula, damage to venous returns, collateral blood supply, patient age, operative procedure, temporary occlusion of the parent artery, and the effect of anesthetic and other agents. However, only temporary occlusion of the parent artery was apparently related to the hyperperfusion syndrome secondary to brain ischemia in our patient.

Temporary vessel occlusion, which facilitates aneurysm clipping and reduces the risk of premature rupture, is a valuable technique in cerebral aneurysm surgery. However, the procedure must be performed within the permissible time limit to avoid stroke. The total duration and maximum single duration of temporary occlusion during clipping were significant factors in the occurrence of hyperperfusion, which increased markedly in patients undergoing surgery for ruptured aneurysm with total duration of temporary occlusion exceeding 20 minutes.<sup>1)</sup> In our patient, only a single 7-minute temporary occlusion period was used, suggesting a

relatively low risk of ischemia and hyperperfusion syndrome.

The present case suggests that postoperative hyperperfusion syndrome is possible following any aneurysm surgery, including surgery for unruptured aneurysms using the temporary occlusion technique. The symptoms of hyperperfusion syndrome mimic those of brain ischemia, but the treatment for hyperperfusion syndrome is quite different from that for brain ischemia. The precise pathology of hyperperfusion cannot be visualized using MR imaging, but SPECT is useful for the differential diagnosis.

### References

- 1) Araki Y, Andoh H, Yamada M, Nakatani K, Andoh T, Sakai N: Permissible arterial occlusion time in aneurysm surgery: postoperative hyperperfusion caused by temporary clipping. *Neurol Med Chir (Tokyo)* 39: 901-907, 1999
- 2) Gourley JK, Heistad DD: Characteristics of reactive hyperemia in the cerebral circulation. *Am J Physiol* 246: H52-H58, 1984
- 3) Heros RC, Scott RM, Kistler JP, Ackerman RH, Conner ES: Temporary neurological deterioration after extracranial-intracranial bypass. *Neurosurgery* 15: 178-185, 1984
- 4) Lawton MT, Spetzler RF: Surgical strategies for giant intracranial aneurysms. *Acta Neurochir Suppl* 72: 141-156, 1999
- 5) Masaoka H, Klatzo I, Tomida S, Vass K, Wagner HG, Nowak TS Jr: Role of circulatory disturbances in the development of post-ischemic brain edema. *Neurochem Pathol* 9: 21-29, 1988
- 6) Murakami H, Inaba M, Nakamura A, Ushioda T: Ipsilateral hyperperfusion after neck clipping of a giant internal carotid artery aneurysm. *J Neurosurg* 97: 1233-1236, 2002
- 7) Nicholas GG, Hashemi H, Gee W, Reed JF: The cerebral hyperperfusion syndrome: diagnostic value of ocular pneumoplethysmography. *J Vasc Surg* 17: 690-695, 1993
- 8) Reigel MM, Hollier LH, Sundt TM, Piepgras DG, Sharbrough FW, Cherry KJ: Cerebral hyperperfusion syndrome: a cause of neurologic dysfunction after carotid endarterectomy. *J Vasc Surg* 5: 628-634, 1987
- 9) Sbarigia E, Speziale F, Giannoni MF, Colonna M, Panico MA, Fiorani P: Post-carotid endarterectomy hyperperfusion syndrome: preliminary observations for identifying at risk patients by transcranial Doppler sonography and the acetazolamide test. *Eur J Vasc Surg* 7: 252-256, 1993

---

Address reprint requests to: K. Kuroki, M.D., Department of Neurosurgery, Hiroshima General Hospital, 1-3-3 Jigozen, Hatsukaichi, Hiroshima 738-8503, Japan.