

Trilochan Srivastava
Sumit Singh
Vinay Goyal
Garima Shukla
Madhuri Behari

Hemichorea-hemiballism associated with frontoparietal bleed

Received: 10 March 2005
Received in revised form: 16 June 2005
Accepted: 28 June 2005

Sirs: We report a case of hemichorea-hemiballism involving the left upper limb following a frontoparietal bleed. Hemichorea-hemiballism associated with a fronto-parietal lobe bleed has not previously been described in the literature.

A 53-year-old woman presented with sudden onset of involuntary movements of her left upper limb. There were flinging, violent and arrhythmic movements, occurring several times a minute. After 5–7 days, these violent movements subsided in intensity and were replaced by forcible, jerky, dancing-like movement suggestive of choreiform movements. There was no past history of stroke, coronary artery disease, hypertension or diabetes mellitus. Her vital signs were normal including blood pressure. The patient was alert. Cranial nerves including fundus examination were normal. There were no cerebellar signs. Motor power, deep tendon jerks and sensory (primary and cortical) examination were also normal. Non contrast enhanced CT revealed a right frontoparietal hemorrhage with mild edema. No mass effect or midline shift were present (Fig. 1). Since the patient was normotensive with an unusual site of her intracranial bleed, search was made for a cause

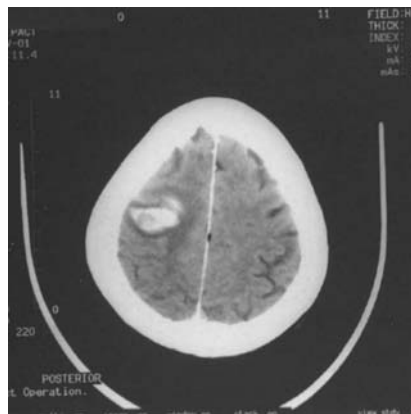


Fig. 1

of hemorrhage. The hemogram, bleeding time, clotting time, prothrombin time and platelet counts were normal. Renal and liver function tests were also normal. Lupus anticoagulant, antiphospholipid antibody and antinuclear antibody were negative. MRI confirmed the presence of hematoma without any evidence of involvement of subthalamus, thalamus or basal ganglia. Digital subtraction angiography (DSA) for cerebral vessels was normal. There was no evidence of venous sinus thrombosis. The patient was managed conservatively and gradually hemiballism resolved within a week and hemichorea appeared which subsided in the next 2 weeks.

Although hemichorea-hemiballism is usually linked to a lesion in the subthalamus, in this case subthalamus, thalamus and basal ganglia were normal and the only lesion was present in the frontoparietal lobe. Hemichorea-hemiballism due to parietal lobe involvement has been described, but it is extremely rare [3, 5]. Mizushima et al. described a case of hemichorea-hemiballism associated with parietal lobe infarction [4]. In another case hemiballism-hemichorea developed post-operatively in a 28-year-old man with meningioma in his right parasagit-

tal parietal lobe [6]. CT immediately after surgery revealed a small hematoma in the tumor bed without any additional lesion in thalamus or basal ganglion. A pure cortical infarction sparing the basal ganglion seldom produces hemichorea-hemiballism. Schwarz and Barrows speculated that interruption of neural circuits from some part of the frontal or parietal cortex to caudate nucleus and putamen as the possible mechanism for hemiballism [5]. Hemiballism following left frontal lobe infarction was reported by Martin who suggested that ischemia of a cerebral hemisphere affected the basal ganglion and hence produced hemiballism [3]. An extensive literature search did not show hemichorea-hemiballism due to fronto-parietal lobe bleed. It has been suggested that a lesion of the subthalamic nucleus (STN) reduces striato-pallidal inhibitory influences leading to reduced excitatory projections from the STN to pars interna of globus pallidus, which in turn disinhibits thalamus and cortex resulting in hyperkinetic movements [1]. The somatosensory cortex also projects to the putamen and may influence this basal ganglion circuit [2]. It is believed that the parietal lobe, especially Brodmann's area 7, may be one of the areas inducing hemiballism [6]. We propose that these abnormal movements may occur if the basal ganglion-thalamo-cortical circuit is affected anywhere, as in this case it was in the fronto-parietal lobe.

References

1. Alexander GE, Crutcher MD (1990) Functional architecture of basal ganglion circuit: neural substrates of parallel processing. *Trends Neurosci* 14: 55–59
2. Delong MR (1990) Primates model of movement disorders of basal ganglia origin. *Trends Neurosci* 13:281–285

-
3. Martin JP (1957) Hemichorea (hemiballism) without lesion in corpus luisii. *Brain* 80:1–10
 4. Mizushima N, Park-Matsumoto YC, Amakawa T, Hayashi H (1997) A case of hemichorea-hemiballism associated with parietal lobe infarction. *Eur Neurol* 37(1):65–66
 5. Schwarz GA, Barrows LJ (1960) Hemiballism without involvement of Luys'body. *Arch Neurol* 2:420–434
 6. Takeshita T, Hamada Y, Fukui M (1993) Hemiballistic involuntary movements as a parietal lobe syndrome. *Fukoka Igaku Zasshi* 84(8):374–376
 7. Martin JP (1957) Hemichorea (hemiballism) without lesion in corpus luisii. *Brain* 80:1–10
- T. Srivastava (✉) · S. Singh · V. Goyal · G. Shukla · M. Behari
Dept. of Neurology
All India Institute of Medical Sciences
New Delhi 110029, India
Tel.: +91-11/26594210
Fax: +91-11/26588663
E-Mail: trilochan_9@yahoo.co.in