

Pedro Vilela  
Augusto Goulão

## Paediatric dissecting posterior cerebral aneurysms: report of two cases and review of the literature

Received: 14 November 2005  
Accepted: 7 March 2006  
Published online: 20 June 2006  
© Springer-Verlag 2006

P. Vilela (✉) · A. Goulão  
Neuroradiology Department,  
Garcia de Orta Hospital,  
Av. Prof. Torrado Silva, Pragal,  
2801-591 Almada, Portugal  
e-mail: ferrovilela@hotmail.com  
Tel.: +351-212948080  
Fax: +351-212726860

**Abstract** *Introduction:* Intracranial aneurysms in the paediatric population are uncommon, accounting for 2% to 6% of all aneurysms, and spontaneous arterial dissection is rarely reported as the cause of aneurysms in children, especially in the posterior cerebral artery. *Methods:* Two cases of paediatric spontaneous posterior cerebral artery dissecting aneurysms are reported, one in a 33-month-old male child presenting with aneurysmal rupture and subarachnoid haemorrhage and the other in a 9-year-old boy with an unruptured aneurysm. *Results:*

The first child was successfully treated by endovascular parent vessel occlusion without neurological deficit and in the second a spontaneous thrombo-

sis of the aneurysm and its parent artery occurred associated with hydrocephalus and a favourable outcome. *Conclusion:* Dissecting aneurysms are dynamic lesions with variable and unpredictable evolution and close follow-up and/or early treatment is warranted. Spontaneous arterial dissection is a rare, probably still under-recognized, cause of intracranial aneurysms that may be responsible for a significant number of aneurysms and spontaneous aneurysmal thromboses in children.

**Keywords** Aneurysm · Posterior cerebral artery · Dissection · Children · Spontaneous thrombosis · Embolization

### Introduction

Paediatric aneurysms are rare, accounting for 2% to 6% of all aneurysms and have distinct characteristics from the aneurysms found in adult population [1–4]. In children, aneurysms have a male predominance and are more commonly located in the carotid bifurcation and posterior circulation, there is a higher incidence of large and giant aneurysms and spontaneous thrombosis of aneurysms is more common [1–11]. In more than half of the paediatric aneurysms there is an underlying disorder predisposing to aneurysmal formation such as infection, trauma, tumour or dissection [1–11].

Paediatric arterial dissections account for 7% of all dissections [12] but represent an important cause of ischaemic stroke in this age group, being the most frequent

cause of stroke in the posterior circulation [13]. The most common arterial dissection location in children is the carotid artery territory in which they are more frequently intradural, and mostly located in the supraclinoid internal carotid artery (ICA) and middle cerebral artery (MCA). [12, 14, 15]. In contrast, posterior circulation dissections are rarely intracranial, being reported in only 4% of cases [14]. Subarachnoid haemorrhage is a rare mode of presentation for dissections in children, accounting for less than 2% of cases [14].

Spontaneous dissections have been rarely reported as a cause of posterior cerebral artery (PCA) aneurysms in the paediatric population [4, 14, 16]. We report here two cases of paediatric spontaneous dissecting aneurysm, including the documentation of aneurysm development, and review the literature on posterior cerebral dissecting aneurysms in this age group.

## Case report

### Patient 1

After a regular night's sleep, this 33-month-old male child awakened with a sudden and strong headache followed by vomiting and loss of consciousness. The child had been otherwise healthy and there was no history of previous trauma. There was no family history of congenital neurological or vascular disease.

During transportation to the hospital, the patient had two generalized seizures and was medicated with two 5 mg diazepam suppositories. He was admitted to the emergency department and on examination he was only responsive to pain stimulation, localizing the pain, had anisocoria with right dilated pupil, right flaccid hemiparesis and irregular ventilation with periods of inspiratory pauses. The patient was sedated and kept on anticonvulsive therapy and ventilation.

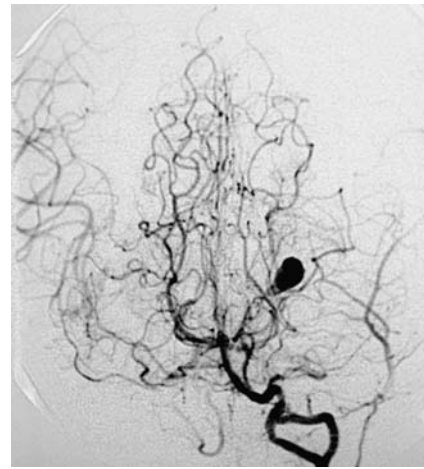
The CT performed showed diffuse subarachnoidal and intraventricular haemorrhage with acute hydrocephalus. The patient was taken immediately to the operating room and a ventricular shunt was placed. Afterwards, an angio-CT was done showing a left posterior P2 cerebral aneurysm. During the hospitalization the patient recovered gradually, was extubated on day 6, and remained only with a mild right hemiparesis (grade 2).

The patient had been admitted to a different hospital from ours and was referred to us after clinical stabilization.

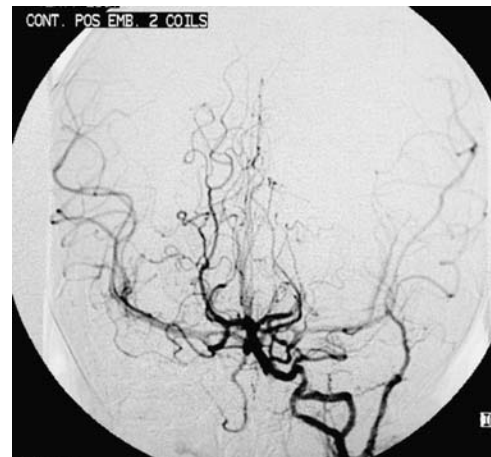We scheduled the patient for immediate embolization that was performed under general anaesthesia and full heparinization. A 5F sheath was placed on the right femoral artery and a 5F guiding catheter was advanced. The diagnostic cerebral angiogram revealed a dissecting P2 aneurysm with a proximal stenosis and aneurysmal contrast agent stagnation (Fig. 1). The posterior communicating arteries were prominent and filled the PCA territories. The guiding catheter was placed in the proximal V2 left vertebral artery segment and a microcatheter was advanced into the left PCA P2 segment. Two bare coils (2D 3×4 mm and 2×2 mm) were placed in the aneurysm and parent artery covering the stenotic segment, achieving P2 PCA occlusion proximal to the stenosis. The control angiogram confirmed the PCA occlusion with neither antegrade nor retrograde aneurysmal filling (Fig. 2). The carotid angiogram showed the opening of leptomeningeal MCA-PCA anastomosis filling the distal PCA territory.

The patient tolerated the procedure well and there were no new clinical deficits, including visual field defect. MRI/MRA performed 3 days after the procedure showed the thrombosis of the aneurysmal sac and the absence of a PCA territory infarct.

The final follow-up MRI/MRA was performed 18 months after the treatment and confirmed the disappearance of the aneurysm and the presence of excellent collateral arterial circulation.



**Fig. 1** Digital subtraction angiography: left vertebral angiogram late arterial phase reveals a dissecting P2 aneurysm with contrast agent stagnation inside. Note the presence of a normal arterial variation of the left vertebral artery: intradural duplication of the vertebral artery at C1–C2



**Fig. 2** Post-treatment (embolization) control angiogram confirming the PCA occlusion and aneurysm exclusion

### Patient 2

This 9-year-old boy had been followed since the age of 11 months in a paediatric neurology clinic for developmental delay and epilepsy. Except for the age of the mother (41 years), the pregnancy and birth were uneventful. There was no family history of neurological or vascular diseases and the child had a healthy older brother. The initial clinical and laboratory search for metabolic and genetic disorders was negative. The patient was under anticonvulsive therapy (sodium valproate) and had sporadic seizures.

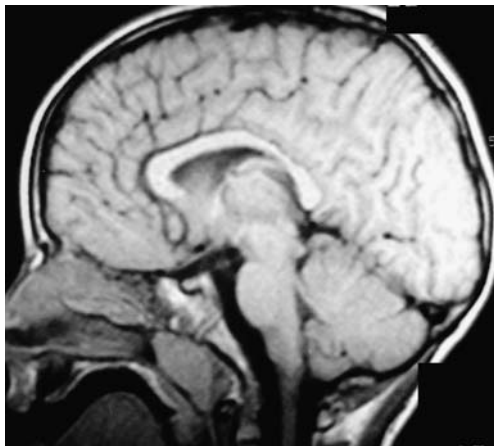
An MRI performed at the age of 7 years was normal (Fig. 3). Although, the patient had been clinically stable, with moderate developmental delay and sporadic seizures, an MRI was repeated at the age of 9 years. This MRI/MRA

depicted a partially thrombosed aneurysm of the right PCA P2 segment (Fig. 4) neither related with a branching point nor having a saccular appearance, suggestive of a spontaneous dissecting aneurysm. There was no recent history of trauma, seizures or any modification of the patient's clinical status.

The patient was referred to our endovascular clinic and scheduled for elective diagnostic angiography and embolization.

In the intervening time, there was a gradual change in the patient's clinical status, characterized by sleepiness, gait disturbance, headache and, finally, vomiting. The child was taken to our emergency department and on examination he was somnolent but responded to verbal orders, had bilateral papilloedema and gait disequilibrium. The CT performed on admission showed acute hydrocephalus caused by quadrigeminal plate compression caused by an enlarged, spontaneously hyperdense (thrombosed) aneurysm, with no signs of intracranial haemorrhage. The patient was taken immediately to the operating room to place a ventricular shunt. The MRI confirmed the quadrigeminal plate compression by the enlarged thrombosed aneurysm (Fig. 5) and the absence of ischaemic infarct on the PCA territory. The patient was submitted to a diagnostic angiogram that confirmed the total spontaneous thrombosis of the dissecting aneurysm with PCA occlusion just proximal to the aneurysm (Fig. 6). It also showed the presence of good collateral circulation through leptomeningeal PCA–MCA anastomosis. The patient gradually recovered to his pre-morbid clinical status and was discharged 2 weeks after admission.

The patient was followed clinically without any interval changes and by imaging. An angiogram acquired 2 months after the first angiogram showed the stability of the aneurysmal spontaneous thrombosis and a final follow-up study at 18 months was done by MRI/MRA and confirmed the disappearance of the aneurysm and the absence of hydrocephalus and brain lesions.



**Fig. 3** Sagittal T1-W SE MR image showing a normal-appearing quadrigeminal cistern and neighbouring brain structures

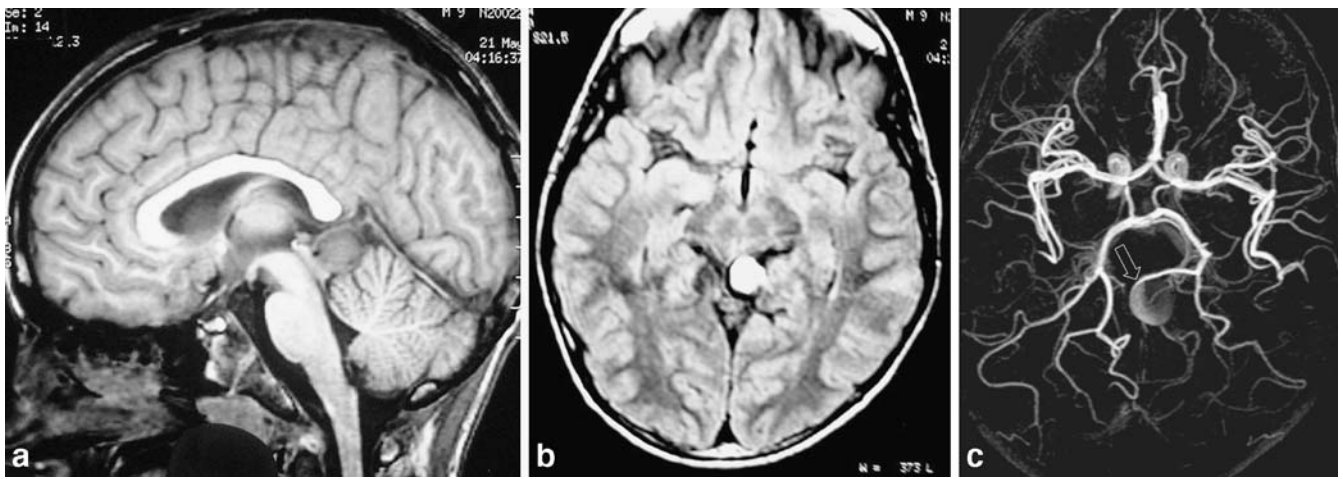
## Discussion

Intracranial dissecting aneurysms have been reported with increasing frequency in recent years probably due to a higher awareness of the disease and to more accurate diagnostic imaging methods. However, the diagnosis of intracranial arterial dissection is still often difficult and the imaging signs are subtle. The most common angiographic signs are the “pearl and string” sign, meaning an aneurysmal dilation preceding or following a stenosis, the “string” sign, signifying an arterial stenosis or occlusion, and the fusiform or saccular aneurysmal dilation with stagnation of contrast agent inside [17–21]. Other less common signs include the double lumen and the intimal flap [17–21]. Repeated follow-up angiography may show different imaging signs, due to the fast morphological evolution of these lesions [21]. In adults it may be difficult to distinguish an arterial dissection from an atherosclerotic lesion [17, 20, 22] or from a saccular aneurysm with concomitant vasospasm, which is generally diffuse and delayed in onset after the bleeding [20, 23]. Moreover, the differentiation between intraluminal and mural thrombosis based only on imaging methods may be also troublesome. Nonetheless, whenever there is an aneurysm associated with proximal or distal parent vessel stenosis and/or with stagnation of contrast agent inside, the diagnosis of dissecting aneurysm should be considered [24].

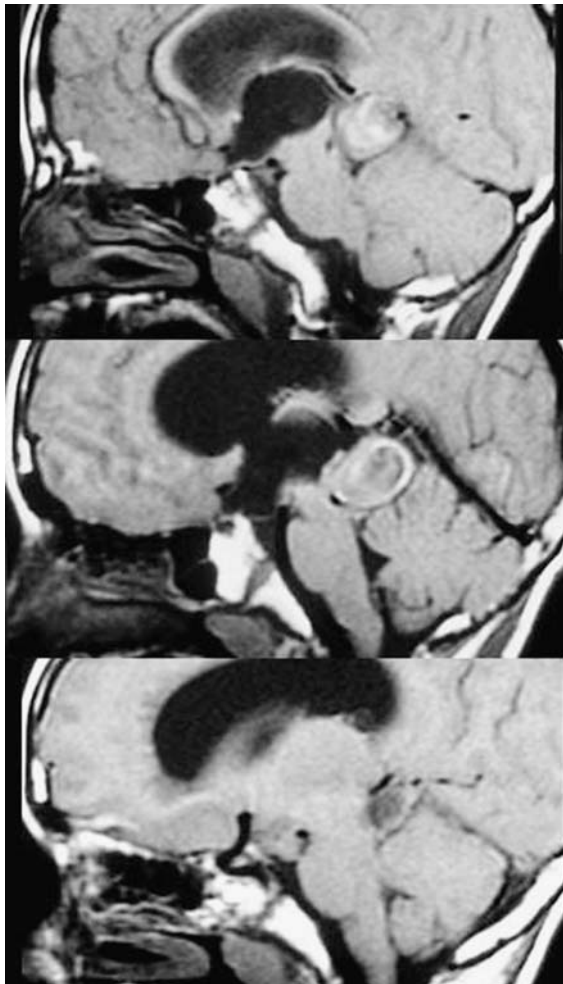
In series of paediatric aneurysms reported by Patel and Richardson [7], Amacher et al. [25] and Storrs et al. [26], there is no mention of spontaneous dissecting aneurysms, in contrast to traumatic aneurysms that have always been a frequently recognized type of aneurysm in children. In more recent series, spontaneous dissection has been inconsistently pointed out as a cause of paediatric aneurysms. Allison et al. [11], in 1998, reviewing a series of patients over a period of 20 years, made no mention of spontaneous dissecting aneurysms. In a paediatric aneurysm series from the Hospital for Sick Children in Toronto [16] there was at least one dissecting aneurysm and, more recently, in a paediatric aneurysm series from the Bicêtre Hospital in Paris spontaneous intradural dissecting aneurysms accounted for up to 45% of all paediatric aneurysms. However, in the latter series a more broad definition of dissecting aneurysms was used including not only acute but also subacute and chronic dissecting aneurysms such as fusiform aneurysms and partially thrombosed aneurysms [4].

In general, PCA aneurysms are rare, accounting for 0.8–1.4% of all aneurysms [9, 27, 28], and 12% of these aneurysms occur in the paediatric age group [27]. Indeed, if one considers that the underlying aetiology of PCA fusiform aneurysms may be the same as that proposed for spontaneous fusiform MCA aneurysms and they may therefore correspond to chronic dissecting lesions [4, 29], some of these reported PCA aneurysms [27, 28, 30–32] may have corresponded to dissecting aneurysms. Paediatric spontaneous dissecting PCA aneurysms are extremely rare,

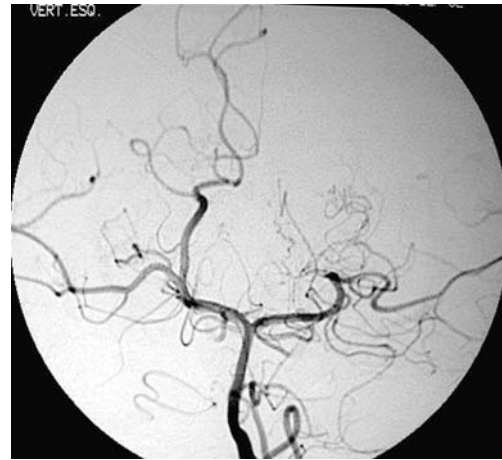



**Fig. 4** a, b Sagittal T1-W SE (a) and axial PD FSE (b) MR images reveal the development of PCA aneurysm. c MRA 3D TOF, MIP axial reconstruction shows the distal PCA (P2 segment) aneurysm with a focal proximal arterial narrowing (*open arrow*)



**Fig. 5** Sagittal T1-W SE MR image reveals spontaneous thrombosis of the PCA aneurysm that caused aneurysmal enlargement, compression of the tectal plate and acute hydrocephalus



**Fig. 6** Digital subtraction angiography: left vertebral angiogram late arterial phase reveals the spontaneous thrombosis of the PCA aneurysm associated with thrombosis of the parent artery just proximal to the aneurysm

being less commonly described than traumatic dissecting aneurysms, and, to the best of our knowledge, there are only three case reports of spontaneous dissecting PCA aneurysms in the literature [4, 14, 16], two presenting with subarachnoid haemorrhage [4, 14] and one with ischaemic stroke [16].

Vertebrobasilar dissections are more frequently extracranial [12, 14, 21, 27–35]. The intradural dissections more commonly affect the vertebral or the basilar arteries that are also the most common locations for dissecting aneurysms of the posterior circulation [12, 14, 21, 27–35]. Trauma is the most common predisposing factor to extracranial and intracranial dissecting aneurysms in the vertebrobasilar territory [8, 21, 36, 37].

The natural history of intracranial dissections remains poorly understood. The dynamic nature of this disease, reflecting injury and healing processes during a period of

time that may last for several months after the initial insult, may lead to distinct outcomes. The cases reported here illustrate two different evolutions of similar PCA aneurysms: spontaneous thrombosis and haemorrhage. Spontaneous disappearance of aneurysms is common in children and its occurrence is unpredictable [1, 2, 4]. It is estimated to occur in 1–2% of saccular aneurysms [38–43], more commonly in large or giant aneurysms [44], being associated with complete thrombosis of the parent vessel in up to 38% of cases [38, 40, 44]. Spontaneous thrombosis has also been reported in traumatic [45, 46] and in dissecting aneurysms [4, 23, 40, 44, 47–49]. In paediatric dissecting aneurysms spontaneous thrombosis is not uncommon and it may occur in up to 28% of cases [4]. The mechanisms responsible for spontaneous thrombosis and the imaging features that could point to such evolution remain obscure. A high ratio of aneurysm sac volume to neck size may be the cause of a low aneurysmal blood inflow that may promote the spontaneous thrombosis of aneurysms [50]. The associated proximal parent artery stenosis, that reduces the inflow and causes blood stagnation inside the aneurysm, may facilitate aneurysmal thrombosis. The dissection progression/recurrence causing proximal artery occlusion or parent artery compression by enlarging the aneurysm can also be responsible for spontaneous thrombosis of dissecting aneurysms.

Ruptured intracranial dissections carry an ominous prognosis and warrant early active treatment. In the paediatric population dissecting aneurysms have a worse prognosis than saccular aneurysms [4]. Dissecting aneurysms have an extremely high rebleeding rate, estimated to be in the range 30–58%, occurring during the acute phase, mostly in the first 24 h, with an associated high mortality rate [24, 51–56]. In contrast, unruptured intracranial dissections have a high recovery potential, including the possibility for spontaneous resolution [20, 23, 38, 39, 57], and can be managed conservatively, the exceptions being the presence of a large symptomatic aneurysmal dilation, aneurysmal enlargement in the follow up studies, and progression of the dissection [20, 23, 38, 39, 57].

There is no evidence that paediatric intracranial dissections will behave differently from those in adults. For unruptured lesions, conservative measures include bed rest and blood pressure control [19]. Antiplatelet or anticoagulant therapy is controversial and may be offered to patients harbouring unruptured stenotic or occlusive lesions without aneurysmal dilation [22]. Although still controversial, conservative treatment has also been advocated for stenotic ruptured intracranial dissections without aneurysmal dilation or the “pearl and string” sign since a significant number of these cases, up to 44%, have a favourable outcome under conservative treatment [56].

Endovascular treatment is a valuable treatment option for intracranial dissecting aneurysms [17] with lower mortality and morbidity than surgery [19, 56]. Intracranial dissecting aneurysms have been treated by parent vessel

occlusion and by aneurysmal coiling with or without stent placement [17]. Distal PCA aneurysm surgery has had distinct reported outcomes [33, 58], but is generally associated with high surgical risk [19, 53, 58–65], and the endovascular approach has been suggested for these surgically challenging cases [66]. Some authors have reported successful PCA dissecting aneurysmal embolization with coiling of the aneurysmal false sac and preservation of the parent artery [37]. We have generally favoured an urgent endovascular deconstructive approach, in view of the fact that the wall of these aneurysms is weak and may easily rupture during coiling. We occlude the PCA with endovascular coil deposition at the lesion, avoiding packing the dissecting aneurysm sac, and just proximal to the aneurysm in order to prevent incomplete thrombosis of the aneurysm. However, if there is significant associated arterial vasospasm we delay the treatment and if there is a known underlying arterial disease predisposing for arterial dissection and recurrence, the management should favour a constructive approach.

There are some anatomic considerations that may predict the probability of neurological deficit after a deconstructive approach to PCA aneurysms. A balloon occlusion tolerance test is the best method to access the outcome of parent vessel occlusion. However, in children this clinical evaluation is not feasible and the physiological evaluation, such as EEG monitoring, may not be entirely reliable. Therefore, a correct anatomic analysis may allow the risk estimation according to the segment of PCA occlusion. The neurological deficit after PCA surgical and endovascular occlusion ranges from 0% to 17% [37, 67–70]. It is important to differentiate the deficit resulting from occlusion of the perforators from that ensuing from the reduced antegrade PCA blood flow. Generally, providing that great care is taken to preserve the central perforator branches, namely those that irrigate the thalamus and midbrain, PCA occlusion beyond the origin of the posterior (inferior) temporal branch is associated with a low morbidity rate [37, 47, 67–71]. According to the anatomic PCA division of Zeal and Rhoton [72], from the P2a segment originate the thalamogeniculate and hippocampal arteries and from the P2b segment arise the medial anterior and lateral posterior choroidal arteries. Distal to these segments, there is a rich cortical leptomeningeal anastomosis between the splenic artery and the posterior pericallosal branch of the anterior cerebral artery, and between the inferior temporal artery and the superior temporal branches of the MCA. These anastomoses may overcome the proximal PCA occlusion. These anastomoses are expected to be well functioning in children without an underlying occlusive vasculopathy.

Finally, there are anecdotal reports of recanalization of thrombosed aneurysms [73–78] and of rebleeding after proximal artery occlusion [19, 60] indicating that there is a need for follow-up studies to ensure definitive aneurysmal thrombosis.

## Conclusions

Spontaneous arterial dissection is a rare, probably still under recognized, cause of intracranial aneurysms. Dissecting aneurysms may be responsible for a significant number of the spontaneous aneurysmal thrombosis in children. Dissecting aneurysms are dynamic lesions with variable and unpredictable evolution and close follow-up

and/or early treatment is warranted. The natural history in children needs to be further elucidated but according to the present knowledge, these lesions should be managed in the same manner as dissecting aneurysms in adults.

**Conflict of interest statement.** We declare that we have no conflict of interest.

## References

1. Lasjaunias P (ed) (1997) Vascular diseases in neonates, infants and children. Springer, Berlin Heidelberg New York, pp 373–392
2. McDonald PJ, Wallace MC (2003) Pediatric intracranial aneurysms. In: Leroux P, Winn HR, Newell D (eds) Management of cerebral aneurysms. Saunders, Philadelphia, pp 357–362
3. Huang J, McGirt M, Gailloud P, Tamargo R (2005) Intracranial aneurysms in the pediatric population: case series and literature review. *Surg Neurol* 63:424–433
4. Lasjaunias P, Wuppalapati S, Alvarez H et al (2005) Intracranial aneurysms in children aged under 15 years: review of 59 consecutive children with 75 aneurysms. *Childs Nerv Syst* 21: 437–450
5. Ostergaard JR, Voldby B (1983) Intracranial arterial aneurysms in children and adolescents. *J Neurosurg* 58 (6):832–837
6. Meyer FB, Sundt TM Jr, Fode NC, Morgan MK, Forbes GS, Mellinger JF (1989) Cerebral aneurysms in childhood and adolescence. *J Neurosurg* 70 (3):420–425
7. Patel AN, Richardson AE (1971) Ruptured intracranial aneurysms in the first two decades of life. A study of 58 patients. *J Neurosurg* 35(5):571–576
8. Putty TK, Luerssen TG, Campbell RL, Boaz JC, Edwards MK (1990–1991) Magnetic resonance imaging diagnosis of a cerebral aneurysm in an infant. Case report and review of the literature. *Pediatr Neurosurg* 16:48–51
9. Locksley HB, Sahs AL, Knowler L (1966) Report on the cooperative study of intracranial aneurysms and subarachnoid hemorrhage. Section V, part I. natural history of subarachnoid hemorrhage, intracranial aneurysms and arteriovenous malformations. Based on 6368 cases in the cooperative study. *J Neurosurg* 25:219–239
10. Weir BK, Macdonald RL (1996) Intracranial aneurysms and subarachnoid hemorrhage: an overview. In: Wilkins RR, Rengachary SA (eds) *Neurosurgery*. New York, McGraw-Hill, pp 2191–2213
11. Allison JW, Davis PC, Sato Y, James CA, Haque SS, Angtuaco EJ, Glasier CM (1998) Intracranial aneurysms in infants and children. *Pediatr Radiol* 28 (4):223–229
12. Schievink WI, Mokri B, Piepgras DG (1994) Spontaneous dissections of cervicocephalic arteries in childhood and adolescence. *Neurology* 44(9): 1607–1612
13. Ganesan V, Chong WK, Cox TC, Chawda SJ, Prengler M, Kirkham FJ (2002) Posterior circulation stroke in childhood: risk factors and recurrence. *Neurology* 59(10):1552–1556
14. Fullerton HJ, Johnston SC, Smith WS (2001) Arterial dissection and stroke in children. *Neurology* 57(7):1155–1160
15. Vilela P, Goulão A (2003) Cervical and intracranial arterial dissection: review of the acute clinical presentation and imaging of 48 cases. *Acta Med Port* 16 (3):155–164
16. Laughlin S, terBrugge K, Willinsky R et al (1997) Endovascular management of pediatric aneurysms. *Intervent Neuroradiol* 3:205–214
17. Berenstein A, Lasjaunias P, terBrugge K (eds) (2001) *Surgical neuroangiography: clinical and endovascular treatment aspects in adults*. Springer, Berlin Heidelberg New York, pp 365–564
18. Sasaki O, Koizumi T, Ito Y, Sorimachi T, Koike T, Tanaka R (1992) Dissecting aneurysm of the posterior cerebral artery treated with proximal ligation. *Surg Neurol* 37(5):394–401
19. Kitanaka C, Tanaka J, Kuwahara M, Teraoka A, Sasaki T, Takakura K, Tanaki J (1994) Nonsurgical treatment of unruptured intracranial vertebral artery dissection with serial follow-up angiography. *J Neurosurg* 80(4): 667–674
20. Hosoya T, Adachi M, Yamaguchi K, Haku T, Kayama T, Kato T (1999) Clinical and neuroradiology features of intracranial vertebrobasilar dissection. *Stroke* 30:1083–1090
21. Massimi L, Moret J, Tamburrini G, Di Rocco C (2003) Dissecting giant vertebral-basilar aneurysms. *Childs Nerv Syst* 19(4):204–210
22. Naito I, Iwai T, Sasaki T (2002) Management of intracranial vertebral artery dissections initially presenting without subarachnoid hemorrhage. *Neurosurgery* 51(4):930–937
23. Pozzati E, Padovani R, Fabrizi A, Sabattini L, Gaist G (1991) Benign arterial dissections of the posterior circulation. *J Neurosurg* 75(1):69–72
24. Nakatomi H, Nagata K, Kawamoto S, Shiokawa Y (1997) Ruptured dissecting aneurysm as a cause of subarachnoid hemorrhage of unverified etiology. *Stroke* 28(6):1278–1282
25. Amacher AL, Drake CG, Ferguson GG (1981) Posterior circulation aneurysms in young people. *Neurosurgery* 8 (3):315–320
26. Storrs BB, Humphreys RP, Hendrick EB, Hoffman HJ (1982) Intracranial aneurysms in the pediatric age-group. *Childs Brain* 9(5):358–361
27. Ferrante L, Acqui M, Trillo G, Lunardi P, Fortuna A (1996) Aneurysms of the posterior cerebral artery: do they present specific characteristics? *Acta Neurochir (Wien)* 138(7):840–852
28. Seoane ER, Tedeschi H, de Oliveira E, Siqueira MG, Calderon GA, Rhoton AL Jr (1997) Management strategies for posterior cerebral artery aneurysms: a proposed new surgical classification. *Acta Neurochir (Wien)* 139(4): 325–331
29. Day A, Gaposchkin CG, Yu C, Rivet D, Dacey R (2003) Spontaneous fusiform middle cerebral artery aneurysms: characteristics and a proposed mechanism of formation. *J Neurosurg* 99:228–240



30. Simpson RK Jr, Parker WD (1986) Distal posterior cerebral artery aneurysm. Case report. *J Neurosurg* 64 (4):669–672
31. Sundt TM (ed) (1990) *Surgical techniques for sacular and giant intracranial aneurysms*. Williams & Wilkins, Baltimore, pp 198–210
32. de Sousa AA, Dantas FL, Neto AP, Carvalho GT (1996) Giant posterior cerebral artery aneurysm in a 4-year-old child: case report. *Surg Neurol* 45 (1):31–35
33. Hayman JA, Anderson RM (1996) Dissecting aneurysm of the basilar artery. *Med J Aust* 2(8):360–361
34. Schoenberg BS, Mellinger JF, Schoenberg DG (1978) Cerebrovascular disease in infants and children: a study of incidence, clinical features, and survival. *Neurology* 28(8):763–768
35. Kim SH, Kosnik E, Madden C, Rusin J, Wack D, Bartkowski H (1997) Cerebellar infarction from a traumatic vertebral artery dissection in a child. *Pediatr Neurosurg* 27(2):71–77
36. Silverboard G, Tart R (2000) Cerebrovascular arterial dissection in children and young adults. *Semin Pediatr Neurol* 7(4):289–300
37. Ciceri EF, Klucznik RP, Grossman RG, Rose JE, Mawad ME (2001) Aneurysms of the posterior cerebral artery: classification and endovascular treatment. *AJNR Am J Neuroradiol* 22 (1):27–34
38. Edner G, Forster DM, Steiner L, Bergvall U (1978) Spontaneous healing of intracranial aneurysms after subarachnoid hemorrhage. Case report. *J Neurosurg* 48(3):450–454
39. Andrews BT, Edwards MS, Gannon P (1984) Acutely thrombosed aneurysm of the middle cerebral artery presenting as intracranial hemorrhage in a 3-year-old child. Case report. *J Neurosurg* 60 (6):1303–1307
40. Davila S, Oliver B, Molet J, Bartumeus F (1984) Spontaneous thrombosis of an intracranial aneurysm. *Surg Neurol* 22 (1):29–32
41. Waga S, Tochio H (1985) Intracranial aneurysm associated with moyamoya disease in childhood. *Surg Neurol* 23 (3):237–243
42. Choudhury AR, al Amiri NH, al Moutaery KR, Aabed M, Strelling MK (1991) Giant middle cerebral aneurysm presenting as hemiathetosis in a child and its spontaneous thrombosis. *Childs Nerv Syst* 7(1):59–61
43. Tanabe M, Inoue Y, Hori T (1991) Spontaneous thrombosis of an aneurysm of the middle cerebral artery with subarachnoid haemorrhage in a 6-year-old child: case report. *Neurol Res* 13 (4):202–204
44. Maeda K, Usui M, Tsutsumi K, Iijima A (1997) Spontaneous occlusion of a giant basilar tip aneurysm and a basilar artery due to the dissection of both structures: case report. *Surg Neurol* 48 (6):606–609
45. Loevner LA, Ting TY, Hurst RW, Goldberg HI, Schut L (1998) Spontaneous thrombosis of a basilar artery traumatic aneurysm in a child. *AJNR Am J Neuroradiol* 19(2):386–388
46. Moron F, Benndorf G, Akpek S, Dempsey R, Strother CM (2005) Spontaneous thrombosis of a traumatic posterior cerebral artery aneurysm in a child. *AJNR Am J Neuroradiol* 26 (1):58–60
47. Nass R, Hays A, Chutorian A (1982) Intracranial dissecting aneurysms in childhood. *Stroke* 13(2):204–207
48. Piske RL, Darwich R, Campos C, Fonseca N et al (1998) Spontaneous resolution of ruptured dissecting PICA aneurysm. Report of two cases. *Interv Neuroradiol* 4:287–292
49. Ciceri EF, Lawhead AL, De Simone T, Valvassori L, Boccardi E (2005) Spontaneous partial thrombosis of a basilar artery giant aneurysm in a child. *AJNR Am J Neuroradiol* 26(1):56–57
50. Black S, German W (1960) Observations of the relationship between the volume and the size of the orifice of the experimental aneurysms. *J Neurosurg* 17:984–990
51. Aoki N, Sakai T (1990) Rebleeding from intracranial dissecting aneurysm in the vertebral artery. *Stroke* 21 (11):1628–1631
52. Yamaura A, Watanabe Y, Saeki N (1990) Dissecting aneurysms of the intracranial vertebral artery. *J Neurosurg* 72(2):183–188
53. Mizutani T, Aruga T, Kirino T, Miki Y, Saito I, Tsuchida T (1995) Recurrent subarachnoid hemorrhage from untreated ruptured vertebrobasilar dissecting aneurysms. *Neurosurgery* 36 (5):905–911
54. Kurata A, Ohmomo T, Miyasaka Y, Fujii K, Kan S, Kitahara T (2001) Coil embolization for the treatment of ruptured dissecting vertebral aneurysms. *AJNR Am J Neuroradiol* 22(1):11–18
55. Mizutani T, Kojima H, Asamoto S (2004) Healing process for cerebral dissecting aneurysms presenting with subarachnoid hemorrhage. *Neurosurgery* 54(2):342–347
56. Yamada M, Kitahara T, Kurata A, Fujii K, Miyasaka Y (2004) Intracranial vertebral artery dissection with subarachnoid hemorrhage: clinical characteristics and outcomes in conservatively treated patients. *J Neurosurg* 101 (1):25–30
57. Yoshimoto Y, Wakai S (1997) Unruptured intracranial vertebral artery dissection. Clinical course and serial radiographic imagings. *Stroke* 28 (2):370–374
58. Terasaka S, Sawamura Y, Kamiyama H, Fukushima T (2000) Surgical approaches for the treatment of aneurysms on the P2 segment of the posterior cerebral artery. *Neurosurgery* 47(2):359–364
59. Berger MS, Wilson CB (1984) Intracranial dissecting aneurysms of the posterior circulation. Report of six cases and review of the literature. *J Neurosurg* 61(5):882–894
60. Friedman AH, Drake CG (1984) Subarachnoid hemorrhage from intracranial dissecting aneurysm. *J Neurosurg* 60 (2):325–334
61. Yamaura A, Watanabe Y, Saeki N (1990) Dissecting aneurysms of the intracranial vertebral artery. *J Neurosurg* 72(2):183–188
62. Andoh T, Shirakami S, Nakashima T et al (1992) Clinical analysis of a series of vertebral aneurysm cases. *Neurosurgery* 31:987–993
63. Steinberg GK, Drake CG, Peerless SJ (1993) Deliberate basilar or vertebral artery occlusion in the treatment of intracranial aneurysms. Immediate results and long-term outcome in 201 patients. *J Neurosurg* 79(2):161–173
64. Durward QJ (1995) Treatment of vertebral artery dissecting aneurysm by aneurysm trapping and posterior inferior cerebellar artery reimplantation. Case report. *J Neurosurg* 82(1):137–139
65. Yamaura I, Tani E, Yokota M, Nakano A, Fukami M, Kaba K, Matsumoto T (1999) Endovascular treatment of ruptured dissecting aneurysms aimed at occlusion of the dissected site by using Guglielmi detachable coils. *J Neurosurg* 90(5):853–856
66. Solomon R (2000) Discussion on: Terasaka S, Sawamura Y, Kamiyama H, Fukushima T. Surgical approaches for the treatment of aneurysms on the P2 segment of the posterior cerebral artery. *Neurosurgery* 47(2):365
67. Taylor C, Kopitnik T, Samson D, Purdy P (2003) Treatment and outcome in 30 patients with posterior cerebral artery aneurysms. *J Neurosurg* 99:15–22

- 
68. Gerber C, Neil-Dwyer G, Evans B (1993) An alternative surgical approach to aneurysms of the posterior cerebral artery. *Neurosurgery* 32:928–931
  69. Hallacq P, Piotin M, Moret J (2002) Endovascular occlusion of the posterior cerebral artery for the treatment of p2 segment aneurysms: retrospective review of a 10-year series. *AJNR Am J Neuroradiol* 23:1128–1136
  70. Vishteh A, Smith, Kris A, McDougall C, Spetzler R (1998) Distal posterior cerebral artery revascularization in multimodality management of complex peripheral posterior cerebral artery aneurysms: technical case report. *Neurosurgery* 43:166–170
  71. Drake CG (1997) Giant posterior cerebral aneurysms: 66 patients. In: Drake CG, Peerless SJ, Hernesniemi JA (eds.) *Surgery of vertebrobasilar aneurysms: London, Ontario, Experience on 1767 patients*. Springer, Berlin Heidelberg New York, pp 230–248
  72. Zeal AA, Rhoton AL Jr (1978) Microsurgical anatomy of the posterior cerebral artery. *J Neurosurg* 48:534–559
  73. Fletcher TM, Taveras JM, Pool JL (1959) Cerebral vasospasm in angiography for intracranial aneurysms. Incidence and significance in one hundred consecutive angiograms. *Arch Neurol* 1:38
  74. Lin JP (1969) Thrombosis of aneurysm of anterior communicating artery. Case report. *Acta Radiol* 8:74–80
  75. Spetzler R, Winestock D, Newton H et al (1974) Disappearance and reappearance of cerebral aneurysm in serial arteriograms. Case report. *J Neurosurg* 41:508–510
  76. Fodstad H, Liliequist B (1979) Spontaneous thrombosis of ruptures intracranial aneurysms during treatment with tranexamic acid (AMCA). Report of three cases. *Acta Neurochir* 49:129–144
  77. Atkinson J, Lane J, Colbassani H et al (1993) Spontaneous thrombosis of posterior cerebral artery aneurysm with angiographic reappearance. *J Neurosurg* 79:434–437
  78. Lee KC, Joo JY, Lee KS, Shin YS (1999) Recanalization of completely thrombosed giant aneurysm: case report. *Surg Neurol* 51(1):94–98