

## EMERGENCY CASEBOOK

## Cerebral venous sinus thrombosis presenting in the puerperium

J Acheson, A Malik

*Emerg Med J* 2006;23:e44 (<http://www.emjonline.com/cgi/content/full/23/7/e44>). doi: 10.1136/emj.2006.035550

Cerebral venous sinus thrombosis is an uncommon disorder that can present with a wide range of signs and symptoms. We describe a case presenting in the puerperium of a young woman and the investigations undertaken.

## CASE REPORT

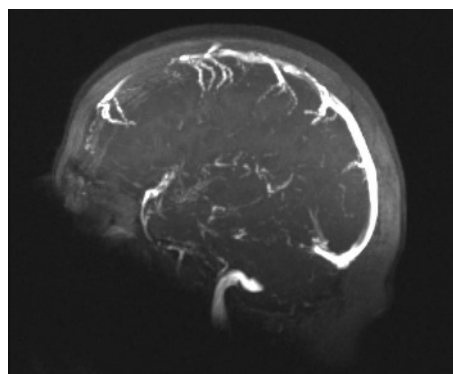
A 27 year old woman with a 10 day history of an increasing dull headache presented to the emergency department with three tonic-clonic seizures over a 90 minute period. Each seizure lasted between one and two minutes in duration. She was three weeks post partum following a normal vaginal delivery. The pregnancy was healthy with no complications. There was no history of epilepsy.

On examination her airway was maintained with a nasopharyngeal airway. Air entry was equal bilaterally. Basic observations revealed: heart rate 68 beats/min, blood pressure 108/56 mm Hg, temperature 36.8 °C and blood glucose 4.8 mmol/l. The Glasgow Coma Scale (GCS) score initially was 7/15 (M5, E1, V1) and pupils were equal and reactive to light with no focal neurology. There was no evidence of a petechial rash. The seizures were controlled with intravenous lorazepam and a loading dose of intravenous phenytoin. Broad spectrum antibiotic cover was given in the form of intravenous cefuroxime and metronidazole. An arterial blood gas on 15L O<sub>2</sub> revealed an uncompensated metabolic acidosis with pH 7.142, P<sub>O</sub><sub>2</sub> 301.68 mm Hg (40.22 kPa), P<sub>CO</sub><sub>2</sub> 40.88 mm Hg (5.45 kPa), HCO<sub>3</sub> 13.7 mmol/l, base excess (BE) -14.7 mmol/l. Urea and electrolytes were normal and inflammatory markers showed white cell count 11.4×10<sup>9</sup>/l and C-reactive protein (CRP) <5 mg/l.

She was intubated for a computed tomography (CT) brain scan that showed high density in the region of the left transverse sinus suggestive of thrombosis. After CT she was extubated and her GCS improved to 15/15. A magnetic resonance venogram out of hours confirmed a left transverse venous thrombosis (fig 1). The patient was transferred to the medical team, and she made an uneventful recovery. Low molecular weight heparin and oral phenytoin were commenced with warfarinisation later. Follow up at the haematology outpatient clinic was arranged, where a thrombophilia screen was to be performed after six months of warfarinisation.

## DISCUSSION

Cerebral venous sinus thrombosis has a variety of clinical presentations ranging from isolated headaches to deep coma. The incidence is increasing to 7 per 1 000 000 as newer and more advanced imaging modalities emerge.<sup>1</sup> Females are more commonly affected than males, with a ratio of 1.29:1.<sup>2</sup> It presents more commonly among women in the 20–35 year age group.<sup>2</sup> There is no race predilection, and the associated mortality is reported to be 7%.<sup>3</sup> The pathogenesis includes infection, trauma, pregnancy and the puerperium, inflammatory bowel disease, and hypercoagulable states.



**Figure 1** Magnetic resonance venogram showing a left transverse venous thrombosis.

Imaging studies remain the cornerstone of diagnosis. A CT scan is usually the first image requested in the emergency department. However, the diagnosis of cerebral venous sinus thrombosis is made on the appearance of the delta sign, a feature which is frequently absent on CT scans. The imaging modality of choice is magnetic resonance venography as it allows direct visualisation of the dural venous sinuses and the large cerebral veins.<sup>4</sup> It is an invasive procedure with catheterisation of the jugular vein and therefore has associated risks.

Treatment options for cerebral venous sinus thrombosis include anticoagulation, thrombolytic therapy, and, in some cases, surgical thrombectomy. Prospective studies have reported an independent survival rate of approximately 80%.<sup>5</sup> The risk of recurrent cerebral venous sinus thrombosis in future pregnancies and the puerperium is low.<sup>6</sup>

## CONCLUSION

Cerebral venous sinus thrombosis is a potentially life threatening condition if it is undiagnosed, but it remains a treatable disorder. The diagnosis should be considered in all women presenting with neurological symptoms during pregnancy or the puerperium.

## Authors' affiliations

J Acheson, A Malik, Emergency Department, Leicester Royal Infirmary, Leicester, UK

Competing interests: none declared

Informed consent was obtained for publication of the person's details in this report.

Correspondence to: Dr J Acheson, Emergency Department, Leicester Royal Infirmary, Infirmary Square, Leicester, LE1 5WW, UK; [achesonjonny@hotmail.com](mailto:achesonjonny@hotmail.com)

Accepted for publication 18 February 2006

**REFERENCES**

- 1 **Daif A**, Awada A, al-Rajeh S, *et al*. Cerebral venous thrombosis in adults. A study of 40 cases from Saudi Arabia. *Stroke* 1995;**26**:1193-5.
- 2 **Ameri A**, Bousser MG. Cerebral venous thrombosis. *Neurol Clin* 1992;**10**:87-111.
- 3 **Ferro JM**, Lopes MG, Rosas MJ, *et al*. Long term prognosis of cerebral vein and dural sinus thrombosis. Results of the venoport study. *Cerebrovasc Dis* 2002;**13**:272-8.
- 4 **Fink JN**, McAuley DL. Cerebral venous sinus thrombosis: a diagnostic challenge. *Intern Med J* 2001;**31**:384-90.
- 5 **Masuhr F**, Hehraein S, Einhaupl K. Cerebral venous sinus thrombosis. *J Neural* 2004;**251**:11-23.
- 6 **Mehraein S**, Ortwein H, Busch M, *et al*. Risk of recurrence of cerebral venous and sinus thrombosis during subsequent pregnancy and puerperium. *J Neural Neurosurg Psychiatry* 2003;**74**:814-16.