

PostScript

LETTERS

Rostral cingulate motor area and paroxysmal alien hand syndrome

Alien hand syndrome (AHS) is characterised by abnormal motor behaviour of the contralateral upper limb, which is subjectively experienced as involuntary or alien induced.¹ The affected hand often shows a grasp reflex and an instinctive grasp reaction, as well as elements of "magnetic apraxia" associated with frontal lobe damage. The most common frontal type of AHS is repeatedly observed in patients with lesions in the supplementary motor area, anterior cingulate gyrus, medial prefrontal cortex, and anterior corpus callosum. Involuntary uncontrolled movements in AHS usually remain unchanged or improve gradually over periods of varying length. A paroxysmal form of alien hand syndrome has been described very rarely. In these exceptional cases, focal epileptic seizures were suspected to be the pathophysiological substrate for paroxysmal alien limb phenomena.^{2,3}

Case report

We report a 61 year old right handed man with a paroxysmal form of alien hand syndrome resulting from an ischaemic lesion within the rostral part of the right cingulate motor area (CMA) (fig 1A). Short episodes with typical spontaneous involuntary movements of his left hand (groping, scratching, grasping) developed suddenly four days before patient's admission to our ward. At that time, normal glycaemia and a transient increase in blood pressure (200/100 mm Hg) were observed. A neurological examination revealed normal findings with the exception of positive grasp reflex on the affected upper limb. Magnetic resonance imaging (MRI) on the same day disclosed circumscribed hyperintense lesion with a 12 mm diameter in the right anterior cingulate cortex. Cerebrospinal fluid examination and an interictal EEG was normal. All "alien hand" episodes started and terminated suddenly; they occurred every 15 minutes and their duration was one to three minutes. The patient was fully conscious during the seizures. He experienced the abnormal motor behaviour of his left hand as involuntary. He was unable to control these hand movements despite great effort. The abnormal movements were repeatedly directed towards external stimuli. A gradual increase in seizure frequency was observed in subsequent days, and discrete myoclonic jerks and slight tonic posturing of the left upper extremity were added to the typical hand automatisms. An FDG-PET investigation showed focal hypermetabolism of the right CMA (corresponding precisely to the structural MRI lesion) and repeated video-EEG monitoring clearly revealed the ictal epileptic mechanism of the "alien hand" seizures (fig 1, panels B and C). A neuropsychological examination revealed no speech problems or problems with bimanual coordination. The paroxysmal complex motor activities of the left upper limb completely disappeared immediately after antiepileptic drug treatment (levetiracetam) was begun.

Control MRI (done after three days, two weeks, and three months) confirmed an ischaemic aetiology of the structural lesion.

Comment

Studies on primates, and increasing evidence in humans, support the notion that the anterior cingulate cortex is strongly involved in the preparation and execution of movements. A specific role may be played by an area that encompasses the ventral bank of the cingulate sulcus and is located just behind and in front of the vertical plane that passes through the anterior commissure (VCA). This region corresponds to the simian rostral cingulate motor area (rCMA); in humans it contains gigantopyramidal neurones which resemble the Betz pyramidal cells of the primary motor cortex. The projections of this area 24c (rCMA) target mainly the rostral portion of the SMA (medial area 6a β).⁴ Interestingly, electrical stimulation of this area, undertaken recently in one epileptic patient, provoked "an irresistible urge to grasp something, ..., accompanied by a wandering arm movement contralateral to the stimulation side".⁵

Based on this finding, an engagement of CMA in compulsive goal directed motor behaviour in humans was suggested. Our present observation clearly demonstrated that even limited impairment of the rostral part of the CMA may produce the clinical alien hand syndrome. It is noteworthy that the structural lesion in AHS patients often encroaches on the supplementary motor area and the middle section of the corpus callosum, and it is therefore difficult to define the precise involvement of the anterior cingulate cortex.

Unequivocal proof of the epileptic origin of paroxysmal AHS represents another important aspect of the present case report. To date, only three patients with an epileptogenic lesion within the frontomedial cortex manifesting with paroxysmal alien limb phenomena have been analysed in the literature. In the light of the seriously limited published sources, our findings provide evidence of an underlying epileptic mechanism in paroxysmal AHS. The ictal EEG pattern in our subject was obtained on the third day after his admission, when a slight tonic posturing of the left upper extremity had already been

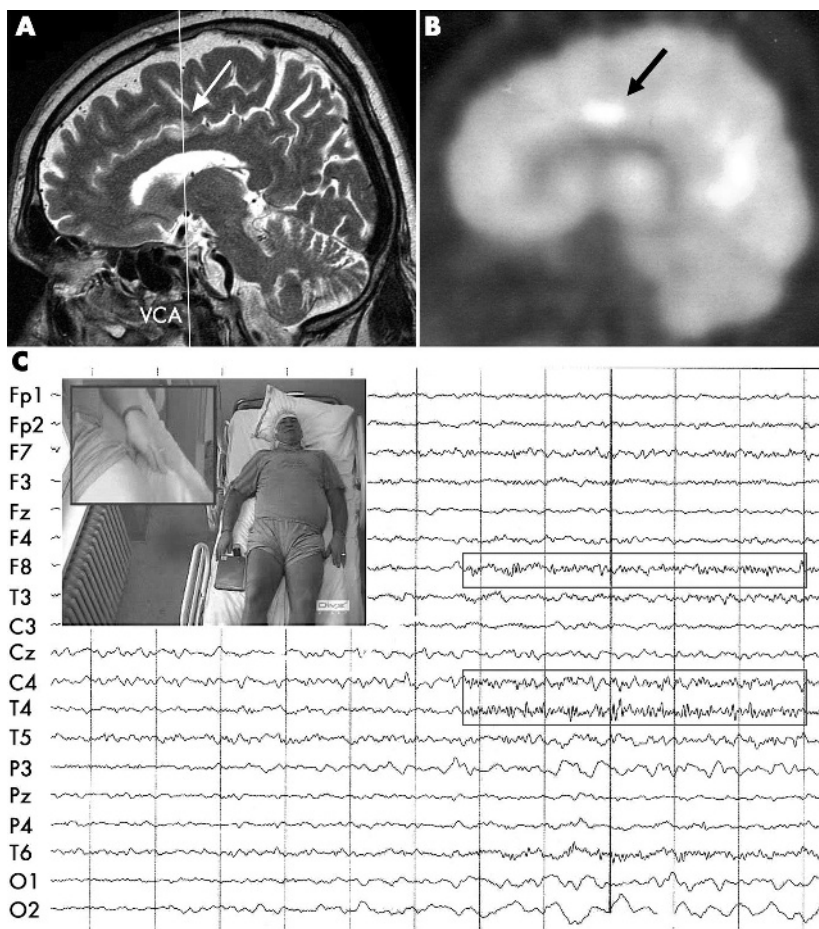


Figure 1 (A) Sagittal T2 weighted magnetic resonance imaging showing the hyperintense lesion in the rostral cingulate motor area (CMA) (day 4); VCA, vertical plane passing through the anterior commissure. (B) FDG-PET scan. (C) Video-EEG trace (ictal pattern (spiking) in the right F-C-T region time locked with an alien hand episode).

added to the typical “alien hand” automatisms (fig 1C). The spreading of the ictal activity from rCMA to premotor and motor cortical areas resulting in the additional tonic phenomena is highly probable. The ictal EEG recordings from the date of the patient’s admission with pure ictal “alien hand” signs revealed only very discrete non-specific changes in the central and right paracentral region (Cz and C4). In this case, an underlying ictal activity in the “hidden” lesional/perilesional region is strongly anticipated. But absolute certainty that the rCMA is solely responsible for the paroxysmal “alien hand” syndrome could only be drawn from invasive EEG investigation or electrical cortical stimulation. This treatment was not necessary for clinical reasons and thus was not undertaken in our patient.

In conclusion, rostral CMA very probably plays a crucial role in the production of ictal automatic motor behaviour of the contralateral hand. This finding may further implicate the participation of this part of the caudal anterior cingulate cortex in the genesis of ictal limb automatisms in epileptic patients.

Acknowledgements

We are grateful to Drs J Vaníček and K Bolčák for their neuroimaging contributions.

M Brázdil, R Kuba, I Rektor

Brno Epilepsy Centre, Department of Neurology, St Anne’s University Hospital, Brno, Czech Republic

Correspondence to: Dr Milan Brázdil, Brno Epilepsy Centre, Department of Neurology, St Anne’s University Hospital, Brno 656 91, Czech Republic; mbrazd@med.muni.cz

doi: 10.1136/jnnp.2005.082529

Competing interests: none declared

References

- 1 **Brion S**, Jedynak CP. Disorders of interhemispheric transfer (callosal disconnection). 3 cases of tumor of the corpus callosum. The strange hand sign. *Rev Neurol* 1972;126:257–66.
- 2 **Leiguarda R**, Starkstein S, Nogues M, et al. Paroxysmal alien hand syndrome. *J Neurol Neurosurg Psychiatry* 1993;56:788–92.
- 3 **Boesebeck F**, Ebner A. Paroxysmal alien limb phenomena due to epileptic seizures and electrical cortical stimulation. *Neurology* 2004;63:1725–7.
- 4 **Paus T**, Petrides M, Evans AC, et al. Role of the human anterior cingulate cortex in the control of oculomotor, manual, and speech responses: a positron emission tomography study. *J Neurophysiol* 1993;70:453–69.
- 5 **Kremer S**, Chassagnon S, Hoffmann D, et al. The cingulate hidden hand. *J Neurol Neurosurg Psychiatry* 2001;70:264–5.

Atypical micrographia associated with corticostriatal white matter lesions in systemic lupus erythematosus

Micrographia is a heterogeneous condition in which various parts of the CNS may be involved. An anatomical substrate for micrographia, however, remains to be established. Here, we report on a patient with systemic lupus erythematosus (SLE), who presented with atypical micrographia, which was associated with bilateral lesions in the corticostriatal white matter.

Case report

A 30-year-old right-handed woman was diagnosed as having SLE in 2002. She had concomitant leukocytopenia, arthritis, nephritis and high titres of antinuclear antibodies, which satisfied the American Rheumatism Association criteria for SLE. Thereafter, maintenance treatment using corticosteroids was started. She was admitted to the Niigata University Medical and Dental Hospital, Niigata, Japan, in February 2005, because of a high fever and headache with affective incontinence.

Examination showed her muscle strength and the sensory function of her extremities to be normal. She did not have involuntary movements or akinetic-rigid symptoms, as her gait was normal and no rigidity was observed in the neck, body and extremities. No impairment was seen in the rapid alternative movements of her hands. She was well oriented and cooperative. Aphasia was absent; her speech was well articulated and grammatically correct, and she had no difficulty in naming objects. She had no abnormalities in praxis, showing an excellent capacity in imitating and pantomiming, and in using tools with either hand. She could perform a fist-palm-alternating task swiftly. Orofacial apraxia, visuospatial disturbance, unilateral spatial neglect or visual agnosia was not observed. She had no memory impairment. No general intellectual deterioration was seen; her score in the revised Hasegawa Dementia Scale, which is widely used for intellectual screening in Japan, was 28 of 30 (cut-off 20/30).

During the neuropsychological evaluation, the quality of the patient’s spontaneous handwriting deteriorated—that is, the characters or drawings were always small. To evaluate this symptom in detail, we asked the patient to write a Japanese character and a Roman alphabet repetitively, and draw a triangle, a circle, a square and a star in a

manner identical to the samples given by the examiner. The initial characters of the patient’s handwriting were smaller than those in the samples, and the small size of the characters was constant throughout the sequence of her handwriting (fig 1A). Furthermore, a marked initial reduction in size was observed in the symbols drawn compared with the corresponding samples (fig 1B). These copying tasks were carried out using her dominant (right) hand. Neither hesitation nor slowness in handwriting was observed. The patient could correctly evaluate the size of objects, as she could sort various objects on the table by size. She acknowledged the disorder, complaining that she could write only such small characters or symbols despite great efforts to write in the same size as that in the samples.

Examination of CSF showed a normal cell count, although a mild rise was observed in IgG level. The patient tested negative for serum antiphospholipid antibodies. MRI of the brain carried out on day 2 of admission showed hyperintensity signal lesions in the bilateral dorsal part of the striatum and adjacent white matter on T2-weighted and diffusion-weighted images (fig 2A). These lesions were contrast enhanced with gadolinium. The other parts of the CNS, however, were intact. Single-photon emission CT using ethyl cystine dimer labelled with technetium-99m carried out on day 12 of admission showed a decreased perfusion of the bilateral striatum and surrounding white matter.

After treatment with 1000 mg of methylprednisolone for 5 days, the initial reduction in the size of handwriting had improved (fig 1C). MRI of the brain carried out 3 months after the treatment showed that the white matter lesions had reduced in size (fig 2B).

Informed consent was obtained from the patient before carrying out the evaluations and giving treatment.

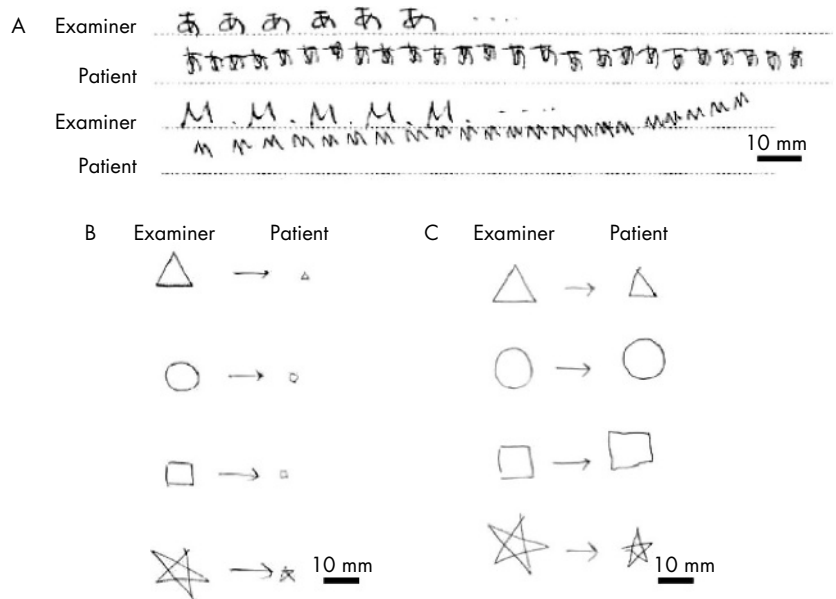


Figure 1 (A) Repetitive writing of a Japanese character and a Roman alphabet was requested. The sizes of the characters and letters in the patient’s handwriting are smaller than those in the examiner’s handwriting, and this small size is constant throughout the handwriting sequence. (B) Before the steroid pulse treatment, a marked initial reduction in size is observed on drawing a triangle, a circle, a square and a star. (C) The initial reduction in size is obviously improved after the steroid pulse treatment.