

Short communication

Acute encephalopathy with refractory status epilepticus: Bilateral mesial temporal and claustral lesions, associated with a peripheral marker of oxidative DNA damage

Takashi Shiihara^{a,*}, Mitsuhiro Kato^a, Takashi Ichiyama^b, Yukitoshi Takahashi^c,
Naoyuki Tanuma^d, Rie Miyata^e, Kiyoshi Hayasaka^a

^a Department of Pediatrics, Yamagata University School of Medicine, 2-2-2 Iida-nishi, Yamagata 990-9585, Japan

^b Department of Pediatrics, Yamaguchi University School of Medicine, 1-1-1 Minamikogushi, Ube, Yamaguchi 755-8505, Japan

^c National Epilepsy Center, Shizuoka Institute of Epilepsy and Neurological Disorders, 886 Urushiyama, Shizuoka 420-8688, Japan

^d Department of Pediatrics, Metropolitan Fuchu Medical Center for Severe Motor and Intellectual Disabilities, 2-9-2, Musashidai, Fuchu, Tokyo 183-0042, Japan

^e Department of Pediatrics, Tokyo Kita Shakai Hoken Hospital, 4-17-56, Akabanedai, Kita-ku, Tokyo 115-0053, Japan

Received 28 March 2006; received in revised form 20 June 2006; accepted 12 July 2006

Available online 28 August 2006

Abstract

We describe a 12-year-old girl, who had been medicated with theophylline for bronchial asthma and developed acute encephalopathy with refractory status epilepticus, showing bilateral mesial temporal and claustral lesions, which were evident on fluid-attenuated inversion recovery images, obtained with 1.5 T magnetic resonance imaging. To date, oxidative stress has been implicated in aging or various disorders, including inflammatory or degenerative neurological disorders. One of the oxidative stress markers, 8-hydroxydeoxyguanosine, was increased in our patient's cerebro-spinal fluid, plasma and urine. We speculate that augmented oxidative stress was associated with refractory status epilepticus in our patient, accompanying bilateral mesial temporal, claustral lesions and severe neuronal damage. Serial measurements of oxidative stress markers in acute encephalitis, encephalopathy, or status epilepticus could clarify the relationships between acute brain damage and free radicals.

© 2006 Elsevier B.V. All rights reserved.

Keywords: Acute encephalopathy; Status epilepticus; Theophylline; 8-hydroxydeoxyguanosine; Oxidative stress; Claustrum

1. Introduction

Acute encephalopathy or encephalitis presenting with refractory status epilepticus is rare, but results in severe mortality, and the known etiologies are diverse, including infection, metabolic derangement, hypoxia–ischemia, and intoxication. However, a certain part of the pathophysiology remains an enigma [1–3]. To date, oxidative damage has been implicated in aging or various disorders, including

inflammatory or degenerative neurological disorders [4]. We report a patient with acute encephalopathy presenting with refractory status epilepticus, showing bilateral mesial temporal and claustral lesions, which could be related to DNA oxidative damage.

2. Case report

A 12-year-old girl developed frequent tonic convulsions and was admitted to our hospital after mild drowsiness and fever for 7 days. Since 9 years of age, she had been medicated with theophylline (300 mg/day) with a blood level of 6.7 µg/ml for bronchial asthma. There was no history of neurological disorders nor any contributory family histories.

* Corresponding author. Department of Neurology, Gunma Children's Medical Center, 779 Shimohakoda, Hokkitsu-machi, Shibukawa, Gunma 377-8577, Japan. Tel.: +81 279 52 3551; fax: +81 279 52 2045.

E-mail address: shiihara-ind@umin.net (T. Shiihara).

She showed consciousness disturbance without focal neurological signs. Routine hematology, blood chemistry, cranial computed tomography and magnetic resonance imaging (MRI) on day 7 of illness did not detect any abnormalities. Cerebro-spinal fluid (CSF) examinations on day 7 and 10 yielded normal findings, including cell count, glucose, protein, bacterial and viral cultures, polymerase chain reactions for herpes simplex and enteroviruses, and autoantibodies against the glutamate receptors, except for elevations of cytokines; interleukin-2, 4 and 6 were 5.0 pg/ml (normal control <4.6), 13.9 pg/ml (normal control <11.6) and 83.9 pg/ml (normal control <9.7), respectively. Oxidative stress marker, 8-hydroxydeoxyguanosine (8-OHdG) was measured with a commercial enzyme-linked immunosorbent assay kit (highly sensitive 8-OHdG check; Japan Institute for the Control of Aging, Shizuoka, Japan. More information is available at <http://www.jaica.com/biotech/>) [5]. The levels of 8-OHdG concentration in CSF on day 10, plasma on day 8 and 17 were 0.070, not detected and 0.245 ng/ml (not detected in normal control), respectively. Urine 8-OHdG/creatinine ratio was 36.6 ng/mg creatinine (normal control 12.1 ± 5.5 , mean \pm SD) on day 23 [6,7]. Because 8-OHdG was measured retrospectively with stored samples, data from other days were not available. Although the fever subsided, seizures progressed to an intractable status; focal clonic convulsions involving the face or extremities generalized after intervals of a few minutes. Electroencephalography showed multifocal spikes or sharp waves, tending to burst. Conventional anti-epileptic drugs, including phenobarbital, phenytoin and valproate, and anesthetic agents, including midazolam, thiamylal and propofol, failed. Thiopental alleviated seizures, but withdrawal resulted in seizure recurrence. Cranial MRI on day 27 demonstrated bilateral mesial temporal and claustral lesions (Fig. 1). Thiopental was stopped on day 82 due to side effects, such as leukopenia, hypotension, atelectasis, thrombophlebitis, renal failure and liver failure. Thereafter,

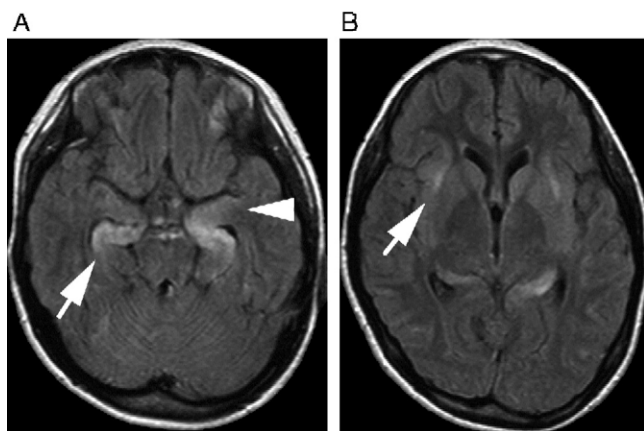


Fig. 1. Axial fluid-attenuated inversion recovery (FLAIR) images (TR/TE/TI 6000/120/2100 ms), using a 1.5 T imager, on day 27 showed high signal lesions in both hippocampi (arrow), amygdalae (arrowhead) (A), and claustrum (arrow) (B).

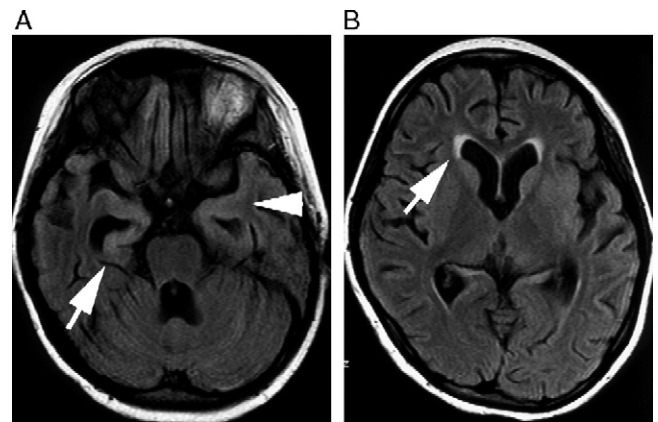


Fig. 2. Axial FLAIR images (TR/TE/TI 8002/104/2000 ms), using a 1.5 T imager, on day 101 showed high signal lesions in both hippocampi (arrow), amygdalae (arrowhead) (A) and ventricular rims (arrow) (B). Cerebellar and cerebral atrophy were evident.

phenytoin and high-dose phenobarbital were administered to reduce seizures. Cranial MRI on day 101 showed severe brain atrophy, and bilateral mesial temporal lesions (Fig. 2). Seven months after the onset, she could not speak or sit alone.

3. Discussion

Deoxyguanosine is one of the constituents of DNA and when it is oxidized, it is altered to 8-OHdG, which is considered a key biomarker of oxidative DNA damage [4]. Furthermore, 8-OHdG is increased in aging or diverse disorders, such as neoplasm, neurodegenerative disorders, cardiovascular disease, diabetes mellitus and inflammatory disorders [4,5,8]. Moreover, 8-OHdG is increased within the brain, including the amygdala and hippocampus, in the seizure-induced rat and it is associated with increased DNA fragmentation, resulting in neuronal cell death [9]. The high levels of 8-OHdG concentrations in our patient's CSF, plasma and urine, indicate that oxidative stress plays a key role in our patients, resulting in severe neuronal damage.

Clastrum, a thin sheet of gray matter between the insula and putamen, is affected in several disorders. However, the pathophysiology of these disorders remains obscure [10]. We hypothesize that oxidative stress plays some role in claustral lesions. Claustrum as well as the cortex, amygdala and hippocampus, contains nitric oxide-producing neurons, which were involved in our patient [11,12]. Neurotoxicity in rats with kainic acid-induced status epilepticus is associated with increments in nitric oxide, possibly resulting in augmented oxidative stress in these regions [12]. Other studies also show that disorders involving the claustrum, such as ischemia–hypoxia, Wilson's disease, mitochondrial disorders, and encephalitis are associated with augmented oxidative stress [10,13–16].

Theophylline affects the seizure threshold, and we speculate that theophylline was associated with a protracted course in our patient [17]. Although, the theophylline blood

level in our patient was within the accepted therapeutic range, Delanty et al. reported that a surprisingly high rate of status epilepticus patients (eleven out of 41; 27%) were taking theophylline at the time status epilepticus developed and all except one had shown standard therapeutic blood levels [18]. Theophylline-induced seizures in mice may be associated with free radicals, which also suggests a causative role of augmented oxidative stress in our patient [19]. Drugs other than theophylline, including anti-epileptic drugs and anesthetic agents, could affect oxidative stress, however, their effects were not one-way; some might augment oxidative stress, others could reduce it [20–24].

There are some difficulties with chronological analysis among symptoms, cranial MRI findings, and 8-OHdG levels, because 8-OHdG serial examinations were lacking and MRI examinations had long intervals. Convulsions started on day 7, but cranial MRI on day 7 revealed no abnormalities, plasma 8-OHdG was not detected on day 8, CSF 8-OHdG was detected on day 10, urinary 8-OHdG was high on day 23, and cranial MRI on day 27 demonstrated bilateral mesial temporal and claustral lesions. In rat experimental models, systemic kainic acid, which induces seizures, increased cerebral 8-OHdG levels, up to seven-fold within 72 h [9]. This is compatible with our patient's course. Oxidative DNA damage could be evoked within a few days after status epilepticus and neuroimaging changes may continue for some time beyond this.

In conclusion, it is possible that oxidative stress was associated with refractory status epilepticus in our patients, accompanying bilateral mesial temporal, claustral lesions and severe neuronal damage, which is partly due to theophylline. There may be a vicious cycle; refractory status epilepticus could result in limbic lesions and limbic lesions could worsen the refractoriness of status epilepticus itself. Serial measurements of oxidative stress markers, including 8-OHdG in acute encephalitis, encephalopathy or status epilepticus could clarify the relationships between acute brain damage and free radicals.

References

- [1] Sagduyu A, Tarlaci S, Sirin H. Generalized tonic-clonic status epilepticus: causes, treatment, complications and predictors of case fatality. *J Neurol* 1998;245:640–6.
- [2] Sahin M, Menache CC, Holmes GL, Riviello JJ. Outcome of severe refractory status epilepticus in children. *Epilepsia* 2001;42:1461–7.
- [3] Baxter P, Clarke A, Cross H, Harding B, Hicks E, Livingston J, et al. Idiopathic catastrophic epileptic encephalopathy presenting with acute onset intractable status. *Seizure* 2003;12:379–87.
- [4] Cooke MS, Evans MD, Dizdaroglu M, Lunec J. Oxidative DNA damage: mechanisms, mutation, and disease. *FASEB J* 2003;17:1195–214.
- [5] Sato S, Mizuno Y, Hattori N. Urinary 8-hydroxydeoxyguanosine levels as a biomarker for progression of Parkinson disease. *Neurology* 2005;64:1081–3.
- [6] Hata I, Kaji M, Hirano S, Shigematsu Y, Tsukahara H, Mayumi M. Urinary oxidative stress markers in young patients with type 1 diabetes. *Pediatr Int* 2006;48:58–61.
- [7] Kimura S, Yamauchi H, Hibino Y, Iwamoto M, Sera K, Ogino K. Evaluation of urinary 8-hydroxydeoxyguanosine in healthy Japanese people. *Basic Clin Pharmacol Toxicol* 2006;98:496–502.
- [8] Calabrese V, Lodi R, Tonon C, D'Agata V, Sapienza M, Scapagnini G, et al. Oxidative stress, mitochondrial dysfunction and cellular stress response in Friedreich's ataxia. *J Neurol Sci* 2005;233:145–62.
- [9] Lan J, Henshall DC, Simon RP, Chen J. Formation of the base modification 8-hydroxy-2'-deoxyguanosine and DNA fragmentation following seizures induced by systemic kainic acid in the rat. *J Neurochem* 2000;74:302–9.
- [10] Sener RN. Lesions affecting the claustrum. *Comput Med Imaging Graph* 1998;22:57–61.
- [11] Guirado S, Real MA, Olmos JL, Davila JC. Distinct types of nitric oxide-producing neurons in the developing and adult mouse claustrum. *J Comp Neurol* 2003;465:431–44.
- [12] Gupta RC, Dettbarn WD. Prevention of kainic acid seizures-induced changes in levels of nitric oxide and high-energy phosphates by 7-nitroindazole in rat brain regions. *Brain Res* 2003;981:184–92.
- [13] Lin RenJye, Liao ChingLen, Lin YiLing. Replication-incompetent virions of Japanese encephalitis virus trigger neuronal cell death by oxidative stress in a culture system. *J Gen Virol* 2004;85:521–33.
- [14] Wallace DC. Mitochondrial diseases in man and mouse. *Science* 1999;283:1482–8.
- [15] Oliver CN, Starke-Reed PE, Stadtman ER, Liu GJ, Carney JM, Floyd RA. Oxidative damage to brain proteins, loss of glutamine synthetase activity, and production of free radicals during ischemia/reperfusion-induced injury to gerbil brain. *Proc Natl Acad Sci U S A* 1990;87:5144–7.
- [16] Watt NT, Hooper NM. The response of neurones and glial cells to elevated copper. *Brain Res Bull* 2001;55:219–24.
- [17] Tchekalarova J, Kambourova T, Georgiev V. Long-term theophylline treatment changes the effects of angiotensin II and adenosinergic agents on the seizure threshold. *Brain Res Bull* 2000;52:13–6.
- [18] Delanty N, French JA, Labar DR, Pedley TA, Rowan AJ. Status epilepticus arising de novo in hospitalized patients: an analysis of 41 patients. *Seizure* 2001;10:116–9.
- [19] Gulati K, Ray A, Pal G, Vijayan VK. Possible role of free radicals in theophylline-induced seizures in mice. *Pharmacol Biochem Behav* 2005;82:241–5.
- [20] Schulpis KH, Lazaropoulou C, Regoutas S, Karikas GA, Margeli A, Tsakiris S, et al. Valproic acid monotherapy induces DNA oxidative damage. *Toxicology* 2006;217:228–32.
- [21] Komatsu M, Hiramatsu M, Willmore LJ. Zonisamide reduces the increase in 8-hydroxy-2'-deoxyguanosine levels formed during iron-induced epileptogenesis in the brains of rats. *Epilepsia* 2000;41:1091–4.
- [22] Tsuchiya M, Asada A, Maeda K, Ueda Y, Sato EF, Shindo M, et al. Propofol versus midazolam regarding their antioxidant activities. *Am J Respir Crit Care Med* 2001;163:26–31.
- [23] Wilson JX, Gelb AW. Free radicals, antioxidants, and neurologic injury: possible relationship to cerebral protection by anesthetics. *J Neurosurg Anesthesiol* 2002;14:66–79.
- [24] Delogu G, Antonucci A, Moretti S, Marandola M, Tellan G, Signore M, et al. Oxidative stress and mitochondrial glutathione in human lymphocytes exposed to clinically relevant anesthetic drug concentrations. *J Clin Anesth* 2004;16:189–94.